



Contents lists available at ScienceDirect

JPRAS Open

journal homepage: www.elsevier.com/locate/jpra



Single stage reconstruction of complex head and neck defects involving the skin with a single ALT flap: A ten year review ☆

Umberto Caliceti^a, Rossella Sgarzani^b, Riccardo Cipriani^c,
Stefano Cantore^a, Federico Contedini^c, Valentina Pinto^c,
Chiara Gelati^c, Ottavio Piccin^{a,*}

^a Department of Otolaryngology Head and Neck Surgery, S.Orsola-Malpighi University Hospital, Alma Mater Studiorum University of Bologna, via Massarenti 9, 40138 Bologna, Italy

^b Department of Emergency, Burn Center, Bufalini Hospital, Azienda USL della Romagna, Cesena, Italy

^c Department of Plastic and Reconstructive Surgery, S.Orsola-Malpighi University Hospital, via Massarenti 9, 40138 Bologna, Italy

ARTICLE INFO

Article history:

Received 9 August 2019

Accepted 25 September 2019

Available online 4 November 2019

Keywords:

Anterolateral thigh flap

Pharyngeal reconstruction

Microsurgical reconstruction

Neck resurfacing

ABSTRACT

Background: Multicomponent defects of the head and neck involving the cervical skin pose a reconstructive challenge for microsurgeons and usually requires two flaps. However, many patients who undergo such surgical treatment had prior treatment with radiotherapy and the availability of recipient vessels for free flap reconstruction may be limited. The purpose of this study was to review our experience in the reconstruction of these extensive head and neck defects using a single ALT free flap.

Methods: A total of 21 patients with complex defects of the head and neck involving multiple anatomical subunits, including the overlying cervical skin, underwent reconstruction with a single ALT flap. The clinical, functional, and aesthetic outcomes of these patients were reviewed.

Results: The mean hospital stay was 24 days. There was one total flap loss due to pedicle thrombosis. The patient underwent a further ALT reconstruction with no postoperative complications. Cer-

☆ This work was accepted to be presented as free paper at the 10 Congress of World Society for Reconstructive Microsurgery (WSRM 2019), 12–15 June 2019-Bologna.

* Corresponding author.

E-mail address: ottavio.piccin2@unibo.it (O. Piccin).

vical fistulas occurred in three patients, and all fistulas were healed by simple wound packing. Three patients with tracheal defect had a functional tracheostoma with adequate stomal patency. A modified barium swallowing study was performed on each patient, and all of them achieved total oral intake. Among them, two patients tolerated only a pureed diet.

Conclusions: Complex neck reconstruction can be accomplished with a single ALT flap with good clinical and functional results, minimal morbidity and quick recovery.

© 2019 Published by Elsevier Ltd on behalf of British Association of Plastic, Reconstructive and Aesthetic Surgeons.
This is an open access article under the CC BY-NC-ND license.
(<http://creativecommons.org/licenses/by-nc-nd/4.0/>)

Introduction

Multicomponent defects of the head and neck involving the cervical skin pose a reconstructive challenge for microsurgeons because of the composite nature of the defect with the requirement to reconstruct multiple tissue types.¹ The extensiveness and complexity of these defects, in the past, have limited treatment options despite potential tumor resectability.

The main goal of surgical treatment is to maximize local control and overall survival while minimizing the morbidity.² As these tumors infiltrate vital speech and alimentary tract structures, and can also involve the neck soft tissues, either through direct invasion or secondary to fistulization, an adjunctive goal is to achieve good functional and aesthetic results. Restoration of a functional aerodigestive tract along with acceptable external neck coverage, traditionally requires two separate flaps and multiple reconstruction stages³ with the disadvantage of limited availability of recipient vessels, having to do two or more sets of microvascular anastomosis and longer operating time. Considering that patients requiring these types of procedures often have very advanced disease and poor survival outcomes despite aggressive treatment, an ideal reconstructive procedure should be performed in a single stage operation, which not only can reduce operative time but also prevent the likelihood of postoperative complications.

Although a variety of free flaps are available for head and neck reconstruction, the anterolateral thigh (ALT) flap has recently gained increasing popularity.⁴ The purpose of this study was to review our experience in the reconstruction of extensive head and neck defects using a single ALT free flap and to describe the clinical and functional outcomes.

Methods

This is a retrospective review of consecutive cases of head and neck malignancies involving the skin treated surgically. Only patients with composite through-and-through defects with cutaneous involvement who underwent reconstruction with a single ALT free flap were included. Cases with prior treatment with radiotherapy and/or chemo-radiotherapy were also included. A prospectively maintained database, electronic medical records including case records, operative details, and follow-up data were studied. The study period was from June 2007 to November 2017. Speech function was not evaluated. This study was approved by our Institutional Review Board.

Results

Patients and tumors characteristics

A total of 21 patients with a complex defect of the head and neck involving multiple anatomical subunits, including the overlying cervical skin, were enrolled. There were 15 male and six female

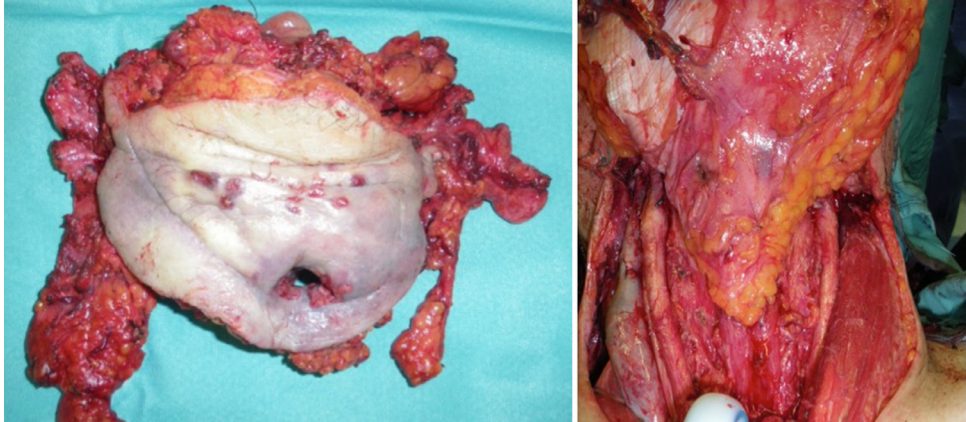


Figure 1. Intraoperative view of the resulting defects after circumferential pharyngectomy, tracheal and anterior neck skin resection for tracheostoma recurrence.

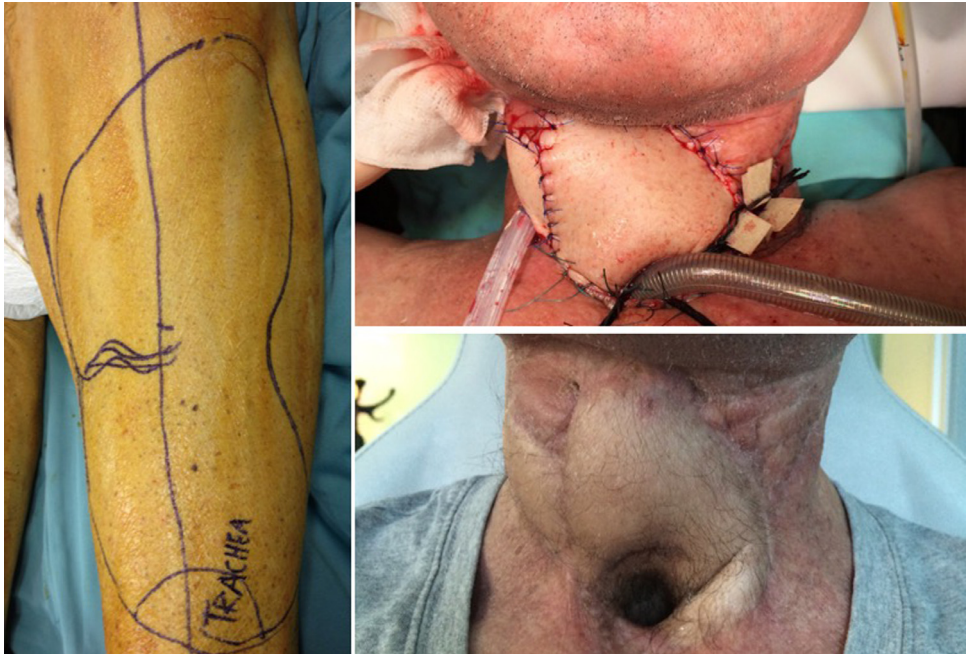

Figure 2. Anterolateral thigh flap design: after de-epithelialization the flap is oriented for neoconduit and tracheostoma reconstruction and for neck resurfacing.

patients, with a mean age of 59.1 years (range 38–73 years). Thirteen patients had primary or recurrent hypopharyngeal/laryngeal cancer, three patients had advanced thyroid cancer requiring resection of the esophagus and trachea below the sternal notch, four patients underwent resection of the pre-existing tracheostoma for recurrence (Figures 1 and 2) and one patient had advanced oral cavity cancer with mandible and chin skin invasion. Thirteen patients had prior history of radiotherapy and/or chemo-radiotherapy.

In 18 patients (85.7%) the histopathology of the tumor was squamous cell carcinoma. None presented with distant metastases at the time of surgery. Tumor size was T3 in 13 patients (62%) and T4 in eight cases. The baseline and follow-up data about the patients are shown in [Table 1](#).

Flap design and harvesting

Flap elevation was usually performed simultaneously with tumor resection using a two-team approach. Doppler was not used to identify the perforators. Perforators were identified with subfascial dissection. In 20 patients only one cutaneous perforator was present. In one case, no perforators were found and the contralateral leg necessitated harvest as a donor site. For a longer pedicle, we selected the distal perforator vessel. In every case, an appropriate preoperative plan and the drawing of an accurate template for reconstruction were done. The mean size of the flap was 23 × 12 cm.

Vascular anastomoses were performed after partial inset of the flap. The recipient arteries included the transverse cervical artery in 11 patients, superior thyroid artery in eight patients, and lingual/facial artery in two patients. The recipient veins included the transverse cervical vein in nine patients, internal jugular vein in two patients, common facial vein in eight patients, and external jugular vein in two patients. When possible we selected two recipient veins for anastomosis. Primary closure of the thigh donor site was achieved in 18 patients (80%); the other three patients required split-thickness skin grafting.

Complications

There were no perioperative deaths. The postoperative complications included a seroma at the thigh donor site in three patients (which resolved after aspiration, only one patient experienced a slight delayed healing of the donor site) and partial flap skin necrosis in the externalized skin island in two patients, which healed secondarily. Cervical fistulas occurred in three patients and all healed by simple wound packing in a mean of 5 weeks.

One microsurgical take-back was necessary due to venous occlusion. There was one total flap loss due to pedicle thrombosis related due to external compression by hematoma, on postoperative day 2. The unstable hemodynamic condition of the patient precluded the early exploration of the pedicle with subsequent failure of the flap. The patient underwent a further ALT reconstruction with no postoperative complications.

Postoperative care

After surgery, the patients were kept sedated on a ventilator overnight in a surgical intensive care unit. They were weaned off ventilator support the next day, when they were usually transferred to a regular ward. Tube feeding was started on postoperative day 1.

The mean hospital stay was 24 days (range 17–62 days). Two patients had a hospitalization time of more than 45 days due to a series of severe medical complications. The mean follow-up time was 53 months (range 9–96 months).

Swallowing

Gastrografin swallow was performed at 14 days postoperative, and peroral feeds were started if no fistulae were revealed. After an adequate swallowing rehabilitation program, functional results were systematically evaluated by modified barium swallowing (MBS) at 4–6 weeks and 6 months postoperatively.

MBS performed 4 to 6 weeks postoperatively revealed a good digestive tract continuity in all patients. At 6 months follow-up, a regular diet was tolerated by 19 patients. The remaining two patients, owing to stricture, tolerated only a pureed diet without the need for supplemental tube feeding.

Table 1
Patient characteristics.

Patient	Sex	Age	Indication	T size	Histopathology	Defect	Complications	Swallowing	Final outcome
1	F	63	Thyroid	T4	PC	Cervical trachea, esophagus	Fistula, partial flap skin necrosis	Regular	Recurrence, death at 15 mo fu
2	M	52	Tracheostoma recurrence	T3	SCC	Cervical trachea		Regular	No recurrence at 96 mo fu
3	M	55	OC	T4	SCC	Anterior tongue, floor of the mouth, mandible, chin	Total flap loss	Regular	Recurrence, death at 31 mo fu
4	M	71	HC	T3	SCC	Laryngo-pharyngectomy		Regular	No recurrence at 35 mo fu
5	F	54	HC	T3	SCC	Partial pharyngectomy		Regular	No recurrence at 29 mo fu
6	F	38	Thyroid	T4	MEC	Cervical trachea, esophagus		Regular	Recurrence death at 9 mo fu
7	M	73	HC	T3	SCC	Partial pharyngectomy			No recurrence at 55 mo fu
8	M	61	Tracheostoma recurrence	T3	SCC	Cervical trachea	Donor site seroma	Regular	No recurrence at 83 mo fu
9	F	57	HC	T3	SCC	Partial laryngo-pharyngectomy	Fistula, stricture	Soft diet	No recurrence at 35 mo fu
10	M	54	HC	T4	SCC	Laryngo-pharyngectomy		Regular	Tonsillar cancer, surgery 19 mo fu
11	F	51	Thyroid	T4	PC	Cervical trachea, esophagus	Donor site seroma	Regular	Distant metastasis. death at 19 mo
12	M	62	HC	T3	SCC	Near circumferential pharyngectomy	Stricture	Soft diet	Death at 28 mo fu
13	M	61	Tracheostoma recurrence	T3	SCC	Cervical trachea		Regular	No recurrence at 57 mo fu
14	M	58	HC	T4	SCC	Near circumferential pharyngectomy	Anastomosis revision	Regular	Death at 13 mo fu
15	M	53	HC	T3	SCC	Partial pharyngectomy		Regular	No recurrence at 36 mo fu
16	M	57	HC	T3	SCC	Partial pharyngectomy		Regular	Death at 15 mo fu
17	F	69	HC	T3	SCC	Circumferential pharyngectomy	Fistula	Regular	No recurrence at 38 mo fu
18	M	68	Tracheostoma recurrence	T3	SCC	Laryngo-pharyngectomy		Regular	No recurrence at 38 mo fu
19	M	59	HC	T3	SCC	Partial laryngo-pharyngectomy	Donor site seroma	Regular	Recurrence at
20	M	63	HC	T4	SCC	Circumferential pharyngectomy		Regular	Death at 12 mo fu
21	M	62	HC	T4	SCC	Laryngo-pharyngectomy	Partial flap skin necrosis	Regular	Recurrence at 5 mo fu

OC: oropharyngeal carcinoma. HC: hypopharyngeal carcinoma. PC: papillary carcinoma. SCC: squamous cell carcinoma. MEC: mucoepidermoid carcinoma. Mo fu: months follow-up.

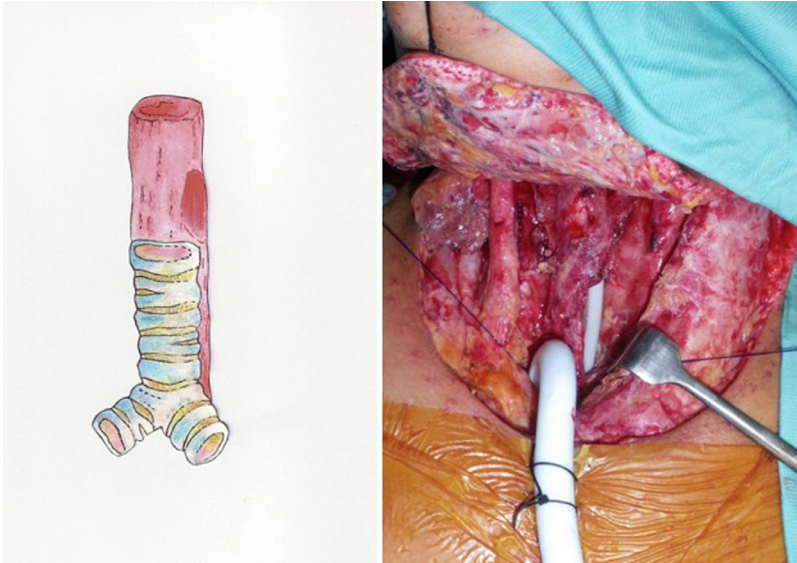


Figure 3. Intraoperative view of the final defect after exenteration of an advanced-stage thyroid cancer resulting in a large tracheal defect as well as cervical esophageal wall defect (white arrow: tube feeding through the esophageal defect).

Discussion

The simultaneous reconstruction of complex head and neck defects, particularly those involving pharyngo-laryngeal tract and large soft tissue loss, are certainly among the greatest challenges for reconstructive surgeons.⁵

Classical reconstruction approaches to pharyngo-laryngeal defects include the jejunal free flap^{6,7} radial forearm flap^{8,9} and the single paddle ALT flap.^{10–12} These reconstructive options provide a satisfactory reconstruction of partial and circumferential defects, but they fail to address more extensive defects that involve the anterior neck soft tissues.

Pedicle flaps such as the pectoralis major myocutaneous flap (PMMF) have historically been used to reconstruct almost every head and neck defect, including partial pharyngeal defects extended to the skin, but provide an unaesthetic reconstruction. In addition, the PMMF has the disadvantage of placing a bulky muscle superiorly to the tracheostomy which frequently may result in partial tracheal occlusion.¹³

In recent years, the simultaneous use of two free flaps was considered the first choice in the repair of these extensive defects.^{14,15} However, many patients who undergo such surgical treatment had prior treatment with surgery and/or radiotherapy and the availability of recipient vessels for free flap anastomosis may be limited. Furthermore, because this subgroup of head and neck cancer patients had advanced disease with limited survivorship, functional and aesthetic outcomes, as well as long-term quality of life issues, weigh just as importantly as oncologic outcome. Hence, the gold standard of reconstruction should be a one-stage procedure with the lowest morbidity, a short hospital stay, early recovery of swallowing and the restoration of a socially acceptable appearance.

In our experience the ALT flap has become an important option for the simultaneous reconstruction of multiple anatomical sites in head and neck.¹⁶ The possibility to harvest the flap with very large dimensions to include skin only or both skin and muscle or, potentially, as a chimeric flap with separately perfused skin paddles for multiple anatomical locations with a minimal donor site morbidity, makes the ALT flap ideal for combined defects of the head and neck like those in this series. Through adequate preoperative planning and the drawing of an accurate template for the reconstruction, we could repair complex defects with a single ALT flap composed by different skin paddles separated by a de-epithelialized area. This allowed us to obtain a rigorous three-dimensional reconstruction.

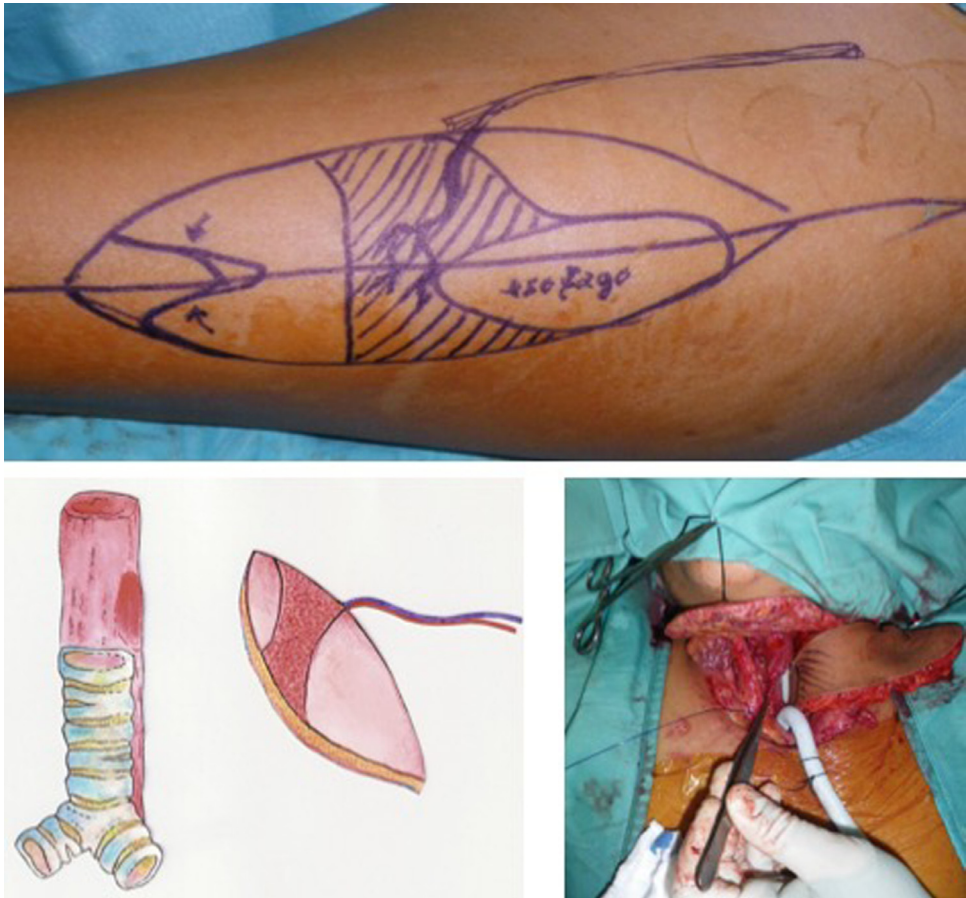


Figure 4. Design of the flap with lines of de-epithelialization marked on the thigh skin. A portion of the flap is oriented to reconstruct the esophageal wall.

Complex defects simultaneously involving the pharynx, cervical esophagus as well as the cervical trachea or tracheostoma and anterior neck skin, can be safely and reliably accomplished with a single ALT flap¹⁷ (Figure 3).

In these cases, the reconstruction had to deal not only with restoration of the alimentary tract but also with the lack of a lower trachea. The primary goal of treating this group of patients is to provide a stable airway with a patent tracheostoma (Figures 4–7), and ALT flap provides well-vascularized soft tissues that can cover the defect after resection and allows suturing of the tracheal remnant to skin edges without tension.

Several authors have reported the use of the musculocutaneous ALT flap in head and neck reconstruction.^{18,19} Combining a smaller fasciocutaneous component with a vastus lateralis muscle flap may ensure primary wound closure of the donor site in all cases, avoiding skin graft of the thigh. Musculocutaneous ALT flap is an excellent option, particularly for its bulkiness when you have to fill large dead space or in total or near total glossectomy that requires muscle bulk. However, in pharyngo-laryngeal reconstruction excessive bulk of the flap should be avoided since it may occlude the tracheostoma. Moreover, to provide anterior neck reconstruction and to create a neo-conduit, the ALT flap should be pliable enough to be folded or tubed without the risk of pedicle compression. Interestingly, seven flaps of our series were considered too bulky and were thinned before inseting.

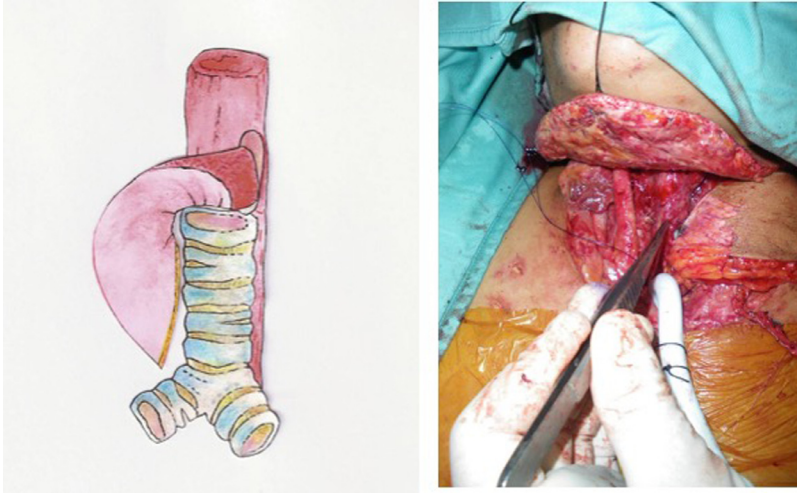


Figure 5. Reconstruction of the esophageal wall completed.

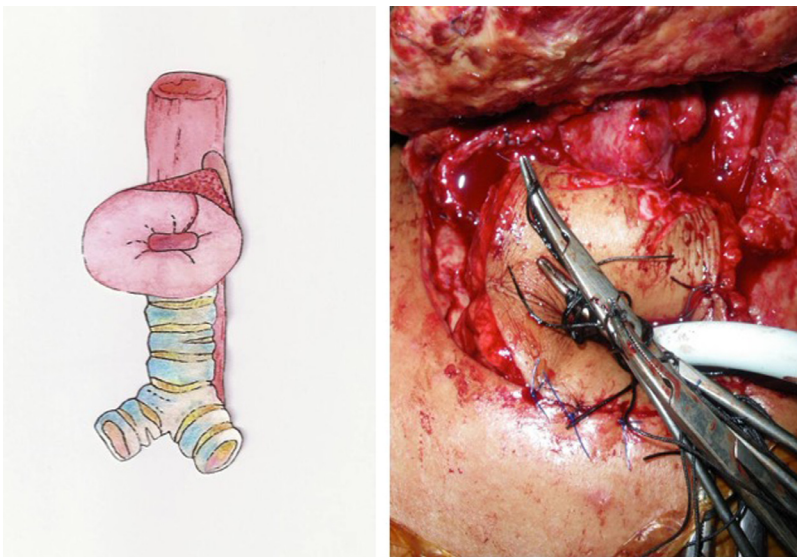


Figure 6. After de-epithelialization, the external portion of the flap was tubed and shaped like a funnel to reconstruct the tracheal and skin defect.

Furthermore, the remote location of the thigh from the head and neck region makes a two-team approach possible in all situations and helps in shortening operative time by permitting simultaneous flap elevation while the ablative step of the procedure is performed. Due to its long pedicle, the ALT may also be applied in challenging vascular situations.

The ALT flap has few disadvantages: the learning curve is undoubtedly longer than other commonly used flaps, mainly because the intramuscular perforator dissection is more challenging.²⁰ While this does not limit the application of this donor site, the anatomical variations may require superior microsurgical skills. Moreover, despite the possibility of flap thinning, the ALT may be very thick in some patients, making it difficult to tube the skin paddle.

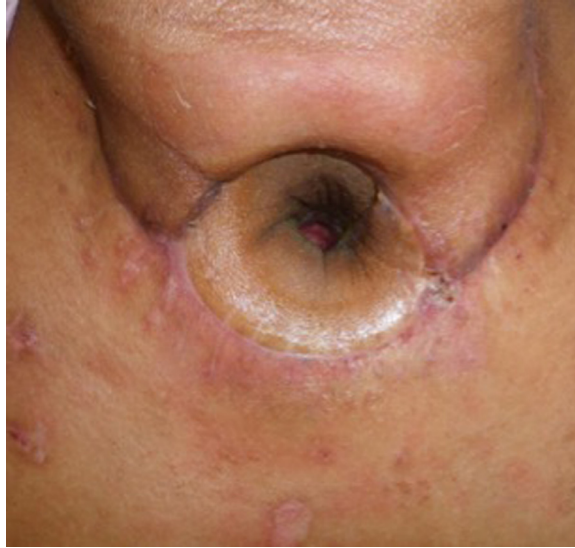

Figure 7. Wide-open tracheostoma 8 months after surgery.

Our experience with ALT flap reconstruction for such complex defects also suggests the flap accomplishment in restoring swallowing function. Only two patients had stricture formation that responded to endoscopic dilatation.

Because reconstructive surgery must strike a balance between oncologic cure, minimizing patient morbidity and optimizing quality of life, to achieve an optimal result in terms of functional and aesthetic outcome with the simplest possible technique, appropriate preplanning is imperative. It helps in reducing operative time, patient's impairment and the necessity of multiple interventions or multiple donor sites.

In summary, our experience suggests that complex head and neck defects extended to the cervical skin can be safely reconstructed with a single ALT flap as a one-stage procedure with good functional and aesthetic outcomes and reasonable survival.

Declaration of Competing Interest

None declared.

Funding

None.

Ethical approval

This study was approved by the Institutional Review Board of S. Orsola-Malpighi University hospital.

Supplementary materials

Supplementary material associated with this article can be found, in the online version, at doi:[10.1016/j.jpra.2019.09.003](https://doi.org/10.1016/j.jpra.2019.09.003).

References

1. Piazza C, Taglietti V, Nicolai P. Reconstructive options after total laryngectomy with subtotal or circumferential hypopharyngectomy and cervical esophagectomy. *Curr Opin Otolaryngol Head Neck Surg.* 2012;20:77–88.
2. Clark JR, Gilbert R, Irish J, Brown D, Neligan P, Gullane PJ. Morbidity after flap reconstruction of hypopharyngeal defects. *Laryngoscope.* 2006;116:173–181.
3. Balasubramanian D, Thankappan K, Kuriakose MA, et al. Reconstructive indications of simultaneous double free flaps in the head and neck: a case series and literature review. *Microsurgery.* 2012;32:423–430.
4. Wong CH, Wei FC. Anterolateral thigh flap. *Head Neck.* 2010;32:529–540.
5. Sharaf B, Xue A, Solari MG, et al. Optimizing outcomes in pharyngoesophageal reconstruction and neck resurfacing: 10-year experience of 294 cases. *Plast Reconstr Surg.* 2017;139:105–119.
6. Disa JJ, Pusic AL, Hidalgo DA, Cordeiro PG. Microvascular reconstruction of the hypopharynx: defect classification, treatment algorithm, and functional outcome based on 165 consecutive cases. *Plast Reconstr Surg.* 2003;111:652–660.
7. Reece GP, Bengtson BP, Schusterman MA. Reconstruction of the pharynx and cervical esophagus using free jejunal transfer. *Clin Plast Surg.* 1994;21:125–136.
8. Anthony JP, Singer MI, Mathes SJ. Pharyngoesophageal reconstruction using the tubed free radial forearm flap. *Clin Plast Surg.* 1994;21:137–147.
9. Scharpt J, Esclamado RM. Reconstruction with radial forearm flaps after ablative surgery for hypopharyngeal cancer. *Head Neck.* 2003;25:261–266.
10. Yu P, Hanasono MM, Skoracki RJ, et al. Pharyngoesophageal reconstruction with the anterolateral thigh flap after total laryngopharyngectomy. *Cancer.* 2010;116:1718–1724.
11. Selber JC, Xue A, Liu J, et al. Pharyngoesophageal reconstruction outcomes following 349 cases. *J Reconstr Microsurg.* 2014;30:641–654.
12. Chan YW, Ng RW, Liu LH, Chung HP, Wei WI. Reconstruction of circumferential pharyngeal defects after tumour resection: reference or preference. *J Plast Reconstr Aesthet Surg.* 2011;64:1022–1028.
13. Vartanian JG, Carvalho AL, Carvalho SMT, et al. Pectoralis major and other myofascial/myocutaneous flaps in head and neck cancer reconstruction: experience with 437 cases at a single institution. *Head Neck.* 2004;26:1018–1023.
14. Andrades P, Bohannon IA, Baranano CF, Wax MK, Rosenthal E. Indications and outcomes of double free flaps in head and neck reconstruction. *Microsurgery.* 2009;29:171–177.
15. Wei FC, Yazar S, Lin CH, Cheng MH, Tsao CK, Chiang YC. Double free flaps in head and neck reconstruction. *Clin Plast Surg.* 2005;32:303–308.
16. Caliceti U, Piccin O, Sgarzani R, et al. Surgical strategies based on standard templates for microsurgical reconstruction of oral cavity and oropharynx soft tissue: a 20 years' experience. *Microsurgery.* 2013;33:90–104.
17. Caliceti U, Piccin O, Cavicchi O, Contedini F, Cipriani R. Anterolateral thigh free flap for tracheal reconstruction after parastomal recurrence. *Head Neck.* 2009;31:1107–1111.
18. Demirkan F, Chen HC, Wei FC, et al. The versatile anterolateral thigh flap: a musculocutaneous flap in disguise in head and neck reconstruction. *Br J Plast Surg.* 2000;53:30–36.
19. Posch NAS, Mureau MAM, Flood SJ, Hofer SOP. The combined free partial vastus lateralis with anterolateral thigh perforator flap reconstruction of extensive composite defects. *Br J Plast Surg.* 2005;58:1095–1103.
20. Wei FC, Jain V, Celik N, et al. Have we found an ideal soft-tissue flap? An experience with 672 antero lateral thigh flaps. *Plast Reconstr Surg.* 2002;109:2219–2226.