

A case report of pulmonary vein isolation performed in a patient with polysplenia and interrupted inferior vena cava

Kaspars Kupics ^{1,2}, Kristine Jubele ^{1,3}, Georgijs Nesterovics ^{1,2*}, and Andrejs Erglis ^{1,2}

¹Latvian Centre of Cardiology, Pauls Stradins Clinical University Hospital, Pilsonu iela 13, Riga LV-1002, Latvia; ²Faculty of Medicine, University of Latvia, Jelgavas iela 3, Riga LV-1004, Latvia; and ³Faculty of Medicine, Riga Stradins University, Dzirciema iela 16, Riga LV-1007, Latvia

Received 26 April 2021; first decision 18 May 2021; accepted 15 November 2021; online publish-ahead-of-print 30 November 2021

Background

Pulmonary vein isolation (PVI) has entrenched itself as one of the main approaches for the treatment of paroxysmal symptomatic atrial fibrillation (AF). Pulmonary vein isolation prevents focal triggers from pulmonary veins from initiating AF paroxysms. As standard—PVI is performed through the inferior vena cava (IVC) approach, through the femoral vein. However, there are conditions when this approach is not appropriate or is not available.

Case summary

We report a case of a 53-year-old male who was referred to Pauls Stradins Clinical University Hospital for PVI due to worsening AF. Due to the rare anatomical variant of the venous system, the standard approach to PVI could not be applied. Interrupted cava inferior did not allow for femoral vein and IVC access. We had to figure out a different path—a combination of internal jugular and subclavian veins was used. Transseptal puncture was performed under transoesophageal echocardiography (TOE) control with a puncture needle stiletto. Pulmonary veins were isolated successfully, no complications were observed, and the patient was discharged in sinus rhythm.

Discussion

In some patients, PVI cannot be done through the standard IVC approach. In such cases, a different venous access must be chosen. Our patient had a rare variant of interrupted IVC and we had to use superior vena cava approach for the procedure. The difficulty of this approach is that procedure instruments are not designed for non-standard venous access; however, a combined use of TOE, general anaesthesia, and contact force-guided ablation has succeeded in isolating patients' pulmonary veins.

Keywords

Pulmonary vein isolation • Superior vena cava approach to PVI • Atrial fibrillation • Needle stiletto • Case report

ESC Curriculum 5.3 Atrial fibrillation • 5.1 Palpitations

Learning points

- When access to the heart via inferior vena cava vein is not available for pulmonary vein isolation, superior vena cava (SVC) approach via right internal jugular and right subclavian vein can be used.
- Atrial septal puncture is hard when SVC approach is chosen, as specially curved instruments are lacking, however, needle stiletto can be used for transseptal puncture.

* Corresponding author. Tel: +371 22347098, Email: georgijsnesterovics@gmail.com

Handling Editor: Christopher Wong

Peer-reviewers: Fabian Barbieri and Francisco Moscoso Costa

Compliance Editor: Rahul Mukherjee

Supplementary Material Editor: Fabienne Vervaat

© The Author(s) 2021. Published by Oxford University Press on behalf of the European Society of Cardiology.

This is an Open Access article distributed under the terms of the Creative Commons Attribution-NonCommercial License (<https://creativecommons.org/licenses/by-nc/4.0/>), which permits non-commercial re-use, distribution, and reproduction in any medium, provided the original work is properly cited. For commercial re-use, please contact journals.permissions@oup.com

Introduction

Pulmonary vein isolation (PVI) is recommended as one of the main approaches for rhythm control in patients with paroxysmal atrial fibrillation (AF).¹ Complete PVI can be achieved by various ablation techniques, but all techniques share a similar feature—an endocardium is accessed through the inferior vena cava (IVC) approach.² However, IVC approach is not always possible. When a patient with an anatomical variant of partly absent IVC was admitted to Pauls Stradins Clinical University Hospital for PVI due to worsening of paroxysmal AF we had to use a different venous access for the procedure.

Timeline

Data	Events
2016	First atrial fibrillation (AF) paroxysm
2021	Worsening of AF, three hospital admissions during the last 4 months
Admission Day 1 (March 2021)	Hospital admission and standard examination
Admission Day 2	Pulmonary vein isolation procedure day
Admission Day 3	Discharge from the hospital
3 months after ablation	No AF symptoms and arrhythmia free during electrocardiogram Holter monitoring

Case presentation

A 53-year-old male with a history of hypertension, obesity, and dyslipidaemia was referred for PVI due to worsening of AF. The patient had a 5-year history of paroxysmal AF. During the previous 4 months, he had been admitted to the hospital three times due to AF paroxysms and was referred for PVI. Previously, he had failed treatment with propafenone and ethacizine, and paroxysms were frequent, causing mental and physical distress. At admission, he used betaxolol and ethacizine as antiarrhythmic drug treatment.

The patient had a rare anatomical variant of IVC. Previous examinations revealed that IVC terminates below the hepatic zone and venous blood flow is compensated through azygos vein draining into the superior vena cava (SVC) (Figure 1). Multiple accessory spleens were also observed. There were four typical pulmonary vein entrances into the left atrium. A thick atrial septum was observed. Transthoracic echocardiography showed a mild left atrial enlargement (Left Atrial Volume Index 43 mL/m²) with normal left ventricular size and function. Laboratory test results showed no significant changes.

Considering the patient's vascular anatomy, we decided to use the right subclavian and right internal jugular veins as access points. The procedure was performed under general anaesthesia and transoesophageal echocardiography (TOE) guidance. A steerable catheter (Dynamic XT, Boston Scientific, MA, USA) was placed into the coronary sinus from a 7-French sheath via the right subclavian vein. Then

a transseptal needle (BRK transseptal needle, St. Jude Medical, Inc., MN, USA) was placed in the right atrium from an 8.5-French steerable sheath via the right internal jugular vein access. A transseptal puncture was attempted under fluorographic and TOE control. The initial attempt failed due to the thick atrial septum and technical challenges to deliver the needle at the desired spot. Finally, a needle stiletto was used for the transseptal puncture, which was successful at first attempt (Figure 2).

After the transseptal puncture, a 10 000-unit unfractionated heparin solution was injected and an activated clotting time of >300 s was achieved. We performed an anatomical 3D and myocardial potential mapping using a multipolar mapping catheter (PENTARAY™ NAV, Biosense Webster, CA, USA) (Figures 3 and 4). No left atrial scarring was observed. Open-irrigated contact force-sensing catheter (THERMOCOOL SMARTTOUCH® SF, Biosense Webster, CA, USA) was used for point-by-point PVI. After PVI sinus rhythm was restored by an electric cardioversion. Bidirectional conduction block between pulmonary veins and left atrium was confirmed. Total procedure time was 5 h 40 min, total fluorography time was 1 h 39 min, with total radiation dose of 4915 mGy/m².

No complications were observed. The patient was discharged the following day. Upon a 3-month follow-up, the patient was asymptomatic and arrhythmia free as confirmed by electrocardiogram Holter monitoring.

Discussion

We have reported a case of PVI performed in a patient with a rare congenital anomaly of polysplenia, which is frequently associated with other cardiovascular anomalies. Our patient had an interrupted IVC and a compensated venous blood return through vena azygos. The standard approach to PVI through femoral vein access was not applicable; therefore, SVC approach was most appropriate. Due to low incidence of the condition, specially designed instruments are not available and a transseptal puncture is frequently complicated when SVC access is used.

Multiple authors report different solutions for such procedures. SVC can be used for heart access. Usman *et al.*³ performed PVI via right subclavian and left axillary veins in a patient with IVC filter, while Kato *et al.* performed PVI in a patient with partly absent IVC through right internal jugular and right subclavian vein access.⁴ The main difficulty with SVC access is the puncture needle positioning, since all available needles are designed for IVC access. Both authors reported about manually curving the needle to achieve better positioning. Although we had no problem delivering the transseptal puncture sheath to the desired position, the sheath was continuously dislodged when the puncture needle was inserted, due to its rigidity. We resolved the problem by using a needle stiletto inside the dilatator, since the stiletto is softer and more easily manipulated than the needle. Another complicating factor was a thick atrial septum. While we have succeeded in applying mechanical pressure on the fossa ovalis, radiofrequency (RF) energy powered needles can be used for an easier puncture.⁵ Another option is percutaneous transhepatic venous access. Although the transseptal puncture can be performed with a standard needle, this approach is more difficult due to greater vascular access site complication risk, such as bleeding. Considering

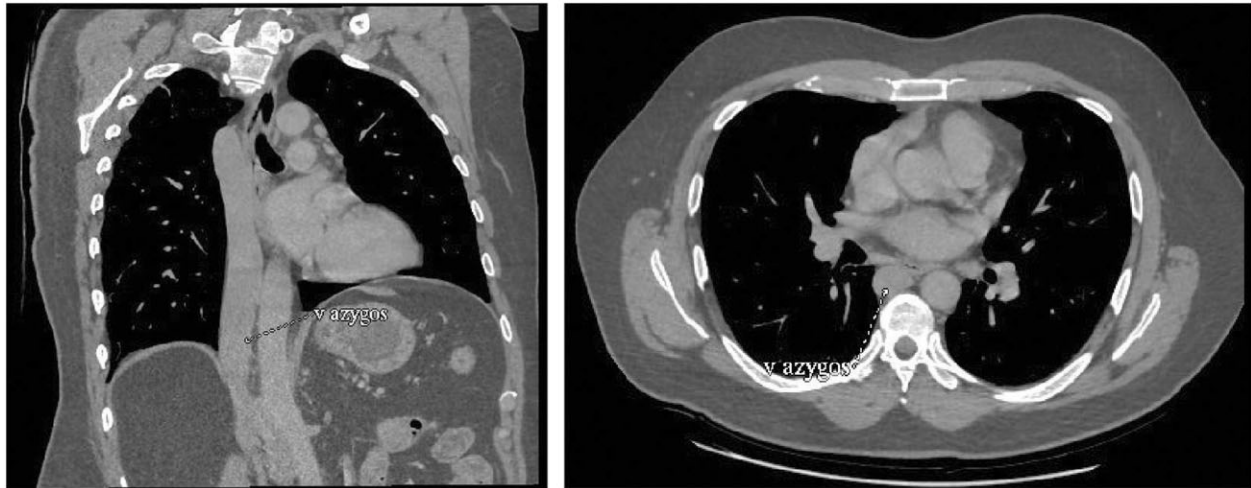


Figure 1 Coronal and axial view of previous computed tomography angiography scan revealing that inferior vena cava is interrupted at hepatic level.

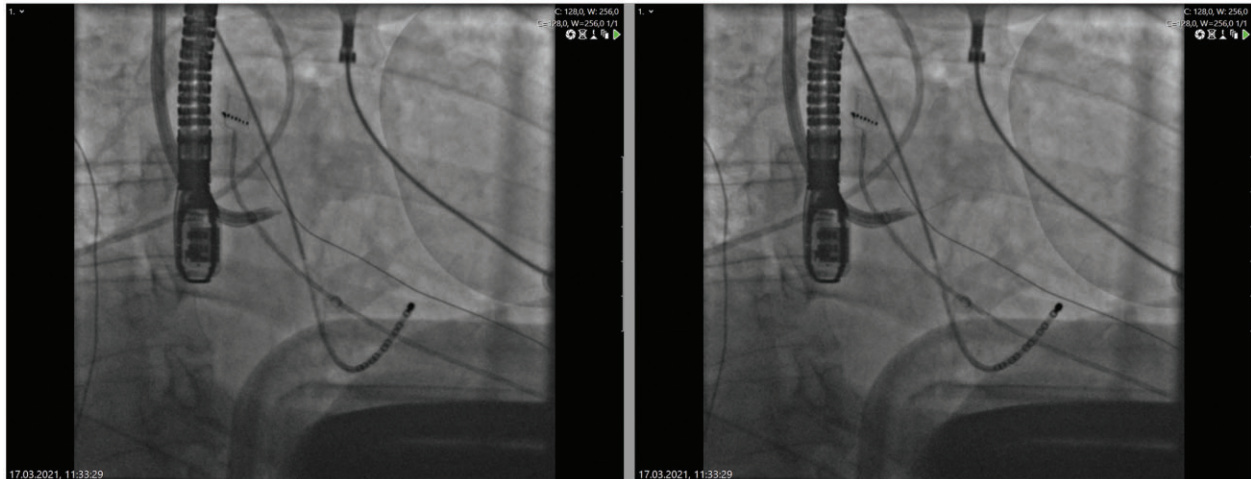


Figure 2 A puncture needle stiletto is used for transseptal puncture. Slides reveal puncture system position before (right) and after (left) the puncture was performed.

transhepatic puncture a non-routine procedure for electrophysiologists, an additional specialist must be involved. Singh *et al.*⁶ have successfully performed transseptal puncture with an RF needle through the percutaneous transhepatic venous access site with no procedure-related complications. Meanwhile, retrograde access to the left atrium excludes any need for transseptal puncture. Roeck *et al.*⁷ used a retrograde left atrium access via the right femoral artery in combination with magnetic navigation system for PVI in a patient with an atrial septal defect (ASD) occluder. Magnetic navigation system allows us to perform ablations that would not otherwise be possible to perform manually. The main disadvantage of this method is unavailability of magnetic navigation system in most centres, therefore other methods have to be chosen.

In non-standard cases, such as ours, fluorography and procedure times are increased, and there is room for procedure and workflow improvement. Remote magnetic navigation (RMN) ablation is known to be superior in reducing total fluorography time, as one meta-analysis has shown.⁸ A case report of a patient with interrupted IVC by Hernandez-Ojeda *et al.*⁹ showed successful PVI with the help of RMN. However, the anatomy of this patient allowed a partial IVC approach, since the advance from the right femoral vein to the right atrium through the azygos vein was possible. This procedure was associated with a lower dose of radiation 4476 mGy/m². Retrograde left atrium access via the right femoral artery can further reduce fluorography time. Buiatti *et al.*¹⁰ used this approach in a patient with ASD occluder. While

the total procedure time was 396 min, fluorography took only 6 min, which is considerably shorter than observed in procedures performed through SVC.

In summary, non-standard cases require non-standard solutions. Different approaches to PVI must be chosen, depending on each individual's anatomy, operator's experience, and available equipment.

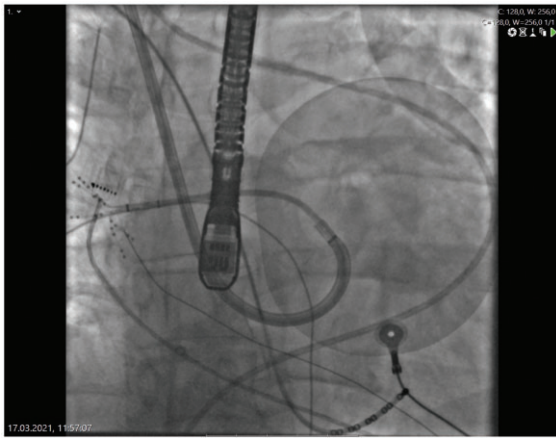



Figure 3 Fluorography of left atrial mapping with multipolar mapping catheter.

Lead author biography



Dr Kaspars Kupics is certified interventional arrhythmologist at Pauls Stradins Clinical University Hospital at Riga, Latvia. He has special interest in radiofrequency ablation and pulmonary vein isolation and performs these procedures on daily basis.

Supplementary material

[Supplementary material](#) is available at *European Heart Journal - Case Reports* online.

Slide sets: A fully edited slide set detailing this case and suitable for local presentation is available online as [Supplementary data](#).

Consent: The authors confirm that written consent for submission and publication of this case report including images and associated text has been obtained from the patient in line with COPE guidance.

Conflict of interest: None declared.

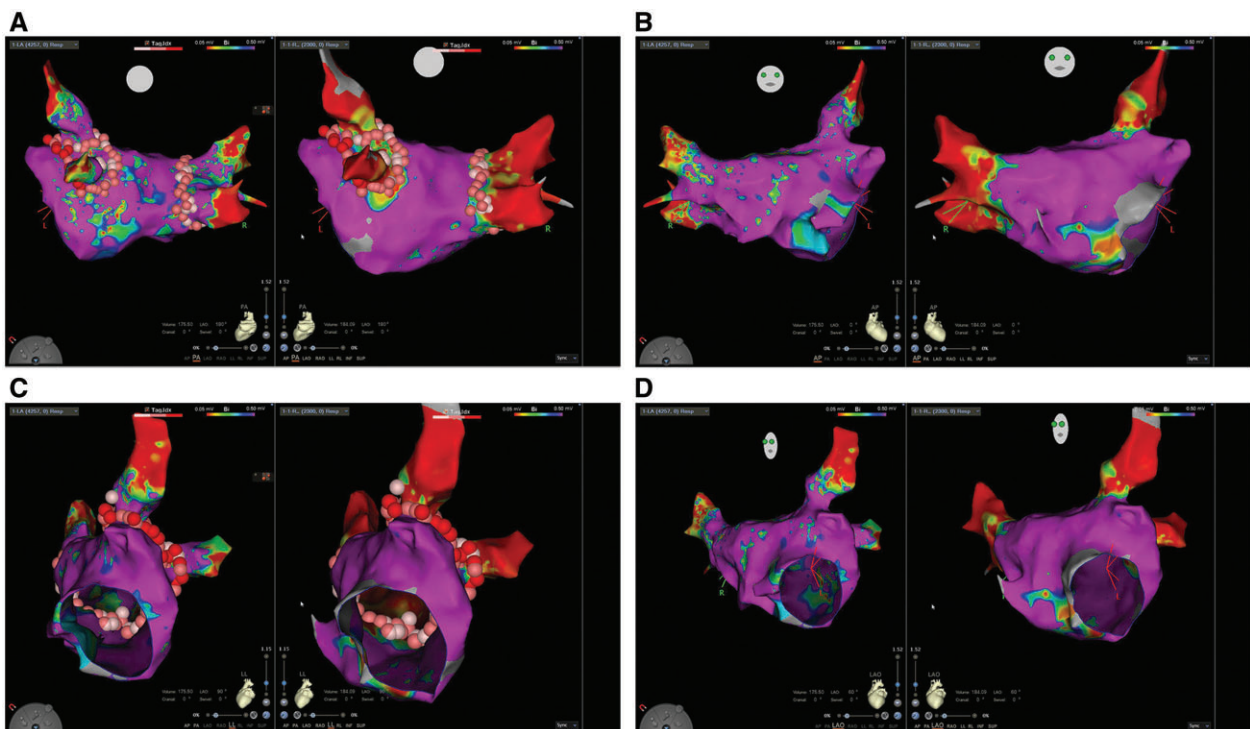


Figure 4 Myocardial potential three-dimensional mapping of left atrium in different projections—PA (A), AP (B), LL (C), and LAO (D). Images represent left atrium myocardial potential three-dimensional map before (left) and after (right) the point-by-point ablation in different projections.

Funding: None declared.

References

- Hindricks G, Potpara T, Dagres N, Arbelo E, Bax JJ, Blomstrom-Lundqvist C et al.; ESC Scientific Document Group. 2020 ESC Guidelines for the diagnosis and management of atrial fibrillation developed in collaboration with the European Association for Cardio-Thoracic Surgery (EACTS): the Task Force for the diagnosis and management of atrial fibrillation of the European Society of Cardiology (ESC) Developed with the special contribution of the European Heart Rhythm Association (EHRA) of the ESC. *Eur Heart J* 2021;**42**:373–498.
- Darrat Y, Morales G, Biase LDi, Natale A, Elayi CS. How to achieve durable pulmonary vein antral isolation? *J Atr Fibrillation* 2014;**6**:1039.
- Usman SR, Adela BG, Suraj K. Atrial fibrillation and atrial flutter ablation—an unconventional approach. *J Atr Fibrillation* 2019;**12**:2106.
- Kato H, Kubota S, Goto T, Inoue K, Oku N, Haba T et al. Transseptal puncture and catheter ablation via the superior vena cava approach for persistent atrial fibrillation in a patient with polysplenia syndrome and interruption of the inferior vena cava: contact force-guided pulmonary vein isolation. *Europace* 2017;**19**: 1227–1232. doi: 10.1093/europace/euw095.
- Tokuda M, Yamashita S, Matsuo S, Kato M, Sato H, Oseto H et al. Radiofrequency needle for transseptal puncture is associated with lower incidence of thromboembolism during catheter ablation of atrial fibrillation: propensity score-matched analysis. *Heart Vessels* 2018;**33**:1238–1244.
- Singh SM, Neuzil P, Skoka J, Kriz R, Popelova J, Love BA et al. Percutaneous transhepatic venous access for catheter ablation procedures in patients with interruption of the inferior vena cava. *Circ Arrhythm Electrophysiol* 2011;**4**: 235–241.
- Roeck LD, Riahi L, Wijchers S, Stockman D, Greef YD, Schwagten B. Retrograde access of the left atrium for pulmonary vein isolation using magnetic navigation after closure of an atrial septum defect. *Neth Heart J* 2015;**23**: 368–369.
- Jia K, Jin Q, Liu A, Wu L. Remote magnetic navigation versus manual control navigation for atrial fibrillation ablation: a systematic review and meta-analysis. *J Electrocardiol* 2019;**55**:78–86.
- Hernandez-Ojeda J, Hoyt W, Patel M, Mackall J, Arruda M. Transseptal access and pulmonary vein isolation via internal jugular veins for persistent atrial fibrillation treatment in a patient with left atrial isomerism, sinus node dysfunction, and interrupted inferior vena cava: the usefulness of robotic magnetic navigation. *HeartRhythm Case Rep* 2020;**6**:210–214.
- Buiatti A, Hessling G, Semmler V, Ammar S. Remote magnetic navigation for persistent atrial fibrillation ablation via a retrograde access: an approach for patients after atrial septal defect device closure. *Clin Res Cardiol* 2014;**103**: 1028–1030.