

# Lying-Down Nystagmus (LDN) – When a Lateralizing Sign of Secondary Importance Attains Ascendancy in the Diagnosis of Horizontal Semicircular Canal Benign Paroxysmal Positional Vertigo (HSC-BPPV)

Ajay K. Vats

Department of Medicine and Neurology, Chaudhary Hospital and Medical Research Centre Private Limited, Udaipur, Rajasthan, India

## Abstract

**Background:** The diagnosis of horizontal semicircular canal benign paroxysmal positional vertigo (HSC-BPPV) mainly depends on the elicitation of asymmetric horizontal positional nystagmus on rolling head to either side, during the diagnostic supine roll test (SRT). The asymmetry in the strength of the elicited horizontal positional nystagmus during SRT is explained by the Ewald's second law and is crucial for lateralizing the affected ear. Rarely the elicited horizontal positional nystagmus on the head roll to either side during the SRT is of symmetric strength. In such situations, the signs with secondary lateralizing value are useful in management by the repositioning maneuvers that require the affected side to be precisely known. **Aim:** The submitted article is a case report. **Results and Discussion:** A 38-year-old male with two days history of vertigo on rolling to either of the lateral recumbent position was seen in the second week of March 2019. His SRT elicited a lying-down nystagmus (LDN) to the right, while the head roll to either side elicited a geotropic horizontal positional nystagmus of symmetric strength. The symmetrical strength of elicited positional nystagmus on SRT to either side led to ascendancy of LDN from a lateralizing sign of secondary importance to one that reliably lateralized the involved horizontal semicircular canal. At two short term follow-ups at 1 hour and 24 hours after the therapeutic Gufoni maneuver, patient neither had vertigo nor any nystagmus elicited on the verifying supine roll test. **Conclusion:** In rare instances, LDN, which is a lateralizing sign of secondary importance becomes pivotal in the management of HSC-BPPV especially when the affected side needs to be precisely determined for the execution of the therapeutic repositioning maneuver.

**Keywords:** Ampullofugal, ampullopetal, HSC-BPPV, lying-down nystagmus, supine roll test

## INTRODUCTION

Benign paroxysmal positional vertigo (BPPV) is the most common mechanical disorder of the vestibular labyrinth. Since BPPV is a purely clinical vestibular disorder, its diagnosis solely depends on the elicitation of specific oculomotor patterns on the diagnostic positional tests, namely Dix-Hallpike test (DHT) for the vertical canals (posterior and anterior semicircular canals) and supine roll test (SRT) for the horizontal semicircular canal. In cases of the most frequent posterior semicircular canal variant of the BPPV (PSC-BPPV), the side to which DHT elicits the upbeat geotropic positional nystagmus during 20-degree head hanging position is the involved side. In the least frequent anterior semicircular canal variant of the BPPV (ASC-BPPV), though the DHT may elicit downbeating positional nystagmus in the 20-degree head hanging position to either side, it is the direction of torsion that lateralizes the involved side.<sup>[1]</sup>

The experiments of Julius Ewald (1855-1921) in pigeons framed the three laws that bear his name, and these laws are fundamental for understanding the pathophysiology of the SRT, which generates the diagnostic oculomotor patterns for the horizontal semicircular canals affected by vestibular lithiasis during the positional tests.<sup>[2]</sup> Ewald (1892) cannulated each of

the three semicircular canals and applied negative and positive pressures to observe the intensity and direction of the generated nystagmus. The two main outcomes of his experiments are:

1. The generated nystagmus is always directed parallel to the plane of the stimulated canal (Ewald's 1<sup>st</sup> law),
2. The generated nystagmus is stronger when the endolymph moves towards the ampulla (ampullopetal) in the case of the horizontal semicircular canal (Ewald's 2<sup>nd</sup> law), and away from the ampulla (ampullofugal) in case of

**Address for correspondence:** Dr. Ajay K. Vats,  
Consultant Neurophysician, Chaudhary Hospital & Medical Research  
Centre Private Limited, 472-473, Sector 4, Hiran Magri, Udaipur - 313 002,  
Rajasthan, India.  
E-mail: vatsneuro@gmail.com

**Submitted:** 18-Apr-2020 **Revised:** 03-May-2020 **Accepted:** 22-May-2020

**Published:** 31-Jul-2020

**Videos available on:** [www.annalsofian.org](http://www.annalsofian.org)

This is an open access journal, and articles are distributed under the terms of the Creative Commons Attribution-NonCommercial-ShareAlike 4.0 License, which allows others to remix, tweak, and build upon the work non-commercially, as long as appropriate credit is given and the new creations are licensed under the identical terms.

**For reprints contact:** [reprints@medknow.com](mailto:reprints@medknow.com)

**DOI:** 10.4103/aian.AIAN\_322\_20

vertical semicircular canals (posterior and anterior) (Ewald's 3<sup>rd</sup> law).

In the geotropic variant of the horizontal semicircular canal benign paroxysmal positional vertigo (*geo*-HSC-BPPV), in which otoconial debris is free-floating in the long posterior non-ampullary arm of the horizontal semicircular canal, an ipsilesional lateral head roll in the yaw-axis, during the SRT, produces an excitatory hydrodynamic drag of the endolymph towards the ampulla. This very reason in the variant, during SRT, elicits stronger geotropic nystagmus to the side of lesion than to the opposite side [Figure 1a and 1b]. In the apogeotropic variant of HSC-BPPV (*apo*-HSC-BPPV), where otoconial debris is either free-floating in the short anterior ampullary arm of the horizontal semicircular canal or is adherent to the cupula, thus making it heavier, the excitatory hydrodynamic drag of the endolymph towards the ampulla occurs when there is contralesional lateral head roll in the yaw axis during SRT. Accordingly, in the *apo*-HSC-BPPV during the SRT, stronger apogeotropic nystagmus is elicited when the head is yawed to the contralesional side [Figure 1a and 1c].

The canalith repositioning maneuvers for treating HSC-BPPV like Gufoni, Appiani, barbecue roll and forced prolonged positioning (FPP) are dependent on precise lateralization of the involved side. During these maneuvers, the head and body of the patient are sequentially oriented in a manner that the utricular exit in the posterior arm of the horizontal semicircular canal is positioned to the most gravity-dependent location. Therefore, it is extremely important to precisely lateralize the involved side for the accurate execution of the repositioning maneuver in cases of HSC-BPPV. Ewald's laws are the basis of the localization and the lateralization of the involved semicircular canal in cases of BPPV. However, cases of HSC-BPPV occasionally occur that violate Ewald's second law and elicit symmetrically strong horizontal positional nystagmus on lateral head rolls to either side during the SRT.<sup>[3]</sup>

A 38-year male patient is reported who presented with two days history of vertigo on lying supine and on assuming either of the lateral recumbent positions. The SRT elicited a lying-down nystagmus (LDN) beating towards the patient's right in the supine neutral position and symmetrically strong intensity geotropic horizontal positioning nystagmus on a lateral head roll to the right as well as left. In HSC-BPPV, the LDN mostly beats toward the involved ear in the apogeotropic variant and directs to the healthy ear in the geotropic type. Accordingly, the lateralization to left was inferred and the patient was successfully treated for left *geo*-HSC-BPPV.

## CASE DESCRIPTION

### History

A 38-year-old male patient presented in the second week of March 2019 with 2-day history of vertigo on assuming either of the lateral recumbent positions, getting to supine position from sitting and *vice-versa*. The severity of vertigo was reported to be more severe on the right lateral recumbent position He

also vomited twice during this period. There was no history of staggering, diplopia, dysarthria, difficulty in swallowing, hiccups, drooping of upper eyelids, or facial or limb weakness. There was no history of hypertension, diabetes, coronary artery disease, hypothyroidism, jaundice, craniocervical trauma, cervical radiculopathies, cervical canal stenosis, rheumatoid arthritis, Paget's disease, ankylosing spondylitis, low back dysfunction, spinal cord injuries, or cerebrovascular disease.

### Examination

The general physical examination and vitals of the patient were normal. The screening examination of the cervical spine did not reveal any limitation of movement. The examination of the back region did not reveal kyphoscoliosis. The examination of the lumbosacral spine, including straight-leg raising (SLR) test and reverse SLR-test, were normal. The neurological examination revealed normal cranial nerve examination; strength was grade 5/5 in all four limbs with normal deep tendon reflexes, and bilateral plantar reflexes were flexor. The examination of the cerebellar system revealed no spontaneous or gaze-evoked nystagmus, and there was no appendicular or axial incoordination. The Otoneurologic examination revealed normal vertical and horizontal saccadic and smooth pursuit eye movements. The head impulse test was bilaterally normal. Before carrying out positional tests, the presence of spontaneous nystagmus was ruled out by using takeaway Frenzel goggles.<sup>[4]</sup> The Dix-Hallpike test carried as per the published guidelines of the American Academy of Otolaryngology, Head, and Neck Surgery Foundation (AAO-HNS)<sup>[5]</sup> did not elicit positional nystagmus. The SRT was performed with patient in long-sitting on the examination table. Placing the patient from the sitting to the supine neutral position elicited a horizontal right beating nystagmus (LDN) lasting approximately ten seconds. The lateral head roll to the right elicited geotropic horizontal nystagmus of six seconds duration and to the left elicited geotropic horizontal nystagmus of four seconds in duration. Elicited geotropic horizontal positional nystagmus during SRT had an almost symmetric strength on the lateral head roll to either side [Video 1]. Because the LDN is directed towards the healthy ear in the variant *geo*-HSC-BPPV [Figure 2], it was reasonable to lateralize the disease involvement to the left horizontal semicircular canal.

### Diagnosis

The aforesaid clinical history and otoneurologic examination were consistent with the diagnosis of geotropic variant of left horizontal semicircular canal benign paroxysmal positional vertigo (Left *geo*-HSC-BPPV). A video recording of the supine head roll test [Video 1], unveiled the symmetrically strong elicited geotropic horizontal positional nystagmus to either side and by capturing the right beating LDN, supported the lateralization of involvement to the left horizontal semicircular canal.

### Intervention

The Gufoni maneuver<sup>[6]</sup> for the left *geo*-HSC-BPPV was performed with patient in short-sitting and lower limbs hanging down the long edge of examination table. From short-sitting,

the patient was positioned briskly to the right lateral recumbent for approximately one minute. Thereupon the head of the patient was inclined 45-degrees downwards in the yaw axis and maintained for two minutes. After this, the patient was brought back to the short sitting position [Video 2].

### Prognosis

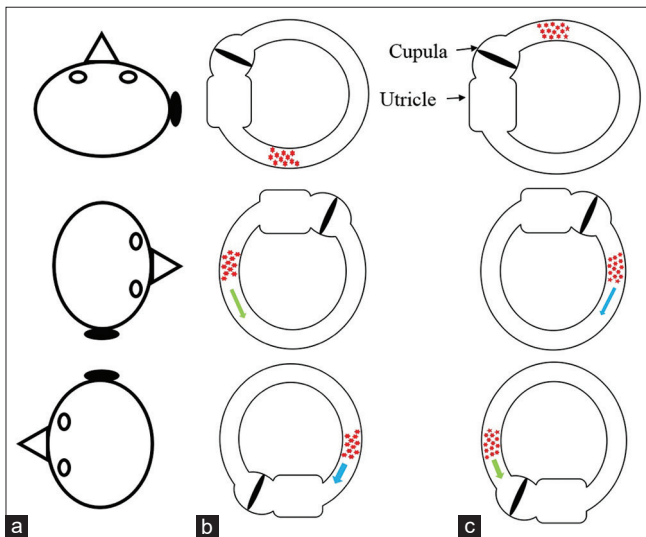
A repeat SRT one hour after Gufoni maneuver [Video 3], as well as 24-hours later [Video 4], did not elicit any positioning nystagmus and the patient did not had vertigo as well. The patient was telephonically enquired weekly for next four weeks about vertigo and he remained symptom-free during that time.

### DISCUSSION

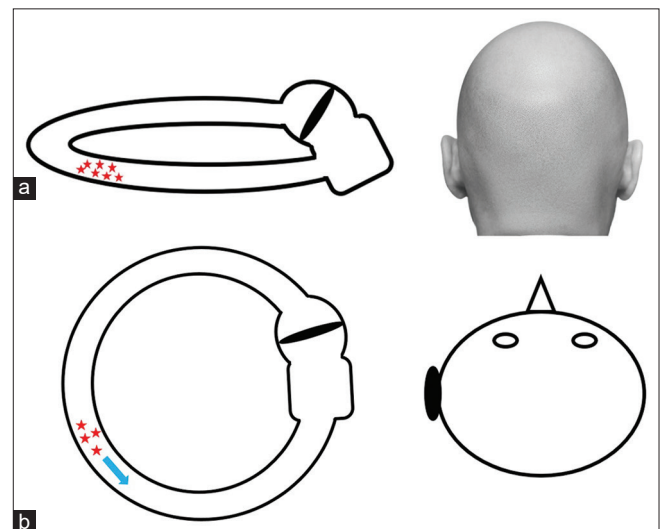
The SRT in patients suffering from HSC-BPPV identifies the affected ear by comparing the relative strengths of elicited horizontal positional nystagmus during the lateral head rolls to either side. As per the Ewald's 2<sup>nd</sup> law, an asymmetric horizontal positional nystagmus is mostly elicited, which is stronger on the ipsilesional lateral head roll in the *geo*-HSC-BPPV and contralesional lateral head roll in the *apo*-HSC-BPPV during SRT due to excitatory ampullopetal cupular deflection as explained [Figure 1]. Rarely the elicited horizontal positional nystagmus in HSC-BPPV is of symmetric strength to either side, making lateralization impossible based on the findings of lateral head rolls during SRT singularly. The initial location of the otoconial debris, the acceleration of rotation, and the angle subtended during the head roll are determinants of the intensity of the elicited horizontal positional nystagmus during the SRT.<sup>[7]</sup> LDN is an important secondary sign of

lateralization, and is particularly useful for the patients in whom SRT elicits horizontal positional nystagmus of almost equal strength on the rolling head to either side during the SRT.<sup>[8]</sup> In cases of long posterior arm horizontal semicircular canalolithiasis (*geo*-HSC-BPPV), lying down from sitting to supine causes otoconial debris to move away from the cupula consequent to the canal attaining a vertical position [Figure 2]. This results in an inhibitory ampullofugal deflection of the cupula, and the resultant nystagmus (clinically appreciated as LDN) is directed away from the affected side [Figure 2].<sup>[9]</sup> The direction of LDN is away from the affected side in most patients with *geo*-HSC-BPPV. By contrast, in almost all patients with *apo*-HSC-BPPV, the LDN is directed towards the affected side.

Pseudo-spontaneous nystagmus (PSN) is long-lasting non-paroxysmal nystagmus observed in the upright position and mostly unveiled by the slow horizontal rotations of the head, which causes the floatation of the otoconial debris in the horizontal semicircular canal which is inclined 30° relative to the horizontal plane. PSN too is a sign of secondary importance for lateralizing the affected ear in HSC-BPPV.<sup>[10]</sup> The frequency of PSN in HSC-BPPV is reported to vary from 40.1-76%, and increases to 96% after mild head-shaking.<sup>[11-13]</sup> In *geo*-HSC-BPPV, it beats to the healthy ear, whereas in the apogeotropic forms, it beats to the affected ear. However, the PSN must be differentiated from the spontaneous nystagmus by the head pitch test (HPT) in the sitting position under videonystagmoscopy control.<sup>[11]</sup> During HPT, on pitching the head forward 30°, the PSN disappears because the horizontal semicircular canal attains an almost horizontal orientation (neutral position) relative to the horizontal plane, which ceases the floatation of the otoconial debris. PSN



**Figure 1:** The position of otoconial debris in supine neutral position and during lateral head rolls. (a): Top to bottom - supine neutral position, lateral head roll right and to left. (b): Otoconia in posterior arm of right horizontal semicircular (geotropic variant) canal shifts ampullopetal (green arrow) on lateral head roll to right and ampullofugal (blue arrow) on lateral head roll to left. (c): Otoconia in anterior arm of right horizontal semicircular (apogeotropic variant) canal shifts ampullofugal (blue arrow) on lateral head roll to right and ampullopetal (green arrow) on lateral head roll to left



**Figure 2:** The mechanism of lying-down nystagmus (LDN) in left *geo*-HSC-BPPV. (a). In the sitting position, the otoconial debris (in red) is in the long posterior non-ampullary arm of the left horizontal semicircular canal. (b). As the patient is shifted to the supine position, the canal becomes vertical and the otoconial debris moves away from the cupula giving rise to ampullofugal deflection (blue arrow) of the cupula. The resulting LDN would be away from the affected side



reverses its direction when the head is pitched 60° forward and reappears again with increased intensity on pitching the head approximately 30° backward.

The incidence of LDN is reported to vary from 59.2-83%,<sup>[3,8,14]</sup> and is comparable to that of PSN. The lateralizing value of LDN is identical to that of PSN, directs to the healthy ear and does not require videonystagmoscopy for its detection. In this case, LDN captured during recording of eye movements during the SRT aided in lateralization given the fact that lateral head roll elicited horizontal nystagmus of equal strength to either side. The direction of the LDN, which is a secondary sign of lateralization, attained ascendancy, and guided to accurately treat the patient with the Gufoni maneuver. Two short term follow-ups at one hour and 24 hours after the therapeutic Gufoni maneuver were aimed to minimize the confounding effects of spontaneous remissions reported in HSC-BPPV.<sup>[15]</sup> The disappearance of vertigo and elicited nystagmi (geotropic horizontal positional nystagmus on the lateral head roll to either side as well as LDN) at short term follow-up reinforces the lateralizing value of LDN in patients who elicit symmetrically strong nystagmus on the head roll to either side during SRT.

## CONCLUSION

The terminology seated supine positioning nystagmus (SSPN) used by the Asprella<sup>[11]</sup> is identical to LDN described earlier<sup>[3,8]</sup> in terms of its pathogenesis and lateralizing value. The LDN is an important secondary sign of lateralization both in geotropic as well as apogeotropic variants of HSC-BPPV (especially in developing countries like India where the videonystagmoscopy equipment are not routinely available), where the diagnostic SRT elicits horizontal positional nystagmus of almost equal strength on rolling the head to either side. Every doctor or trained vestibular physical therapist who is directly involved in the care of patients with benign paroxysmal positional vertigo should explicitly look for this secondary albeit important lateralizing sign while performing the SRT. A close-up video recording of the SRT focusing on eye movements can be a useful aid for comparing the strength of the elicited horizontal positional nystagmus and can occasionally unveil an LDN.

## Declaration of patient consent

The authors certify that they have obtained all appropriate patient consent forms. In the form the patient(s) has/have given his/her/their consent for his/her/their images and other clinical information to be reported in the journal. The patients understand that their names and initials will not be published and due efforts will be made to conceal their identity, but anonymity cannot be guaranteed.

## Acknowledgements

Renith Kurian, video recorded the diagnostic and therapeutic maneuvers and precisely captured the nystagmus during the entire diagnostic and treatment period.

## Financial support and sponsorship

Nil.

## Conflicts of interest

There are no conflicts of interest.

## REFERENCES

1. Korres S, Riga M, Sandris V, Danielides V, Sismanis A. Canalithiasis of the anterior semicircular canal (ASC): Treatment options based on the possible underlying pathogenetic mechanisms. *Int J Audiol* 2010;49:606-12.
2. Ewald JR. *Physiologische Untersuchungen Ueber das Endorgan de Nervus Octavus*. Wiesbaden, Germany: Bergmann JF Publishers; 1892.
3. Koo JW, Moon IJ, Shim WS, Moon SY, Kim JS. Value of lying-down nystagmus in the lateralization of horizontal semicircular canal benign paroxysmal positional vertigo. *Otol Neurotol* 2006;27:367-71.
4. Strupp M, Fischer C, Hanß L, Bayer O. The takeaway Frenzel goggles: A Fresnel-based device. *Neurology* 2014;83:1241-5.
5. Bhattacharyya N, Gubbels SP, Schwartz SR, Edlow JA, El-Kashlan H, Fife T, *et al*. Clinical practice guideline: Benign paroxysmal positional vertigo (Update). *Otolaryngol Head Neck Surg* 2017;156 (3\_Suppl):S1-47.
6. Ciniglio Appiani G, Catania G, Gagliardi M. A liberatory maneuver for the treatment of horizontal canal paroxysmal positional vertigo. *Otol Neurotol* 2001;22:66-9.
7. Strupp M, Brandt T, Stedding S. Horizontal canal benign paroxysmal positioning vertigo: reversible ipsilateral caloric hypoexcitability caused by canalolithiasis. *Neurology* 1995;45:2072-6.
8. Han BI, Oh HJ, Kim JS. Nystagmus while recumbent in horizontal canal benign paroxysmal positional vertigo. *Neurology* 2006;66:706-10.
9. Casani AP, Vannucci G, Fattori B, Berrettini S. The treatment of horizontal canal positional vertigo: our experience in 66 cases. *Laryngoscope* 2002;112:172-8.
10. Asprella Libonati G. Diagnostic and treatment strategy of lateral semicircular canal canalolithiasis. *Acta Otorhinolaryngol Ital* 2005;25:277-83.
11. Asprella-Libonati G. Pseudo-spontaneous nystagmus: a new sign to diagnose the affected side in lateral semicircular canal benign paroxysmal positional vertigo. *Acta Otorhinolaryngol Ital* 2008;28:73-8.
12. Califano L, Melillo MG, Mazzone S, Vassallo A. "Secondary signs of lateralization" in apogeotropic lateral canalolithiasis. *Acta Otorhinolaryngol Ital* 2010;30:78-86.
13. De Stefano A, Kulamarva G, Citraro L, Neri G, Croce A. Spontaneous nystagmus in benign paroxysmal positional vertigo. *Am J Otolaryngol* 2011;32:185-9.
14. Wu F, Xing YZ, Bi W, Liu JX. [The value of lean nystagmus and sitting to supine positioning nystagmus in the diagnosis of horizontal semicircular canal benign paroxysmal positional vertigo]. *Lin Chung Er Bi Yan Hou Tou Jing Wai Ke Za Zhi* 2019;33:106-9.
15. Imai T, Ito M, Takeda N, Uno A, Matsunaga T, Sekine K, *et al*. Natural course of the remission of vertigo in patients with benign paroxysmal positional vertigo. *Neurology* 2005;64:920-1.