

Case Report

Occipitalized os odontoideum: A case report

Junich Ohya, Kota Miyoshi, Tomoaki Kitagawa, Shogo Nakagawa

Department of Orthopedic surgery, Yokohama Rosai Hospital, Yokohama, Japan

Corresponding author: Dr. Junichi Ohya, Department of Orthopaedic surgery, Faculty of Medicine, The University of Tokyo, Hongo 7-3-1, Bunkyo-ku, Tokyo, 113-0033, Japan.
E-mail: oyaj-ort@h.u-tokyo.ac.jp

Journal of Craniovertebral Junction and Spine 2014, 5:42

Abstract

We report on a 36-year-old man presenting with a sudden onset of motor weakness and numbness in the upper extremities following a fall from a truck bed. Radiological findings demonstrated an os odontoideum and osseous continuity between the occiput and an ossicle, termed an “occipitalized os odontoideum.” The occipitalized ossicle and atlas moved as a functional unit from the body of the axis. He underwent atlantoaxial stabilization with an atlas lateral mass screw and axis pedicle screw. Eighteen months later, he remained free of symptoms and showed solid bone fusion. Atlantoaxial stabilization resulted in an excellent clinical outcome for this condition. Our report provides useful knowledge regarding treatment of extremely rare osseous anomalies in the craniovertebral junction.

Key words: Atlantoaxial instability, os odontoideum, occipitalized atlas, spinal cord injury

INTRODUCTION

An os odontoideum is a rare condition in the craniovertebral junction (CVJ) which can cause mild progressive myelopathy or sudden spinal cord injury even after minor trauma.^[1] Here, we report our experience with a patient who had a spinal cord injury due to atlantoaxial instability secondary to os odontoideum associated with an osseous continuity between the occiput and an ossicle, which was termed an “occipitalized os odontoideum.” To our knowledge, this is the first report describing an occipitalized os odontoideum.

CASE REPORT

A 36-year-old man presented with sudden motor weakness and numbness in the upper extremities following a fall from a

truck bed. Neurological examination revealed motor weakness (grade 4/5) in his left triceps and intrinsic muscles. He had decreased sensation in both hands. He had intact cranial nerves and hyperreflexia in the left upper extremity with a positive Hoffmann sign. Knee and ankle reflexes were also abnormally increased bilaterally, with positive Babinski signs. A spastic gait and clumsiness of his hands were also noted. He denied any bowel or bladder difficulties.

Plain lateral radiographs showed an os odontoideum, and atlantoaxial instability was demonstrated during flexion-extension [Figure 1] Reconstruction computed tomography (CT) images demonstrated osseous continuity between the occiput and an ossicle, termed as “occipitalized os odontoideum.” The occipitalized ossicle and atlas moved as a functional unit from the body of the axis [Figure 2]. Magnetic resonance imaging (MRI) demonstrated intramedullary high signal intensity changes at the posterior arch of the atlas [Figure 3a]. High signal-intensity changes without spinal cord compression suggest the presence of focal spinal cord contusion due to instability between the cranial unit and the body of the axis.

The patient underwent uncomplicated atlantoaxial stabilization with an atlas lateral mass screw and axis pedicle screw. The bone graft harvested from the iliac crest was interposed between the posterior arc of atlas and the lamina of the axis. His post-operative

Access this article online	
Quick Response Code:	Website: www.jcvjs.com
	DOI: 10.4103/0974-8237.147087

course was uneventful. His symptoms, including motor weakness and sensory disturbance, improved shortly after surgery. At the 8-month follow-up examination, he had no symptoms, and dynamic lateral radiographs showed stabilization between the atlas and axis. MRI revealed that the intramedullary high-intensity lesion had disappeared [Figure 3b]. At month 18, he remained free of symptoms and showed solid bone fusion [Figure 4].

DISCUSSION

An os odontoideum is defined as the dissociation between the body of the axis and the dens, such that a disconnected ossicle takes the place of an intact odontoid process.^[2] Surgical treatments, such as posterior atlantoaxial fixation with an atlas lateral mass screw and axis pedicle screw, have been reported as the mainstay of treatment for the patients who have os odontoideum and show neurological symptoms. They have also been reported, on occasion, to be a preventive treatment for spinal cord injury in patients without neurological symptoms.^[1,3,4] Although the choice of surgical procedures for

patients with atlantoaxial instability depends on the pathology of the instability, the patients' individual anatomical features, and their comorbidity, pre-operative imaging in the craniovertebral junction may often show concomitant diseases or conditions, such as osseous anomalies,^[5,6] vertebral artery anomalies,^[7] and congenital disease.^[8] Knowledge of the treatments for these coexisting states can help the surgeon to prevent intra- or post-operative complications. We reported a case of an occipitalized os odontoideum, which was an extremely rare osseous anomaly in CVJ, causing spinal cord injury following an accidental fall. Atlantoaxial fixation was performed, which resulted in an excellent clinical outcome for this condition. We believe that our experience provide a basis for the selection of surgical procedure in this rare condition in CVJ.

The surgical stabilization of the os odontoideum with atlantoaxial fusion involving transarticular screw fixation or atlas lateral mass and axis pedicle fixation with polyaxial screws and rods have been described as mainstay surgical treatments. However, in this special condition, the main fear was that atlantoaxial fixation with atlas lateral mass screws and axis pedicle screws alone might be insufficient to fix the cranial unit consisting of the occipitalized ossicle and atlas with the axis. Pre-operative imaging revealed instability between the unit and the body of the axis, not atlantodental or occipitotlas instability. Hence, we chose to perform atlantoaxial stabilization and not occipitocervical fixation. Two previous reports regarding surgical

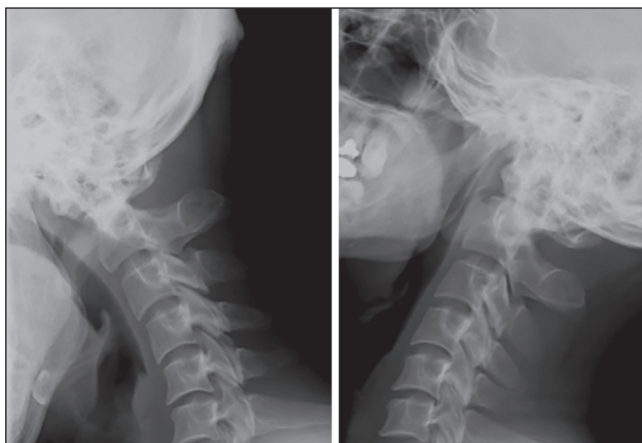


Figure 1: Lateral radiographs of cervical spine showing an os odontoideum and atlantoaxial instability during flexion-extension

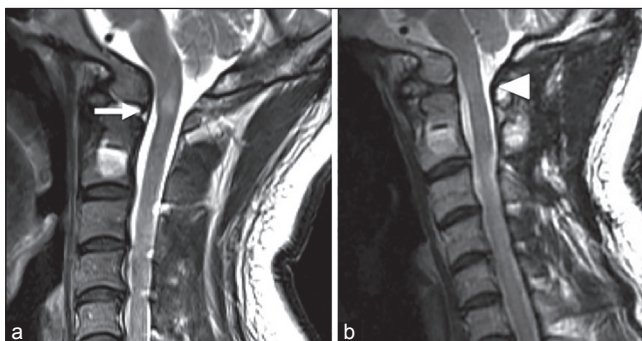


Figure 3: (a) Pre-operative sagittal T2-weighted magnetic resonance image demonstrating intramedullary high signal-intensity changes at the posterior arc of the atlas. High signal-intensity changes between the cranial unit and the body of the axis without spinal cord compression (arrow) suggest the presence of instability at the level (b) Post-operative sagittal T2-weighted magnetic resonance image showing that the intramedullary high signal-intensity changes at the posterior arc of the atlas had disappeared (arrowhead)

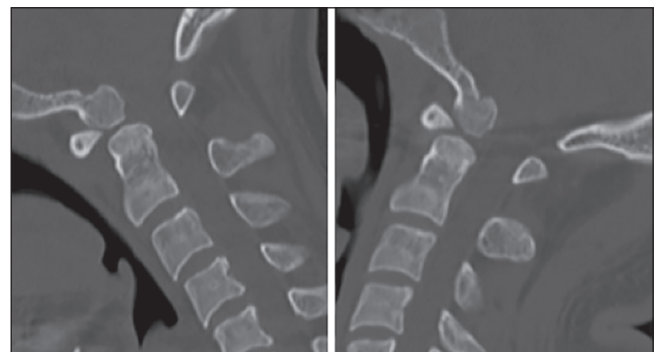

Figure 2: Sagittal reconstruction computed tomography showing an osseous continuity between occiput and an ossicle

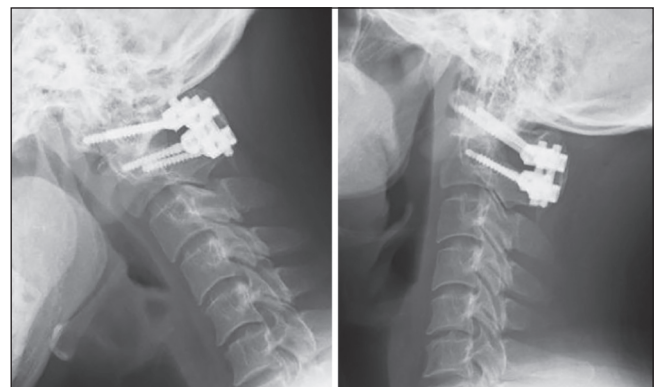


Figure 4: Post-operative flexion/extension lateral radiographs of cervical spine showing rigid fixation between atlas and axis

treatment for atlantoaxial instability with an occipitalized atlas, resembling the current case with the presence of a fused cranial unit, have been published. Jain *et al.*^[9] performed occipitoaxial posterior fusion for 46 patients having congenital atlantoaxial dislocation with an occipitalized atlas. After that, Goel *et al.*^[10] reported eight patients with an occipitalized atlas who had a mobile and reducible atlantoaxial dislocation and underwent lateral mass plate and screw fixation instead of fixation of the much longer plates or rods necessary for occipitocervical fixation. The method could be used even in the situation where the facet of the atlas is occipitalized. This latter report supports our consideration that the shortest fixation for the extent of instability is the ideal intervention. Use of atlantoaxial fixation, instead of occipitoaxial fixation, has the advantage that it can provide stabilization in the anteroposterior direction, while still preserving the flexion-extension motion between the cranial unit and the body of the axis. Although occipitoaxial fixation for this condition seems to be a reasonable strategy for surgical treatment, the longer fixation can spoil the flexion-extension motion and increase the mobility and loading at the inferior adjacent segment.

REFERENCES

- Klimo P Jr, Kan P, Rao G, Apfelbaum R, Brockmeyer D. Os odontoideum: Presentation, diagnosis, and treatment in a series of 78 patients. *J Neurosurg Spine* 2008;9:332-42.
- Klimo P Jr, Rao G, Brockmeyer D. Congenital anomalies of the cervical spine. *Neurosurg Clin N Am* 2007;18:463-78.
- Arvin B, Fournier-Gosselin MP, Fehlings MG. Os odontoideum: Etiology and surgical management. *Neurosurgery* 2010;66:22-31.
- Dai L, Yuan W, Ni B, Jia L. Os odontoideum: Etiology, diagnosis, and management. *Surg Neurol* 2000;53:106-8.
- Ohya J, Chikuda H, Sugita S, Ono T, Oshima Y, Takeshita K, et al. Ossification of the posterior atlantoaxial membrane associated with an os odontoideum: A case report. *J Orthop Surg (Hong Kong)* 2011;19:392-4.
- Weng C, Wang LM, Wang WD, Tan HY. Bipartite atlas with os odontoideum and synovial cyst: Case report and review literature. *Spine (Phila Pa 1976)* 2010;35:E568-75.
- Yamazaki M, Okawa A, Furuya T, Sakuma T, Takahashi H, Kato K, et al. Anomalous vertebral arteries in the extraand intra-osseous regions of the craniovertebral junction visualized by 3-dimensional computed tomographic angiography: Analysis of 100 consecutive surgical cases and review of the literature. *Spine (Phila Pa 1976)* 2012;37:E1389-97.
- Trabacca A, Dicuonzo F, Gennaro L, Palma M, Cacudi M, Losito L, et al. Os odontoideum as a rare but possible complication in children with dyskinetic cerebral palsy: A clinical and neuroradiologic study. *J Child Neurol* 2011;26:1021-5.
- Jain VK, Mittal P, Banerji D, Behari S, Acharya R, Chhabra DK. Posterior occipitoaxial fusion for atlantoaxial dislocation associated with occipitalized atlas. *J Neurosurg* 1996;84:559-64.
- Goel A, Kulkarni AG. Mobile and reducible atlantoaxial dislocation in presence of occipitalized atlas: Report on treatment of eight cases by direct lateral mass plate and screw fixation. *Spine (Phila Pa 1976)* 2004;29:E520-3.

How to cite this article: Ohya J, Miyoshi K, Ki! tagawa T, Nakagawa S. Occipitalized os odontoideum: A case report. *J Craniovert Jun Spine* 2014;5:170-2.

Source of Support: Nil, **Conflict of Interest:** None declared.