

Pelvic lipomatosis: Bladder sparing extirpation of pelvic mass to relieve bladder storage dysfunction symptoms and pelvic pain

Ahmed Ali, Sanjaya Swain and Murugesan Manoharan

Department of Urology, University of Miami Miller School of Medicine, Miami, FL, USA

Article history

Submitted: Feb. 17, 2014

Accepted: April 17, 2014

Correspondence

Murugesan Manoharan
University of Miami Miller School of Medicine
Department of Urology
P.O. Box 016960 (M814)
Miami, FL, 33101, USA
phone: +1 305-243-1973
mmanoharan@med.miami.edu

Pelvic lipomatosis is a rare benign disease, associated with overgrowth of fat in the perivesical and perirectal area. It is of unknown etiology. We describe a 45-year-old male with pelvic lipomatosis causing bladder storage dysfunction symptoms and pelvic pain that affected his quality of life. Surgical excision of the pelvic mass with bladder preservation was performed. After surgery, the patient had a marked improvement in his quality of life, with resolution of bladder storage dysfunction symptoms and pelvic pain.

Key Words: pelvic lipomatosis ♦ bladder

INTRODUCTION

Pelvic lipomatosis is an uncommon benign disease caused by overgrowth of benign fatty tissue in the perivesical and perirectal space [1]. The etiology of pelvic lipomatosis is unknown. Around 70% of cases of pelvic lipomatosis are associated with proliferative cystitis, such as cystitis cystica and cystitis glandularis [1]. These proliferative changes may occur secondary to obstruction of bladder wall drainage, leading to an altered environment rich in protein fluid, which is a nutritional medium for proliferation of tissue [2]. Although pelvic lipomatosis is considered a benign disease, it can cause upper tract obstruction and subsequent renal failure [3]. Computed tomography (CT) is the cornerstone of the diagnosis of pelvic lipomatosis, as the absorption coefficient of pelvic fatty tissue calculated by computer is distinct from that of other pelvic structures in the CT scan. A pear-shaped bladder is a common finding on CT urogram that

is a characteristic indicative of pelvic lipomatosis [3]. The ideal management of pelvic lipomatosis is not well established due to the lack of literature and follow-up information. The recommended treatment options vary from watchful waiting to radical surgical options, including total cystectomy and urinary diversion [4]. Cystitis cystica and cystitis glandularis have been observed in more than two-thirds of cases of pelvic lipomatosis, and both of these lesions have been regarded as a premalignant lesion of adenocarcinoma of the bladder [5]. Diagnosis of cystitis glandularis is based on pathological examination. The treatment options vary from long-term antibiotics, transurethral resection of the lesions to cystectomy and urinary diversion [6]. We describe a 45-year-old male patient with pelvic lipomatosis associated with voiding symptoms, persistent pelvic pain and poor quality of life. A bladder-sparing excision of the pelvic lipomatosis mass was performed, thereby avoiding the need for urinary diversion.

CASE REPORT

A 45-year-old Hispanic male patient with BMI of 31.8, presented with persistent pelvic and suprapubic pain for more than two years. He also complained of voiding symptoms in the form of increased daytime frequency (every 15 minutes), nocturia (2–3 times), urgency and urge incontinence affecting his quality of life. Physical examination revealed vague lower abdominal tenderness, with no palpable bladder. CT urogram showed a tubular bladder extending up to the level of the fourth lumbar vertebrae and surrounded by fat that showed some infiltrative changes (Figure 1A). Fine needle aspiration (FNA) biopsies from the fat around the bladder and urine cytology were negative for malignancy. Cystoscopy was performed and it showed a tubular bladder with bladder capacity less than 100 cc. A biopsy was taken from the bladder wall, which was negative for malignancy. Because of bothersome symptoms and a poor quality of life, the patient elected to undergo surgical excision of the pelvic mass. A laparotomy was performed through a midline incision, the urachus was identified and a fatty lump with some indurations was noted. The urachus and the fatty lump over the bladder dome sent for frozen section analysis revealed no malignancy. The pelvic mass was bivalved up to the level of the bladder. The bladder was mobilized all around and the pelvic mass was excised completely. We avoided dissection around the posterior trigone and lateral aspect of the rectum to preserve the nerve supply to the bladder. After surgery, a marked improvement of the patient's symptoms was noted with bladder capacity reaching 400 cc. A CT cystogram was performed showing a return of normal globular pattern of the bladder with marked reduction in the surrounding fat (Figure 1B).

DISCUSSION

Pelvic lipomatosis is a rare proliferative disease characterized by overgrowth of fat in the pelvic retroperi-

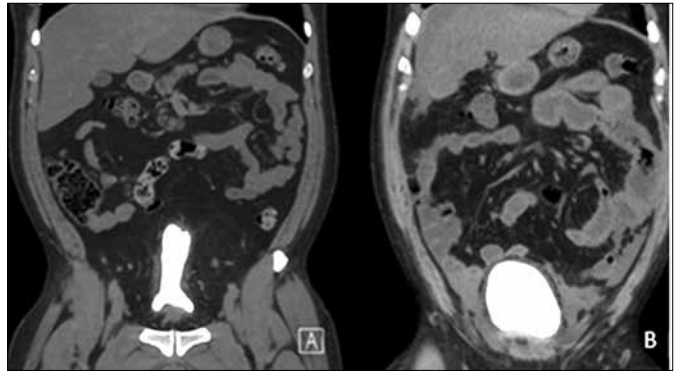


Figure 1. A. CT Cystogram showed excessive fat deposition around the bladder and elongated bladder. B. Marked reduction of fatty tissue around the bladder and globular contour of the bladder (post-operative).

toneal space. Various options to treat pelvic lipomatosis, including steroids, long-term antibiotics, weight reduction and radiation therapy have proven to be ineffective [1]. Urinary diversion, in the form of ileal conduit, nephrostomy tube or vesicostomy, is a treatment option to relieve urinary obstruction associated with pelvic lipomatosis [7]. In the present case, due to persistent and progressive complaints of pelvic pain and bladder storage dysfunction symptoms with a poor quality of life, we elected to perform surgical exploration and pelvic mass resection. After discussing various treatment options, the patient opted for a bladder-preserving procedure due to his age and intention to preserve his quality of life. We used the bladder wall as a guide for dissection. In this case, we were able to preserve the bladder and avoid urinary diversion. During the procedure, care was taken to protect the ureters, iliac vessels and pelvic nerves. Postoperatively, we recommended lifestyle modification in the form of weight reduction. Finally, in patients with pelvic lipomatosis with persistent pelvic pain and voiding dysfunction symptoms, we recommend surgical excision of pelvic fat with bladder preservation as a treatment option.

References

1. Heyns CF. Pelvic lipomatosis: a review of its diagnosis and management. *J Urol.* 1991; 146: 267–273.
2. Heyns CF, Kirsten PH, Van Velden DJ. Pelvic lipomatosis associated with cystitis glandularis and adenocarcinoma of the bladder. *J Urol.* 1991; 145: 364–366.
3. Xia S, Yan Y, Peng B, Yang B, Zheng J. Image characteristics of computer tomography urology in pelvic lipomatosis. *Int J Clin Exp Med.* 2014; 7: 296–299.
4. Jones BJ. Pelvic lipomatosis. *Br J Urol.* 1991; 67: 656–657.
5. Sözen S1, Gürocak S, Uzüm N, Biri H, Memiş L, Bozkırlı I. The importance of re-evaluation in patients with cystitis glandularis associated with pelvic lipomatosis: a case report. *Urol Oncol.* 2004; 22: 428–430.
6. Michajłowski J, Matuszewski M, Kłęcz J, Gibas A, Biernat W, Krajka K. Acute urinary retention in a patient with extended cystitis glandularis. *Cent European J Urol.* 2011; 64: 94–96.
7. Halachmi S, Moskovitz B, Calderon N, Nativ O. The use of an Ultrasonic Assisted lipectomy device for the treatment of obstructive pelvic lipomatosis. *Urology.* 1996; 48: 128–130. ■