



## Case report

# Persistent complete hydatidiform molar pregnancy following assisted reproductive technology in a gestational carrier: Case report

Oleksandra Dzyubak, Jamie Lee Fritz, Taryn Taylor, Jacob McGee\*

Department of Obstetrics & Gynecology, London Health Sciences Centre, Victoria Hospital, 800 Commissioners Rd E, London, Ontario N6A 5W9, Canada

## ARTICLE INFO

## Keywords:

Hydatidiform mole  
Complete molar pregnancy  
Assisted reproduction techniques  
Persistent trophoblastic disease  
In vitro fertilization  
Frozen embryo transfer

## ABSTRACT

A hydatidiform mole is a rare pathology associated with pregnancy, attributed to abnormal gametogenesis and fertilization. When assisted reproduction techniques (ART) are used, the incidence of molar pregnancy is significantly lower however not eliminated. We report a case of a patient serving as a gestational carrier who developed a complete molar pregnancy, with features indicating persistent trophoblastic disease. This 33-year-old G4T3P0A1L3 woman presented with bleeding at 8 weeks gestational age, after in vitro fertilization and frozen embryo transfer. Ultrasound findings and beta-HCG levels were consistent with molar pregnancy. Pathology specimen from D&C confirmed a complete hydatidiform mole. Despite surgical treatment, beta-HCG remained elevated and multiple pulmonary nodules and enlarged lymph nodes were noted on imaging. Methotrexate was considered but was deemed unnecessary because beta-HCG levels returned to normal over time and nodules resolved. Because molar pregnancy carries a risk of malignant transformation, albeit low, individuals undergoing ART should be counselled.

## 1. Introduction

A hydatidiform mole (HM) is a premalignant form of a gestational trophoblastic disease, associated with abnormal gametogenesis and fertilization (Ngan, 2018). In most parts of the world, the incidence of HM is roughly 1 per 1000 pregnancies (Ngan, 2018). Risk is associated with age at each extreme (<15 and > 45) and with a history of previous molar pregnancy (Ngan, 2018); (Candelier, 2016). Following a single molar pregnancy, the recurrence rate is 1–2%. This risk substantially increases to 15–20%, after a second (Candelier, 2016).

The Human Fertility and Embryology Authority (HFEA) in the United Kingdom has been collecting data on molar pregnancies resulting from assisted reproduction techniques (ART) since 1991 until February of 2018 (Nickkho-Amiry, 2019). Among data from 276,655 pregnancies, between 68 and 71 cases of hydatidiform moles developed from fresh or frozen embryo transfer (Nickkho-Amiry, 2019). Despite the greatly reduced risk, the incidence of molar pregnancy is not completely eliminated with the use of ART. The following case covers a persistent complete molar pregnancy occurring in a gestational carrier post frozen embryo transfer.

## 2. Case

A 33-year-old, G4T3P0A1L3 woman, presented to the gynecology oncology clinic with a recently treated complete molar pregnancy post in vitro fertilization (IVF) with a lack of regression of beta-HCG levels, raising concerns regarding persistent trophoblastic disease.

The patient was a gestational carrier for the second time, for the same couple. Biological father's age was 38. The egg was obtained from a 26-year-old donor. She underwent a frozen embryo transfer, at the day 5 blastocyst stage. Intracytoplasmic sperm injection (ICSI) procedure and pre-implantation genetic diagnosis was used. The patient had 3 previous pregnancies without complications, with the third one being a surrogate. Past medical history was insignificant; however, she had a D&C for a retained placenta product after the third delivery. Family history was negative, with the only significant instance being a grandmother with cervical cancer.

At approximately 8 weeks gestational age, the patient presented to the emergency department with vaginal bleeding, ongoing nausea, and emesis. Beta-HCG level was 287, 645. The ultrasound showed a bulky uterus with heterogeneous material. There was no gestational sac or embryo identified (Fig. 1). The chest X-ray was normal. She had a D&C and was discharged with weekly blood work to monitor beta-HCG levels.

\* Corresponding author.

E-mail address: [Jacob.McGee@lhsc.on.ca](mailto:Jacob.McGee@lhsc.on.ca) (J. McGee).

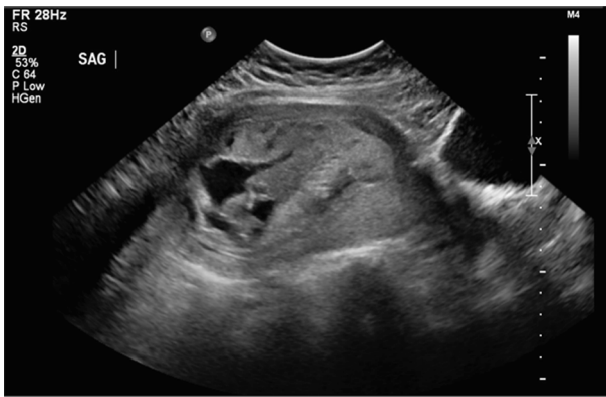

Fig. 1. Pelvic ultrasound showing an enlarged uterus with heterogeneous material.

The pathology report was consistent with a complete hydatidiform mole. A week following the operation, beta-HCG was 4161. However, on four subsequent assessments, beta-HCG remained in the 1, 000 s range (Table 1).

Due to a month-long history of continually elevated beta-HCG levels, the patient was referred to the gynecology oncology clinic for possible persistent trophoblastic disease. She was asymptomatic and a repeat ultrasound showed a normal uterus. However, a further chest X-ray demonstrated a new 1 cm nodule in the right lung. The patient received follow-up imaging with a CT scan of her thorax, abdomen, and pelvis, as well as a brain MRI. The CT scans showed multiple bilateral pulmonary nodules (Fig. 2), as well as, enlarged axillary and iliac lymph nodes. No abnormalities were seen on brain MRI. At the time of the CT scans, the beta-HCG level was 501. She remained asymptomatic, and the beta-HCG level repeated a week later was 86. Beta-HCG was assessed weekly and continued trending down, ultimately to  $< 1$  (Table 1). Following 2 months, a CT scan showed a reduction in the size of the dominant nodule and resolution of all other nodules. At 7 months, all lesions were resolved on imaging. Regarding the enlarged axillary lymph nodes, the patient had ultrasound follow-ups at 3-month intervals. With no resolution after 2 assessments, a biopsy was done. Pathology was consistent with reactive lymphoid hyperplasia, without evidence of lymphoma or metastasis. Systemic chemotherapy was initially considered; however, as beta-HCG levels were in decline, pulmonary nodules were resolving, and the patient remained asymptomatic, a decision was made to hold off on the treatment.

### 3. Discussion

The incidence of molar pregnancy is significantly lower with the use of ART in comparison to spontaneous conception; however, it is not eliminated. According to the HFEA data, the incidence of molar pregnancy with a fresh cycle IVF is 1/4333 and between 1/2317 to 1/28967 with a frozen cycle. This suggests that molar pregnancies may be 50–100% more likely to occur in a frozen cycle IVF (Nickkho-Amiry, 2019). The HFEA data does not distinguish between complete and partial moles (Nickkho-Amiry, 2019).

Hydatidiform moles are histologically classified as complete or partial. A partial mole arises from the fertilization of a haploid ovum by two separate sperm, resulting in a triploid genome (Candelier, 2016). On gross examination, focal villous edema and fetal parts are present (Candelier, 2016); (Froeling and Seckl, 2014). By contrast, a complete mole has a diploid, androgenetic genome, consisting of chromosomes of paternal origin. The majority (80%) of complete moles arise when maternal DNA is lost from the ovum, before or immediately after fertilization, followed by a subsequent duplication of a single sperm's chromosomes (Candelier, 2016). The rest (20%) of complete moles occur when two separate sperm fertilize an empty ovum – with absent

Table 1

Beta-hCG levels over the post-operative course.

1	4161
2	1321
3	1497
4	1211
5	1144
6	931
6.5	507
7.5	86
8	44
8.5	12
9	6
10	1
11	1
12	1

maternal DNA (Candelier, 2016). In rare cases (1%), a complete mole occurs when an egg carrying a mutated copy of the *NLRP7* gene, is fertilized by a healthy sperm. This results in a biparental diploid mole (Murdoch, 2006). Complete moles are characterized by hydropic villi with diffuse trophoblast hyperplasia and the absence of fetal parts (Candelier, 2016); (Froeling and Seckl, 2014). Despite the exact cause remaining unknown, mole formation is attributed to abnormal gametogenesis and fertilization (Candelier, 2016).

ART has been used to overcome infertility and includes IVF – with or without intracytoplasmic sperm injection (ICSI) (Nickkho-Amiry, 2019). ICSI allows direct injection of a single sperm into an ovum during IVF.

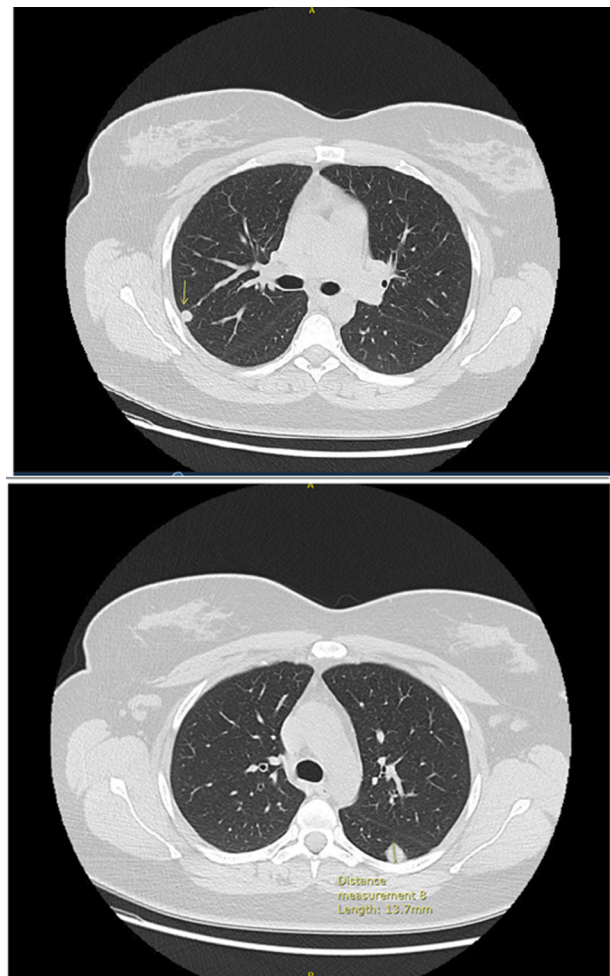


Fig. 2. CT scan of the thorax showing multiple pulmonary nodules.

IVF, especially when accompanied by ICSI, should theoretically protect against dispermic fertilization. The use of IVF coupled with ICSI and pre-implantation genetic diagnosis can serve as a means to avoid a recurrent molar pregnancy, as ICSI can guarantee monospermic fertilization (Nickkho-Amiry, 2019).

The origins of triploidy can be diandric (69%) or digynic (31%) (Zaragoza, 2000). The majority (86%) of the diandry occurs due to dispermic fertilization while 8.3% is attributed to diploid sperm (Zaragoza, 2000; Rosen, 2006). The majority of digynic triploidy cases originate from a diploid egg, occurring following the failure of meiosis (Zaragoza, 2000). The protective nature of ART may be the elimination of dispermic fertilization through ICSI, as well as, morphology-based assessment and selection of embryos during standard IVF (Nickkho-Amiry, 2019). However, there are a few mechanisms by which molar pregnancy may evolve despite the use of ART.

Following standard IVF, evidence suggests that triploidy most commonly occurs due to dispermic fertilization (Rosen, 2006). The underlying mechanism for this is a defect in oocyte function and failure to block fertilization by multiple sperm (Rosen, 2006). Diandric triploidy results in a partial mole; however, if during this process, maternal DNA is lost or destroyed, a complete mole can arise. While the use of ICSI completely eliminates the possibility of dispermic fertilization, cases of triploidy have been reported following its use. In their study, Grossmann et al. found the non-extrusion of the second polar body is the main cause of triploid zygotes, with ICSI treatment (Grossmann, 1997). Macas et al. found that the rate of chromosomal abnormalities, transmitted through spermatozoa during ICSI, was 7.4%; out of this, sperm diploidy constituted 33% (Macas et al., 2001).

During IVF, cytogenetic assessment of the fertilized ovum can pick up the presence of the three pronuclei, which arise following dispermic fertilization (Rosenbusch, 2008). However, in the case of diploidy, spermatozoa will still provide only one pronucleus, thus the pronuclear stage would appear normal during visualization (Rosenbusch, 2008). In healthy men, diploid sperm account for about 0.2–0.3%, but it may be as high as 1.9% in males with oligozoospermia (Rosenbusch, 2008). Because ICSI is geared towards couples with male factor infertility, there is a possibility that a diploid sperm was used.

Molar pregnancy may arise during ART because of a genetic anomaly. In rare cases, complete moles can be diploid with a biparental contribution (Murdoch, 2006). They tend to be recurrent in the same patient and arise due to a mutation in the maternal *NLRP7* gene (Murdoch, 2006). A mutation in the *NLRP7* gene can also manifest as recurrent spontaneous abortions or stillbirths (Murdoch, 2006), which are common reasons for couples to seek gestational carriers and use ART in the first place.

In this case, the patient served as a gestational carrier for the second time, for the same couple. As the first pregnancy was successful and unremarkable, it is unlikely that a mutation of the *NLRP7* gene was at play. It is important to note that factors such as advanced age, immature oocytes, failure to prevent dispermic fertilization and severe sperm abnormalities that lead to infertility, and the need for ART, are also responsible for the development of molar pregnancies. As a result, a pre-implantation genetic diagnosis may be warranted during IVF.

A complete molar pregnancy carries a 15% risk of malignant transformation (Candelier, 2016). In our case, beta-HCG persisted post D&C and lung nodules were seen on the chest x-ray and the CT scan. Systemic chemotherapy was considered; however, it was not necessary due to the nodules resolving on their own and beta-HCG levels gradually declining.

Nodules resolved before a biopsy was performed. It is unclear whether these findings stem from the persistent trophoblast disease or are incidental. Candelier reports approximately 80% of moles to be self-limiting (Candelier, 2016).

Despite the low incidence of molar pregnancies, their risk is not completely eliminated through the use of IVF. The egg and sperm that are used may have underlying anomalies, leading to both infertility and mole development. The Canadian guideline “Pregnancy Outcomes After Assisted Human Reproduction”, lists multiple risks, but molar pregnancy is not one of them (Froeling and Seckl, 2014). Considering the risk of malignant transformation and even the development of choriocarcinoma, it may be worthwhile to include it in future guidelines and counsel both the couple and the gestational carrier regarding this rare, but important outcome. Pre-implantation genetic diagnosis can detect a mole, as well as other genetic disorders, and thus may be offered during counselling as a means to eliminate the risk of this complication (Nickkho-Amiry, 2019).

#### Informed Consent

Written informed consent was obtained from the patient for publication of this case report. A copy of the written consent is available for review by the Editor-in-Chief of this journal on request.

#### CRediT authorship contribution statement

**Oleksandra Dzyubak:** Writing - original draft, Writing - review & editing. **Jamie Lee Fritz:** Writing - review & editing. **Taryn Taylor:** Writing - review & editing. **Jacob McGee:** Supervision, Writing - review & editing.

#### Declaration of Competing Interest

The authors declared that there is no conflict of interest.

#### Acknowledgements

The woman whose story is described in this case report has provided written consent for its publication.

#### References

- Ngan, H.Y.S., et al., 2018. Update on the diagnosis and management of gestational trophoblastic disease. *Int. J. Gynecology Obstetrics* 143, 79–85.
- Candelier, J.-J., 2016. The hydatidiform mole. *Cell Adhesion Migration* 10 (1-2), 226–235.
- Nickkho-Amiry, M., et al., 2019. Hydatidiform molar pregnancy following assisted reproduction. *J. Assist. Reprod. Genet.* 36 (4), 667–671.
- Froeling, F.E.M., Seckl, M.J., 2014. Gestational trophoblastic tumours: an update for 2014. *Current Oncology Reports* 16 (11), 408.
- Murdoch, S., et al., 2006. Mutations in *NALP7* cause recurrent hydatidiform moles and reproductive wastage in humans. *Nat. Genet.* 38 (3), 300.
- Zaragoza, M.V., et al., 2000. Parental origin and phenotype of triploidy in spontaneous abortions: predominance of diandry and association with the partial hydatidiform mole. *Am. J. Human Genetics* 66 (6), 1807–1820.
- Rosen, M.P., et al., 2006. Triploidy formation after intracytoplasmic sperm injection may be a surrogate marker for implantation. *Fertil. Steril.* 85 (2), 384–390.
- Grossmann, M., et al., 1997. Origin of triprounucleate zygotes after intracytoplasmic sperm injection. *Human Reproduction (Oxford, England)* 12 (12), 2762–2765.
- Macas, E., Imthurn, B., Keller, P.J., 2001. Increased incidence of numerical chromosome abnormalities in spermatozoa injected into human oocytes by ICSI. *Hum. Reprod.* 16 (1), 115–120.
- Rosenbusch, B.E., 2008. Mechanisms giving rise to triploid zygotes during assisted reproduction. *Fertil. Steril.* 90 (1), 49–55.