

---

## Radiofrequency ablation and phenol neurolysis in a case of glossopharyngeal neuralgia due to a rare aetiology

Sir,

Glossopharyngeal neuralgia (GPN) is a rare facial pain syndrome (incidence 0.2–0.7 per 1,00,000) with clinical features of excruciating lateralised pain in the sensory innervation territory of glossopharyngeal nerve; triggered by chewing, yawning, talking and emotional stress.<sup>[1]</sup> Aetio-pathologically, GPN can be idiopathic or secondary to compression from adjacent vascular structures or tumour; Paget's disease; Eagle's syndrome or Sjogren's syndrome.<sup>[2]</sup> Interventional cranial nerve IX (CN IX) neurolysis, though a feasible management strategy, has been rarely performed<sup>[3]</sup> compared to trigeminal neurolysis,<sup>[4]</sup> in view of the complexity of approach and risk of serious complications. We report a case of GPN due to a rare aetiology and its management.

A 38-year-old female has been having gradually progressing pain inside the ear, tonsils and base of the

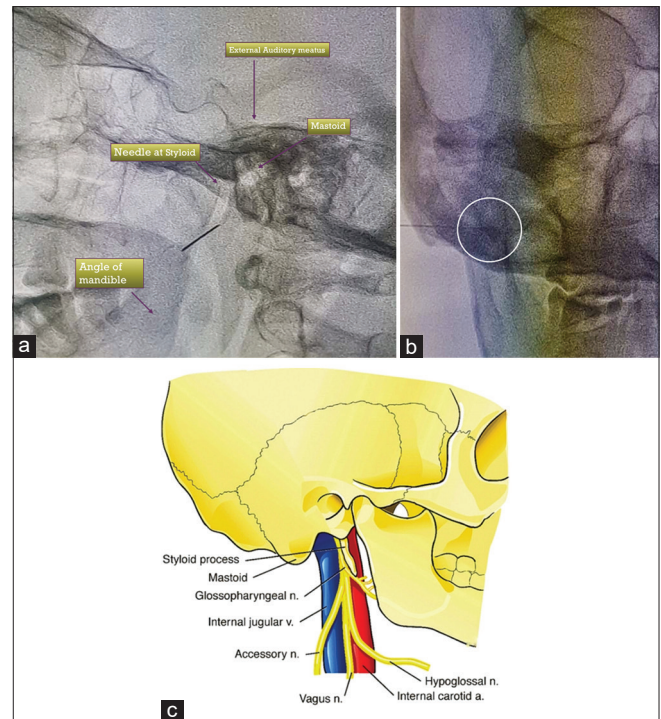
tongue since last 6–8 months. The patient reported up to 30–40 attacks of pain, with numeric rating score (NRS) of 9–10/10, during a 24-h stretch which seriously disturbed her daily pursuit with suicidal ideas and sleep disturbances. She didn't have any other comorbidity apart from a past history of partial styloidectomy done one and a half years back for similar symptoms. After an asymptomatic postoperative interval, the pain recurred by 7–8 months. Neurologic examination revealed hyperaesthesia of posterior pharyngeal wall. MRI revealed no vascular abnormality/tumour. We diagnosed her as a case of scar induced secondary GPN. After obtaining written informed consent, we conducted a diagnostic CN IX block with local anaesthetic (LA) Lignocaine and 40 mg triamcinolone intra-orally at the base of the posterior tonsillar pillar. The patient had dramatic pain relief lasting 24 h. Further, we did a conventional radio-frequency ablation (RFA) of CN IX and phenol neurolysis under fluoroscopic guidance via extraoral approach. We localised the remnant of styloid process in lateral fluoroscopic view [Figure 1a and b] using curved RF needle of 10-mm active tip. At the posterior aspect of remnant styloid (almost 4 cm from the skin), using 0.5 mV current at 50 Hz frequency, pain along CN IX sensory innervation area was reproduced. On subsequent motor stimulation, no contractions of

diaphragm and sternocleidomastoid muscles were noticed. RFA lesioning was done at 50°C for 60 s, 60°C for 60 s and 70°C for 60 s; following which 1 mL of 7% phenol was instilled in order to provide lasting pain relief. For 48 h post-procedure, the patient reported an NRS score of 5–6/10 which we attributed to probable neuritis. The patient reported near to complete pain relief on assessments at 2 weeks, 1 month, 6 months and 1-year post-procedure (NRS 3/10, 1/10, 0/10 and 0/10 respectively) and analgesics were gradually discontinued.

To date, very few case reports have considered RFA and neurolysis for GPN.<sup>[3]</sup> Our case posed a challenging and rare scenario of scar induced GPN as partial styloidectomy made the fluoroscopic landmarks difficult to identify. Nerve entrapment in the scar tissue was probably the cause of pain in our case. This can be further demanding as scars after bone resections are highly collagenised and thicker compared to post-tonsillectomy scars. Collagen in scar tissue has properties similar to electrical dipoles.<sup>[5]</sup> We assume that scar traction induced action potentials are transmitted centrally via CN IX afferent nociceptive fibres reinforcing the central sensitisation process.

A CN IX neurolysis must be performed by an experienced pain physician with extreme caution due to its proximity to other CNs and major vascular structures [Figure 1c]. A well-circumscribed lesion created by conventional RFA is shaped like a match head. Using a needle of 22-gauge with 0.71 mm in diameter the usual lesion size is around 2–4 mm. The heated lesion is maximal around the shaft of the needle and minimal ahead of the tip with the needle placed parallel to the nerve. During CN IX RFA the thermo-coagulation needle is perpendicular to the nerve; therefore expected lesion size need not be optimal. Hence, in our case, we used RFA needle for sensory-motor stimulation to confirm optimal needle placement whereas to provide a long-lasting effect and good lesion we added chemical neurolysis with Phenol. The reported complications of RFA and alcohol neurolysis in GPN are upper airway obstruction, weakness of trapezius and hypertension due to blockade of CN XII, XI and X respectively.<sup>[6]</sup> Our patient underwent RFA and neurolysis without any of the disabling complications.

Another therapeutic option which we considered was neurolysis of superior cervical ganglion<sup>[7]</sup> though



**Figure 1:** (a) Lateral fluoroscopic image with labelled anatomical landmarks and RFA needle at remnant styloid process. (b) Antero-posterior fluoroscopic view confirming needle position just inside the mandibular margin. (c) Diagrammatic depiction of anatomical relation between glossopharyngeal nerve, styloid process and other cranial nerves

we did not attempt the same due to reported higher incidence of complications. Adequate preprocedural clinical and radiologic evaluation to rule out all etiologic possibilities of neuralgia; trial of maximum medical therapy; conduct of a diagnostic block with LA; and further meticulous conduct of RFA and phenol neurolysis lead to successful pain-free outcome in our case without any peri-procedural complications.

#### Declaration of patient consent

The authors certify that they have obtained all appropriate patient consent forms. In the form, the patient(s) has/have given his/her/their consent for his/her/their images and other clinical information to be reported in the journal. The patients understand that their names and initials will not be published and due efforts will be made to conceal their identity, but anonymity cannot be guaranteed.

#### Financial support and sponsorship

Nil.

#### Conflicts of interest

There are no conflicts of interest.

**Anurag Aggarwal, Varun Suresh<sup>1</sup>**

Consultant Neuroanesthetist and Pain Medicine, Department of Anaesthesia, Fortis Hospital, Noida, Gautam Buddh Nagar, Uttar Pradesh, <sup>1</sup>Department of Anaesthesiology, Government Medical College, Thiruvananthapuram, Kerala, India

**Address for correspondence:**

Dr. Anurag Aggarwal,  
Consultant Neuroanesthetist and Pain Medicine, Fortis Hospital, Noida, Gautam Buddh Nagar, Uttar Pradesh, India.  
E-mail: anuragaggarwal10@gmail.com

**Submitted:** 19-Jan-2020

**Revised:** 20-Feb-2020

**Accepted:** 29-Feb-2020

**Published:** 01-May-2020

**REFERENCES**

1. Blumenfeld A, Nikolskaya G. Glossopharyngeal neuralgia. *Curr Pain Headache Rep* 2013;17:343.
2. Claesen P, Plets C, Goffin J, Van den Bergh R, Baert A, Wilms G. The glossopharyngeal neurinoma. Case reports and literature review. *Clin Neurol Neurosurg* 1989;91:65-9.
3. Shah RV, Racz GB. Pulsed mode radiofrequency lesioning to treat chronic post-tonsillectomy pain (secondary glossopharyngeal neuralgia). *Pain Pract* 2003;3:232-7.
4. Maarbjerg S, Di Stefano G, Bendtsen L, Cruccu G. Trigeminal neuralgia-diagnosis and treatment. *Cephalalgia* 2017;37:648-57.
5. Athenstaedt H. Pyroelectric and piezoelectric properties of vertebrates. *Ann N Y Acad Sci* 1974;238:68-94.
6. Jänig W, Baron R. Complex regional pain syndrome: Mystery explained? *Lancet Neurol* 2003;2:687-97.
7. Siegenthaler A, Haug M, Eichenberger U, Suter MR, Moriggl B. Block of the superior cervical ganglion, description of a novel ultrasound-guided technique in human cadavers. *Pain Med* 2013;14:646-9.

This is an open access journal, and articles are distributed under the terms of the Creative Commons Attribution-NonCommercial-ShareAlike 4.0 License, which allows others to remix, tweak, and build upon the work non-commercially, as long as appropriate credit is given and the new creations are licensed under the identical terms.

Access this article online	
Quick response code	Website: www.ijaweb.org
	DOI: 10.4103/ija.IJA_9_20

**How to cite this article:** Aggarwal A, Suresh V. Radiofrequency ablation and phenol neurolysis in a case of glossopharyngeal neuralgia due to a rare aetiology. *Indian J Anaesth* 2020;64:437-9.  
© 2020 Indian Journal of Anaesthesia | Published by Wolters Kluwer - Medknow