

Abnormal uterine bleeding: an evaluation endometrial biopsy, vaginal ultrasound and outpatient hysteroscopy

D C Hunter, N McClure

Accepted 26 March 2001

SUMMARY

Abnormal uterine bleeding is a common gynaecological symptom. Whilst most patients have benign disease, thorough investigation is necessary, particularly in the peri- and post-menopausal woman. Hysteroscopy with directed biopsy of suspicious lesions is the gold standard investigation but it is invasive and is not offered in all units as an outpatient procedure. Ultrasound and outpatient biopsy techniques may allow patients to be triaged to select those who require formal evaluation by hysteroscopy.

We assessed the records of 100 consecutive referrals to the outpatient hysteroscopy clinic at the Royal Maternity Hospital, Belfast. In order to develop a nomogram for the investigation of women with abnormal bleeding patterns, we compared ultrasound/biopsy diagnoses with hysteroscopy/biopsy diagnosis. Pre- and peri-menopausal patients, and post-menopausal patients taking hormone replacement therapy should be investigated further if the endometrial thickness is more than 10 mm, if endometrial biopsy is abnormal, or if symptoms are recurrent. Similarly, post-menopausal patients not taking hormone replacement therapy with an endometrial thickness of 5 mm or more should be referred for hysteroscopy.

INTRODUCTION

Abnormal uterine bleeding is a common gynaecological symptom. In peri- and post-menopausal women it is essential to exclude endometrial carcinoma although the incidence is only 6.96 per 1000 women with post menopausal bleeding.¹ In younger women, endometrial hyperplasia and anatomical anomalies, such as uterine fibroids, comprise the main pathology.²

The recommendation regarding investigation of abnormal uterine bleeding from the Royal College of Obstetricians and Gynaecologists is that women, over the age of 45, should be investigated with hysteroscopy and endometrial biopsy.³ Frequently, this is performed as an inpatient procedure with the biopsy being obtained by uterine curettage (D&C). Blind sharp curettage covers as much as 60% of the cavity but may miss polyps as they recoil from the passing curette.⁴ However, inpatient investigations are costly and there are risks associated with the use of general anaesthesia.

Outpatient alternatives to D&C include microhysteroscopy (either flexible or rigid),

transvaginal ultrasonography, with or without saline infusion (sonohysterography) and endometrial biopsy. Transvaginal ultrasonography is useful in determining endometrial thickness and morphology as well as the regularity of the endo/myometrial border.⁵ Whilst the procedure is well tolerated by patients, sessile or pedunculated lesions of the endometrium and malignant disease cannot be definitively excluded.^{6,7} However, it has been reported that post-menopausal malignant disease is very unlikely when the endometrial thickness is less than 5 mm and the patient is not taking hormone replacement therapy (HRT).⁸ Vaginal sonohysterography is a modification of vaginal ultrasound in which a small volume of saline is injected into the uterine cavity during ultrasound examination.⁹ This enables irregularities of the

School of Medicine, Obstetrics and Gynaecology, Queen's University Belfast, Grosvenor Road, Belfast BT12 6BJ.

David C Hunter, Specialist Registrar.

Neil McClure, Professor of Obstetrics and Gynaecology.

endo/myometrial border and the free endometrial border to be more easily visualised.¹⁰

Outpatient endometrial sampling devices have a narrow bore (typically about 3 mm external diameter) and sample the endometrium by aspiration. Although they pass relatively easily through the cervical canal, there may be associated pain when the sample is harvested and, unlike directed biopsy, the sample is obtained blind. As little as 4% of the cavity may be sampled and polypoid lesions are unlikely to be removed.¹¹ However, the reported sensitivity for detecting endometrial abnormality is approximately 85%.^{12, 13}

Outpatient hysteroscopy is both feasible and highly acceptable in the majority of patients, giving a high detection rate for intrauterine pathology.^{14, 15} It allows the operator to take a directed biopsy and is more specific and sensitive than transvaginal ultrasound or blind endometrial sampling. As an investigation for abnormal uterine bleeding it was recommended by both the Royal College of Obstetricians and Gynaecologists and the American College of Obstetricians and Gynecologists in 1994.^{3, 16} However, it is significantly less easily performed than either ultrasound or biopsy. Therefore, a means of selecting patients by, for example, menopausal status, symptomatology and associated clinical findings might lead to a more efficient use of hysteroscopy than a blanket recommendation that all cases of abnormal bleeding should undergo the procedure.

Our aim was to develop a nomogram using historical information, ultrasound and biopsy results to select those women who should have a formal hysteroscopic evaluation.

METHODS

The charts of 100 consecutive referrals for outpatient hysteroscopy from the general gynaecology clinics at the Royal Group of Hospitals' Trust, Belfast, were reviewed. The decision to refer was made by the patient's consultant: there were no defined guidelines for referral: a number of patients had vaginal ultrasound scan and endometrial biopsy at the outpatient clinic prior to referral (these procedures were repeated at the outpatient hysteroscopy clinic). The indication for the procedure, the subject's age, parity, menstrual status and outcome of the investigation were recorded. All of the

procedures were performed by a single operator. Whilst the data was recorded prospectively at the time of consultation it was analysed retrospectively.

The examination of each subject followed a standard protocol. The patient was placed in the lithotomy position with her ankles supported by stirrups. A bimanual vaginal examination was performed to note the size, position and shape of the uterus and the presence or absence of adnexal pathology. Vaginal ultrasound examination using a 5 MHz probe (FF Sonic, Fukuda Denshi, Japan) was performed to determine the dual endometrial thickness (ET), that is, the perpendicular distance from one endo/myometrial border to the other at its widest part in longitudinal section, and to identify endometrial polypoid lesions, free fluid or fibroids.

For the hysteroscopy a Simm's speculum was inserted into the vagina and the cervix grasped with a single toothed tenaculum forceps. A 3.4 mm external diameter Hamou Microhysteroscope (Karl Storz, Tuttlingen, Germany) was passed through the cervix, under direct vision, into the uterine cavity which was distended by carbon dioxide via a hysteroflator (Karl Storz) set at maximum pressure 75 mmHg and flow rate of 200 mls/minute. The cavity was illuminated by a Coldlight Fountain (Karl Storz) and the images displayed on a Sony Trinitron monitor using a Telecam Pal single chip camera system (Karl Storz). The endometrium was serially inspected for pathology. When the inspection of the cavity was complete the gas and scope were removed from the uterus.

Finally, a Pipelle endometrial sampler was used to obtain a biopsy of the endometrium using no more than two attempts at sample aspiration. The specimen was placed in formalin and sent for histopathological analysis. Neither analgesia or anaesthesia was routinely used and was not required by any patient in this series.

The histological and ultrasound diagnoses were combined to formulate a working ultrasound/biopsy diagnosis and this was compared with a similarly combined hysteroscopy/biopsy diagnosis.

RESULTS

The average age of the patients referred was 48.5 years (29-78). Six subjects were nulliparous, six were grand multiparas and the remainder had had

Table I
 Comparison of hysteroscopy/biopsy and transvaginal scanning/biopsy diagnoses in postmenopausal patients

<i>Hysteroscopy/biopsy diagnosis</i>	<i>Ultrasound/biopsy diagnosis concordant</i>	<i>Ultrasound/biopsy diagnosis discordant</i>
Normal	16	0
Atrophy	16	1 endometrial polyp
Endometrial polyp	2	2 normal cavity
Endocervical polyp	0	3 normal uterus
Neoplasm	1	0

between one and five vaginal deliveries. Of the 100 patients, it was not possible to perform outpatient hysteroscopy in two cases. Both were post-menopausal and subsequently underwent hysteroscopy under general anaesthesia. In one of these patients the uterus was anteverted and acutely anteflexed, in the other, access to the vaginal vault and cervix was impossible and a diagnosis of erosive vaginal lichen planus was eventually made. These two patients were not considered further in the analysis.

Ninety two (94%) patients had endometrial biopsy samples which were adequate for histological diagnosis. The six patients whose biopsies were not adequate for diagnosis had atrophic endometrium diagnosed both by hysteroscopy and scanning.

Forty-one (41.8%) of the patients were post-menopausal and, of these, 25 (61%) were using hormone replacement therapy. In 35 of the 41 subjects (85.4%) the hysteroscopic diagnosis was in agreement with the ultrasound diagnosis. Thirty-two (78%) had a diagnosis of a normal cavity or of atrophy, two (4.9%) of benign endometrial polyps and one (2.4%) of endometrial cancer (endometrial thickness 20 mm on scanning and copious blood clot within the cavity on hysteroscopy). Of the remaining six (14.6%), three had normal ultrasound and biopsy but endocervical polyps were noted at hysteroscopy (two HRT users), one of whom also had a small endometrial polyp (endometrial thickness >5 mm in all three). Three further subjects had endometrial polyps in isolation noted on hysteroscopy (one HRT user), two of whom had an endometrial thickness >6 mm (summarised in Table I) and one a diagnosis of atrophy on the

basis of the ultrasound biopsy findings (endometrial thickness 3 mm, HRT user). Use of HRT was associated with a non-significant increase in ET on scanning (average ET: no HRT 3.9 mm, HRT 5.8 mm, $p=0.23$) and patients were no more likely to have endometrial or endocervical pathology if using HRT.

Of the 57 peri- and pre-menopausal patients the ultrasound/biopsy and hysteroscopy/biopsy diagnoses were concordant in 52 (91%). There were 50 (87%) cases with a normal cavity, atrophy or small fibroids not causing significant distortion of the cavity, one (2%) case of benign hyperplasia and one (2%) endometrial polyp.

Two further cases of endocervical polyps (both with ET >10 mm), one (2%) sub-septate uterus and one (2%) endometrial polyp (ET 12 mm) were diagnosed with hysteroscopy but not with ultrasound and one (2%) case of suspected neoplasm on ultrasound (but not on biopsy) was found to have a benign fibroid at hysteroscopy (Table II). No endometrial or endocervical pathology was detected in any pre- or perimenopausal patient with an ET of less than 11 mm. However, in postmenopausal patients with an ET of 5 mm or less one patient had a small endometrial polyp noted at hysteroscopy.

In total, the diagnoses were concordant in 87 (89%) cases. Five cases of endocervical and four cases of endometrial polyps were noted at hysteroscopy but not at ultrasound/biopsy. If hysteroscopy/biopsy is taken as the gold standard the overall sensitivity of transvaginal scanning combined with biopsy is 75% for endometrial pathology with a specificity of 90% (positive predictive value 40%, negative predictive value

Table II

Comparison of hysteroscopy/biopsy and transvaginal scanning/biopsy diagnoses in pre- and perimenopausal patients

<i>Hysteroscopy/biopsy diagnosis</i>	<i>Ultrasound/biopsy diagnosis concordant</i>	<i>Ultrasound/biopsy diagnosis discordant</i>
Normal	40	0
Fibroids	9	1 suspected neoplasm
Endometrial polyp	1	1 normal uterus
Endocervical polyp	0	2 normal uterus
Huperplasia	1	0
Septum	0	1 normal uterus
Atrophy	1	0

98%). When a cut-off value of 5 mm for ET in post-menopausal women not taking HRT is taken, vaginal ultrasound/biopsy achieved a sensitivity of 100%. The 10 mm ET cut off for pre-, peri- and postmenopausal women taking HRT, has a lower sensitivity, however, the positive predictive value is increased (i.e. when pathology was diagnosed, it was more often present).

DISCUSSION

This is the first prospective comparison of transvaginal ultrasound with biopsy versus outpatient hysteroscopy with biopsy in a patient population with both pre- and postmenopausal patients. A single operator who had considerable experience in each technique performed all of the procedures. The subject body constituted 100 consecutive referrals from seven gynaecologists: the decision to refer was taken by the clinicians on an individual basis and no specific criteria were set. The patients included were those whom the referring gynaecologists felt were likely to have pathology and to require a more thorough evaluation than could be offered by ultrasound and biopsy alone. As the purpose of this study was to develop a nomogram for evaluation of patients with abnormal pre- or postmenopausal bleeding, we feel that this enhanced the power of the study by including only those likely to have pathology.

In the literature to date, there have been numerous reports examining the role of ultrasound or hysteroscopy but without biopsy. Biopsy is likely to miss polyps and fibroids whilst ultrasound is

likely to identify intramural fibroids but be unable to differentiate between endometrial hyperplasia, endometrial polyps and early cancers. Hysteroscopy can identify discrete lesions but does not give a histological diagnosis. Therefore, any effective clinical service is likely to require all three methods of investigation. However, hysteroscopy is expensive in comparison and requires considerable operator skill.

In this study, the evaluation of the post-menopausal group suggests that if the endometrium is thin (<5 mm) the likely diagnosis is atrophy and this can be confirmed by endometrial sampling although caution must be exercised when an inadequate biopsy is reported.¹⁷ If atrophy is diagnosed, oestrogen replacement may alleviate symptoms. If bleeding recurs hysteroscopy should be performed. By contrast, if the ET is >5 mm then formal hysteroscopic evaluation is indicated.

In the group of postmenopausal women using HRT, an ET of more than 10 mm (even with a normal biopsy) is an indication for hysteroscopy. In women with normal biopsy and ET 10 mm or less a period of observation is acceptable but if further bleeding occurs, referral for hysteroscopy should be made. The advantage of the raise in limit for those taking HRT is that the number of unnecessary hysteroscopies will be decreased.

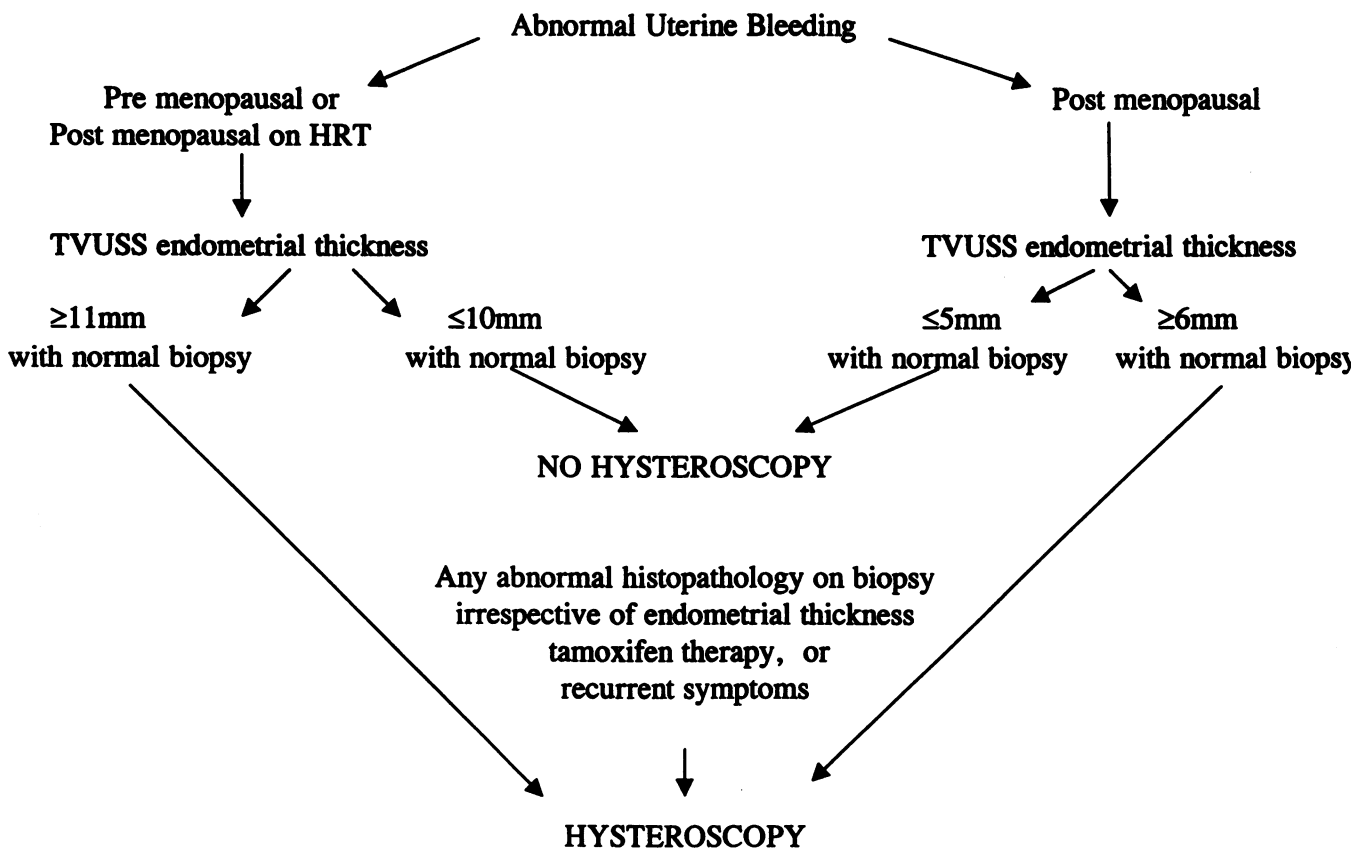
For pre-menopausal patients changes in endometrial thickness throughout the menstrual cycle may cause confusion. Although ET commonly exceeds 10 mm in normal uteri,

because of the difficulty in differentiating between polyps, hyperplasia and fibroid polyps, we believe that ET greater than 10 mm should lead to referral for hysteroscopy in women with abnormal uterine bleeding. If, at ultrasound, the cavity appears distorted by submucosal fibroids, the only indication for hysteroscopy is to assess their suitability for hysteroscopic resection.

Our findings largely support those previously reported.¹⁸ For example, Guidot¹² and Schei⁴ have shown that micro-curettage alone is not a safe alternative to hysteroscopy as polyps are often missed and may contain focal hyperplastic or malignant change. We have refined this further to demonstrate that, in combination with ultrasound and with the provisos given above, hysteroscopy can often be safely avoided. However, an abnormal histological report on a biopsy specimen in a woman of any age, or persistent abnormal uterine bleeding, should prompt urgent referral for hysteroscopy.

Whilst Naegele *et al*⁴ suggested that outpatient hysteroscopy may become a routine procedure (as ultrasound presently is in some units) the financial implications of such a shift in clinical practice would be huge and a large number of unnecessary procedures would be performed. The guidelines of both the American and Royal Colleges of Obstetricians and Gynaecologists are less radical in their enthusiasm for hysteroscopy and suggest appropriate patient selection. Guidelines for such patient selection have yet to be drawn up at a national level and we believe that a significant number of procedures are being performed without adequate indication. Hysteroscopy is well tolerated by women and is an important adjunct to clinical examination, transvaginal ultrasound scanning and endometrial biopsy. However, as the most invasive of the procedures it should be reserved for those cases where it is clearly indicated rather than applied to all cases.

Nomogram



REFERENCES

1. Koss L G. Detection of occult endometrial carcinoma. *J Cell Biochem* 1995; Suppl, **23**: 165-73.
2. Wagman H. Post menopausal bleeding. In Bailliere's, *Clin Obstet Gynaecol* 1998; Vol 2 No. 2: 355-62.
3. Royal College of Obstetricians and Gynaecologists. Guidelines No. 3, April 1994.
4. Schei B, Bang TF, Halgunset J, Haugen O A, Tlaarsat I, Onsrud M. Microcurettage sampling of the endometrium for histopathological examination: simpler but not safe? Comparison of endometrial histopathology in samples obtained by a disposable mechanical curette and by traditional curettage. *Acta Obstet Gynecol Scand* 1994; **73**: 497-501.
5. Karlsson B, Granberg S, Wikland M *et al*. Transvaginal ultrasonography of the endometrium in women with postmenopausal bleeding: a Nordic multicentre study. *Am J Obstet Gynecol* 1995; **172**: 1488-94.
6. Mortakis A K, Mavrelou K. Transvaginal ultrasonography and hysteroscopy in the diagnosis of endometrial abnormalities. *J Am Assoc Gynecol Laparosc* 1997; **4**: 449-52.
7. Bombieri L, Hogston P. Endometrial carcinoma with an endometrial thickness of 3.2mm on vaginal ultrasonography. *J Obstet Gynecol* 1995; **15**: 421.
8. Dorum A, Kristensen G B, Langebrette A *et al*. Evaluation of endometrial thickness measured by endovaginal ultrasound in women with postmenopausal bleeding. *Acta Obstet Gynecol Scand* 1993; **72**: 116-9.
9. Perrot N, Frey I, Bigot J M. Sonohysterography: technique and indications. *J Radiol* 1996; **77**: 687-90.
10. Cohen J R, Luxman D, Sagi J, Yovel I, Wolman I, David M P. Sonohysterography for the diagnosis of endometrial thickening in postmenopausal bleeding – a preliminary study. *J Am Assoc Gynecol Laparosc* 1994; **1** (4, part2): S7-8.
11. Rodriguez G C, Yaqub N, King M E. A comparison of the Pipelle device and the Vabra aspirator as measured by endometrial denudation in hysterectomy specimens: the Pipelle device samples significantly less of the endometrial surface than the Vabra aspirator. *Am J Obstet Gynecol* 1993; **168**: 55-9.
12. Guido R S, Kanbour-Shakir A, Rulin M C, Christopherson W A. Pipelle endometrial sampling. Sensitivity in the detection of endometrial cancer. *J Reprod Med* 1995; **40**: 553-5.
13. Ben-Baruch G, Seidman D S, Schiff E, Moran O, Menczer J. Outpatient endometrial sampling with the Pipelle curette. *Gynecol Obstet Invest* 1994; **37**: 260-2.
14. Naegele F, O'Connor E T, Davies A, Badawy A, Mohamed H, Magos A. 2,500 outpatient diagnostic hysteroscopies. *Obstetrics and Gynaecology* 1996; **88**: 87-92.
15. Kremer C, Barik S, Duffy S. Flexible outpatient hysteroscopy without anaesthesia: a safe, successful and well tolerated procedure. *Br J Obstet Gynaecol* 1998; **105**: 672-6.
16. Anonymous ACOG Technical Bulletin number 191-April 1994. *Int J Gynaecol Obstet* 1994; **45**: 175-80.
17. Farrell T, Jones N, Owen P, Baird A. The significance of an 'insufficient' Pipelle sample in the investigation of post-menopausal bleeding. *Acta Obstet Gynecol Scand* 1999; **78**: 810-2.
18. Vercellini P, Cortesi I, Oldani S, Moschetta M, De Giorgi O, Crosignani P G. The role of transvaginal ultrasonography and outpatient diagnostic hysteroscopy in the evaluation of patients with menorrhagia. *Hum Reprod* 1997; **12**: 1768-71.