

[ ORIGINAL ARTICLE ]

# Two-year Follow-up Results of Magnetic Resonance Imaging-guided Focused Ultrasound Unilateral Thalamotomy for Medication-refractory Essential Tremor

Hisashi Ito<sup>1</sup>, Kazuaki Yamamoto<sup>2</sup>, Shigeru Fukutake<sup>1</sup>, Takashi Odo<sup>1</sup> and Tetsumasa Kamei<sup>1</sup>

## Abstract:

**Objective** To investigate the long-term efficacy and safety of magnetic resonance imaging-guided focused ultrasound (MRgFUS) unilateral ventral intermediate nucleus (Vim) thalamotomy for medication-refractory essential tremor (ET).

**Methods** We performed MRgFUS left-sided Vim thalamotomy for 10 medication-refractory ET patients (8 men and 2 women, aged 67.1±17.5 years, all right-handed). We followed them for 2 years using the clinical rating scale for tremor (CRST) and the quality of life in essential tremor questionnaire (QUEST).

**Results** Right-handed tremor improved immediately after the left Vim thalamotomy in all patients. The tremor became re-exacerbated in 2 patients by 6 months after treatment; however, an approximately 60% decrease in the average CRST score of the right hand persisted until 2 years. On the other hand, the average CRST score of the left hand and the average QUEST score showed no improvement. Headache was the most common adverse event during the sonication (8 patients), followed by a floating sensation (4 patients). On the other hand, sensory disturbances (4 patients) and gait instability (4 patients) were observed after the treatment, but most of them were mild and transient. There were no delayed adverse events.

**Conclusion** MRgFUS unilateral Vim thalamotomy could be adopted as one of the therapeutic options for intractable ET. Further improvement of tremor in the targeted hand or contralateral Vim thalamotomy may be necessary to improve the quality of life.

**Key words:** essential tremor, MRI-guided focused ultrasound, thalamotomy, ventral intermediate nucleus

(Intern Med 59: 2481-2483, 2020)

(DOI: 10.2169/internalmedicine.4360-19)

## Introduction

Essential tremor (ET) is one of the most common movement disorders in adults, with an overall prevalence of 2.5% to 10.0%. Medication is a first-line treatment; however, its efficacy is limited (1, 2). Neurosurgical or radiological interventions targeting the ventral intermediate nucleus (Vim) can be considered for medication-refractory ET patients and they have demonstrated proven clinical efficacy (3, 4).

Transcranial magnetic resonance imaging (MRI)-guided focused ultrasound (MRgFUS) is a new modality facilitating intracranial focal ablation. It has been applied for several

neurological and psychological disorders including ET (5); however, studies describing the long-term outcomes of patients following MRgFUS Vim thalamotomy for medically intractable ET are limited (6-9). In this article, we report the clinical efficacy and safety 2 years after MRgFUS unilateral Vim thalamotomy for medication-refractory ET.

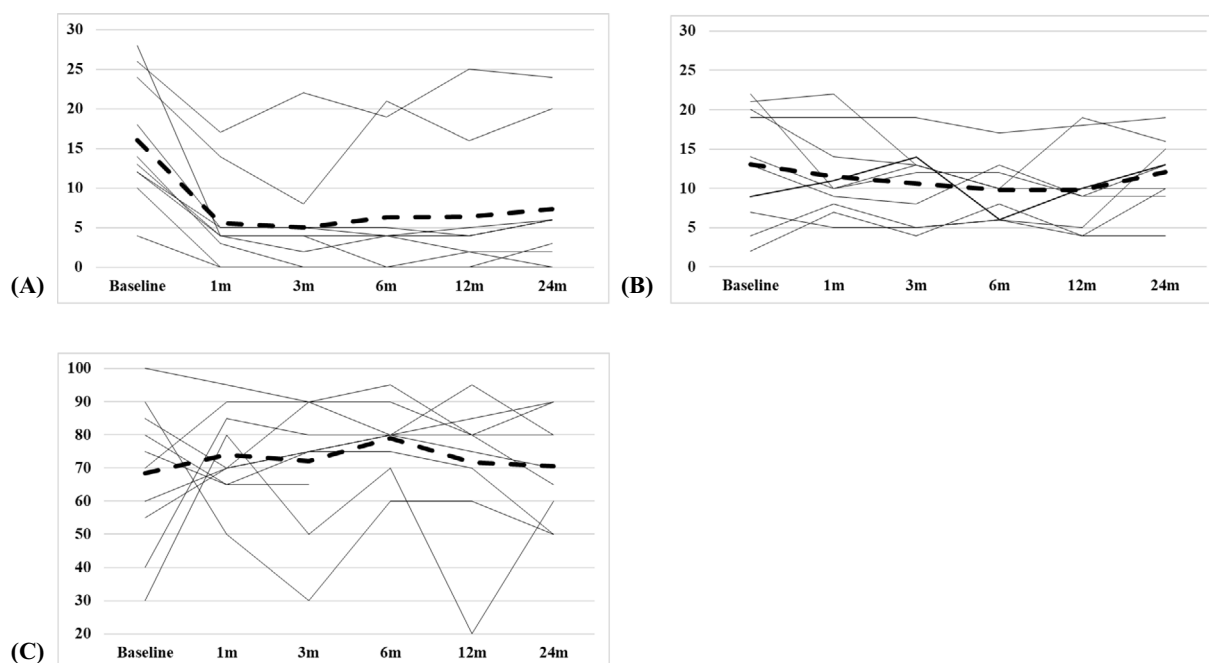
## Materials and Methods

This was a hospital-based, prospective, open-labeled study. We enrolled 10 patients with medication-refractory ET (8 men and 2 women, aged 67.1±17.5 years, right-handed) diagnosed by at least 2 movement disorder neurolo-

<sup>1</sup>Department of Neurology, Shonan Fujisawa Tokushukai Hospital, Japan and <sup>2</sup>Department of Neurosurgery, Tokyo Women's Medical University, Japan

Received: December 20, 2019; Accepted: May 12, 2020; Advance Publication by J-STAGE: July 7, 2020

Correspondence to Dr. Hisashi Ito, hisashi.ito@tokushukai.jp



**Figure.** (A) Hand subscore of CRST of treated hand. (B) Hand subscore of CRST of non-treated hand. (C) GIS of QUEST. The improvement of the average CRST score of the right hand persisted until 2 years; however, both the average CRST score of the left hand and the average GIS of QUEST score showed no improvement (Dotted-lines are the average). CRST: clinical rating scale for tremor, GIS: global impression score, QUEST: quality of life in essential tremor questionnaire

gists (H.I., S.F., and T.K.). We defined medication-refractory tremor as persistent disabling tremor despite at least two therapeutic medications including propranolol, primidone, and benzodiazepine such as clonazepam. All patients desired left-sided Vim thalamotomy because all of them were right-handed. They received the standard clinical and imaging workup as part of the study's baseline requirements and all were eligible for inclusion: between 18 and 80 years of age and had a moderate to severe postural or kinetic hand tremor defined by a score of  $\geq 2$  based on the clinical rating scale for tremor (CRST) (10). The exclusion criteria included a contraindication for MRI, patients with psychiatric disorder, dementia, current substance abuse, Parkinson's syndrome, and a low skull density ratio (SDR, less than 0.30). SDR is the mean value of the ratio of Hounsfield units of marrow and cortical bone and its value correlates with the target temperature (11). We planned MRgFUS left-sided Vim thalamotomy with 1.5-Tesla MRI Signa HDx (GE Healthcare, Milwaukee, USA) using an ExAblate Neuro<sup>®</sup> (InSightec, Tirat Carmel, Israel) from March 2017 at Shonan Fujisawa Tokushukai Hospital (research project: H.I., T.K.; patient managements: H.I., S.F., T.O.; Exablate Neuro 4000 operation: K.Y., H.I.). The details of the procedure have been described previously (6, 7). We evaluated the severity of the tremor with the hand subscore of CRST (ranging from 0 to 32, with higher scores indicating more severe tremor), quality of life with the global impression score (GIS) of quality of life in essential tremor questionnaire (QUEST) (ranging from 0 to 100%, with higher scores indicating better health) (12), and adverse events until 2 years.

All patients provided their written informed consent in accordance with the Declaration of Helsinki before treatment. This study received full ethics approval from the Review Board of Tokushukai Medical Alliance for ET patients suffering from medication-refractory tremor and who refused other procedures involving radiofrequency (RF) Vim thalamotomy, Vim-deep brain stimulation (DBS), or radiological Vim thalamotomy with a gamma knife (GK) (January 2017: TGE00770-008).

## Results

Right-handed tremor improved immediately after left-sided Vim thalamotomy. Although one patient was lost to the follow-up due to accidental vehicle death, others were analyzed in each follow-up period. Tremor became re-exacerbated in 2 patients by 6 months. The target volume of one of these patients was smallest ( $42.5 \text{ mm}^3$ ; the average was  $129.7 \pm 53.1 \text{ mm}^3$ ). On the other hand, the misalignment of the target was suggested in the other patient as the target volume was above average ( $137.0 \text{ mm}^3$ ) (13).

The average CRST score of the right hand decreased by approximately 60% from the baseline and this score decline persisted until 2 years (-65.2% at 1 month, -60.9% at 6 months, -60.2% at 1 year, and -54.0% at 2 years) (Figure A). We observed no improvement in the average CRST score of the left hand (Figure B). In addition, the average GIS of QUEST score did not improve after 2 years (Figure C). During the sonication, headache (8 patients) and floating sensation (4 patients) were observed. Sensory dis-

turbances in the right face and fingers (4 patients) and instability during walking (4 patients) were observed after the treatment. Most of them were mild and transient; however, an improvement in the sensory impairment required 3 to 6 months in 2 patients. We observed no delayed adverse events.

## Discussion

The characteristics of ET are a postural and kinetic tremor typically affecting the hands, which could interfere with the patient's functional activities in daily life and socialization. Propranolol and primidone are first-line medications; however, as many as 50% of all patients fail to gain sufficient efficacy or cannot tolerate these medications (2). Stereotactic RF Vim thalamotomy, Vim-DBS, and GK Vim thalamotomy have proven to be highly effective for medication-refractory ET (3, 4). However, the former two interventions involve surgical invasiveness and a risk of brain hemorrhage, infection, and hardware-related complications. The latter needs a long duration to achieve a therapeutic effect and involves radiation exposure (14).

Transcranial MRgFUS is a novel technology to enable intracranial focal ablation. It is characterized by minimum invasiveness and an immediate therapeutic effect; however, previous reports on the long-term outcome of MRgFUS unilateral Vim thalamotomy for intractable ET are limited. Elias et al. reported that the improvement of tremor in 15 intractable ET patients persisted until 1 year later and most of the adverse events were transient (6). In addition, a multicenter study conducting evaluations up to 1 year (7), a multicenter study up to 2 years (8), and a single-center study up to 4 years (9) showed a sustained improvement of the treated hand tremor.

Our study showed that the improvement of treated hand tremor in 7 patients lasted for 2 years; however, we could not confirm the improvement of the GIS of QUEST. Although the tendency of improvement of treated hand tremor was clear, complete disappearance was limited to only 3 patients and the improvement of non-treated hand tremor was poor, which might lead to no improvement in GIS. Therefore, it is important to modify the procedure to achieve a greater improvement of tremor in the targeted hand or consider contralateral Vim thalamotomy.

Regarding adverse events, headache, nausea, vomiting, and a floating sensation are common during sonication. On the other hand, paresthesia and instability during walking may occur after the procedure. Serious, persistent, or delayed adverse events including large hematoma have not been reported (6-9). As in previous reports, all adverse events resolved within 6 months of treatment and no delayed adverse events occurred in this study. These results indicate the safety of MRgFUS Vim thalamotomy for ET.

One limitation of this study is the small number of patients; however, the long-term efficacy and safety of MRgFUS unilateral Vim thalamotomy for intractable ET was suggested. Further investigations to assess the longer-term outcomes and identify ways to promote the therapeutic effects are necessary to improve the patients' quality of life.

**The authors state that they have no Conflict of Interest (COI).**

## Acknowledgement

We thank Dr. Takaomi Taira (Department of Neurosurgery, Tokyo Women's Medical University), Dr. Toshio Yamaguchi (Research Institute of Diagnostic Imaging, Shin-Yurigaoka General Hospital) for their technical support in performing MRgFUS Vim thalamotomy.

## References

1. Elble RJ. Diagnostic criteria for essential tremor and differential diagnosis. *Neurology* **54**: S2-S6, 2000.
2. Diaz NL, Louis ED. Survey of medication usage patterns among essential tremor patients: movement disorder specialists vs. general neurologists. *Parkinsonism Relat Disord* **16**: 604-607, 2010.
3. Schuurman PR, Bosch DA, Merkus MP, Speelman JD. Long-term follow-up of thalamic stimulation versus thalamotomy for tremor suppression. *Mov Disord* **23**: 1146-1153, 2008.
4. Niranjana A, Raju SS, Kooshkabi A, Monaco E 3rd, Flickinger JC, Lunsford LD. Stereotactic radiosurgery for essential tremor: Retrospective analysis of a 19-year experience. *Mov Disord* **32**: 769-777, 2017.
5. Weintraub D, Elias WJ. The emerging role of transcranial magnetic resonance imaging-guided focused ultrasound in functional neurosurgery. *Mov Disord* **32**: 20-27, 2017.
6. Elias WJ, Huss D, Voss T, et al. A pilot study of focused ultrasound thalamotomy for essential tremor. *N Engl J Med* **369**: 640-648, 2013.
7. Elias WJ, Lipsman N, Ondo WG, et al. A randomized trial of focused ultrasound thalamotomy for essential tremor. *N Engl J Med* **375**: 730-739, 2016.
8. Chang JW, Chang KP, Lipsman N, et al. A prospective trial of magnetic resonance-guided focused ultrasound thalamotomy for essential tremor: results at the 2-year follow-up. *Ann Neurol* **83**: 107-114, 2018.
9. Park YS, Jung NY, Na YC, Chang JW. Four-year follow-up results of magnetic resonance-guided focused ultrasound thalamotomy for essential tremor. *Mov Disord* **34**: 727-734, 2019.
10. Sweet RD, Blumberg J, Lee JE, McDowell FH. Propranolol treatment of essential tremor. *Neurology* **24**: 64-67, 1974.
11. Chang WS, Jung HH, Zadicario E, et al. Factors associated with successful magnetic resonance-guided focused ultrasound treatment: efficiency of acoustic energy delivery through the skull. *J Neurosurg* **124**: 411-416, 2016.
12. Tröster AI, Pahwa R, Fields JA, Tanner CM, Lyons KE. Quality of life in essential tremor questionnaire (QUEST): development and initial validation. *Parkinsonism Relat Disord* **11**: 367-373, 2005.
13. Ito H, Yamamoto K, Fukutake S, Kamei T. MRI-guided focused ultrasound unilateral thalamotomy for 10 essential tremor patients -A short-term analysis of effectiveness and safety-. *Shinkei Chiryō Gaku (Neurol Therap)* **35**: 567-570, 2018 (in Japanese, Abstract in English).
14. Siderowf A, Gollump SM, Stern MB, Baltuch GH, Riina HA. Emergence of complex, involuntary movements after gamma knife radiosurgery for essential tremor. *Mov Disord* **16**: 965-967, 2001.

The Internal Medicine is an Open Access journal distributed under the Creative Commons Attribution-NonCommercial-NoDerivatives 4.0 International License. To view the details of this license, please visit (<https://creativecommons.org/licenses/by-nc-nd/4.0/>).