



## Successful outcome of second allogeneic bone marrow transplantation for blastic plasmacytoid dendritic cell neoplasm with *MYC* locus rearrangement



Takeharu Kato<sup>a</sup>, Hidehiro Itonaga<sup>b,\*</sup>, Jun Taguchi<sup>c</sup>, Junya Makiyama<sup>a,d</sup>, Machiko Fujioka<sup>b</sup>, Masataka Taguchi<sup>b</sup>, Makiko Horai<sup>b</sup>, Yasushi Sawayama<sup>b</sup>, Daisuke Niino<sup>e</sup>, Yoshitaka Imaizumi<sup>i</sup>, Tomoko Hata<sup>i</sup>, Shinichiro Yoshida<sup>a</sup>, Kana Sakamoto<sup>f,g</sup>, Kengo Takeuchi<sup>f,g</sup>, Koichi Ohshima<sup>h</sup>, Yasushi Miyazaki<sup>b,i</sup>

<sup>a</sup> Department of Hematology, National Hospital Organization Nagasaki Medical Center, Nagasaki, Japan

<sup>b</sup> Department of Hematology, Nagasaki University Hospital, Nagasaki, Japan

<sup>c</sup> Department of Hematology, Japanese Red Cross Nagasaki Genbaku Hospital, Nagasaki, Japan

<sup>d</sup> Department of Hematology/Oncology, Research Hospital, The Institute of Medical Science, The University of Tokyo, Tokyo, Japan

<sup>e</sup> Department of Pathology, Nagasaki University Hospital, Nagasaki, Japan

<sup>f</sup> Pathology Project for Molecular Targets, The Cancer Institute, Japanese Foundation for Cancer Research, Tokyo, Japan

<sup>g</sup> Division of Pathology, The Cancer Institute, Japanese Foundation for Cancer Research, Tokyo, Japan

<sup>h</sup> Department of Pathology, School of Medicine, Kurume University, Fukuoka, Japan

<sup>i</sup> Department of Hematology, Atomic Bomb Disease and Hibakusha Medicine Unit, Atomic Bomb Disease Institute, Nagasaki University, Nagasaki, Japan

### ARTICLE INFO

#### Keywords:

Blastic plasmacytoid dendritic cell neoplasm  
Allogeneic hematopoietic stem cell transplantation  
Donor change  
*MYC* rearrangement

### ABSTRACT

A 62-year-old male was diagnosed with blastic plasmacytoid dendritic cell neoplasm (BPDCN) with a *MYC* rearrangement. Four months after the first unrelated bone marrow transplantation (BMT), he developed the relapsed BPDCN. After the achievement of partial remission following re-induction therapy, he underwent a second BMT from another unrelated donor, and experienced complete remission with grade II acute graft-versus-host disease and moderate chronic graft-versus-host disease. He remains alive in complete remission more than 71 months after the second BMT. These results suggested that donor change at the second transplantation may represent a considerable therapeutic option for patients with relapsed BPDCN.

### 1. Introduction

Blastic plasmacytoid dendritic cell neoplasm (BPDCN) is a highly aggressive malignant disorder derived from the precursors of plasmacytoid dendritic cells with a high frequency of cutaneous and bone marrow involvement [1,2,7]. Patients with BPDCN have a poor prognosis; the median overall survival after chemotherapy has been 7.1 to 11.0 months [1,2]. Previous reports showed that allogeneic hematopoietic stem cell transplantation (allo-HSCT) or autologous-HSCT are promising modalities that provide durable remission for BPDCN patients, with median overall survival after transplantation ranging from 22.7 to 53.5 months [1,3,4]. Therefore, allo-HSCT and autologous-HSCT should be considered as a therapeutic option for eligible patients.

However, the relapse rate after allo-HSCT is approximately 30% [3,4], and relapsed patients have an extremely poor prognosis. Treatment options for the relapsed disease after allo-HSCT include withdrawal of immunosuppressants, donor lymphocyte infusion, and

chemotherapy [5], but there are few reports describing the feasibility of a second allo-HSCT.

We here report a patient with BPDCN who achieved long-term remission after a second allo-HSCT from an unrelated donor using reduced-intensity conditioning (RIC).

### 2. Case report

A 62-year-old male presented with a cutaneous tumor on the left arm and lymphadenopathy in the left axilla. Skin biopsy showed a diffuse infiltration of tumor cells with immunoblastoid cytology [6]. The cells were positive for CD4, CD123, TCL1, and *MYC* and partly positive for CD56 (Fig. 1A-G); but negative for CD3, CD20, CD79a, terminal deoxynucleotidyl transferase (TdT), myeloperoxidase (MPO), CD34, and the Epstein-Barr encoding region. In split fluorescence *in situ* hybridization (FISH) assay [10], tumor cells were positive for 8q24 (*MYC* locus) rearrangement but negative for *SUPT3H* and *MYB*

\* Corresponding author.

E-mail address: [itonaga-ngs@umin.ac.jp](mailto:itonaga-ngs@umin.ac.jp) (H. Itonaga).

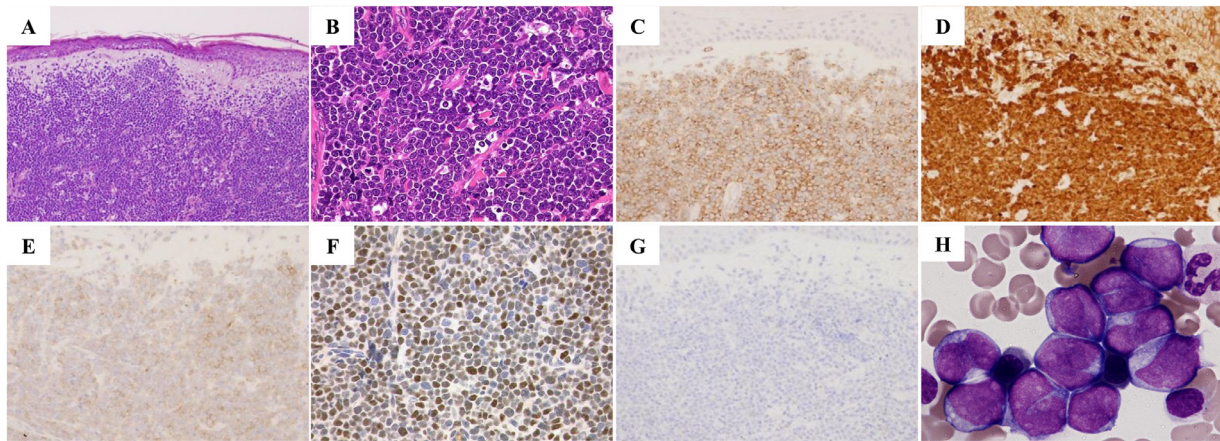
<https://doi.org/10.1016/j.lrr.2019.04.005>

Received 8 October 2018; Received in revised form 9 April 2019; Accepted 21 April 2019

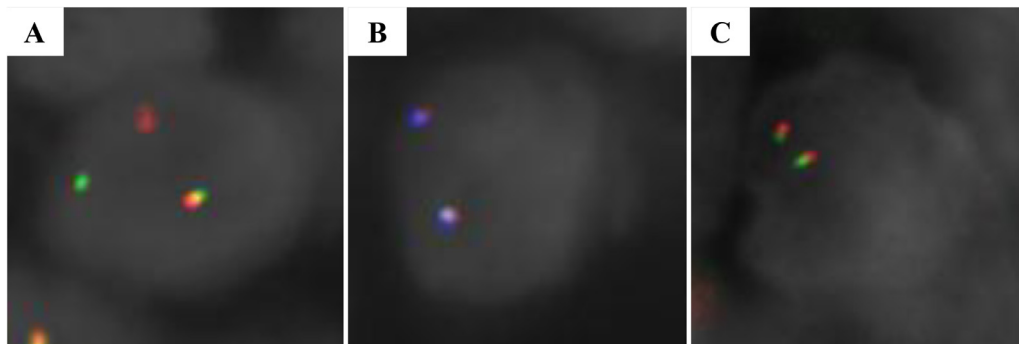
Available online 22 April 2019

2213-0489/© 2019 The Authors. Published by Elsevier Ltd. This is an open access article under the CC BY-NC-ND license

(<http://creativecommons.org/licenses/by-nc-nd/4.0/>).



**Fig. 1.** Pathological features of a cutaneous tumor and microscopic features of blastoid cells in bone marrow. Skin biopsy showed diffuse infiltration of tumor cells with immunoblastoid cytology in the dermis (H-E staining: A,  $\times 100$ ; B,  $\times 400$ ). Immunohistochemically, the infiltrating immunoblastoid cells were positive for CD4 (C,  $\times 200$ ), CD123 (D,  $\times 200$ ), TCL1 (E,  $\times 200$ ), and MYC (F,  $\times 400$ ) and partly positive for CD56 (G,  $\times 200$ ). Bone marrow aspiration showed the infiltration of medium-sized blastoid cells (May-Giemsa staining: H,  $\times 1000$ ).



**Fig. 2.** Split fluorescence *in situ* hybridization assessment of a cutaneous tumor. Tumor cells were positive for an 8q24 (*MYC* locus) rearrangement using Vysis LSI IGH-MAF dual colour dual fusion translocation probe (A), but negative for *SUPT3H* (B) and *MYB* rearrangements (C).

rearrangements (Fig. 2). The present patient was diagnosed with BPDCN according to the diagnostic criteria proposed by Julia et al. [7]. Peripheral blood yielded a hemoglobin level of 14.4 g/dL, a leukocyte count of  $6.6 \times 10^3/\mu\text{L}$  and a platelet count of  $13.5 \times 10^4/\mu\text{L}$ . Bone marrow examination showed 92% blast cells (Fig. 1H), of which MPO activity was not detected by the diaminobenzidine method. Flow cytometry analysis revealed that the leukemic cells were positive for CD4, CD33, CD123, interleukin-3 receptor, human leukocyte antigen (HLA)-DR, and CD45RA, partly positive for CD56 and negative for TdT and cytoplasmic MPO. G-banding analysis showed del(13)(q12q22) in 7 out of 16 metaphase cells. Rearrangements of the T cell receptor gamma-chain gene by polymerase chain reaction (PCR) analysis and immunoglobulin heavy-chain genes by Southern blotting analysis were not detected. These findings confirmed bone marrow involvement of BPDCN. The induction chemotherapy was initiated with daunorubicin 50 mg/m<sup>2</sup> daily for 5 days and cytarabine 100 mg/m<sup>2</sup> daily for 7 days, resulting in complete hematological remission (CR). Subsequently, he received 2 courses of consolidation chemotherapy. The patient did not have a related donor who was serologically HLA-matched. Thus, he was transplanted with unrelated bone marrow from a male donor (total nucleated cell dose,  $3.4 \times 10^8$  cells/kg; genotypically matched for HLA-A, -B, -Cw, and -DR1) from the Japan Marrow Donor Program using a RIC regimen with total body irradiation (TBI) 2 Gy / 1 fraction, fludarabine (Flu) 125 mg/m<sup>2</sup>, and melphalan (Mel) 80 mg/m<sup>2</sup>. A combination of tacrolimus (Tac) and short-term methotrexate (sMTX) was used as graft-versus-host disease (GVHD) prophylaxis. Neutrophil engraftment (absolute neutrophil count of at least  $>0.5 \times 10^9/\text{L}$  for 3 consecutive points) and platelet recovery (platelet count of

$>50 \times 10^9/\text{L}$  without transfusion for 3 consecutive points) were obtained on days +15 and +30 after transplantation, respectively. He maintained CR without any symptoms of GVHD.

Four months after the initial transplantation, he developed two cutaneous tumors on his legs. Skin biopsy showed the infiltration of tumor cells but bone marrow aspiration showed no evidence of relapse, which confirmed extramedullary relapse of BPDCN. Despite the cessation of Tac, lymphadenopathy in the left inguinal was noted. At day 180 after allo-HSCT, bone marrow examination revealed 10% leukemic cells, and short tandem repeat DNA analysis showed 5.5% recipient-type cells at day 180, indicating a progression to hematological relapse of BPDCN. He achieved partial remission after 1 course of re-induction chemotherapy with daily cyclophosphamide 600 mg/m<sup>2</sup> on day 1, vincristine 1.3 mg/m<sup>2</sup> on days 1, 8, 15, 22, doxorubicin 20 mg/m<sup>2</sup> on days 1 to 3, prednisolone 60 mg/body po on days 1 to 7 (then tapered for 28 days) and L-asparaginase 2000 IU/m<sup>2</sup> div on days 11, 13, 18, 21. The patient was transplanted with HLA-matched unrelated male bone marrow (total nucleated cell dose,  $2.3 \times 10^8$  cells/kg; genotypically matched for HLA-A, -B, -Cw and -DR1) followed by a RIC regimen with Flu 30 mg/m<sup>2</sup> daily for 5 days, intravenous busulfan (BU) 3.2 mg/kg daily for 2 days, and TBI 2 Gy / 1 fraction. Tac and sMTX were administered as prophylaxis against GVHD. Ten days after the second transplantation (before neutrophil engraftment), he presented with stridor due to severe laryngeal irritation, and underwent mechanical ventilation. Neutrophil engraftment and platelet recovery were achieved on days +21 and +127 after the second transplantation, respectively. He achieved the second CR of BPDCN with complete second-donor chimerism. He developed grade II acute GVHD with stage

2 skin involvement 48 days after transplantation, but did not require additional immunosuppressive treatment, such as systemic administration of corticosteroid. He presented lichen planus-like features in the skin and oral mucosa due to moderate chronic GVHD. He started anti-androgen therapy for localized prostate cancer at day +1525. During anti-androgen therapy, he did not experience any symptom of relapse disease of BPDCN. Furthermore, chronic GVHD in oral mucosa and skin persisted without progression in any other organ, and a lymphocyte count was maintained between  $3.01$  and  $4.41 \times 10^9/L$ . The withdrawal of immunosuppressants was performed on day +1748. He was alive without any symptom of relapse more than 71 months after the second allo-HSCT.

### 3. Discussion

We treated a BPDCN patient who was maintained in CR for more than 5 years after a second allo-HSCT. Use of a new donor for the second allo-HSCT was reported to be a valid option in patients who developed relapse of acute leukemia after the first allo-HSCT [8]. To the best of our knowledge, this is the first report of the feasibility of using a different donor for a second allo-HSCT for a relapsed BPDCN patient.

Importantly, the second allo-HSCT provided long-term remission for relapsed BPDCN after the first unrelated allo-HSCT in the present case. One interesting finding was that no symptom of GVHD was observed after the first allo-HSCT, but acute and chronic GVHD developed after the second allo-HSCT. Based on the facts previously reported about graft-versus-leukemia effect together with the occurrence of GVHD for several other hematological malignancies [9,10], we speculate that the potent graft-versus-tumor effect for BPDCN was enhanced by the development of GVHD following the second allo-HSCT. Thus, it is possible that avoidance of additional treatment for active GVHD preserved the potential graft-versus-BPDCN effect in the present case. In this regard, donor change at the second allo-HSCT would be a considerable option for relapsed BPDCN patients without a history of GVHD after their first allo-HSCT.

The present case suggested that the application of a second allo-HSCT should be considered for BPDCN patients if the patient is eligible and a suitable donor is available. For such patients, a RIC regimen would be suitable in order to minimize life-threatening complications. Aoki et al. reported promising results of allo-HSCT using a RIC regimen for chemosensitive BPDCN [4]. However, our patient experienced severe laryngeal irritation early after the second allo-HSCT. Thus, careful management is needed for patients who undergo a second allo-HSCT regardless of the intensity of the conditioning regimen.

A recent retrospective study showed that 8q24 rearrangement and subsequent MYC expression in BPDCN correlated with a poor prognosis [6], and a standard therapeutic strategy is not yet established. Therefore, it would be of interest to determine whether allo-HSCT utilizing a graft-versus-tumor effect could overcome the negative impact of 8q24 rearrangement and subsequent MYC expression in BPDCN. Considering the promising experimental results of novel molecular-targeting agents for BPDCN with MYC rearrangement [6], the efficacy of sequential treatment with such agents and allo-HSCT using RIC should be investigated in future studies.

In summary, our results suggested that donor change at a second allo-HSCT might have a considerable therapeutic benefit for relapsed BPDCN with MYC rearrangement. Further research in a larger cohort is necessary to draw definitive conclusions.

### Conflict of interest

The authors have declared that there is no conflict of interest.

### CRedit authorship contribution statement

**Takeharu Kato:** Project administration, Investigation, Data curation, Writing - original draft. **Hidehiro Itonaga:** Project administration, Investigation, Data curation, Writing - original draft. **Jun Taguchi:** Project administration, Investigation, Data curation, Writing - original draft. **Junya Makiyama:** Project administration, Data curation, Writing - review & editing. **Machiko Fujioka:** Project administration, Data curation, Writing - review & editing. **Masataka Taguchi:** Project administration, Data curation, Writing - review & editing. **Makiko Horai:** Project administration, Data curation, Writing - review & editing. **Yasushi Sawayama:** Project administration, Data curation, Writing - review & editing. **Daisuke Niino:** Investigation, Writing - review & editing. **Yoshitaka Imaizumi:** Project administration, Data curation, Writing - review & editing. **Tomoko Hata:** Project administration, Data curation, Writing - review & editing. **Shinichiro Yoshida:** Project administration, Data curation, Writing - review & editing. **Kana Sakamoto:** Formal analysis, Investigation, Writing - review & editing. **Kengo Takeuchi:** Formal analysis, Investigation, Writing - review & editing. **Koichi Ohshima:** Investigation, Writing - review & editing. **Yasushi Miyazaki:** Project administration, Investigation, Data curation, Writing - original draft, Formal analysis, Writing - review & editing.

### Acknowledgments

The authors thank Dr. Seiji Sakata and Ms. Satoko Baba for supporting FISH analysis.

### Supplementary materials

Supplementary material associated with this article can be found, in the online version, at [doi:10.1016/j.lrr.2019.04.005](https://doi.org/10.1016/j.lrr.2019.04.005).

### References

- [1] L. Pagano, C.G. Valentini, A. Pulsoni, et al., Blastic plasmacytoid dendritic cell neoplasm with leukemic presentation: an Italian multicenter study, *Haematologica* 98 (2) (2013) 239–246.
- [2] J. Feuillard, M.-C. Jacob, F. Valensi, et al., Clinical and biologic features of CD4(+)CD56(+) malignancies, *Blood* 99 (5) (2002) 1556–1563.
- [3] D. Roos-Weil, S. Dietrich, A. Boumendil, et al., Stem cell transplantation can provide durable disease control in blastic plasmacytoid dendritic cell neoplasm: a retrospective study from the European Group for Blood and Marrow Transplantation, *Blood* 121 (3) (2013) 440–446.
- [4] T. Aoki, R. Suzuki, Y. Kuwatsuka, et al., Long-term survival following autologous and allogeneic stem cell transplantation for blastic plasmacytoid dendritic cell neoplasm, *Blood* 125 (23) (2015) 3559–3562.
- [5] S. Dietrich, M. Andrusis, U. Hegenbart, et al., Blastic plasmacytoid dendritic cell neoplasia (BPDC) in elderly patients: results of a treatment algorithm employing allogeneic stem cell transplantation with moderately reduced conditioning intensity, *Biol. Blood Marrow Transplant* 17 (8) (2011) 1250–1254.
- [6] K. Sakamoto, R. Katayama, R. Asaka, et al., Recurrent 8q24 rearrangement in blastic plasmacytoid dendritic cell neoplasm: association with immunoblastoid cytomorphology, MYC expression, and drug response, *Leukemia*, 32, 2590 (2603, 12) (2018), [http://doi.org/10.1038/s41375-018-0154-5](https://doi.org/10.1038/s41375-018-0154-5).
- [7] F. Julia, S. Dalle, G. Duru, et al., Blastic Plasmacytoid Dendritic Cell Neoplasms. Clinico-immunohistochemical Correlations in a Series of 91 Patients, *Am. J. Surg. Pathol.* 38 (5) (2014) 673–680.
- [8] M. Christopheit, O. Kuss, J. Finke, et al., Second allograft for Hematologic relapse of acute leukemia after first allogeneic stem-cell transplantation from related and unrelated donors: the role of donor change, *J. Clin. Oncol.* 31 (26) (2013) 3259–3271.
- [9] D. Valcárcel, R. Martino, D. Caballero, et al., Sustained remissions of high-risk acute myeloid leukemia and myelodysplastic syndrome after reduced intensity conditioning allogeneic hematopoietic transplantation: chronic graft-versus-host disease is the strongest factor improving survival, *J. Clin. Oncol.* 26 (4) (2008) 577–584.
- [10] H. Itonaga, M. Iwanaga, K. Aoki, et al., Impacts of graft-versus-host disease on outcomes after allogeneic hematopoietic stem cell transplantation for chronic myelomonocytic leukemia: a nationwide retrospective study, *Leuk Res* 41 (2016) 48–55.