

## CASE REPORT

# A Case of Post-trauma Dysphagia: Peculiar Swallowing Dynamics Due to Associated Laryngeal Paralysis

Takafumi Sugi, MD<sup>a</sup> Hideaki Kanazawa, MD<sup>a</sup> Ayano Takinami, SLP<sup>b</sup> Kenjiro Kunieda, MD, PhD<sup>a</sup>  
Hiroshi Yaguchi, MD, PhD<sup>c</sup> Masahiro Sugiyama, MD, PhD<sup>a</sup> Hirotatsu Takahashi, MD, PhD<sup>a</sup>  
Ichiro Fujishima, MD, PhD<sup>a</sup>

**Background:** Associated laryngeal paralysis (ALP) is defined as vagus nerve impairment combined with other lower cranial nerve paralysis. Traumatic ALP is reported infrequently. **Case:** A 72-year-old man was injured on the back of the head when a large tree fell on him; he was admitted to a general hospital, where he was diagnosed with brain concussion and Guillain-Barre syndrome (GBS). The patient developed aspiration pneumonia due to severe dysphagia. Although he underwent treatment and rehabilitation for 6 months, some disabilities persisted, and a percutaneous endoscopic gastrostomy tube was placed. Six months after the accident, the patient was transferred to our rehabilitation hospital. Videoscopic examination and videofluoroscopy revealed persistent upper esophageal sphincter (UES) opening, left dominant bilateral IX and X nerve paralysis, and left XII nerve paralysis; moreover, these examinations showed that the swallowing reflex was absent, although a bolus could pass through the UES. We suspected that the patient's condition was not GBS and performed head computed tomography and magnetic resonance imaging; these revealed a bone fracture at the skull base. Consequently, the patient's diagnosis was changed to bilateral ALP. He received swallowing rehabilitation for 2 months and could orally consume alternative nutrition. Finally, the patient was able to eat orally texture-modified foods (Food Intake LEVEL Scale level 8). **Discussion:** While post-trauma dysphagia due to bilateral ALP might be severe, patients can regain the ability to eat orally if clinicians understand the etiology of dysphagia and provide appropriate swallowing rehabilitation techniques, including patient position adjustment while eating and selection of food textures.

**Key Words:** bilateral associated laryngeal paralysis; dysphagia; head trauma; upper esophageal sphincter opening

## INTRODUCTION

Associated laryngeal paralysis (ALP) is defined as vagus nerve impairment combined with other lower cranial nerve paralysis. Most patients experience idiopathic paralysis due to infections, whereas 5% of patients experience paralysis due to trauma. Bilateral lower cranial nerve paralysis due to head trauma is rare; this injury is expected to be fatal because it leads to an inability to swallow, as well as aspiration and brain death. The patient described herein could not swallow

due to bilateral ALP caused by head trauma and persistent upper esophageal sphincter (UES) opening. However, the patient regained the ability to eat orally after undergoing appropriate swallowing rehabilitation.

## CASE

A 72-year-old man who worked as a lumberjack was hit on the back of the head by a big tree that had fallen while he was working. He was immediately admitted to a general

Received: May 26, 2019, Accepted: January 28, 2020, Published online: February 22, 2020

<sup>a</sup> Department of Rehabilitation Medicine, Hamamatsu City Rehabilitation Hospital, Shizuoka, Japan

<sup>b</sup> Department of Rehabilitation, Hamamatsu City Rehabilitation Hospital, Shizuoka, Japan

<sup>c</sup> Department of Neurology, Tokyo Jikei Medical University Kashiwa Hospital, Chiba, Japan

Correspondence: Takafumi Sugi, 1-6-1 Wago-kita, Naka-ku, Hamamatsu, Shizuoka 433-8511, Japan, E-mail: tsugi0217@me.com

Copyright © 2020 The Japanese Association of Rehabilitation Medicine

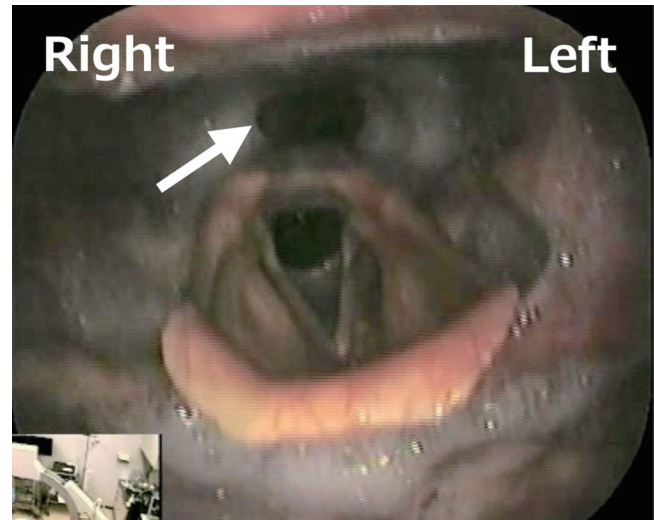


This is an open-access article distributed under the terms of the Creative Commons Attribution Non-Commercial No Derivatives (CC BY-NC-ND) 4.0 License. <http://creativecommons.org/licenses/by-nc-nd/4.0/>

hospital for brain concussion. Subsequently, the patient developed hoarseness; he reported no family history or medical history of chronic obstructive pulmonary disease. Soon after admission, the patient developed aspiration pneumonia due to severe dysphagia. He received clinical treatment and underwent neurological examination, the findings of which were suggestive of Guillain-Barre syndrome (GBS). However, the patient did not show symptoms and a clinical course consistent with GBS, such as muscle weakness or eyeball muscle paralysis. He underwent rehabilitative therapy at the previous rehabilitation hospital, and indirect training including head elevation exercise, blowing, and ice massage, among others, to improve swallowing function; moreover, his Food Intake LEVEL Scale (FILS) was level 2<sup>1)</sup> (swallowing training is performed without using food) and a gastrostomy tube was placed. Six months after the accident, the patient was transferred to our hospital for treatment to improve swallowing. At the time of transfer, the patient exhibited an independent level of activities of daily living, and there were no problems other than oral intake, hoarseness, and headache. The patient's tongue deviated toward the left on protrusion.

When the patient was transferred to our hospital, we performed videoendoscopic examination of swallowing (VE), which revealed persistent upper UES opening, pooling of saliva in the pharynx, left dominant bilateral IX and X nerve paralysis, and left XII nerve paralysis (**Fig. 1**). The posterior pharyngeal wall moved toward the right during phonation ("curtain movement"). The bilateral palate could not elevate on phonation, and the left side elevation was particularly disturbed. Several days after performing VE (day 2, 182 days after onset), we performed videofluoroscopic examination of swallowing (VF), which revealed the absence of the swallowing reflex and worsened esophageal movement; however, a bolus could pass through the UES. The slice jelly partially passed to the left UES but the patient's pharyngeal sensation was assumed deteriorating as he was unaware that food remained in the pharynx. Based on these results, feeding training was initiated. The posture required 60° of reclining and right head rotation. We estimated the patient's FILS to be level 4<sup>1)</sup> (easy-to-swallow food less than the quantity of a meal [enjoyment level] is ingested orally).

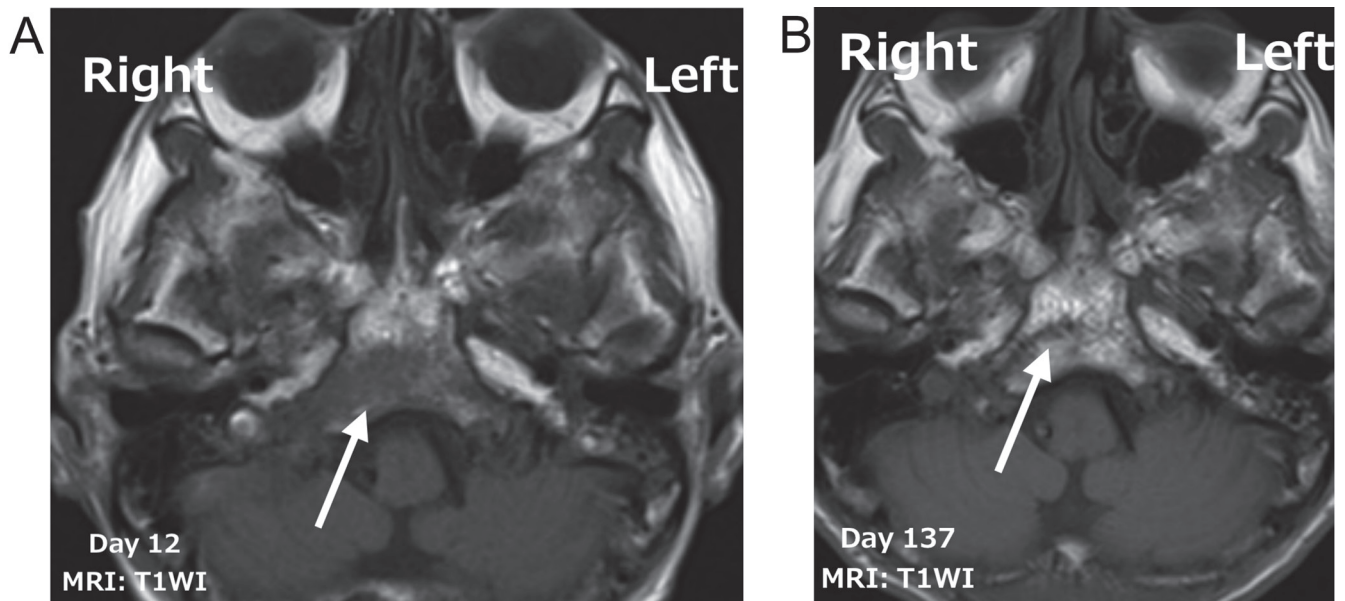
We concluded that the patient had left dominant bilateral IX and X nerve paralysis, as well as left XII nerve paralysis. However, his symptoms and clinical course were not in agreement with GBS; therefore, we performed further clinical examinations. Nerve conduction studies revealed only age-related changes in the left tibial and left peroneal nerves.



**Fig. 1.** Findings of videoendoscopic examination of swallowing of the present patient. We noted persistent upper esophageal sphincter opening (arrow), a reduction in pharyngeal contractility, pooling of saliva in the pharynx, and paralysis of the left pharynx and vocal cord.

The patient tested negative for anti-ganglioside antibody, and cytoalbuminologic dissociation was not visible in the cerebrospinal fluid. As a result, we suspected acute oropharyngeal palsy, a subtype of GBS; however, confirmatory analysis revealed negative results. Next, we suspected bilateral ALP with head trauma. Consequently, we performed head computed tomography (CT) and magnetic resonance imaging (MRI); CT findings were suggestive of a fracture of the clivus. We also noted a signal change in the clivus bone marrow on acute phase MRI performed on day 12; this finding had normalized on a chronic-stage MRI performed on day 137. Therefore, we concluded that the patient had a fracture of the clivus. Based on these findings, we diagnosed the patient with bilateral ALP with head trauma due to high-impact injury to the base of the skull (**Fig. 2A,B**).

On day 30 (211 days after onset), we performed a second VF assessment. Jelly and bolus could be swallowed based on gravity, and there were no signs of aspiration or penetration. However, esophageal peristalsis was poor due to lower cranial nerve palsy, and residue in the esophagus was observed. Consequently, we dilated the patient's UES with a balloon to induce esophageal peristalsis. This facilitated esophageal orifice opening and promoted esophageal peristalsis. After the evaluation, the patient began eating in the sitting position and exhibited an estimated FILS level of 5<sup>1)</sup> (easy-to-swallow food is orally ingested in one to two meals, but alternative



**Fig. 2.** Findings of head MRI (acute and chronic stages). (A) Acute stage: T1-weighted axial MRI image. On T1-weighted MRI performed during the acute phase, the clivus marrow shows a low signal (arrow), which reflects edema and bleeding caused by the fracture: normal clivus marrow would exhibit a high signal. (B) Chronic stage: T1-weighted axial MRI image. On T1-weighted MRI performed during the chronic stage, the signal of the clivus marrow has improved to a normal high signal (arrow).

nutrition is also given). The patient could eat in the sitting position, without reclining or head rotation. Moreover, he did not exhibit fever relapse, and his dietary conditions improved gradually.

Subsequently, the patient continued to undergo swallowing rehabilitation, including accurate positioning and strict meal conditions. We instructed him to thrust out his lower jaw to facilitate movement of the bolus by opening the UES, thereby preventing aspiration. He could swallow high-viscosity boluses by alternating bolus swallowing with water. We performed VE occasionally and modified our feedback based on VE findings because the patient exhibited reduced pharyngeal sensation; this was also useful for swallowing training.

After 2 months of rehabilitation, the patient's swallowing level improved to FILS level 8<sup>1)</sup> (three meals can be eaten by excluding food that is particularly difficult to swallow) and he was discharged home. However, his neurological findings had not improved during the hospital stay. The patient is undergoing rehabilitation and has finally returned to work. Moreover, he has been able to get compensation for industrial accidents that was not recognized at the time of injury; this may enable use of the social support system that should have originally been used. The entire clinical course

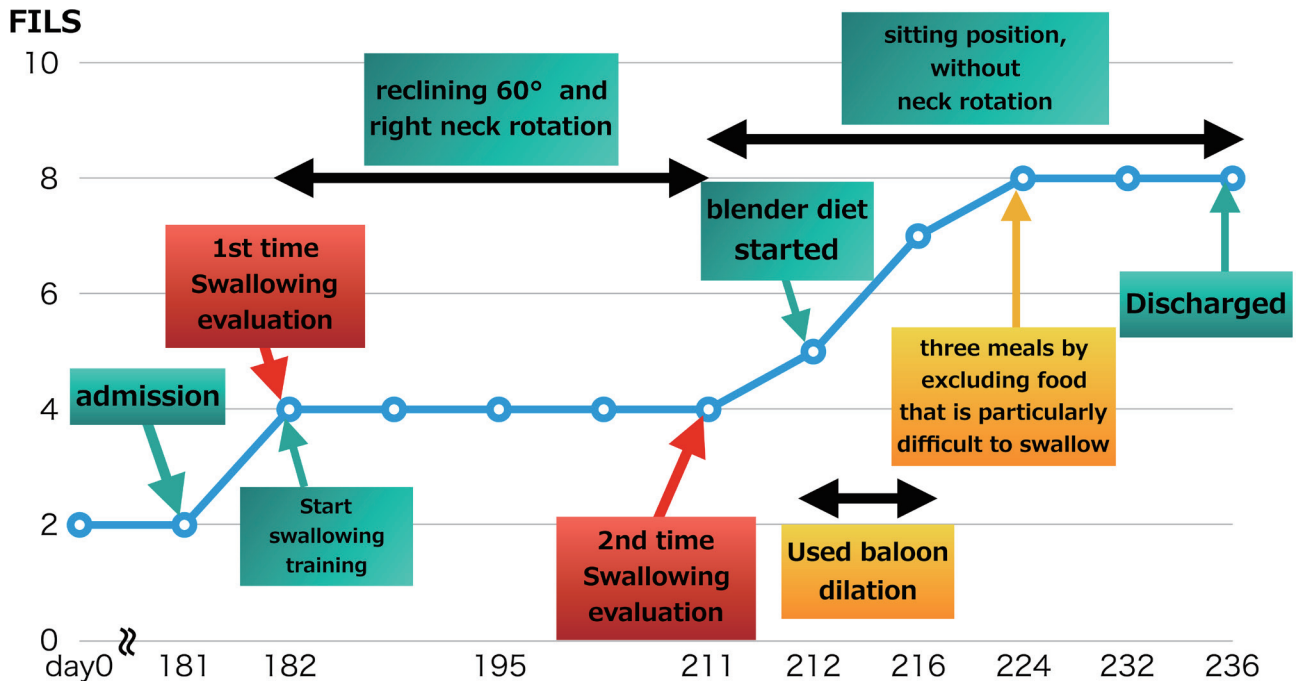
is depicted in **Fig. 3**. Informed consent for the publication of this case report was obtained from the patient.

## DISCUSSION

The patient described herein had been diagnosed with GBS in an acute-care hospital, although his symptoms were inconsistent with the diagnostic criteria for GBS. If the patient had had GBS, the disability would have improved over time; however, no clinical improvement was evident. Therefore, because other findings were not suggestive of GBS, we performed comprehensive CT and MRI examinations, which were indicative of a clivus fracture. Because the skull base fracture was treated conservatively, the course of this case was presumably not significantly affected.

ALP was first described by Jackson in 1816 as a syndrome of X, XI, and XII nerve paralysis. Approximately 50% of affected patients have idiopathic paralysis, whereas only 5% of patients experience paralysis due to trauma.<sup>2)</sup> The literature suggests an approximately 10% incidence of complications of aspiration due to laryngoparalysis.<sup>3)</sup> While there is no established therapy for ALP-related laryngoparalysis, improvement has been observed using swallowing training with cervical rotation.<sup>4,5)</sup> Previous studies have reported

# Clinical course



**Fig. 3.** Clinical course of the present patient. FILS, Food Intake LEVEL Scale.

that even minimal trauma can cause this disorder.<sup>6,7)</sup> Furthermore, lower cranial nerve palsy due to head trauma is generally unilateral; bilateral palsy is rare.<sup>8)</sup>

In the present case, we found left dominant bilateral IX and X nerve paralysis, as well as left XII nerve paralysis; XI nerve paralysis was not observed. The classification of classic laryngeal paralysis includes Collet-Sicard syndrome and Avellis' syndrome; however, we assumed that these classifications were not applicable in our case because the nerve was damaged multiple times as a result of high-impact trauma.

We suspected that the force of the trauma was concentrated on the clivus because, on imaging analyses, there were no fractures other than those of the clivus. The patient also showed severe superior constrictor muscle paralysis, persistent UES opening, and absence of the swallowing reflex, combined with loss of laryngopharyngeal sensation due to lower cranial nerve paralysis. Because there was a significant reduction in pharyngeal contractility and a strong driving force was not produced, we presumed that food with high viscosity and high dispersibility was at high risk of remaining in the pharynx. We determined that the ideal food

was a small amount of liquid or a small amount of added liquid thickener to enhance cohesion; therefore, we began oral intake training using these substances. Gradually, the patient learned to swallow and could eat soft foods that required minimal chewing; however, he needed a small amount of liquid to clear pharyngeal residue. Our main instruction was as follows:<sup>9)</sup>

1. To thrust out the lower jaw to open the UES, thereby preventing aspiration.
2. To swallow high-viscosity boluses by alternating bolus swallowing with water.
3. To provide occasional feedback based on VE findings.

These measures were extremely effective, and the patient was finally able to ingest three meals per day. We determined that a precise diagnosis was needed; therefore, a treatment strategy was designed to improve swallowing without considering the diagnosis in the acute-care hospital.

In conclusion, we encountered a patient with peculiar swallowing dynamics due to bilateral ALP caused by trauma. Initially, the patient was misdiagnosed with GBS at an acute-care hospital, where it was judged that oral ingestion was impossible without a proper resolution of dysphagia.



When we reviewed the case at our hospital, we diagnosed the patient with ALP with head trauma. Oral ingestion was possible with proper swallowing rehabilitation. When a patient is diagnosed with laryngeal paralysis, it is important to carefully confirm the findings of lower cranial nerve paralysis. Clinicians should understand the etiology of dysphagia and provide appropriate swallowing rehabilitation techniques to ensure that patients experience a favorable prognosis.

#### CONFLICT OF INTEREST

The authors declare that there are no conflicts of interest.

#### REFERENCES

1. Kunieda K, Ohno T, Fujishima I, Hojo K, Morita T: Reliability and validity of a tool to measure the severity of dysphagia: The Food Intake LEVEL Scale. *J Pain Symptom Manage* 2013;46:201–206. DOI:10.1016/j.jpainsymman.2012.07.020, PMID:23159683
2. Ichihara M, Shirakura K, Ueno S: On the mixed type paralysis of larynx. *Med J Showa Univ Sch Med* 1954;14–15. [in Japanese]
3. Karaho T: A pathologic characteristic of dysphagia: the disease of the head and neck region and remedial point. *J Otolaryngol Jpn* 2010;56:S99–S106. [in Japanese]
4. Saito Y, Kinoshita A, Kabeya M: Five cases of idiopathic associated laryngeal paralysis. *J Med Pract Otolaryngol* 2008;101:785–789. [in Japanese]
5. Sugiura J, Fujimoto Y, Nakashima T: On the efficiency of swallowing rehabilitation for dysphagia with associated laryngeal paralysis after head and neck surgery. *J Otolaryngol Jpn* 2004;50:264–267. [in Japanese]
6. Koizumi M, Kitahara N, Suzuki Y: A case of associated laryngeal paralysis from head injury. *Jpn J Logop Phoniater* 2012;53:208–211. DOI:10.5112/jjlp.53.208 [in Japanese]
7. Ohmae Y, Karaho T, Hanyu Y, Murase Y, Kitahara S, Inouye T: [Effect of posture strategies on preventing aspiration]. *Nippon Jibiinkoka Gakkai Kaiho* 1997;100:220–226. DOI:10.3950/jibiinkoka.100.220, PMID:9071122
8. Brar G, Kumar P, Chacko J, Mundlapudi B: Bilateral lower cranial nerve palsy after closed head injury: a case report and review of literature. *Indian J Crit Care Med* 2018;22:879–882. DOI:10.4103/ijccm.IJCCM\_476\_18, PMID:30662229
9. Nakamura S, Tohi J, Miyake Y: A case of the basal skull fracture which produced a jugular foramen syndrome. *J Jpn Congr Neurol Emergencies* 2007;20:85–88. [in Japanese]