




Contrast leakage distant from the hematoma in patients with spontaneous ICH: A 7 T MRI study

Wilmar MT Jolink¹, Arjen Lindenholz² , Ellis S van Etten³, Koen M van Nieuwenhuizen¹ , Floris HBM Schreuder⁴, Hugo J Kuijff⁵ , Matthias JP van Osch⁶ , Jeroen Hendrikse², Gabriel JE Rinkel¹, Marieke JH Wermer³ and Catharina JM Klijn^{1,4}

Abstract

Disruption of the blood–brain barrier (BBB) might play a role in the pathophysiology of cerebral small vessel disease-related ICH. The aim of this study was to assess presence and extent of contrast agent leakage distant from the hematoma as a marker of BBB disruption in patients with spontaneous ICH. We prospectively performed 7 tesla MRI in adult patients with spontaneous ICH and assessed contrast leakage distant from the hematoma on 3D FLAIR images. Thirty-one patients were included (mean age 60 years, 29% women). Median time between ICH and MRI was 20 days (IQR 9–67 days). Seventeen patients (54%; seven lobar, nine deep, one infratentorial ICH) had contrast leakage, located cortical in 16 and cortical and deep in one patient. Patients with contrast leakage more often had lobar cerebral microbleeds (CMBs; 77%) than those without (36%; RR 2.5, 95% CI 1.1–5.7) and a higher number of lobar CMBs (patients with contrast leakage: median 2, IQR 1–8 versus those without: median 0, IQR 0–2; $p = 0.02$). This study shows that contrast leakage distant from the hematoma is common in days to weeks after spontaneous ICH. It is located predominantly cortical and related to lobar CMBs and therefore possibly to cerebral amyloid angiopathy.

Keywords

Blood–brain barrier, cerebral microbleeds, intracerebral hemorrhage, magnetic resonance imaging, small vessel disease

Received 8 March 2019; Revised 17 April 2019; Accepted 30 April 2019

Introduction

Intracerebral hemorrhage (ICH) related to cerebral small vessel disease (cSVD) is a detrimental disease resulting in high case-morbidity and -fatality.^{1,2} Despite ongoing advances in imaging and supportive treatment, incidence has not declined and outcome after ICH has at most marginally improved.^{2–4} An important contributing factor may be that the underlying pathophysiology is incompletely understood. cSVD-related ICH is mostly attributed to hypertensive vasculopathy or cerebral amyloid angiopathy (CAA),⁵ but the exact sequence of events and mechanisms that lead to vessel rupture remains unknown. Accumulating evidence suggests that disruption of the blood–brain barrier (BBB) plays a role in cSVD-related ICH.^{6–8}

¹Department of Neurology and Neurosurgery, Brain Center Rudolf

Magnus, University Medical Center Utrecht, Utrecht, The Netherlands

²Department of Radiology, University Medical Center Utrecht, Utrecht, The Netherlands

³Department of Neurology, Leiden University Medical Center, Leiden, The Netherlands

⁴Department of Neurology, Donders Institute for Brain, Cognition and Behaviour, Centre for Neuroscience, Radboud university medical center, Nijmegen, The Netherlands

⁵Image Sciences Institute, University Medical Center Utrecht, Utrecht, the Netherlands

⁶C.J. Gorter Center for High Field MRI, Department of Radiology, Leiden University Medical Center, Leiden, The Netherlands

Corresponding author:

Wilmar MT Jolink, Department of Neurology and Neurosurgery, University Medical Center Utrecht, G03.232, PO Box 85500, Utrecht 3508 GA, The Netherlands.

Email: w.jolink@umcutrecht.nl

Contrast agent leakage (further referred to as contrast leakage) on dynamic contrast enhanced (DCE) MRI as a biomarker of BBB disruption has been demonstrated in patients with (lacunar) stroke,^{9–11} mild cognitive impairment and Alzheimer's disease.^{12,13} Using dedicated fluid-attenuated inversion recovery (FLAIR) sequences after gadolinium contrast agent injection, hyperintense foci can be found in the normal appearing brain parenchyma or cerebrospinal fluid (CSF) space: the so-called Hyperintense Acute Reperfusion Marker (HARM).^{14–17} In the acute phase after ICH (median interval between ICH and MRI 11 h), HARM was found in 85% of patients.¹⁸ We hypothesized that contrast leakage as a marker of BBB disruption is a marker of the underlying cSVD in patients with ICH. Therefore, we assessed the presence and extent of contrast leakage in normal-appearing brain and CSF distant from the hematoma in patients with spontaneous ICH on 7 tesla (T) MRI in the subacute phase after ICH. Additionally, we related the presence and extent of contrast leakage to classical markers of cSVD.

Materials and methods

Study population

Patients were enrolled from an ongoing multicenter prospective observational cohort study in the Netherlands, the Finding the Etiology in spontaneous Cerebral Hemorrhage (FETCH) study. In this study, we included 31 consecutive adult patients who presented to the University Medical Centers of Utrecht, Leiden or Nijmegen, since 1 October 2013, with spontaneous ICH confirmed by computed tomography (CT) and were able to undergo 3 T and/or 7 T MR imaging. Patients with a known cause of ICH, such as a vascular malformation, tumor or trauma, are excluded. For this study, we included all patients who underwent 7 T MRI with a gadolinium-containing contrast agent within three months of the ICH.

The FETCH study was approved by the Medical Ethics Review Committee of the University Medical Center Utrecht, and by all participating centers. Each patient gave written informed consent for participation in the study. The guidelines according to the Declaration of Helsinki were followed.

We categorized the ICH according to location as lobar, deep or infratentorial. Patients with possible or probable CAA were identified using the modified Boston criteria.¹⁹ Hypertension was defined as use of antihypertensive medication, a systolic blood pressure greater than 140 mm Hg, a diastolic blood pressure greater than 90 mm Hg on two documented independent measurements prior to the ICH or left ventricular hypertrophy on ECG.

Imaging protocol and analysis

On admission CT, we assessed hematoma volume using an in-house developed tool,²⁰ and ICH location. Lobar ICH was defined as ICH isolated to the cortex (with or without involvement of subcortical white matter) and non-lobar ICH as deep (thalamus and basal ganglia) or infratentorial (brainstem and cerebellum) ICH. We used 7 T MRI to assess presence of contrast leakage, CMBs and white matter hyperintensities (WMH). Presence of enlarged perivascular spaces (EPVS) and diffusion weighted imaging (DWI) lesions was assessed on 3 T MRI.

7 T MRI (Philips, Best, The Netherlands) scans were acquired by a standardized protocol; 3D T₂-weighted (repetition time (TR)/equivalent echo time (TE) = 3158/60 ms; voxel size = acquired: 0.70 × 0.70 × 0.70 mm³, reconstructed: 0.35 × 0.35 × 0.35 mm³), 3D T₁-weighted (TR/TE = 4.8/2.2 ms; voxel size = acquired: 1.00 × 1.01 × 1.00 mm³, reconstructed: 0.66 × 0.66 × 0.50 mm³), dual echo 3D T₂*-weighted (TR/first TE/second TE = 20/6.9/15.8 ms; voxel size = acquired: 0.50 × 0.50 × 0.70 mm³, reconstructed: 0.39 × 0.39 × 0.35 mm³) and 3D FLAIR images were acquired (TR/TE/inversion time (TI) = 8000/300/2325 ms; voxel size = acquired: 0.80 × 0.82 × 0.80 mm³, reconstructed: 0.49 × 0.49 × 0.40 mm³). A gadolinium-containing contrast agent was administered in a single intravenous injection of 0.1 mL Gadovist/kg body weight with a maximum of 10 mL Gadovist or 0.2 mL Dotarem/kg body weight with a maximum of 30 mL Dotarem. Postgadolinium FLAIR images were acquired at least 10 min after contrast injection.

3 T unenhanced MRI (Philips, Best, The Netherlands) scans were acquired by a standardized protocol including DWI with apparent diffusion coefficient (ADC) map, an axial T₂*, T₂-proton density-weighted sequence, inversion recovery and FLAIR, all with 48 contiguous slices and 0.96 × 0.95 × 3.00 mm³ voxels. Also, a 3D T₁-weighted sequence was acquired.

Contrast leakage, CMBs, EPVS, WMH and DWI lesions were annotated by two trained readers (WMTJ and AL) independently and blinded for patient information. Discrepancies were resolved in a consensus meeting with an experienced neuroradiologist (JH) and neurologist (CJMK). Contrast leakage was defined as a hyperintense signal in normal-appearing brain or CSF on delayed postgadolinium FLAIR images, while absent on precontrast images. The signal had to be visually distinct and anatomically non-contiguous with the hematoma. We used the 5-point HARM rating scale to rate the extent of the contrast leakage as HARM 0: no contrast leakage, HARM 1: punctate lesions of contrast leakage, HARM 2: multiple punctate lesions of contrast leakage, HARM 3: focal sulcal contrast enhancement, and HARM 4: bilateral and

diffuse contrast leakage.¹⁸ CMBs were rated in accordance with the Standards for Reporting Vascular changes on nEuroimaging (STRIVE) definitions and the Microbleed Anatomical Rating Scale,^{21,22} and WMH by the Fazekas rating scale.²³ DWI lesions were defined as small, hyperintense lesions on DWI with low intensity in the corresponding region on ADC maps remote from ICH and the area of perihematomal edema.²⁴ EPVS were rated in basal ganglia and centrum semiovale regions on axial T₂-weighted sequences using a validated rating scale.^{25,26}

Statistical analysis

We used the Student t-test, χ^2 test, Mann-Whitney U test and logistic regression, as appropriate, to analyze group differences in presence, frequency and distribution of baseline characteristics, CMBs (presence (yes/no) and number of CMBs), DWI lesions (yes/no), categories of EPVS in basal ganglia and centrum semiovale (0: no EPVS, 1: 1–10, 2: 11–20, 3: 21–40, 4: > 40 EPVS) and WMH (Fazekas ≥ 2 vs. < 2) between patients with and without contrast leakage on 7 T MRI.

Results

We included 31 patients (mean age 60 years, standard deviation 12 years; 29% women). Baseline characteristics are listed in Table 1. Median time interval between ICH and 7 T MRI was 20 days (IQR 9–67 days) and median time interval between 3 T and 7 T MRI was 7 days (IQR 1–44 days). Location of the ICH was supratentorial in 90% (lobar in eleven (36%), deep in 17 (55%)) and infratentorial in 3 patients (10%). Five of the 11 patients with lobar ICH fulfilled the modified Boston Criteria for probable CAA and two patients for possible CAA.¹⁹

In 17 patients (54%; seven with lobar, nine with deep, and one with infratentorial ICH), postgadolinium FLAIR images showed contrast leakage distant from the hematoma. Contrast leakage most frequently occurred in a cortical location (16 patients, 94%), rarely deep (1 patient had both cortical and deep contrast leakage, 6%), and never infratentorial. Nine patients (53%) had contrast enhancement in both hemispheres, two (12%) in the symptomatic hemisphere only, and six (35%) in the contralateral hemisphere only. One patient with a cerebellar ICH had supratentorial contrast enhancement in both hemispheres. Four patients (24%) had a punctate lesion of contrast leakage (HARM 1), five patients (29%) multiple punctate lesions of contrast leakage (HARM 2), three patients (18%) showed focal sulcal contrast enhancement (HARM 3) and five patients (29%) bilateral and diffuse contrast leakage (HARM 4). Illustrative examples of

patients with different HARM scale scores are provided in Figure 1.

Among the patients with contrast leakage, there was a relatively high proportion of women (0.41; risk ratio (RR) 2.5 (95% confidence interval (CI) 0.7–8.8)), a low proportion of patients with a history of atrial fibrillation (0; RR 0.4 (95% CI 0.2–0.6)) and a high mean diastolic blood pressure at admission (95 mm Hg; $p=0.12$), although these differences were not all statistically significant. All other patient characteristics were comparable in patients with and without contrast leakage (Table 1). There was no difference in time interval between ICH and 7 T MRI in patients with (median 20 days; IQR 11–70 days) and without (median 22 days; IQR 5–67 days) contrast leakage ($p=0.55$).

Patients with contrast leakage more often had lobar CMBs (77%) than those without contrast leakage (36%; RR 2.5 (95% CI 1.1–5.7, Table 1)) as well as a higher number of lobar CMBs (patients with contrast leakage: median 2, IQR 1–8 versus those without contrast leakage: median 0, IQR 0–2; $p=0.02$, Table 1). Seven out of 17 patients with contrast leakage had a lobar ICH of which five fulfilled the modified Boston criteria for probable ($n=4$) or possible CAA ($n=1$). The other two patients (44 and 51 years old) with lobar ICH had lobar CMBs or superficial siderosis but did not fulfill the modified Boston criteria for probable CAA, because they were younger than 55 years. We found no differences between patients with and without contrast leakage in the proportion of patients with Fazekas score ≥ 2 , categories of EPVS or the proportion of patients with DWI lesions (Table 1). We found no spatial relationship between the location of the DWI lesions and the location of the contrast leakage.

Discussion

This study shows that over 50% of the patients with spontaneous ICH have contrast leakage distant from the hematoma as evidenced by high field 7 T MRI in the subacute phase, up to 70 days after ICH. It occurs both in patients with lobar and in those with deep and infratentorial ICH, with a predominantly cortical location. In half of the patients, contrast leakage is moderate or severe (HARM 3 and 4) and presence of contrast leakage is associated with presence and number of lobar CMBs.

The proportion of patients with contrast leakage in our cohort (54%) is higher than that in a recent study using 3 T MRI delayed postgadolinium FLAIR images in healthy elderly subjects (mean age 73 years; 19% with contrast leakage), in patients with mild cognitive impairment (mean age 69 years; 30%) and in patients with Alzheimer's disease (mean age 72 years; 40%).¹⁴ In

Table 1. Baseline characteristics of patients with and without contrast leakage.

Characteristics	All N = 31	Contrast leakage N = 17 (55%)	No contrast leakage N = 14 (45%)	Risk ratio (95% CI)	p-value
Patient characteristics					
Mean age, years (SD)	60 (12)	61 (13)	59 (12)		0.55*
Female sex, n (%)	9 (29)	7 (41)	2 (14)	2.5 (0.7–8.8)	0.10 [#]
GCS at presentation, median (IQR)	15 (13–15)	15 (12–15)	14 (13–15)		0.53 [^]
NIHSS at presentation, median (IQR)	5 (2–9)	6 (3–9)	4 (1–8)		0.31 [^]
Mean systolic BP at admission, mm Hg (SD)	166 (33)	174 (36)	158 (28)		0.28*
Mean diastolic BP at admission, mm Hg (SD)	94 (21)	95 (24)	92 (16)		0.12*
History of hypertension, n (%)	19 (61)	9 (53)	10 (71)	0.7 (0.3–1.5)	0.38 [#]
History of TIA, n (%)	4 (13)	3 (18)	1 (7)	1.9 (0.4–11.0)	0.39 [#]
History of ischemic stroke, n (%)	3 (10)	2 (12)	1 (7)	1.4 (0.3–7.2)	0.67 [#]
History of cardiac disease, n (%)	1 (3)	0 (0)	1 (7)	0.4 (0.3–0.7)	0.26 [#]
Diabetes mellitus, n (%)	2 (7)	1 (6)	1 (7)	0.9 (0.2–3.8)	0.89 [#]
Atrial fibrillation, n (%)	3 (10)	0 (0)	3 (21)	0.4 (0.2–0.6)	0.045 [#]
Smoking (current or past), n (%)	13 (42)	5 (31)	8 (57)	0.6 (0.3–1.2)	0.15 [#]
Anticoagulants, n (%)	5 (16)	2 (12)	3 (21)	0.7 (0.3–1.6)	0.47 [#]
Antiplatelets, n (%)	6 (19)	4 (24)	2 (14)	1.4 (0.4–4.8)	0.52 [#]
Hematoma characteristics					
Lobar ICH location, n (%)	11 (36)	7 (41)	4 (29)	1.4 (0.6–3.4)	0.47 [#]
Median hematoma volume, mL (IQR)	14 (4–30)	14 (5–30)	11 (4–32)		0.74 [^]
Subarachnoid extension, n (%)	5 (16)	3 (18)	2 (14)	1.2 (0.4–3.6)	0.80 [#]
Intraventricular extension, n (%)	9 (29)	3 (18)	6 (43)	0.5 (0.3–1.1)	0.12 [#]
Presence of CMBs					
CMBs (yes, %)	23 (74)	14 (82)	9 (64)	1.6 (0.8–3.3)	0.25 [#]
0–1	12 (39)	6 (35)	6 (43)		ref
2–5	8 (26)	3 (18)	5 (36)		0.58 [@]
6–10	5 (16)	2 (12)	3 (21)		0.071 [@]
>10	6 (19)	6 (35)	0 (0)		0.99 [@]
Any lobar CMBs (yes, %)	18 (58)	13 (77)	5 (36)	2.5 (1.1–5.7)	0.02 [#]
Strictly lobar CMBs (yes, %)	5 (16)	4 (24)	1 (7)	2.5 (0.4–15.0)	0.22 [#]
Number of CMBs by location, median (IQR)					
Number of lobar CMBs	1 (0–4)	2 (1–8)	0 (0–2)		0.02 [^]
Number of non-lobar CMBs	1 (0–4)	1 (0–10)	1 (0–1)		0.57 [^]
Total number of CMBs	3 (0–9)	3 (1–23)	3 (0–5)		0.15 [^]
White matter hyperintensities					
Fazekas score ≥ 2 , n (%)	16 (52)	9 (53)	7 (50)	1.6 (0.7–3.4)	0.24 [#]
DWI lesions					
Presence, n (%) [§]	4 (13)	3 (18)	1 (7)	2.0 (0.3–11.5)	0.36 [#]
EPVS					
Basal ganglia[§]					
<10	12 (39)	6 (35)	6 (43)		ref
11–20	13 (42)	8 (47)	5 (36)		0.85
21–40	1 (3)	0 (0)	1 (7)		0.56
>40	0 (0)	0 (0)	0 (0)		1.00
Centrum semiovale[§]					
<10	3 (10)	0 (0)	3 (21)		ref

(continued)

Table 1. Continued

Characteristics	All	N = 31	Contrast leakage N = 17 (55%)	No contrast leakage N = 14 (45%)	Risk ratio (95% CI)	p-value
11–20	11	(36)	7 (41)	4 (29)		0.97
21–40	12	(39)	7 (41)	5 (36)		1.00
>40	0	(0)	0 (0)	0 (0)		1.00
Cortical superficial siderosis						
Presence, n (%)	3	(10)	3 (18)	0 (0)		0.20 [#]
Modified Boston criteria						
Probable CAA, n (%)	5	(16)	4 (24)	1 (7)	2.5 (0.4–15.0)	0.17 [#]
Probable CAA (including patients < 55 years), n (%)	8	(26)	6 (35)	2 (14)	2.1 (0.6–7.4)	0.18 [#]

BP: blood pressure; CI: confidence interval; CMB: cerebral microbleed; DWI: diffusion weighted imaging; EPVS: enlarged perivascular spaces; GCS: Glasgow coma scale; ICH: intracerebral hemorrhage; IQR: interquartile range; NIHSS: National Institutes of Health Stroke Scale; SD: standard deviation; TIA: transient ischemic attack.

*t-test, [#]Chi square, [^]Mann–Whitney U, [@] logistic regression, [§]in five patients 3 T MRI was not available.

a retrospective cohort study of 46 spontaneous ICH patients, contrast leakage was found distant from the hematoma in 85% of patients with conventional 1.5 T and 3 T MRI performed in the acute phase (median 11 hours) after hemorrhage onset.¹⁸ In that study, a possible but not significant association was found with a higher National Institutes of Health Stroke Scale score (NIHSS) at baseline and shorter time to MRI. Location of the hematoma, however, was not reported in that study. Our patients were scanned in the subacute phase (median 20 days), which may explain the smaller proportion of patients with contrast enhancement, despite higher field MRI. The smaller proportion in our study might also be explained by another potential mechanism of the BBB disruption. In the acute study, the BBB disruption may be due to direct injury of the hematoma.¹⁸ The persisting contrast leakage that we found might still be related to the direct effect of the hematoma but could also be an indicator of BBB disruption as a result of cSVD.²⁷ A previous study described contrast leakage in 2 of 19 patients with probable CAA, presenting with either atypical or multiple hemorrhages or superficial siderosis, on postgadolinium T₁-weighted sequences on 1.5 T MRI.²⁸ That study did not report the time interval between symptom onset and MRI. In 51 patients with lacunar stroke who underwent MRI in the subacute phase (mean 64 days, SD±12), BBB permeability was present more generalized in most of the sulci and EPVS, in contrast to the areas of focal enhancement in our study of ICH patients. In that study, BBB permeability was visualized using pre- and postgadolinium T₁-weighted MR sequences and two image processing methods.⁹

We found no association of contrast leakage with DWI lesions on 3 T MRI. A possible explanation might be the variable time interval between 3 T and 7 T MRI with a median time interval of 7 days (IQR

1–56 days), and DWI lesions may start to disappear after approximately 7 to 10 days.²⁹

The results of our study suggest that increased permeability of the BBB might play a role in cSVD-related ICH, in particular in the presence of lobar CMBs. A potential mechanism explaining contrast leakage is the cascade of events that follow the direct injury and mass effect of ICH, consisting of a release of clot-derived factors, cortical spreading depression and an inflammatory response, including leukocyte infiltration, microglia activation, cytokine and chemokine elevation and glutamate neurotoxicity. These lead to additional brain injury and BBB disruption, supporting the hypothesis that contrast leakage may be a consequence of ICH.^{1,30–36} This might also explain why contrast leakage can be found in a different lobe than the hematoma or the contralateral hemisphere.

Another hypothesis based on animal studies is that BBB disruption may in fact precede ICH.^{37,38} This hypothesis is supported by our previous observation of a patient with multiple lobar ICHs who showed focal contrast enhancement before appearance of a CMB exactly at the site of that contrast enhancement.³⁹ As we assessed patients only after they had experienced the ICH, our study cannot draw conclusions on causal inference. MRI contrast leakage indicative of BBB disruption may be another marker of the underlying cSVD pathology next to the ICH and classic MRI markers of cSVD, including WMH, lacunes, EPVS, CMBs, recent small subcortical infarcts and brain atrophy.²¹ To date, it remains unclear why in some patients cSVD manifests as ischemia, whereas in others cSVD causes hemorrhage. Even in the cSVD that is related to hypertension and not CAA, some patients appear to be more prone to hemorrhage than others as suggested by the fact that new CMBs are found more frequently in those who already had CMBs before, than in those who did not.^{40–42}

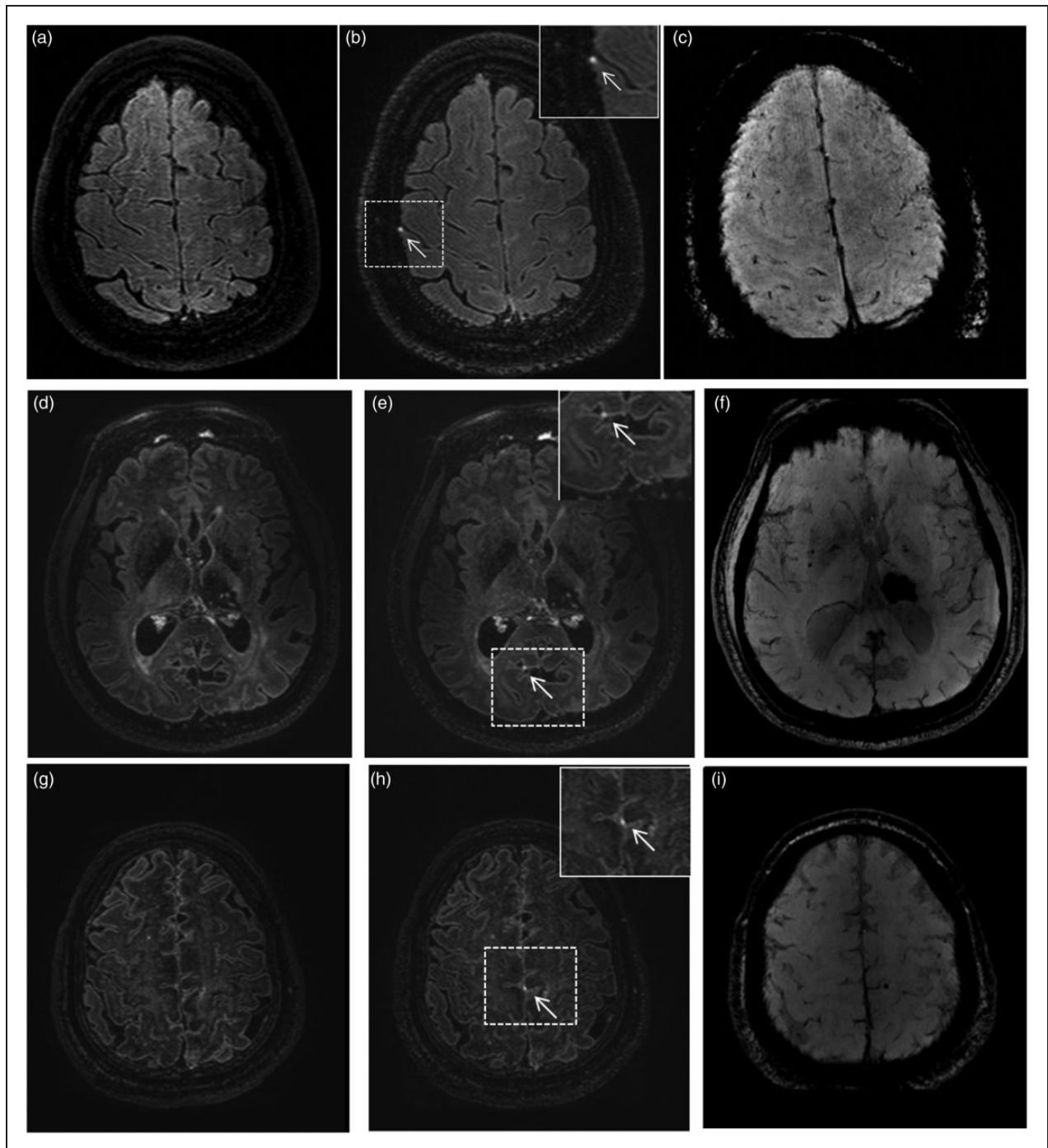


Figure 1. Examples of patients with different HARM scale scores. HARM 1: Punctate lesion of contrast leakage. Pre- (panel A) and postgadolinium (panel B) FLAIR images of a 41-year-old man with an infratentorial hemorrhage, a right frontal punctate lesions (white arrow) of contrast leakage and no abnormalities at that site on SWI (panel C). HARM 2: Multiple punctate lesions of contrast leakage. Pre- (panels D and E) and postgadolinium (panels G and H) FLAIR images of a 54-year-old man with left deep ICH, right occipital (white arrow) and left frontal lesions (white open arrow) of contrast leakage and no abnormalities at those sites on SWI (panel F and I). HARM 3: Focal sulcal contrast leakage. Pre- (panel J) and postgadolinium (panel K) FLAIR images of a 45-year-old man with a left deep ICH, left parietal focal sulcal contrast leakage (white arrow) and no abnormalities at that site on SWI (panel L). HARM 4: Bilateral and diffuse contrast leakage. Pre- (panel M) and postgadolinium (panel N) FLAIR images of a 67-year-old woman with right deep ICH, extensive bilateral and generalized occipital contrast enhancement (white arrows) and multiple cerebral microbleeds at that site on SWI (panel O).

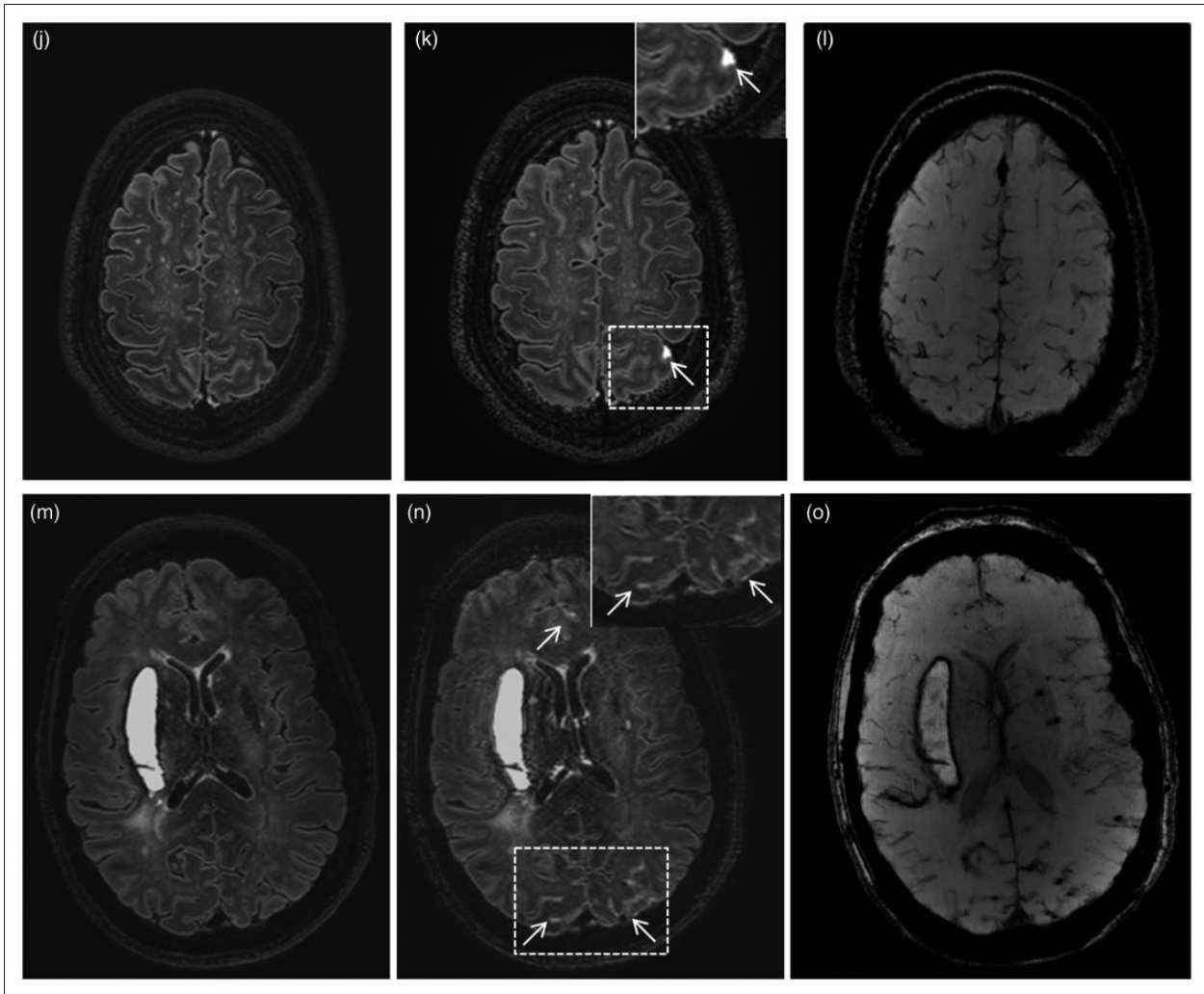


Figure 1. Continued.

We found contrast leakage predominantly cortical, even in patients with deep ICH. A potential explanation is that hypertensive vasculopathy not only affects the deep penetrating vessels but also the superficial cortical vessels or that it affects deep penetrating vessels in a different way than superficial cortical vessels.⁴³ Also, it could be that patients with non-lobar ICH have CAA in addition to hypertensive vasculopathy (for example HARM score 4 in Figure 1).⁴⁴ Other studies describe that contrast leakage or BBB disruption might be caused by cortical spreading depression.^{31,45–48} The association of contrast leakage with lobar CMBs and that four of the five patients in our study with probable CAA according to the modified Boston criteria had contrast leakage, tentatively supports a relation with CAA. The predilection of contrast leakage in cortical rather than deep areas was also found by others in cognitive healthy elderly

subjects, and in patients with mild cognitive impairment or Alzheimer's disease and ischemic stroke.^{14–16,18,49,50}

We found no association with other cSVD markers than CMBs (i.e. DWI lesions, EPVS and WMH). In a previous cohort of ICH patients, there was also no association of contrast leakage with WMH.¹⁸ In the study in cognitively healthy elderly patients, patients with mild cognitive impairment and Alzheimer's disease, there was also no association of contrast leakage with lacunes or WMH.¹⁴ This might indicate that contrast leakage is a marker independent of other cSVD features, and possibly be particularly associated with CAA.

Strengths of our study are that we were able to prospectively collect patients with spontaneous ICH from multiple centers and assess these patients in the 7 T MRI scanner in the subacute stage of ICH. Another

strength is that 7 T MRI has a high signal-to-noise ratio with also better contrast-to-noise in FLAIR images than conventional MRI scanners. This allows the use of voxel sizes less than a millimeter and consequently the possibility of a better yield by being able to detect small punctate lesions of contrast leakage, including in deeper areas.⁵¹ We used FLAIR images instead of T₁-weighted images, because this MR sequence has a better sensitivity in detecting low concentrations of Gadolinium.^{14,52,53} Furthermore, FLAIR images are less sensitive to the effects of gadolinium contrast in the blood vessels, because of a stronger signal decay due to the effects of blood flow in combination with shortening of the T₂ relaxation time at higher concentrations of gadolinium.^{14,54} Postgadolinium FLAIR enhancement on 3T MRI is a novel technique which has also been used in cranial nerve imaging for identifying both normal and abnormal cranial nerves.^{55–57}

Our study also has limitations. First, the sample size was small. Second, including severely affected ICH patient for 7T MR imaging is challenging and this may have resulted in a selection bias in that we included less affected patients with smaller hematomas and a relatively lower NIHSS scores. Third, assessing contrast leakage on postgadolinium FLAIR images may be more rater dependent than techniques such as DCE-MRI and cannot be used to quantify the amount of leakage. Fourth, raters were not blinded for ICH location which might have included detection bias. Finally, there was variation in time interval between ICH and MRI between patients. As the median time interval was similar between patients with and without contrast leakage, this will not have affected the analyses of different cSVD markers in these groups.

Our findings need confirmation, preferably in a larger cohort of ICH patients with and without CAA. Furthermore, it would be of interest to study the relation between contrast leakage and outcome. Also, sequential scanning of patients with contrast leakage to follow changes in contrast enhancement over time would be of interest. Further work is needed to determine whether FLAIR contrast enhancement, as a biomarker of BBB disruption, is able to predict recurrent ICH or cognitive deterioration.²¹

Funding

The author(s) disclosed receipt of the following financial support for the research, authorship, and/or publication of this article: Dr. Klijn is supported by a clinical established investigator grant of the Dutch Heart Foundation (Grant Number 2012T077) and an ASPASIA grant from The Netherlands Organisation for Health Research and Development, ZonMw (grant number 015008048)





Declaration of conflicting interests

The author(s) declared no potential conflicts of interest with respect to the research, authorship, and/or publication of this article.

Authors' contributions

Wilmar MT Jolink: study concept and design, acquisition of data, rating images, interpretation of the results, drafting the manuscript. Arjen Lindenholtz: rating images, interpretation of the results, critical revisions. Ellis S van Etten: acquisition of data, critical revisions. Koen M van Nieuwenhuizen: acquisition of data, critical revisions. Floris HBM Schreuder: acquisition of data, critical revisions. Hugo J Kuijf: imaging analysis, critical revisions. Matthias JP van Osch: acquisition of data, critical revisions. Jeroen Hendrikse: rating images, critical revisions. Gabriel JE Rinkel: interpretation of the results, critical revisions. Marieke JH Wermer: interpretation of the results, critical revisions. Catharina JM Klijn: study concept and design, rating images, interpretation of the results, critical revisions.

ORCID iDs

Arjen Lindenholtz  <https://orcid.org/0000-0002-5333-5723>
 Koen M van Nieuwenhuizen  <https://orcid.org/0000-0002-4815-002X>
 Hugo J Kuijf  <https://orcid.org/0000-0001-6997-9059>
 Matthias JP van Osch  <https://orcid.org/0000-0001-7034-8959>

References

1. Qureshi AI, Mendelow AD and Hanley DF. Intracerebral haemorrhage. *Lancet* 2009; 373: 1632–1644.
2. van Asch CJ, Luitse MJ, Rinkel GJ, et al. Incidence, case fatality, and functional outcome of intracerebral haemorrhage over time, according to age, sex, and ethnic origin: a systematic review and meta-analysis. *Lancet Neurol* 2010; 9: 167–176.
3. Jolink WM, Klijn CJ, Brouwers PJ, et al. Time trends in incidence, case fatality, and mortality of intracerebral hemorrhage. *Neurology* 2015; 85: 1318–1324.
4. Bejot Y, Grelat M, Delpont B, et al. Temporal trends in early case-fatality rates in patients with intracerebral hemorrhage. *Neurology* 2017; 88: 985–990.
5. Wilson D, Charidimou A and Werring DJ. Advances in understanding spontaneous intracerebral hemorrhage: insights from neuroimaging. *Expert Rev Neurother* 2014; 14: 661–678.
6. Freeze WM, Jacobs HIL, Schreuder FFBM, et al. Blood-brain barrier dysfunction in small vessel disease related intracerebral hemorrhage. *Front Neurol* 2018; 9: 926.
7. Pantoni L. Cerebral small vessel disease: from pathogenesis and clinical characteristics to therapeutic challenges. *Lancet Neurol* 2010; 9: 689–701.
8. Wardlaw JM, Smith C and Dichgans M. Mechanisms of sporadic cerebral small vessel disease: insights from neuroimaging. *Lancet Neurol* 2013; 12: 483–497.

9. Wardlaw JM, Doubal F, Armitage P, et al. Lacunar stroke is associated with diffuse blood-brain barrier dysfunction. *Ann Neurol* 2009; 65: 194–202.
10. Villringer K, Sanz Cuesta BE, Ostwaldt AC, et al. DCE-MRI blood-brain barrier assessment in acute ischemic stroke. *Neurology* 2017; 88: 433–440.
11. Topakian R, Barrick TR, Howe FA, et al. Blood-brain barrier permeability is increased in normal-appearing white matter in patients with lacunar stroke and leuko-araiosis. *J Neurol Neurosurg Psychiatry* 2010; 81: 192–197.
12. van de Haar HJ, Burgmans S, Jansen JF, et al. Blood-brain barrier leakage in patients with early Alzheimer disease. *Radiology* 2016; 281: 527–535.
13. Starr JM, Farrall AJ, Armitage P, et al. Blood-brain barrier permeability in Alzheimer's disease: a case-control MRI study. *Psychiatry Res* 2009; 171: 232–241.
14. Freeze WM, Schnerr RS, Palm WM, et al. Pericortical enhancement on delayed postgadolinium fluid-attenuated inversion recovery images in normal aging, mild cognitive impairment, and Alzheimer disease. *AJNR Am J Neuroradiol* 2017; 38: 1742–1747.
15. Latour LL, Kang DW, Ezzeddine MA, et al. Early blood-brain barrier disruption in human focal brain ischemia. *Ann Neurol* 2004; 56: 468–477.
16. Lee KM, Kim JH, Kim E, et al. Early stage of hyperintense acute reperfusion marker on contrast-enhanced FLAIR images in patients with acute stroke. *AJR Am J Roentgenol* 2016; 206: 1272–1275.
17. Kidwell CS, Latour L, Saver JL, et al. Thrombolytic toxicity: blood brain barrier disruption in human ischemic stroke. *Cerebrovasc Dis* 2008; 25: 338–343.
18. Kidwell CS, Burgess R, Menon R, et al. Hyperacute injury marker (HARM) in primary hemorrhage: a distinct form of CNS barrier disruption. *Neurology* 2011; 77: 1725–1728.
19. Linn J, Halpin A, Demaerel P, et al. Prevalence of superficial siderosis in patients with cerebral amyloid angiopathy. *Neurology* 2010; 74: 1346–1350.
20. Kuijf H. *Image processing techniques for quantification and assessment of brain MRI*. Doctoral Dissertation, Utrecht University, Utrecht, 2013.
21. Wardlaw JM, Smith EE, Biessels GJ, et al. Neuroimaging standards for research into small vessel disease and its contribution to ageing and neurodegeneration. *Lancet Neurol* 2013; 12: 822–838.
22. Gregoire SM, Chaudhary UJ, Brown MM, et al. The microbleed anatomical rating scale (MARS): reliability of a tool to map brain microbleeds. *Neurology* 2009; 73: 1759–1766.
23. Fazekas F, Barkhof F, Wahlund LO, et al. CT and MRI rating of white matter lesions. *Cerebrovasc Dis* 2002; 13(Suppl 2): 31–36.
24. Prabhakaran S, Gupta R, Ouyang B, et al. Acute brain infarcts after spontaneous intracerebral hemorrhage: a diffusion-weighted imaging study. *Stroke* 2010; 41: 89–94.
25. Charidimou A, Meegahage R, Fox Z, et al. Enlarged perivascular spaces as a marker of underlying arteriopathy in intracerebral haemorrhage: a multicentre MRI cohort study. *J Neurol Neurosurg Psychiatry* 2013; 84: 624–629.
26. Doubal FN, MacLulich AM, Ferguson KJ, et al. Enlarged perivascular spaces on MRI are a feature of cerebral small vessel disease. *Stroke* 2010; 41: 450–454.
27. Wardlaw JM, Sandercock PA, Dennis MS, et al. Is breakdown of the blood-brain barrier responsible for lacunar stroke, leuko-araiosis, and dementia? *Stroke* 2003; 34: 806–812.
28. Hartz AM, Bauer B, Soldner EL, et al. Amyloid-beta contributes to blood-brain barrier leakage in transgenic human amyloid precursor protein mice and in humans with cerebral amyloid angiopathy. *Stroke* 2012; 43: 514–523.
29. Lansberg MG, Thijs VN, O'Brien MW, et al. Evolution of apparent diffusion coefficient, diffusion-weighted, and T2-weighted signal intensity of acute stroke. *AJNR Am J Neuroradiol* 2001; 22: 637–644.
30. Xi G, Keep RF and Hoff JT. Mechanisms of brain injury after intracerebral haemorrhage. *Lancet Neurol* 2006; 5: 53–63.
31. Dreier JP. The role of spreading depression, spreading depolarization and spreading ischemia in neurological disease. *Nat Med* 2011; 17: 439–447.
32. Sharp F, Liu DZ, Zhan X, et al. Intracerebral hemorrhage injury mechanisms: glutamate neurotoxicity, thrombin, and Src. *Acta Neurochir Suppl* 2008; 105: 43–46.
33. Keep RF, Zhou N, Xiang J, et al. Vascular disruption and blood-brain barrier dysfunction in intracerebral hemorrhage. *Fluids Barriers CNS* 2014; 11: 18.
34. Aronowski J and Zhao X. Molecular pathophysiology of cerebral hemorrhage: secondary brain injury. *Stroke* 2011; 42: 1781–1786.
35. Wang J and Dore S. Inflammation after intracerebral hemorrhage. *J Cereb Blood Flow Metab* 2007; 27: 894–908.
36. Wang J. Preclinical and clinical research on inflammation after intracerebral hemorrhage. *Prog Neurobiol* 2010; 92: 463–77.
37. Schreiber S, Bueche CZ, Garz C, et al. Blood brain barrier breakdown as the starting point of cerebral small vessel disease? New insights from a rat model. *Exp Transl Stroke Med* 2013; 5: 4.
38. Lee JM, Zhai G, Liu Q, et al. Vascular permeability precedes spontaneous intracerebral hemorrhage in stroke-prone spontaneously hypertensive rats. *Stroke* 2007; 38: 3289–3291.
39. van Nieuwenhuizen KM, Hendrikse J and Klijn CJM. New microbleed after blood-brain barrier leakage in intracerebral haemorrhage. *BMJ Case Rep* 2017; bcr-2016-218794. DOI: 10.1136/bcr-2016-218794.
40. Gregoire SM, Brown MM, Kallis C, et al. MRI detection of new microbleeds in patients with ischemic stroke: five-year cohort follow-up study. *Stroke* 2010; 41: 184–186.
41. Lee SH, Lee ST, Kim BJ, et al. Dynamic temporal change of cerebral microbleeds: long-term follow-up MRI study. *PLoS One* 2011; 6: e25930.
42. van Leijsen EMC, van Uden IWM, Ghafoorian M, et al. Nonlinear temporal dynamics of cerebral small vessel disease: the RUN DMC study. *Neurology* 2017; 89: 1569–1577.

43. Broderick J, Brott T, Tomsick T, et al. Lobar hemorrhage in the elderly. The undiminishing importance of hypertension. *Stroke* 1993; 24: 49–51.
44. Pasi M, Charidimou A, Boulouis G, et al. Mixed-location cerebral hemorrhage/microbleeds: underlying microangiopathy and recurrence risk. *Neurology* 2018; 90: e119–e126.
45. Leira R, Sobrino T, Rodriguez-Yanez M, et al. Mmp-9 immunoreactivity in acute migraine. *Headache* 2007; 47: 698–702.
46. Dreier JP and Reiffurth C. The stroke-migraine depolarization continuum. *Neuron* 2015; 86: 902–922.
47. Jung JE, Kim GS, Chen H, et al. Reperfusion and neurovascular dysfunction in stroke: from basic mechanisms to potential strategies for neuroprotection. *Mol Neurobiol* 2010; 41: 172–179.
48. Gursoy-Ozdemir Y, Qiu J, Matsuoka N, et al. Cortical spreading depression activates and upregulates MMP-9. *J Clin Invest* 2004; 113: 1447–1455.
49. Choi HY, Lee KM, Kim HG, et al. Role of hyperintense acute reperfusion marker for classifying the stroke etiology. *Front Neurol* 2017; 8: 630.
50. Warach S and Latour LL. Evidence of reperfusion injury, exacerbated by thrombolytic therapy, in human focal brain ischemia using a novel imaging marker of early blood-brain barrier disruption. *Stroke* 2004; 35(11 Suppl 1): 2659–2661.
51. Wardlaw JM, Doubal FN, Valdes-Hernandez M, et al. Blood-brain barrier permeability and long-term clinical and imaging outcomes in cerebral small vessel disease. *Stroke* 2013; 44: 525–527.
52. Kohrmann M, Struffert T, Frenzel T, et al. The hyperintense acute reperfusion marker on fluid-attenuated inversion recovery magnetic resonance imaging is caused by gadolinium in the cerebrospinal fluid. *Stroke* 2012; 43: 259–261.
53. Mathews VP, Caldemeyer KS, Lowe MJ, et al. Brain: gadolinium-enhanced fast fluid-attenuated inversion-recovery MR imaging. *Radiology* 1999; 211: 257–263.
54. Fukuoka H, Hirai T, Okuda T, et al. Comparison of the added value of contrast-enhanced 3D fluid-attenuated inversion recovery and magnetization-prepared rapid acquisition of gradient echo sequences in relation to conventional postcontrast T1-weighted images for the evaluation of leptomeningeal diseases at 3T. *AJNR Am J Neuroradiol* 2010; 31: 868–873.
55. Kuya J, Kuya K, Shinohara Y, et al. Usefulness of high-resolution 3D multi-sequences for peripheral facial palsy: differentiation between Bell's Palsy and Ramsay Hunt syndrome. *Otol Neurotol* 2017; 38: 1523–1527.
56. Naganawa S, Suzuki K, Yamazaki M, et al. Serial scans in healthy volunteers following intravenous administration of gadoteridol: time course of contrast enhancement in various cranial fluid spaces. *Magn Reson Med Sci* 2014; 13: 7–13.
57. Hong HS, Yi BH, Cha JG, et al. Enhancement pattern of the normal facial nerve at 3.0T temporal MRI. *Br J Radiol* 2010; 83: 118–121.