

# Bronchogenic cyst of the stomach: A case report and literature review

BO SUN, AN-KANG WANG, HAO CHEN, BAO-LIN QIAN, XIAO-KANG YI,  
YU JIANG, QIU LI, WEN-GUANG FU and JING LI

Department of Hepatobiliary Surgery, The Affiliated Hospital of Southwest Medical University,  
Luzhou, Sichuan 646000, P.R. China

Received January 2, 2020; Accepted August 19, 2020

DOI: 10.3892/etm.2020.9295

**Abstract.** Bronchogenic cyst (BC) is a rare congenital disease with pre-embryonic intestinal malformation. BC of the stomach is rare. The present study reported on the case of a 68-year-old male who presented with a spleen and stomach space mass detected incidentally upon a routine health examination. The patient underwent laparotomy. Postoperative histopathological diagnosis confirmed BC of the stomach. Postoperative recovery was smooth and the patient is currently under follow-up. A literature review suggested that BC is a rare disease and the location of the stomach is very rare. Indications of surgical intervention remain controversial for asymptomatic cases. Owing to no specific clinical or radiologic features to define the disease profile for diagnosis, surgery may be a good choice for both diagnosis and therapy if the patient's condition permits.

## Introduction

Bronchogenic cyst (BC) is a type of congenital cyst occurring during embryogenesis due to preintestinal malformations (1). BC is relatively rare, with a prevalence rate of 1/68,000-1/42,000 (2). Nearly 90% of BC cases have been reported in the mediastinum, particularly in the posterior (3). BC of the stomach has been rarely reported (4). Due to the heterogeneous clinical presentations and no specific manifestations of BC of the stomach, this disease is frequently misdiagnosed as gastrointestinal stromal tumor (GIST). The present study retrospectively reported on a case of BC of the stomach and reviewed previously published case reports on this rare condition.

## Case report

A 68-year-old Chinese male was admitted to the Department of Hepatobiliary Surgery, The Affiliated Hospital of Southwest Medical University, China in December 2019 due to a spleen and stomach space mass detected incidentally upon a routine health examination. The patient had been in good health, denying any anorexia, nausea, vomiting, diarrhea or constipation. There was no history of weight loss or fever. The patient's medical history included hypertension for ~10 years. There were no obvious signs of pain or tenderness and no lumps to palpate during the physical examination. Blood routine and tumor markers were within the normal range. Abdominal ultrasound revealed a heterogeneous lesion in the spleen and stomach space measuring 10.0x8.2x7.3 cm. CT displayed a well-defined, 9.5x8.4x7.8 cm ovate homogenous lesion attached to the fundus of the stomach, with a CT value of ~17 HU. The density was uniform, and spot-shaped calcifications were visible on the edges. The edges were clear and no obvious enhancement was seen on enhanced CT (Fig. 1). As the patient rejected endoscopy, no endoscopy was performed prior to the operation. The preoperative diagnosis was retroperitoneal mass. During abdominal exploration, an 10x8x8 cm cyst originating from the bottom of the stomach, with thin walls and smooth edges, was encountered. It had a clear boundary with the posterior peritoneum and surrounding organs. The area of adhesion to the stomach was ~2.1x2.3 cm. Cystic lesions were isolated and were not connected to the stomach cavity. The capsule was filled with yellow-white mucous, gelatinous contents. Considering the close relationship between the cyst and the stomach, the final decision was to remove the cyst at the bottom of the stomach and repair the stomach wall. The cysts originated from the serous muscle layer of the gastric wall. The cyst was separated and completely removed. The gastric muscle was repaired by intermittent suture. For histopathology, the tissue of the cyst wall was selected while avoiding the calcified part. Histopathology was performed according to standard protocols. The sample was fixed with 15% formaldehyde at room temperature for 24 h, washed for 20 min after fixation and then embedded in paraffin. Subsequently, the specimen was cut into 50- $\mu$ m slices and the cut slices were flattened in hot water, attached to a glass slide and dried in a 45°C thermostat. Xylene was used to remove the

---

*Correspondence to:* Professor Wen-Guang Fu or Professor Jing Li, Department of Hepatobiliary Surgery, The Affiliated Hospital of Southwest Medical University, 25 Taiping Street, Luzhou, Sichuan 646000, P.R. China  
E-mail: fuwg@swmu.edu.cn  
E-mail: weilinli268@126.com

*Key words:* bronchogenic cyst, stomach disease, case report

Table I. Previously reported cases of bronchogenic cyst of the stomach.

First author (year)	Age (years)/sex	Diameter (mm)	Symptoms	Location	Treatment	Outcome	(Refs.)
Keohane (1988)	64/F	150	Epigastric pain	Posterior	Resection	NR	(10)
Song (2005)	62/F	15	-	U/less	Resection	NR	(11)
Shibahara (2009)	43/M	90	Epigastric pain	U/less	Resection	NR	(12)
Yang (2013)	50/M	75	-	Fundus	Resection	Alive/24 mo	(13)
Yang (2013)	37/F	100	-	Posterior	Resection	NR	(13)
Chhaidar (2017)	65/M	80	Epigastric pain	U/less	Resection	Alive/24 mo	(5)
Han (2019)	62/F	60	Epigastric pain	U/less	Resection	NR	(14)
Present study (2020)	68/M	100	-	Fundus	Resection	Alive/to date	(-)

M, male; F, female; U, upper portion of the stomach; less, lesser curvature of the stomach; mo, months; NR, not reported.

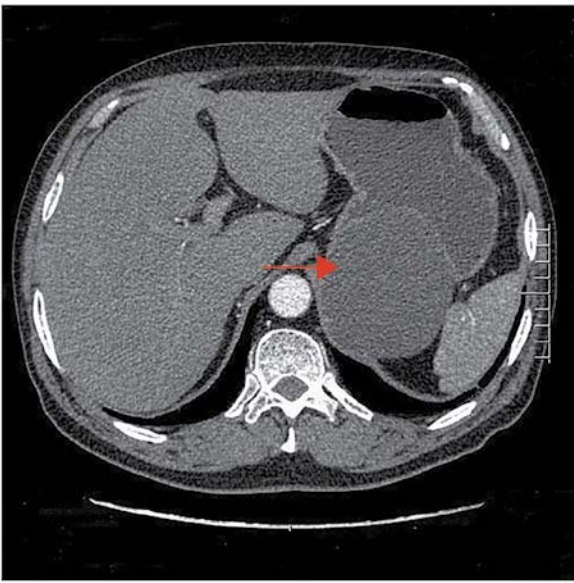


Figure 1. CT image displaying cystic lesion between the spleen and stomach (red arrow).

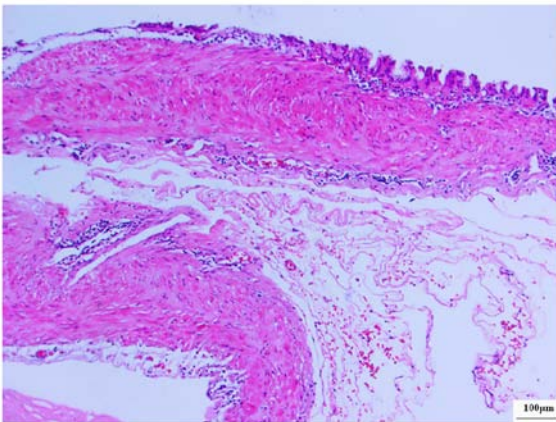


Figure 2. Image of the cystic lesion adjacent to the stomach. Hematoxylin and eosin staining; scale bar, 100  $\mu$ m.

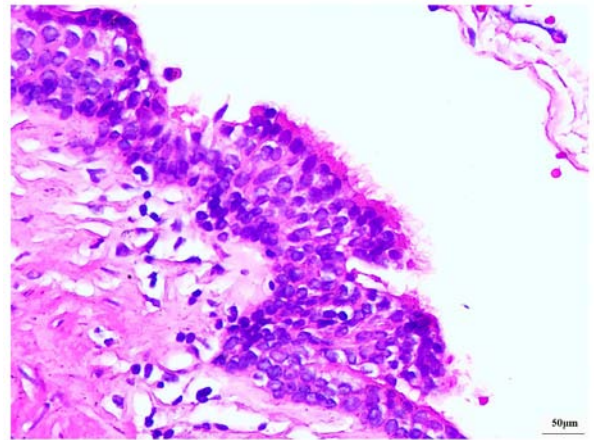


Figure 3. Representative histological image of BC of the stomach. Hematoxylin and eosin staining; scale bar, 50  $\mu$ m; BC, bronchogenic cyst.

immersed in distilled water and stained with hematoxylin and eosin (H&E) at 60°C for 30 min. The transparent slices were mounted with coverslips with and sealed with gum before they were observed under the light microscope. Histopathological examination of the resected specimen revealed that the cyst wall was lined by pseudostratified ciliated columnar epithelium and was without cellular atypia (Figs. 2 and 3). Based on the abovementioned pathologic features, the patient was diagnosed with BC of the stomach. The patient's recovery was smooth and he was discharged after 8 days.

### Discussion

Congenital cyst is a rare type of benign gastric lesion. Several types of congenital cyst have been reported in the literature, including foregut cysts, gastric replication cysts and bronchial cysts. The difference between them is the type of lining epithelium and surrounding layers, which may contain smooth muscle, cartilage, bronchial glands or may not be present. BC is a term traditionally used to describe pseudostratified columnar or cuboidal ciliated (respiratory) epithelium with cartilage or glandular tissue on the inner wall of the cyst (5). BC is a type of foregut-derived dysplasia, most commonly in the mediastinum, and is rarely seen in the abdomen or

paraffin wax from the slices, followed by rehydration with a descending series of graded alcohols. Finally, the sample was

retroperitoneum (6). Because they are produced by abnormal budding of the original tracheobronchial tree, they are usually located in the mediastinum or lung parenchyma (7). However, in some cases, they may detach and migrate to the abdomen. Depending on the degree of migration, they can be found anywhere in the abdominal cavity, including the ileal mesentery and hepatogastric ligament (8,9). The occurrence of BC in the stomach wall is very rare.

The current knowledge regarding the clinical features and optimal treatment of BC of the stomach is limited. A systematic review of the PubMed database was performed using the following keywords: [bronchogenic cysts (Title)] and [stomach (Title)], but it yielded only 10 potentially relevant articles. Exclusion of articles without full text (n=3, English language) resulted in a final count of 6 articles, describing 8 cases (10-15), including the present case (Table I). BC of the stomach appeared to be a disease detected in older individuals (from 37 to 68 years of age) and there was no gender difference (4 females and 4 males). Cysts ranged in diameter from 1.5 to 15 cm. They were mostly located on the lesser curved side of the stomach and the second most frequent location was at the bottom and back of the stomach. Upper abdominal pain, nausea and vomiting were the most common complaints and symptoms. These are consistent with the findings described in the present report. Symptoms are usually related to enlarged cysts, secondary infections, perforations or compression of adjacent structures.

To date, the etiology and mechanisms of BC of the stomach remain to be fully elucidated. The occurrence of BC in the abdominal cavity may be explained as follows: In the early embryonic stage, the thoracic cavity and the abdominal cavity are connected by a pericardial abdominal cavity tube, and the abdominal cavity is divided into two separate cavities by fusion of the pleura and the peritoneum, which is a component of the diaphragm. In cases developing BC, the abnormal buds of the tracheobronchial tree were cutoff and migrated to the abdomen (13).

Accurate preoperative diagnosis remains a challenge and there are no characteristic changes in laboratory tests. No distinctive radiologic characteristics were apparent. On conventional imaging, such as CT, BC lesions present as definite cystic lesions with or without calcification (16). On MRI, lesions appear as equal to high intensity on T1-weighted images and high intensity on T2-weighted images (1,15,16). However, these imaging features are similar to GIST and are frequently misdiagnosed. Endoscopic ultrasonography (EUS) may help determine the exact location of the cyst in the stomach wall. CT- or EUS-guided biopsy may reveal mucus-like substances, providing clues for correct diagnosis. It should be performed as an important supplementary method to secure a definitive diagnosis in some cases (3,16). Possible complications include recurrence, ulceration, infection and hemorrhage.

To date, due to the small number of cases reported worldwide, no optimal treatment strategy for the clinical management of BC of the stomach has been established. In the reported cases, all patients underwent surgical resection of the BC of the stomach, and BC of the stomach with malignant transformation was rare. The possible pathology may be as follows: Chronic inflammation, repeated erosion and regeneration may lead to atypical hyperplasia or canceration (12,17).

Most patients with non-cancerous BC recovered well after surgery and there was no recurrence or metastasis during the follow-up.

A limitation of the present study was that no intraoperative images and photos of resected specimens were acquired. So far, there is no standard treatment for this rare disease. The review of the relevant literature as part of the present study indicated that surgery may be the best choice for diagnosis and treatment, as long as the patient's physical condition allows, but the choice of treatment should be based on the size, location and number of cystic lesions and the patient's physical condition. Further reports will enhance the current understanding of this rare disease and help improve its management.

### Acknowledgements

Not applicable.

### Funding

No funding was received.

### Availability of data and materials

The datasets used and/or analyzed during the current study are available from the corresponding author on reasonable request.

### Authors' contributions

BS analyzed the data, drafted the manuscript and critically revised the draft. AKW analyzed the data and critically discussed the results. HC and XKY performed the literature search and selection. BLQ performed the pathological analysis. YJ collected the clinical data. WGF and QL performed the operation and discussed the manuscript. WGF and JL were involved in the conception of the study and finalized the draft. All authors read and approved the final manuscript.

### Ethics approval and consent to participate

The present study was approved by the Ethics Committee of The Affiliated Hospital of Southwest Medical University (Luzhou, China; approval reference no. KY2019053).

### Patient consent for publication

Written consent was provided by the patient for the publication of his data and images.

### Competing interests

The authors declare that they have no competing interests.

### References

1. Tu C, Zhu J, Shao C, Mao W, Zhou X, Lin Q, Li Z, Zhang J, Zhou Q and Chen W: Gastric bronchogenic cysts: A case report and literature review. *Exp Ther Med* 11: 1265-1270, 2016.
2. Limaïem F, Ayadi-Kaddour A, Djilani H, Kilani T and El Mezni F: Pulmonary and mediastinal bronchogenic cysts: A clinicopathologic study of 33 cases. *Lung* 186: 55-61, 2008.

3. Sato M, Irisawa A, Bhutani MS, Schnadig V, Takagi T, Shibukawa G, Wakatsuki T, Imamura H, Takahashi Y, Sato A, *et al*: Gastric bronchogenic cyst diagnosed by endo-sonographically guided fine needle aspiration biopsy. *J Clin Ultrasound* 36: 237-239, 2008.
4. Hedayati N, Cai DX and Mchenry CR: Subdiaphragmatic bronchogenic cyst masquerading as an 'adrenal incidentaloma'. *J Gastrointest Surg* 7: 802-804, 2003.
5. Chhaidar A, Ammar H, Abdessayed N, Azzaza M, Gupta R, Abdennaceur N, Bdioui A, Mokni M and Ali AB: Large bronchogenic cyst of stomach: A case report. *Int J Surg Case Rep* 34: 126-129, 2017.
6. Liang MK, Yee HT, Song JW and Marks JL: Subdiaphragmatic bronchogenic cysts: A comprehensive review of the literature. *Am Surg* 71: 1034-1041, 2005.
7. Aktođu S, Yuncu G, Halilçolar H, Ermete S and Buduneli T: Bronchogenic cysts: Clinicopathological presentation and treatment. *Eur Respir J* 9: 2017-2021, 1996.
8. Petrina A, Boselli C, Cirocchi R, Covarelli P, Eugeni E, Badolato M, Finocchi L, Trastulli S and Noya G: Bronchogenic cyst of the ileal mesentery: A case report and a review of literature. *J Med Case Rep* 4: 313, 2010.
9. Gou Y, Wang YG, Fang H, Xu X, Yu W, Zhang K and Yu Y: Bronchogenic cyst in the hepatogastric ligament masquerading as an esophageal mesenchymal tumor: A case report. *Int J Clin Exp Pathol* 8: 15307-15311, 2015.
10. Keohane ME, Schwartz I, Freed J and Dische R: Subdiaphragmatic bronchogenic cyst with communication to the stomach: A case report. *Hum Pathol* 19: 868-871, 1988.
11. Song SY, Noh JH, Lee SJ and Son HJ: Bronchogenic cyst of the stomach masquerading as benign stromal tumor. *Pathol Int* 55: 87-91, 2005.
12. Shibahara H, Arai T, Yokoi S and Hayakawa S: Bronchogenic cyst of the stomach involved with gastric adenocarcinoma. *Clin J Gastroenterol* 2: 80-84, 2009.
13. Yang X and Guo K: Bronchogenic cyst of stomach: Two cases report and review of the English literature. *Wien Klin Wochenschr* 125: 283-287, 2013.
14. Han WG, Xue HD and Pan WD: Bronchogenic cyst of stomach: Report of one case. *Zhongguo Yi Xue Ke Xue Yuan Xue Bao* 41: 572-574, 2019 (In Chinese).
15. Sun L, Lu L, Fu W, Li W and Liu T: Gastric bronchogenic cyst presenting as a gastrointestinal stromal tumor. *Int J Clin Exp Pathol* 8: 13606-13612, 2015.
16. Belli S, Noyan T, Kayaselçuk F and Erbay G: Gastric duplication (bronchogenic) cyst mimicking a gastrointestinal stromal tumour. *Ulus Cerrahi Derg* 29: 35-37, 2013.
17. Murakami M, Machida M, Kobayashi Y, Ogura J, Ichikawa T and Kumazaki T: Retroperitoneal bronchogenic cyst: CT and MR imaging. *Abdom Imaging* 25: 444-447, 2000.



This work is licensed under a Creative Commons Attribution-NonCommercial-NoDerivatives 4.0 International (CC BY-NC-ND 4.0) License.