



Case Report

Traumatic gastric laceration with injury of splenic and celiac vessel following intentional self-harm by crashing of motor vehicle: A case report

Shiwani Sharma Acharya^{a,*}, Robin Man Karmacharya^b, Satish Vaidya^b,
Mahesh Mani Adhikari^a, Gaurav Upadhyay^a, Niroj Bhandari^a, Swechha Bhatt^a

^a Kathmandu University School of Medical Sciences, Dhulikhel Hospital, Dhulikhel, 45210, Nepal

^b Cardio-Thoracic and Vascular Surgery Unit, Department of Surgery, Kathmandu University School of Medical Sciences, Dhulikhel, 45210, Nepal



ARTICLE INFO

Keywords:

Abdominal injuries
Accident and emergency department
Case report
Lacerations
Splenoectomy
Vascular injuries

ABSTRACT

Intra-abdominal injury due to blunt trauma accounts for 5–10% of all traumatic cases. It usually occurs secondary to motor vehicle collision, pedestrian injury, and falls. Typically these result in injury to solid abdominal organs—liver and spleen, hollow visceral organs, and rarely the abdominal vasculature. Blunt abdominal trauma causing concurrent injury to the hepatic branch of the celiac artery and the associated vein along with gastric laceration is a rare presentation and has a high mortality rate, thereby warranting prompt evaluation. While the initial stabilization should follow Advanced Trauma Life Support guidelines, the adherence to nonoperative management or operative care depends upon the severity of the injury and the patient's clinical status. Here, we present an unusual case of gastric and splenic laceration with damage to the hepatic branch of celiac artery, splenic artery, and the associated vein following blunt abdominal trauma in a 12-year-old child following intentional self-harm by crashing a self-inflicted motor vehicle. Despite the negative preoperative radiological finding, the case was managed successfully with the laparotomic correction of the damaged stomach segment, splenoectomy, and repair of the damaged artery, and ligation of the transected vein to control hemorrhage.

1. Introduction

Abdominal vascular injury is rare and can be potentially lethal [1]. The etiology is usually due to penetrating injury and less commonly following blunt traumatic insult [1–3]. Abdominal vascular injury generally involves the superior mesenteric artery [2], while damage to the celiac artery is rare, representing only 1–2% of these cases [1]. The celiac artery and its branches provide supply to the vital organs of the foregut [2], therefore injury to this artery accounts for a high mortality rate [1].

Here, we present a case of a 12-year-old child with gastric and splenic injury along with damage to the hepatic branch of celiac trunk and transection of the associated vein managed successfully by splenoectomy, repair of the damaged viscera and artery, and ligation of the transected vein. This case report was written in line with SCARE guidelines [4].

2. Case report

A 12-year-old male presented to the Emergency Department due to blunt trauma following intentional self-harm by crashing of the tractor from a cliff of 10 m. There was a direct impact over the left side of the patient's abdomen upon landing on a graveled surface from a significant height. He complained of left sided chest pain and swelling over the left upper abdominal quadrant. There was no loss of consciousness, vomiting, abnormal body movement, and other significant external injuries. On further questioning, the visitors added that the patient was mentally disturbed following the demise of his father but they never sought professional help due to financial constraints.

On further evaluation, the child was conscious, however, he was hemodynamically unstable and in distress with pulse rate of 156 beats per minute, blood pressure of 90/60 mmHg and a respiratory rate of 28 breaths/min. Chest compression test, C-spine tenderness, and pelvic compression test were negative. Examination of the abdominal region

* Corresponding author.

E-mail addresses: shiwaniasharma1243@gmail.com (S.S. Acharya), reachrobin773@gmail.com (R.M. Karmacharya), satish.vaidya.nep@gmail.com (S. Vaidya), adhikarimmani1@gmail.com (M.M. Adhikari), Decgaurav1@gmail.com (G. Upadhyay), bhandariniroj15@gmail.com (N. Bhandari), swechhabhatt48@gmail.com (S. Bhatt).

<https://doi.org/10.1016/j.amsu.2022.103827>

Received 26 March 2022; Received in revised form 15 May 2022; Accepted 16 May 2022

Available online 24 May 2022

2049-0801/© 2022 The Authors. Published by Elsevier Ltd on behalf of IJS Publishing Group Ltd. This is an open access article under the CC BY-NC-ND license (<http://creativecommons.org/licenses/by-nc-nd/4.0/>).

revealed abrasions and bruising over the left upper quadrant with decreased chest movements and reduced air entry on the left side of the chest. On palpation, generalized abdominal tenderness with rigidity and rebound tenderness was present.

Extended Focused Assessment with Sonography in Trauma (E-FAST) showed the presence of non-sliding of the left pleura and collection of blood in the rectovesical pouch. Computed Tomography Scan of Chest and Abdomen revealed left-sided pneumothorax, gross pneumoperitoneum, and hemoperitoneum with possible bowel injury. However splenic injury couldn't be ruled out.

To gain hemodynamic stability, continuous infusion of intravenous fluids was done, followed by transfusion of two units of Packed Red Blood Cells (PRBC) over a duration of 4 h during the perioperative period. Emergency exploratory laparotomy was done on suspicion of underlying bowel perforation. Intraoperative findings were suggestive of laceration in the body of stomach near greater curvature of size 5×3 cm (Fig. 1) with collection of sanguineous fluid and food particles in the peritoneal cavity. Peritoneal wash was done followed by repair of the gastric laceration in two layers with polydioxanone 3-0 suture. 450 ml of sanguineous fluid was noted in the subhepatic drain and 50 ml of serosanguinous fluid in the chest drain.

Further exploration revealed another laceration of 1×5 cm near the hilum of the spleen. Due to the laceration and persistent bleeding from the spleen, splenectomy was done. Despite this, there was a continuous source of hemorrhage obscuring the operative field. Surprisingly, a rent in a hepatic branch of celiac artery of 3 mm size was discovered. It was repaired with prolene 6-0 suture. Moreover, there was also a partial (50%) transection of a branch of the associated vein, which was ligated. The liver, small bowel, and large bowel were grossly intact.

Immediate placement of the chest tube on the left side was performed for the left-sided pneumothorax which showed significant improvement. Following the procedure, the patient was kept Nil Per Oral (NPO) for two days, then gradually sips of liquid started. Flatus passed on the third day after which a soft diet was started. In the post-operative period, four units of PRBC and three units of fresh frozen plasma were transfused.

He developed two episodes of absence seizure on the fifth post-operative day with a drop in oxygen saturation to 65%. He was intubated and placed under mechanical ventilation for 6 days. He developed hoarseness of voice after extubation. CT scan of the head did not reveal any abnormalities. However, soft fluctuant swelling of size 2×2 cm was noticed just below the left costal margin. Frank pus was aspirated from the swelling suggestive of abscess. The pus culture showed methicillin-resistant coagulase-negative staphylococcal growth sensitive to vancomycin so he received a complete course of vancomycin. During his hospital stay, he received a pneumococcal vaccine. He improved gradually thereafter and was discharged on the nineteenth day of hospital

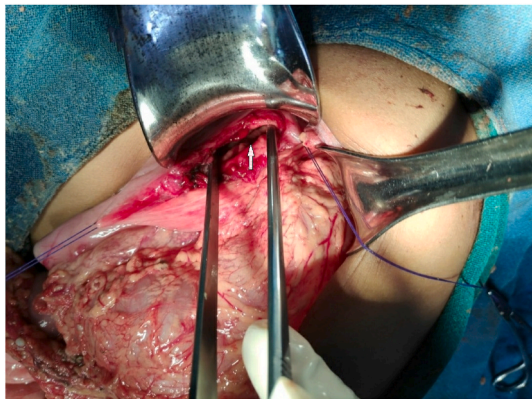


Fig. 1. Intraoperative finding showing gastric laceration (white arrow). The two lacerated ends of the stomach were held by the suture for a better view.

admission.

On one month's follow-up, the hoarseness of voice subsided gradually after speech therapy. Currently, the child is in an improved state of health and attends school regularly.

3. Discussion

Abdominal vascular injury is rare and potentially lethal [1]. Blunt abdominal vascular trauma usually results following motor vehicle crash, fall from height and crush injuries [2,3,5]. These can also result in damage to the solid visceral organs such as the liver, kidney, pancreas and mainly the spleen [6]. Moreover, blunt abdominal trauma with celiac artery injury is rare and has a mortality rate of around 75% [1]. These findings were consistent with our study wherein there was a splenic injury with gastric laceration following blunt abdominal trauma associated with damage to the celiac artery.

Celiac artery injury can have variable presentation including—avulsions, dissections, thrombosis, occlusion, pseudoaneurysm formation, and intimal tears or intimal flaps [2,5]. The anatomical correlation of celiac artery with Median Arcuate Ligament (MAL) explains the mechanism of blunt celiac artery injury [7]. Celiac artery arises from the aorta and is located just below the diaphragm at the level of the 12th thoracic vertebra [2] whereas MAL is the condensation of medial fibrous border of two crura of diaphragm, crossing the aorta higher to the origin of celiac artery [7]. As mentioned by Linuma et al., an increase in the intra abdominal pressure and rapid elevation of the diaphragm during blunt trauma causes compression of celiac artery against the median arcuate ligament of the diaphragm leading to dissection or avulsion or partial tearing of the artery [7]. Celiac artery injury can cause massive hemorrhage and ischemia to the organ supplied by it [2]. So it is very crucial for the clinicians for early diagnosis of such vascular injury for the better prognosis of the patient.

The management of celiac artery injury depends upon the type of injury, patient's clinical status, other associated injuries, alongside considering any underlying comorbidities, or vascular disease [5]. Conservative management is feasible when the patient is hemodynamically stable [5]. The treatment primarily starts with medical therapy with antiplatelet or anticoagulation agent [5]. Short-term anticoagulation helps to prevent thrombus progression [5]. Additionally, operative techniques such as primary repair, surgical bypass, endovascular stenting, open ligation of celiac artery are required for correction [5]. Open surgical ligation of the celiac artery is recommended in hemodynamically unstable patients following trauma and those undergoing damage control surgery [5]. All and all, the key to successful management is immediate proximal and distal control of the injured vessel by primary repair or revascularization [8,9].

The management of the solid organ injury following blunt abdominal trauma is nonoperative provided that the patient is hemodynamically stable [6]. However, operative management is performed in patients with ongoing hemorrhage indicated by hemodynamic instability with decreased hematocrit and increased requirement of transfusion [6]. Peritonitis, vascular injury, free air, pancreatic transection, and any suspected bowel injury are considered for operative intervention [6]. In our case, the patient was hemodynamically unstable at the time of presentation and bowel injury was detected by EFAST and confirmed by CT scan of the chest and abdomen which was an indication for operative intervention. Splenectomy was performed for intraoperative detection of splenic laceration near the hilum due to continuous bleeding from the spleen. Whereas, celiac vessel injury—detected intraoperatively was managed by repair of the injured hepatic branch of celiac artery and ligation of partially transected vein.

Studies have recommended a second-look surgery in case of further deterioration of the condition following surgical management [10]. In our case, the celiac artery injury was detected during laparotomy and primary repair was done. Since the patient was stable following initial surgical repair, so second-look surgery was not mandatory.

In another retrospective study, 13 patients with confirmed celiac artery injury, the mechanism of injuries was penetrating in 12 (92%) and blunt in 1 (8%) with a survival rate of 38% among these cases. All the patients underwent surgical management in which 11 patients underwent ligation and 1 patient underwent repair of celiac artery [8]. In our case, repair of the celiac artery was performed along with ligation of the transected celiac vein.

In a case study involving 11 patients with abdominal vascular injury, the most common age group was 45 years with a minimum age of 17 years [5]. Unlike their case study, our patient belonged to a pediatric age group—12 years, which has been rarely reported.

For the diagnosis of splenic injury, a hospital based study has revealed that contrast enhanced imaging or intraoperative injury detection are reliable techniques [11]. They added that Contrast-enhanced CT scan has a significant role in the diagnosis of splenic parenchymal injury and vascular injuries [11]. However, a plain CT scan of the abdomen was performed in our case, which might have led to delayed identification of splenic and celiac vessel injury. Additionally, inadequate bowel preparation owing to an emergency condition could be considered as another factor for the delayed detection.

Other authors have also reported associated injuries along with celiac axis injury. A study mentioned that celiac artery disruption with concurrent splenic laceration and associated pelvic fractures and bowel herniation through pelvis [12]. Li et al. in their study mentioned about celiac artery dissection with a splenic laceration near the lower pole following blunt trauma [13]. In the very case, the celiac dissection was diagnosed on the fourth day of injury by repeat CT abdominal angiography that was performed with respect to increasing abdominal pain of the patient and was managed conservatively considering the hemodynamic stability of the patient [13]. In contrast to their case, our patient sustained celiac vessel injury with a concurrent gastric laceration and splenic laceration near the hilum, therefore the surgeons opted on performing splenectomy.

All things considered, this is a rare presentation owing to the patient's age, presence of abdominal vascular injury despite negative preoperative radiological findings, and the repair of the celiac artery as the core step in management without the need of second-look surgery—yielding a good outcome.

4. Conclusion

Injuries to intra-abdominal viscera are rare and have a high mortality rate. High clinical suspicion of concealed vascular injury should be made if there is persistent oozing of blood despite surgical repair, and negative preoperative radiological findings.

Ethical approval

We have obtained written consent from the patient's mother for the publication of this case report.

Sources of funding

None.

Declaration of competing interest

No conflict of interest.

Author contribution

All authors contributed equally to the manuscript preparation.

Consent

Written informed consent was obtained from the patient for

publication of this case report and accompanying images. A copy of the written consent is available for review by the Editor-in-Chief of this journal on request.

Registration of research studies

N/A.

Provenance and peer review

Not commissioned, externally peer-reviewed.

Patient perspective

After explaining to the patient about the entire project and its benefit for clinicians and patients globally, the patient was happy and gave us consent for the publication of this case report.

Conflicts of interest

There are no conflicts of interest.

Sources of funding for your research

None.

Ethical approval

Written informed consent was obtained from patient.

Consent

Written expressed consent was taken from patient.

Author contribution

Shiwani Sharma Acharya: manuscript writing and editing. Robin Man Karmacharya: Surgical procedure, Patient care, guarantor. Satish Vaidya: Surgical procedure, Patient care. Mahesh Mani Adhikari: Surgical procedure, Patient care. Gaurav Upadhyay: Manuscript editing. Niroj Bhandari: Manuscript editing. Swechha Bhatt: manuscript writing and editing.

Registration of research studies

N/A.

Guarantor

Dr. Robin Man Karmacharya.

Acknowledgements

N/A.

Appendix A. Supplementary data

Supplementary data to this article can be found online at <https://doi.org/10.1016/j.amsu.2022.103827>.

References

- [1] J.A. Asensio, S. Chahwan, D. Hanpeter, et al., Operative management and outcome of 302 abdominal vascular injuries, *Am. J. Surg.* 180 (2000) 528–533, discussion 533–4.

- [2] C. Kirchoff, J. Stegmaier, M. Krotz, et al., Celiac dissection after blunt abdominal trauma complicated by acute hepatic failure: case report and review of literature, *J. Vasc. Surg.* 46 (2007) 576–580.
- [3] T.P. Davis, D.V. Feliciano, G.S. Rozycki, et al., Results with abdominal vascular trauma in the modern era, *Am. Surg.* 67 (2001) 565–570, discussion 570–1.
- [4] R.A. Agha, T. Franchi, C. Sohrabi, et al., The SCARE 2020 guideline: updating consensus surgical CAse REport (SCARE) guidelines, *Int. J. Surg.* 84 (December 2020), <https://doi.org/10.1016/j.ijsu.2020.10.034>. Epub ahead of print.
- [5] M.D. Kronick, A.R. Doben, M.E. Morris, et al., Blunt traumatic celiac artery avulsion managed with celiac artery ligation and open aorto-celiac bypass, *Trauma Case Rep.* 11 (2017) 8–12.
- [6] M. Tataria, M.L. Nance, J.H. Holmes, et al., Pediatric blunt abdominal injury: age is irrelevant and delayed operation is not detrimental. *Journal of trauma: injury, Infection Critical Care* 63 (2007) 608–614.
- [7] Y. Linuma, Y. Yamazaki, Y. Hirose, et al., A case of isolated celiac axis injury by blunt abdominal trauma, *J. Trauma* 61 (2006) 451–453.
- [8] J.A. Asensio, P. Petrone, B. Kimbrell, et al., Lessons learned in the management of thirteen celiac axis injuries, *South. Med. J.* 98 (2005) 462–466.
- [9] Z. Osborne, U.J. Oliphant, J. Aucar, et al., Celiac artery avulsion secondary to blunt trauma: a case report and review of the literature, *J. Med. Cases* 4 (2013) 280–283.
- [10] J.A. Asensio, W. Forno, G. Roldán, et al., Visceral vascular injuries, *Surg. Clin.* 82 (2002) 1–20, xix.
- [11] D.R. Murken, J.J. Weis, G.C. Hill, et al., Radiographic assessment of splenic injury without contrast: is contrast truly needed? *Surgery* 152 (2012) 676–682, discussion 682–4.
- [12] D.B. Brown, H. Singh, R.G. Atnip, et al., Blunt traumatic injury to the superior mesenteric artery and celiac axis, *J. Vasc. Intervent. Radiol.* 9 (1998) 783–785.
- [13] B.V. Li, R.D. Prabha, M. Narra, et al., Traumatic dissection of the coeliac artery and splenic injury following blunt trauma, *BMJ Case Rep.* 12 (2019), e229405.