

MAJEWSKI OSTEODYSPLASTIC PRIMORDIAL DWARFISM TYPE II: CLINICAL FINDINGS AND DENTAL MANAGEMENT OF A CHILD PATIENT*

Majewski Osteodisplastik Primordial Cücelik Tip II: Bir Çocuk Hastanın Klinik Bulguları ve Dental Rehabilitasyonu

Arslan TERLEMEZ¹, Mustafa ALTUNSOY², Hakkı ÇELEBİ³

Received: 09/03/2013

Accepted: 11/12/2014

ABSTRACT

Majewski osteodysplastic primordial dwarfism type II (MOPD II) is an unusual autosomal recessive inherited form of primordial dwarfism, which is characterized by a small head diameter at birth, but which also progresses to severe microcephaly, progressive bony dysplasia, and characteristic facies and personality. This report presents a case of a five-year-old girl with MOPD II syndrome. The patient was referred to our clinic with the complaint of severe tooth pain at the left mandibular primary molar teeth. Clinical examination revealed that most of the primary teeth had been decayed and all primary teeth were hypoplastic. Patient's history revealed delayed development in the primary dentition and radiographic examination showed rootless primary molar teeth and short-rooted incisors. The treatment was not possible due to the lack of root of the left mandibular primary molars; so the teeth were extracted. Thorough and timely dental evaluation is crucial for the prevention of dental problems and the maintenance of oral health in patients with MOPD II syndrome is of utmost importance.

Keywords: Majewski, Osteodysplastic, Primordial Dwarfism Type II

ÖZ

Mikrosefalik osteodisplastik primordial cücelik tip II (MOPCII), küçük kafa ölçüleri ile doğum ve ilerleyen ciddi mikrosefali, ilerleyen kemik displazisi ve tipik yüz ve kişilik farklılıkları ile karakterize, otozomal çekinik olarak aktarılan ve nadir görülen bir cücelik tipidir. Bu olgu sunumunda, MOPC II sendromlu beş yaşında bir kız bildirilmektedir. Hasta, kliniğimize sol mandibular molar süt dişlerde şiddetli diş ağrısı ile başvurdu. Klinik incelemede birçok süt dişinin çürük olduğu ve dişlerin hipoplastik olduğu görüldü. Sol alt süt molar dişler köksüz olduğu için tedavi edilmesi mümkün değildi ve bu dişler çekildi. MOPC II sendromlu hastaların dişlerinin doğru ve zamanında değerlendirilmesi, bu hastalarda dişsel problemlerin önlenmesi ve ağız sağlığının sürdürülebilmesi için büyük önem taşımaktadır.

Anahtar kelimeler: Majewski, Osteodisplastik, Primordial cücelik Tip II

¹ Department of Endodontics Faculty of Dentistry Necmettin Erbakan University

² Department of Pediatric Dentistry Faculty of Dentistry Sifa University

³ Department of Prosthodontics Faculty of Dentistry Necmettin Erbakan University

*This study was an oral presentation at the 18th BASS Congress, 23-27 April 2013, Skopje, Macedonia



Introduction

Majewski or micro cephalic osteodysplastic primordial dwarfism type II is a rare autosomal recessive transferred form of primordial dwarfism (PD) characterized by serious prenatal and postnatal growth retardation (1, 2). Primordial dwarfism is a very heterogeneous group of disorder and it has been classified into three main types: Seckel syndrome, microcephalic osteodysplastic primordial dwarfism (MOPD) type I/III and type II (3, 4).

MOPDs are autosomal recessive pericentromeric (PCNT) gene disruption disorders (5) distinctive by pre- and postnatal growth retardation, microcephaly, and characteristic facial gestalt with prominent billed nose and micrognathia (4, 6). Type II MOPD is the most common type of primordial dwarfisms with more than 90 patients reported so far (1, 7-13). Characteristic features of MOPD II are peculiar growth pattern with very severe intrauterine growth retardation and adult height below 110 cm, neonatal proportioned head size later progressing to microcephaly, absent or mild mental retardation, and typical bone dysplasia (1). Dental anomalies, skin pigmentation and obesity may also be seen together with cerebral vascular anomalies (7). Other clinical hallmarks of MOPD II are stocky build with somewhat short extremities, progressive loose-jointedness and other minor skeletal anomalies, high-pitched nasal voice, cheerful personality, and enamel dysplasia or microdontia (14).

There are no effective treatments for PD yet. It is known that PD is caused by inheritance of a mutant gene from both parents. The lack of normal growth in the disorder is not due to a deficiency of growth hormone, as in hypo-pituitary dwarfism (7). Therefore, applying growth hormone to these patients has little or no effect on the growth of the individual with PD (7, 12). In 2008, the mutations in the PCNT gene were found to cause PD. PCNT has a role in cell division, cytokinesis, and proper chromosome segregation (12, 14).

Due to a high risk for cerebral vessel insults, early onset diabetes and cardiomyopathy, patients with MOPD II have limited life expectancy (12, 13). For adequate preventive disease management, it is essential to establish the correct diagnosis in an individual with primordial dwarfism (14). Herein, clinical findings with emphasis on the distinctive dental anomalies of a child patient with MOPD II are reported.

Case report

A five-year-old female patient was referred to our clinic with complaints of tooth pain and mobility in the left mandibular primary first and second molar teeth. Before the initiation of the therapy, informed consent was taken from her family. Except for the MOPD II features, she was born healthy. Her parents were distant relatives and the mother was 33 and the father was 37 years old. The older sister was fourteen years old and was not affected by MOPD II syndrome. On clinical examination, she was proportionally short (Figure 1).

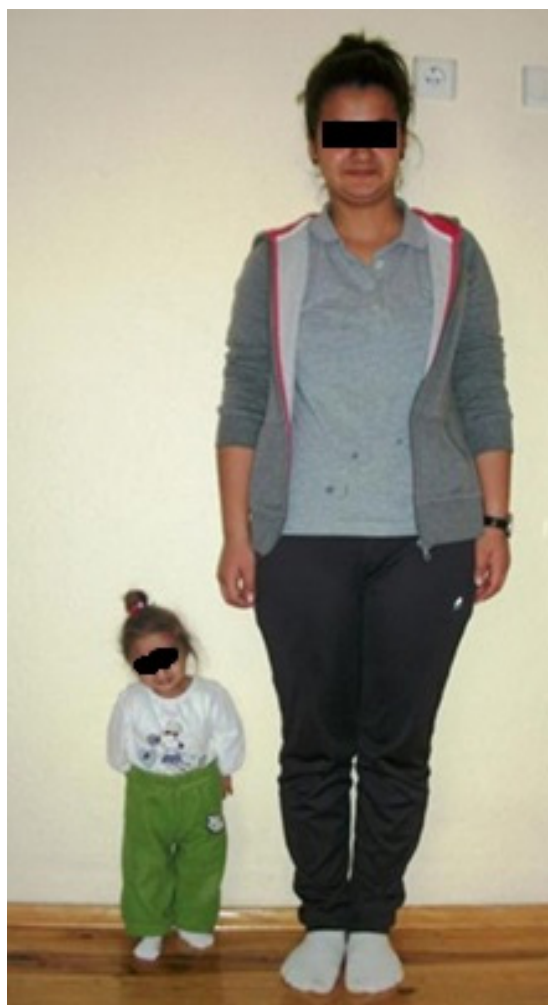

Figure 1. The patient with MOPD II at left and her older sister at right. Patient is five years old and the older sister is fourteen years old. Relatively proportionate short stature is noted.

The patient was born 6 weeks earlier than the normal birth time. Psychomotor development was retarded and she sat alone at 12 months and walked alone at 30 months. Her chest was narrow, the scapula and pelvis were hypoplastic and all bones were slender (Figure 2). Her elbows were bent, and the fingers and

thumbs were short (Figure 3). Her hair was dry and thin. The large nose with a prominent nasal bridge was observed (Figure 4). Pinnae were small. Hearing was normal. She had a high-pitched voice. Intelligence was normal (Table 1). Shows some physical measurements of the present case and normal children at her age.

Table 1. Measurements of the patient and normal children.

	Patient's values	Normal values for females
Current Height (Age 5)	61 cm	108 cm (Age 5)
Current Weight (Age 5)	4.5 kg	18 kg (Age 5)
Birth Length	35 cm	50 cm
Birth Weight	920 g	3300 g
Birth Head Circumference	31 cm	38 cm
Current Head Circumference (Age 5)	36.5 cm	51 cm (Age 5)

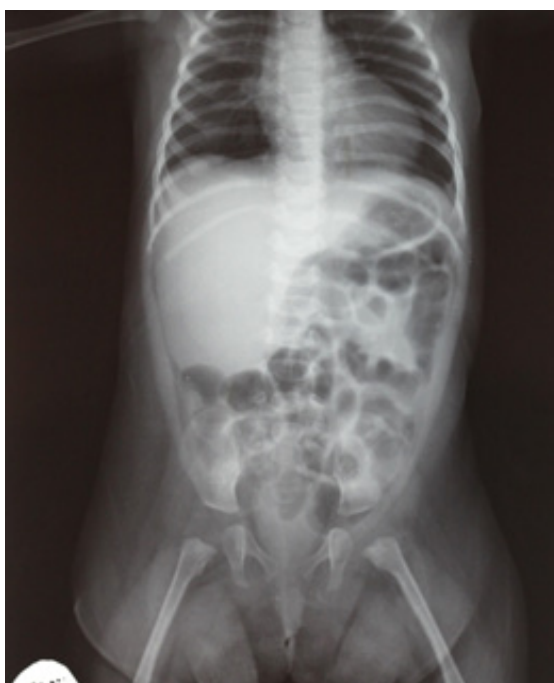


Figure 2. Patient's chest radiograph at age 2 shows narrow chest, hypoplastic scapula, hypoplastic pelvis and slender bones.

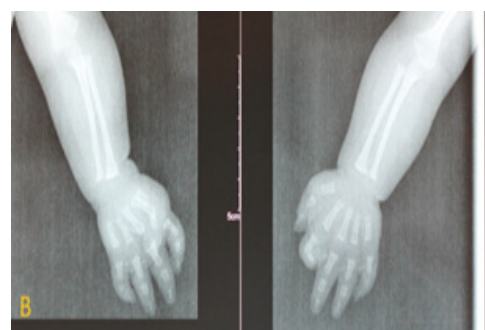
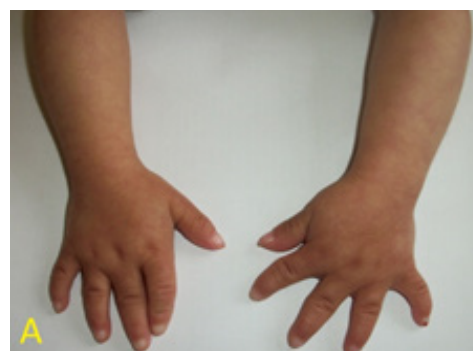

Figure 3. Hand photo of the patient at age 5 (A) and hand radiograph of the patient at age 2 (B).

Dental Management of a Dwarf Child Patient

The mouth was extremely small. Oral examination elicited generalized microdontia and opalescent teeth. The patient's first tooth had erupted at 30 months and all deciduous teeth had erupted later than the normal eruption time. Oral hygiene was poor and there were

many decayed teeth (Figure 4). All teeth were hypoplastic and there were increased spaces between the teeth in maxilla but the spaces between the teeth in mandibula were normal (Figure 4).

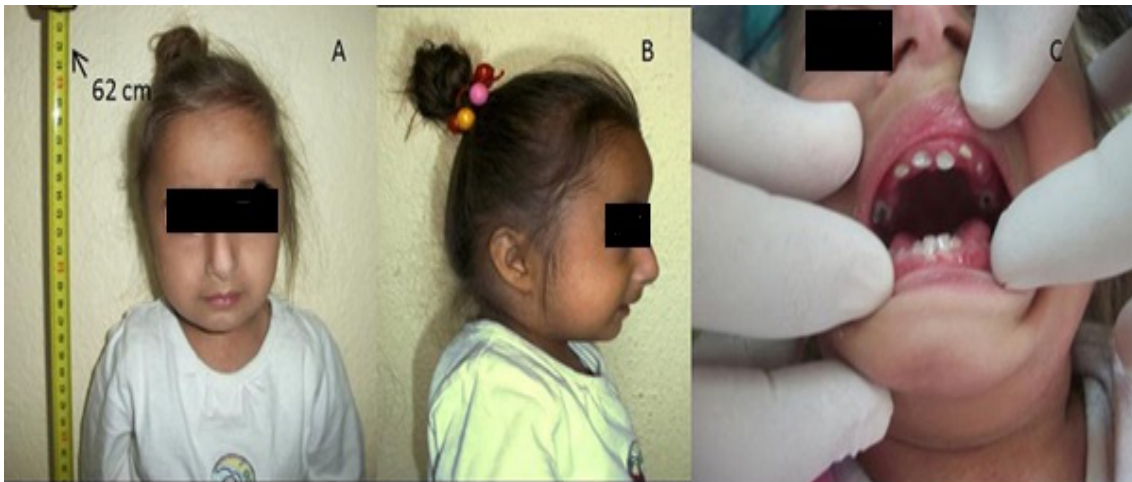

Figure 4. (A) Her height is only 62 cm. (B) Large and prominent nose and small pinnae. Hair is thin and dry. (C) Oral examination of the patient revealed small incisors and posterior teeth with severe caries.

The patient was not cooperative enough to get a panoramic radiograph and the parents did not allow additional radiographs of their daughter to be taken. Therefore, the existing lateral cephalometric radiograph that had been taken at age 2 and newly

obtained periapical radiographs were used to evaluate the dental situation. Radiographic examination revealed rootless primary molars, and most deciduous incisors appeared to have premature exfoliation (Figure 5).

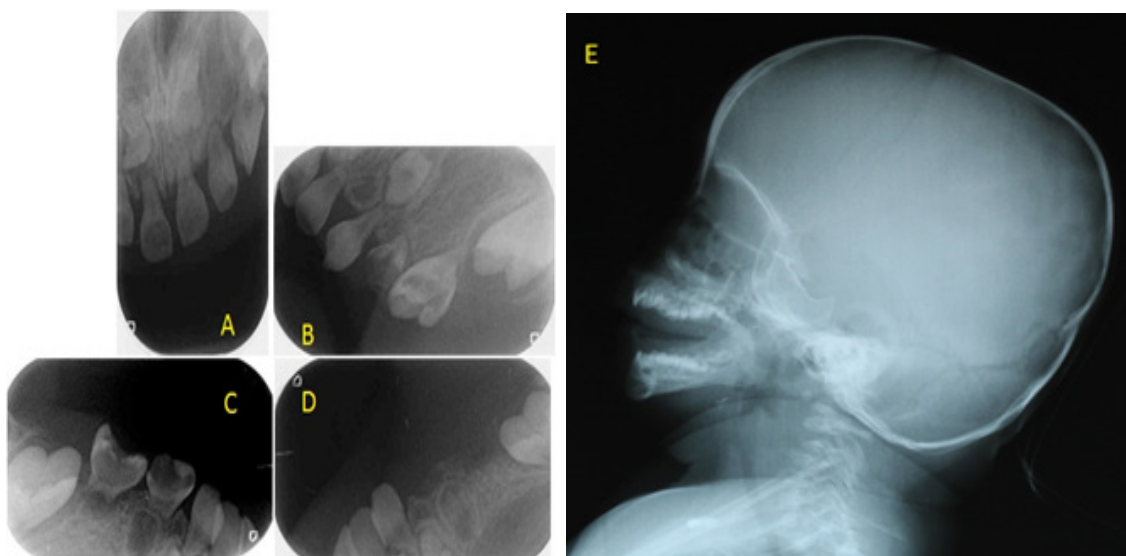


Figure 5. Periapical (A,B,C,D) and lateral cephalometric (E) radiographs show short-rooted incisors, rootless primary molars, micrognathia and hypoplastic alveolar bone. (D) shows the extraction area after two weeks. In (E), large sella turcica and premature closure of cranial sutures are observed.

The crowns of the primary molars were tapered occluso-cervically. The conservative treatment of the left mandibular first and second primary molar teeth was not possible due to their rootlessness, so these

teeth were extracted. After two weeks, the extraction area was healthy (Figures 6A and 6B).

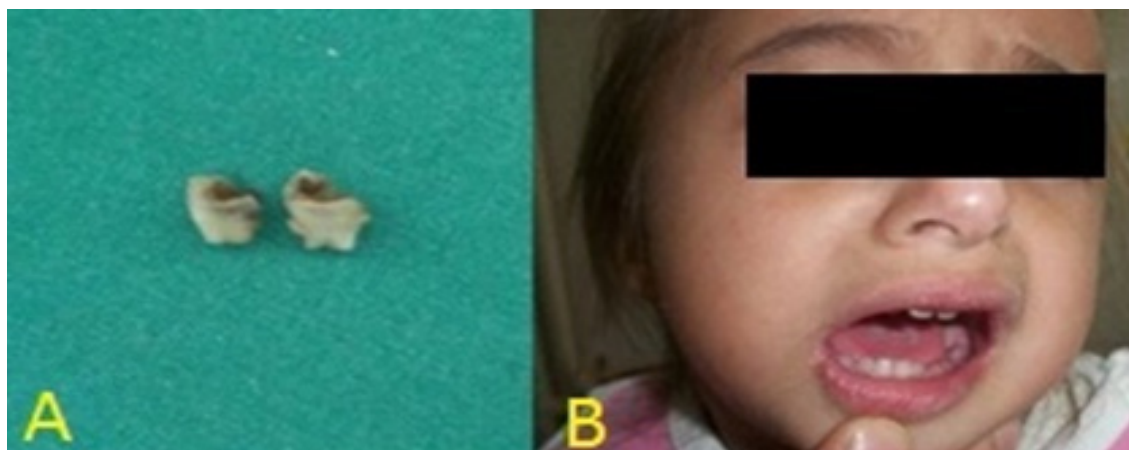

Figure 6. (A) Extracted teeth. (B) Extraction area after two weeks.

Discussion

Patients with MOPD II present different craniofacial features, consisting of prominent nose with hypoplastic alae nasi, small mouth, small and dysplastic pinnae, and sparse hair. Truncal obesity, esotropia, farsightedness, mild developmental delay, astigmatism, abnormal pigmentation of skin and acanthosis nigricans around the neck are additional features of MOPD II (2).

MOPD II, which is a rare syndrome, has been presented based on only about 90 affected individuals (1, 7-13). A case of a Turkish girl with MOPD II is reported in the present article. The severity of hypoplasia of the teeth and microdontia found in this patient was remarkable. The patient compliance was very poor and the parents were anxious about their daughter's health and did not permit us to take additional radiographs. The patient's mouth was too small to place a photo mirror, so extra oral photos had to be taken.

The combination of hypoplastic alveolar processes, microdontia, short-rooted incisors, and rootless molar teeth has been described in MOPD (2, 7, 8, 15). In the current case report, the female patient with MOPD II syndrome was characterized by microdontia in the primary dentition. Her permanent teeth had not erupted. Normal eruption time of the first primary tooth was around 6 months. The patient's first primary tooth has been erupted at 30

months, indicating delayed dental development in the primary dentition. Deleval and Doxsey (5) reported that the phenotype caused by PCNT gene mutations might represent a role for dysfunction of spindle in primordial dwarfism. The disruption of pericentrin would induce mislocalization of proteins, which is crucial for microtubule nucleation or organization, and subsequently cause mitotic spindle defects, mitotic failure, chromosome missegregation, cell arrest, and/or cell death (5, 12). The malformation and the small sizes of the teeth found in the current patient with MOPD II might have been the results of loss of microtubule integrity which caused defective centrosome function. (2, 5). This female child had many carious teeth, possibly due to poor oral hygiene and the malformation of the teeth. It was also reported that the patients with MOPDII tend to lose their teeth at early ages (2, 7). The findings presented in this case report emphasize the importance of early preventive measures in these patients.

Conclusion

Dental treatment of patients with MOPDII syndrome might be difficult because of small mouth, rootless teeth, and poor oral hygiene. In these patients, dental development is defective and teeth tend to decay. Because of retardation in physical development, oral hygiene habits are inadequate. Due to ineffective mastication and hypoplastic teeth, the

patients are constrained to be fed soft and cariogenic foods. Thus, MOPDII patients and their families should be careful with oral hygiene measures for long-term maintenance.

Source of funding

None declared

Conflict of interest

None declared

References

1. Brancati F, Castori M, Mingarelli R, Dallapiccola B. Majewski osteodysplastic primordial dwarfism type II (MOPD II) complicated by stroke: clinical report and review of cerebral vascular anomalies. *Am J Med Genet A* 2005;139(3):212-215.
2. Kantaputra P, Tanpaiboon P, Pornaveetus T, Ohazama A, Sharpe P, Rauch A, Hussadaloy A, Thiel CT. The smallest teeth in the world are caused by mutations in the PCNT gene. *Am J Med Genet A* 2011;155A(6):1398-1403.
3. Meinecke P, Passarge E. Microcephalic osteodysplastic primordial dwarfism type I/III in sibs. *J Med Genet* 1991;28(11):795-800.
4. Majewski F, Goecke TO. Microcephalic osteodysplastic primordial dwarfism type II: report of three cases and review. *Am J Med Genet* 1998;80(1):25-31.
5. Delaval B, Doxsey SJ. Pericentrin in cellular function and disease. *J Cell Biol* 2010;188(2):181-190.
6. Majewski F, Ranke M, Schinzel A. Studies of microcephalic primordial dwarfism II: the osteodysplastic type II of primordial dwarfism. *Am J Med Genet* 1982;12(1):23-35.
7. Hall JG, Flora C, Scott CI, Jr., Pauli RM, Tanaka KI. Majewski osteodysplastic primordial dwarfism type II (MOPD II): natural history and clinical findings. *Am J Med Genet A* 2004;130A(1):55-72.
8. Kantaputra PN, Tanpaiboon P, Unachak K, Praphanphoj V. Microcephalic osteodysplastic primordial dwarfism with severe microdontia and skin anomalies: confirmation of a new syndrome. *Am J Med Genet A* 2004;130A(2):181-190.
9. Kannu P, Kelly P, Aftimos S. Microcephalic osteodysplastic primordial dwarfism type II: a child with cafe au lait lesions, cutis marmorata, and moyamoya disease. *Am J Med Genet A* 2004;128A(1):98-100.
10. Young ID, Barrow M, Hall CM. Microcephalic osteodysplastic primordial short stature type II with cafe-au-lait spots and moyamoya disease: another patient. *Am J Med Genet A* 2004;127A(2):218-220.
11. Ozawa H, Takayama C, Nishida A, Nagai T, Nishimura G, Higurashi M. Pachygyria in a girl with microcephalic osteodysplastic primordial short stature type II. *Brain Dev* 2005;27(3):237-240.
12. Rauch A, Thiel CT, Schindler D, Wick U, Crow YJ, Ekici AB, van Essen AJ, Goecke TO, Al-Gazali L, Chrzanowska KH, Zweier C, Brunner HG, Becker K, Curry CJ, Dallapiccola B, Devriendt K, Dörfler A, Kinning E, Megarbane A, Meinecke P, Semple RK, Spranger S, Toutain A, Trembath RC, Voss E, Wilson L, Hennekam R, de Zegher F, Dörr HG, Reis A. Mutations in the pericentrin (PCNT) gene cause primordial dwarfism. *Science* 2008;319(5864):816-819.
13. Bober MB, Khan N, Kaplan J, Lewis K, Feinstein JA, Scott CI, Jr., *et al.* Majewski osteodysplastic primordial dwarfism type II (MOPD II): expanding the vascular phenotype. *Am J Med Genet A* 2010;152A(4):960-965.
14. Rauch A. The shortest of the short: pericentrin mutations and beyond. *Best Pract Res Clin Endocrinol Metab* 2011;25(1):125-130.
15. Kantaputra PN. Apparently new osteodysplastic and primordial short stature with severe microdontia, opalescent teeth, and rootless molars in two siblings. *Am J Med Genet* 2002;111(4):420-428.

Corresponding Author:

Arslan TERLEMEZ

Department of Endodontics

Faculty of Dentistry

Necmettin Erbakan University

Konya, TURKEY

Phone: 0 332 220 0025

e-mail: arslanterlemez@gmail.com