



Since January 2020 Elsevier has created a COVID-19 resource centre with free information in English and Mandarin on the novel coronavirus COVID-19. The COVID-19 resource centre is hosted on Elsevier Connect, the company's public news and information website.

Elsevier hereby grants permission to make all its COVID-19-related research that is available on the COVID-19 resource centre - including this research content - immediately available in PubMed Central and other publicly funded repositories, such as the WHO COVID database with rights for unrestricted research re-use and analyses in any form or by any means with acknowledgement of the original source. These permissions are granted for free by Elsevier for as long as the COVID-19 resource centre remains active.



COVID-19: Important Updates and Developments
 Edited by Franco Rongioletti, MD, and Leonard J. Hoenig, MD

Cutaneous adverse effects of the available COVID-19 vaccines



Georgi Bogdanov, MD, PhD^{a,*}, Ivan Bogdanov, MD, PhD^b, Jana Kazandjieva, MD, PhD^c, Nikolai Tsankov, MD, PhD^b

^a Department of Pharmacology and Toxicology, Medical University Sofia, Sofia, Bulgaria

^b Acibadem City Clinic Tokuda Hospital, Sofia, Bulgaria

^c Department of Dermatology and Venerology, Medical University Sofia, Sofia, Bulgaria

Abstract Vaccination has played a crucial role in the improvement of global health. Some of the world's deadliest diseases, like smallpox and rinderpest, have been eradicated with the help of vaccines, and many others have been restrained. The appearance of the strain of coronavirus disease 2019 (COVID-19) severe acute respiratory syndrome coronavirus 2 and its impact on global health have made the development of effective and safe vaccines crucial for this new lethal disease. So far, there are three main types of COVID-19 vaccines in use around the world: messenger RNA-based vaccines, adenoviral vector vaccines, and inactivated whole-virus vaccines. Some of them have passed through phase 3 of safety and efficacy trials and are widely used for prophylaxis of COVID-19 infection. A plethora of cutaneous adverse events have been reported, most of them mild or moderate injection-site reactions. Some rare delayed inflammatory reactions such as "COVID arm" have also been reported, posing questions on their pathophysiology and clinical importance. Some rare serious adverse events, such as vaccine-induced prothrombotic immune thrombocytopenia and anaphylaxis, have been described raising great concerns on the safety of some widely spread vaccines. More data need to be collected with further and more detailed analysis. The overall risk of such severe adverse reactions remains extremely low, and the benefits of the existing vaccines in combating the widespread threat of COVID-19 continue to outweigh the risk of their side effects.

© 2021 Elsevier Inc. All rights reserved.

Introduction

Vaccination has played a crucial role in the improvement of global health.¹ Smallpox, a deadly infectious disease, has been eradicated by vaccines. At the same time, there are worries about possible reactions to vaccines. The frequency of reported vaccine-induced adverse events is low and ranges between 4.8 to 83.0 per 100 000 doses of the most

commonly used vaccines. The exact number of genuine allergic reactions to the usual vaccines is not determined, but the estimations vary between one per 500,000 to one per 1 million doses for most vaccines. When the vaccines contain gelatin or egg proteins as in those for influenza, measles, mumps, and rubella virus, rabies, and yellow fever, the serious allergic reactions might be more common, but still, the life-threatening cases of anaphylaxis remain rare (roughly 1 per 1.5 million doses).²

The appearance of the strain of COVID-19 severe acute respiratory syndrome coronavirus 2 (SARS-CoV-2) and its impact on global health have made the development of ef-

* Corresponding author.

E-mail address: dr.georgi.bogdanov@gmail.com (G. Bogdanov).

fective and safe vaccines crucial for this new lethal strain.³ Until the end of March 2021, the COVID-19 pandemic had affected 219 countries and territories, 125 million people had been infected, and more than 2.7 million had died from this virus. SARS-CoV-2 consists of four structural proteins:

1. S-spike protein (outer spiky glycoprotein);
2. Envelope protein (E);
3. Membrane glycoprotein (M); and
4. Nucleocapsid protein (N), which can interfere with the host's immune system, enhancing the attachment and transportation into the host cells.⁴

SARS-CoV-2 enters the host cells by binding to angiotensin-converting enzyme (ACE)-2 receptors, although the protease transmembrane protease, serine 2 (TMPRSS2) might also play a role.⁵ The S protein is the main target for most of the currently available vaccines.

So far, there are three main types of COVID-19 vaccines in use around the world:

1. Messenger ribonucleic acid (mRNA) vaccines: BNT162b2 (Pfizer-BioNTech, New York, New York) and mRNA-1273 (Moderna, Inc., Cambridge, Massachusetts)
2. Adenoviral vector vaccines: ChAdOx1 nCoV-19 (AstraZeneca-Oxford), Gam-COVID-Vac (Gamaleya National Centre of Epidemiology and Microbiology), Ad26.COVS.2.S (Janssen Pharmaceuticals, Inc), and Ad5-nCoV (CanSinoBIO)
3. Inactivated whole-virus vaccines: BBIBP-CorV (Sinofarm) and CoronaVac (Sinovac Life Sciences)

In the mRNA vaccines, short-lived synthetically produced molecules of the RNA sequence transfected (infected by transformation) by COVID-19 are injected into the subject.⁴ After the intramuscular injection, the transfected RNA molecules are taken by the antigen-presenting cells, and this induces an immune response. The vaccine's mRNA is transferred to the ribosomes of the host cells, and the spike protein is translated and exposed on the surface of the cells, which later triggers the immune response. The spike protein molecules stimulate adaptive immune responses that can further identify and destroy the corresponding pathogen.⁶ The mRNA is covered with lipid microvesicles (liposomes) which protect it from degradation and carry it into the human cells. As a result, mRNA vaccines mimic the natural infection with the virus, retaining only a short synthetic viral mRNA that encodes the required antigen.⁴ The mRNA vaccines are easier to create and design, faster to produce, and are able to stimulate strong humoral and cellular immunity. The steps leading to the production of mRNA are simple, fast, and most importantly, robust, which means that they do not depend on the mRNA sequence.⁷ To date, the mRNA vaccines demonstrate the strongest efficacy against infection with the virus.

The adenoviral vector vaccines use adenoviruses from chimpanzees or gorillas to deliver a DNA gene unique to the virus which encodes the spike protein. The reason why non-

human adenoviruses are used is to avoid the risk of preexisting immunity against the vector and to increase their efficacy.⁴ Once inside the human cell, the viral vector uses the gene and the cell's mechanism to produce the spike protein which is later displayed on the cell's surface. The exposed S protein triggers an immune response. The adenoviral vector COVID-19 vaccines show varying efficacy against infection with SARS-CoV-2, but they demonstrate strong protection from severe disease and death.⁸⁻¹⁰

The inactivated whole-virus vaccines are based on a living virus that has been killed or inactivated, and thus, is not able to cause clinical disease. These are the oldest and most studied types of vaccines so far. Inactivated virus vaccines are usually made by exposure of a virulent virus to chemical or physical agents—for example, formalin or β -propiolactone—to destroy infectivity while retaining immunogenicity.¹¹ Their major disadvantage is the need to use large amounts of antigens to obtain an adequate antibody response. These vaccines induce an immune response directed against many SARS-CoV-2 antigens, not only against the S protein. The inactivation process decreases the immunogenicity, and this requires the use of special adjuvants such as aluminum.¹² These live attenuated vaccines are employed to protect against mumps, measles, rubella, and varicella. The inactivated vaccines are not widely used for COVID-19 prophylaxis and do not enter the scope of this contribution.

All three types of COVID-19 vaccines can cause large spectra of vaccine-related adverse reactions. The most common side effects are limited to the injection site and are due to nonspecific stimulation of inflammation.

Injection-site reactions

Just as in other vaccines, the COVID-19 vaccines often cause cutaneous reactions close to the injection site including redness and swelling (Figure 1).¹³

Until the end of 2020, other skin injection-site reactions, such as injection-site urticaria and an injection-site maculopapular dermatitis, have been reported for the Moderna vaccine.^{13,14}

Type I hypersensitivity reactions

Type I immunoglobulin E-mediated allergic reactions to vaccines are rarely induced by the vaccine's antigens and are usually caused by inactive ingredients such as egg protein, formaldehyde, gelatin, thimerosal, or neomycin.⁴ According to the European Medicines Agency (EMA), the excipients are constituents of a pharmaceutical form apart from the active substance. The excipients (originates from the Latin "*excipere*" which means to receive) are inactive substances that serve as the vehicle or medium for a drug or other active substance. Their purpose is to improve stability and absorption, increase solubility, influence palatability, or cre-

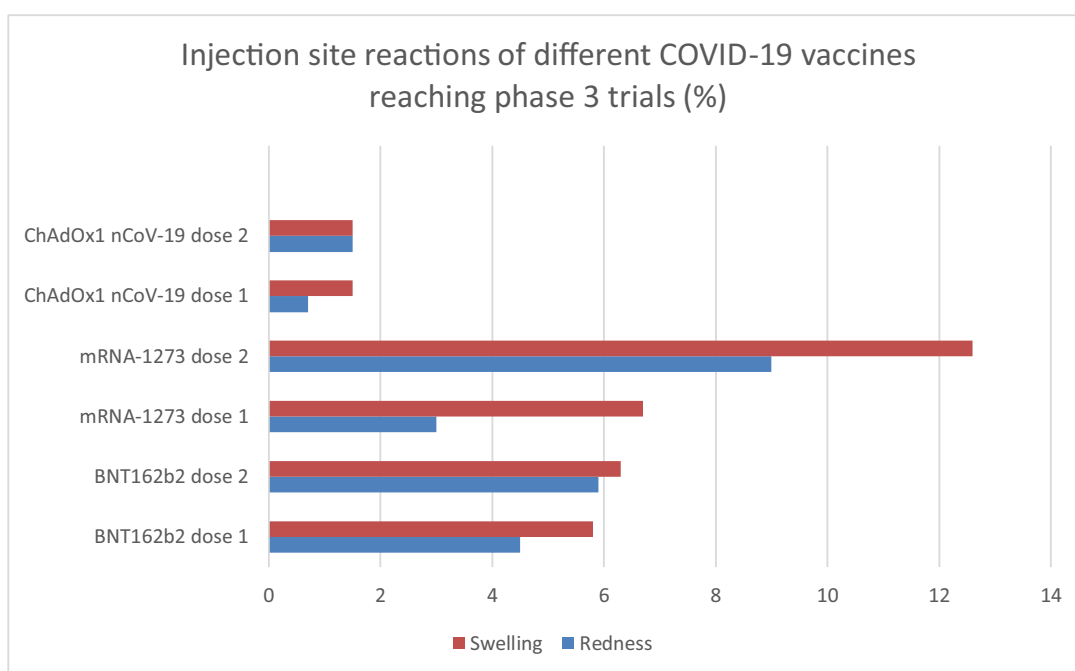


Fig. 1 Percentage of local site reactions such as swelling and redness from the first and the second dose of different COVID-19 vaccines (results from phase 3 trials).¹³ COVID-19, coronavirus disease 2019.

ate a specific appearance. Among the different excipients in the COVID-19 vaccines, polyethylene glycol (PEG), present in the mRNA vaccines, is the one suspected for the induction of allergic reactions.¹³ Polysorbate, which is used to improve the water solubility of drugs, may also induce allergic reactions.¹⁵ PEG, which is present in the two mRNA vaccines, and polysorbate 80, found in the adenoviral vector vaccines ChAdOx1 nCoV-19 (AstraZeneca-Oxford) and Ad26.COVS.2 (Janssen Pharmaceutical Companies), are the excipients blamed for allergic reactions.⁴

PEG and polysorbate are components in numerous vaccines and other injectable medications.¹⁶

Polyethylene glycols

PEGs are also known under different names such as Polikol, Carbowax, oxyethylene polymer, Polyox, ethylene glycol polymer, polyethylene oxide, polyoxyethylene diol, and Macrogol. PEGs are synthesized via polymerization of ethylene oxide¹⁷ and are widely used in medical materials (wound dressings, ultrasound gels, cleansing preparation for colon endoscopy, hydrogels, and orthopedic bone and neurosurgical dural sealants). PEGs are also part of household products (detergents and polishes) and food additives (preservatives and supplements). Macrogols are widespread in cosmetic products such as creams, ointment bases, facial products, baby wipes, shampoos, hair gels, lipsticks, shaving creams, and oral hygiene products.

Drugs containing PEG can be divided into five groups according to their PEG molecular weight (MW):

1. 3,350 MW: Macrogol bowel preparation, Depo-Medrol injection, and Depo-Provera contraceptive injection
2. 4,000 MW: Macrogol bowel preparation, SonoVue contrast
3. 6,000 MW: V-Pen mega antibiotic, Fludent fluoride tablet, Bafucin throat lozenge, and Balancid Novum reflux tablet
4. 8,000 MW: Imposit throat lozenge, Malarone anti-malarials, Chester packaging ultrasound gel, and Eflexor antidepressant tablet
5. 20,000 MW: Some sodium alginate antacid tablets

PEGylation occurs when PEGs are attached to various protein medications, allowing greater solubility for certain drugs. PEGylated drugs are common in cancer, gout, and immunotherapies.

PEGs are generally weak contact sensitizers.¹⁸ Low molecular weight (200-700 kDa) PEGs are liquids, whereas high molecular weight (1,000-7,500 kDa) PEGs are solids. Usually, high molecular weight allergens produce type I hypersensitivity, whereas contact sensitization is mainly reported with low molecular weight PEGs, for example, PEG 200 to PEG 400.¹⁹

Clinical picture

Various allergic reactions, such as allergic contact dermatitis, contact urticaria, and anaphylaxis, have been described. Data from the European Anaphylaxis Registry with

7,935 registered anaphylactic cases show that only three of them were induced by Macrogol.²⁰ Recently, in the anaphylaxis registry, six PEG cases and one polysorbate case had been registered, resulting in a percentage for PEG and polysorbate of 0.3% (7 out of 2,350) for drug-induced anaphylaxis.²¹ There are a few cases described concerning Macrogol-induced hypersensitivities due to drugs, personal hygiene products, dental products, and lubricants.

Testing

There is no standardized diagnostic testing for suspected hypersensitivity to PEGs.²² Simultaneous testing to multiple PEG MWs or repeating positive intradermal testing should be avoided.

Cross-reactions

Cross-reactions to polysorbate 80 must be considered.²³

Polysorbate

Polysorbate has several synonyms including polyoxyethylene (20) sorbitan monooleate, polysorbate 80, polysorbate 20, and polyoxyethylenesorbitan monooleate. Polysorbates are a class of emulsifiers and dispersing agents derived from ethoxylated sorbitan. They are used in medicinal products (eg, vitamin oils, vaccines, anticancer agents, and additives in tablets), cosmetics (creams, ointments, lotions), and food. Polysorbate 20 is added in brodalumab, and polysorbate 80 is added in infliximab, adalimumab, ustekinumab, and secukinumab.²⁴

Polysorbate 80 was identified as the causative agent for the anaphylactoid reaction of non-immunologic origin in the patients.¹⁵

Polysorbate 80 has been involved in isolated cases of allergy in the form of contact dermatitis caused by topical drugs, but its relevance as a contact allergen has declined during the past decades. The most commonly involved topical agents with polysorbate are acyclovir and inhaled budesonide. The most frequently involved parenteral drugs with polysorbate are adalimumab and ustekinumab, erythropoietin and darbepoetin, and omalizumab.²⁵

Clinical picture

Polysorbates have a potential to induce urticarial and/or anaphylactoid reactions. Urticaria due to polysorbate 20 in brodalumab has been described. Urticaria and/or anaphylactoid reactions could appear owing to polysorbate 80 in infliximab, adalimumab, ustekinumab, and secukinumab.

Testing

In most cases, a combination of skin prick, intradermal, and challenge testing with standard methodologies has been used.

Cross-reactions

Immediate hypersensitivity to PEG 3350 with cross-reactive polysorbate 80 hypersensitivity may be under-recognized in clinical practice and can be detected with skin testing.²⁶

Anyone with a history of immediate allergic reaction of any severity to any component of the mRNA COVID-19 vaccines, PEG, or polysorbate should not be vaccinated with the BNT162b2 (Pfizer-BioNTech) or mRNA-1273 (ModernaTX) vaccines. People with a history of severe allergic reactions due to any cause should be monitored for a 30-minute observation period after the application of the vaccine.⁴

There is no consensus on the use of antihistamines for prophylaxis. The H1-receptor blockers are unable to prevent anaphylaxis. They could mask cutaneous signs and symptoms, and thus, might delay treatment. Antihistamines could suppress some of the allergic manifestations such as dermatitis or itching, but they are unable to prevent death from anaphylaxis. It is important for patients with anaphylaxis to seek immediate medical care, because the only proven lifesaving treatment is epinephrine, and any delay in receiving appropriate treatment can be fatal.²⁷ We present a modification of the decalogue of treatment “REVIVE NOW” proposed by the European Academy of Allergy and Clinical Immunology²⁸:

- Recline position of the patient (Trendelenburg position) with legs up
- Epinephrine injection intramuscularly
- Volume replacement with sodium chloride 0.9% solution
- Inspiration support (clear airways, oxygen administration via facial mask 10 L/min)
- Vital signs check, repeat epinephrine if needed
- Emergency bronchodilation with short-acting β_2 agonists (eg, salbutamol) for severe dyspnea or wheezing; glucagon should be applied for patients who do not respond to adrenaline due to treatment with beta blockers
- Nebulized epinephrine and nebulized short-acting β_2 agonists
- Oral or intravenous corticosteroids + oral or intravenous antihistamines
- Warrant anaphylaxis diagnosis by measuring mast cell tryptase 2 to 3 hours after the onset of the reaction

The anaphylactic reactions to the mRNA COVID-19 vaccines are more common compared with such reactions to the other vaccines, but they still remain very rare. Early safety monitoring of the Pfizer-BioNTech COVID-19 vaccine has

detected 21 cases of anaphylaxis, after reported administration of 1,893,360 first doses of the Pfizer-BioNTech COVID-19 vaccine (11.1 cases per 1 million vaccine doses administered) as well as cases of less severe non-anaphylaxis allergic reactions, based on United States data for December 14–23, 2020.²⁹

Other rare reactions have been reported for the mRNA-1273 (Moderna) vaccine. These include reactions to hyaluronic acid (HA) dermal fillers and delayed-type or T cell-mediated local hypersensitivity reactions, also known as “COVID arm.”

Reactions to HA dermal fillers

The Food and Drug Administration (FDA) briefed on the mRNA-1273 (Moderna) vaccine reported reactions to dermal filler after vaccination in three patients in the experimental arm of the trial.¹³ Two of these patients had facial swelling, with one reporting filler injection 6 months before and the other one 2 weeks before vaccination. The third patient had only edema of the lips. In this case, the time of the filler injection was unknown, but a similar reaction had occurred after influenza vaccination in the past.³⁰ All reactions resolved. At the same time, two patients in the placebo group of this trial also developed facial swelling, which might indicate that other triggers, apart from the vaccine or filler, could have confounded the cases in the experimental group.

Immunogenic dermal filler reactions are rare, with immediate and delayed-type hypersensitivity reactions (DTR) reported and a global incidence rate of 0.8% for HA fillers.¹³ There is a review of the cases of delayed-onset inflammatory nodules developing in people injected with HA fillers. Although delayed nodules are uncommon from hyaluronic acid, juvéderm voluma (HA-V) (0.5%), the clinician should be aware of this adverse effect and have a management protocol in place. We believe from the patient responses and from the literature that these nodules are immune-mediated in nature.³¹ Usually the DTRs, mediated by macrophage and T cell interactions, develop 48 to 72 hours after injection, but sometimes they can occur weeks or months later. These reactions present with swelling and erythema at the filler site³² or with formation of granulomas at the injection site months or even years later.³³

It has been hypothesized that DTRs develop in people with dermal fillers after certain immunogenic triggers (eg, COVID-19 or other vaccines), because the fillers might act as adjuvants rather than direct T cell activators, enhancing the antigen-specific immune response without triggering one on their own.¹³ Genetically predisposed individuals might have a lower threshold for vaccines, infections, or other factors to trigger inflammatory reactions.³³ New data indicate a higher risk of DTRs to fillers in patients with human leukocyte antigen system (HLA) subtypes B*08 and DRB1*03, with association to a predisposition for autoimmune and/or granulomatous disorders.³⁴ Abnormalities in acute phase reactants,

C-reactive protein, fibrinogen, and low complement levels might also be involved in the reaction, probably through an autoimmune mechanism.³⁵ HA begins to degrade 3 to 5 months after injection, and this might cumulate unknown breakdown products that could stimulate the immune system when combined with additional triggers.³¹

A possible mechanism for the development of delayed inflammatory reaction (DIR) to HA dermal fillers has been proposed: this is a reaction induced by COVID-19/SARS-CoV-2 virus spike protein.³⁶ Although the exact mechanism of DIR is unknown, the COVID-19 spike protein may evoke a proinflammatory response in the location of dermal HA fillers through blockade of a cutaneous ACE-2 inhibitory pathway. Whether the DIR is related specifically to the mRNA-1273 (Moderna) vaccine or is a potential adverse reaction to widespread immune surveillance after infection is to be determined.

Treatment of delayed inflammatory reactions to HA dermal fillers

The treatment of patients with extensive findings should include a combination of oral corticosteroids and hyaluronidase injections initially to reduce the inflammatory response, stimulate ACE-2 upregulation, and eliminate the HA nidus of the inflammation.³⁶ The administration of oral corticosteroids to treat an active and/or ongoing viral infection is usually avoided to evade inhibition of host immune response. In the case of COVID-19, SARS-CoV-2 induces a hyperimmune response that benefits from corticosteroid administration. Based on the knowledge of the angiotensin pathways in the body, ACE-I or angiotensin receptor blockers might be used in the acute phase treatment of DIR.³⁷ Other possibilities of ACE-I therapy would include pretreatment to prevent DIR prior to administration of the first vaccine dose in a patient with a longstanding history of filler placement, or pretreatment of a patient before the second vaccine dose if a DIR develops after the first dose. Therapeutic intervention with ACE-I or angiotensin receptor blockers would not be expected to affect vaccine efficacy in a similar manner to corticosteroids.

Type IV hypersensitivity reactions

Other interesting but rare and non-dangerous reactions to the mRNA-1273 (Moderna) vaccine against SARS-CoV-2 have been observed, including delayed large local reactions, most probably T cell-mediated hypersensitivity reactions. From the phase 3 clinical trial of the mRNA-1273 vaccine against COVID-19, there is information about immediate injection-site reactions; such reactions were observed in 84.2% of the participants after the first dose.¹⁴ The trial also revealed that delayed injection-site reactions (defined in that

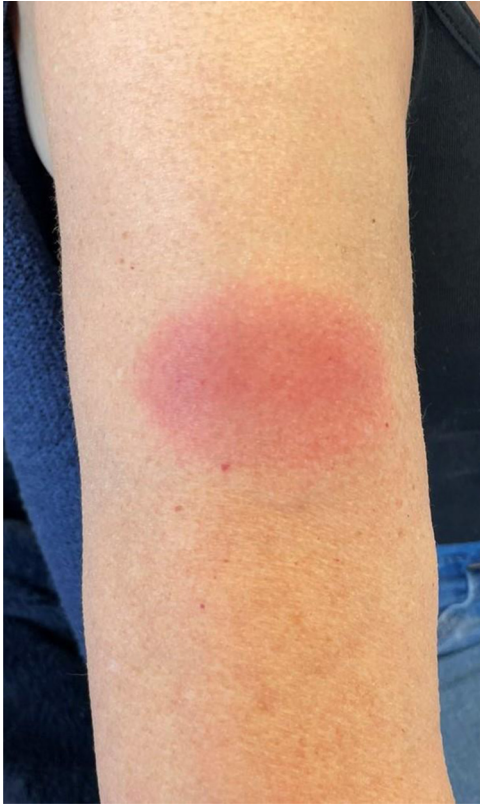

Fig. 2 DIR (COVID arm) appearing on the forearm of a patient 5 days after the first vaccination with mRNA-1273 (Moderna, Inc.). DIR, delayed inflammatory reaction. Reproduced with permission from Dr. Margarita Kacheva, Acibadem City Clinic Tokuda Hospital.

trial as those with an onset on or after day 8) occurred in 244 of the 30,420 participants (0.8%) after the first dose and in 68 participants (0.2%) after the second dose. These reactions include erythema, induration, and tenderness. In most of the cases, the reactions resolved in 4 to 5 days.

Recently, there have been observed delayed large local reactions with variable appearance to the mRNA-1273 vaccine, with a median onset on day 8 (range, days 4-11) after the first dose.³⁸ The reactions are also known as “COVID arm” (Figure 2). In a series of 12 patients with such reactions, these appeared near the injection site after complete resolution of the initial local and systemic manifestations associated with the vaccination. Five of the reactions were grade 3 plaques (>10 cm in diameter). Some of the patients had co-existing systemic adverse effects, including two persons with additional skin findings. Most of the patients were treated symptomatically with ice and antihistamines, some of them received corticosteroids (topical, oral, or both), and one patient was given antibiotic therapy for supposed cellulitis. The signs and symptoms resolved in a median of 6 days after onset (range, 2- 11 days).³⁸ The authors’ suspicion of DTR was supported by skin biopsy specimens taken from a patient with a delayed large local reaction who was not among the 12 pa-

tients described by this team. The specimens revealed superficial perivascular and perifollicular lymphocytic infiltrates with rare eosinophils and scattered mast cells. The injection-site reactions and the DTR were not contraindications to subsequent vaccination, so all 12 patients were encouraged to receive the second dose and complete their mRNA-1273 vaccination course. Six of these 12 patients did not have recurrence of large local reactions, three of them had reactions similar to the initial ones, and three had recurrent reactions of a lower grade than the initial ones. The median onset of cutaneous symptoms after the second dose (day 2; range, days 1-3) was earlier compared to that after the first dose.

The mass vaccination campaign against COVID-19 is progressing and different skin changes, including delayed local reactions, are more likely to appear. These adverse reactions are not serious and should not discourage people to complete the vaccination.

Adenoviral vector vaccines

Adenoviral vector vaccines (ChAdOx1 nCoV-19 [AstraZeneca-Oxford], Gam-COVID-Vac [Gamaleya National Centre of Epidemiology and Microbiology], Ad26.COV2.S [Johnson and Johnson’s Janssen Pharmaceutical Companies], and Ad5-nCoV [CanSinoBIO]) have shown reasonably good safety profiles. Some recent concerns that vaccination with ChAdOx1 nCoV-19 (AstraZeneca-Oxford) is linked to thromboembolic events³⁹ and the precautionary move of several European countries (Denmark, Norway, Iceland, Austria, Estonia, Lithuania, Luxembourg, Italy, and Latvia) that have suspended use of this vaccine have led to an issue of a statement by the EMA that unusual blood clots with low blood platelets should be listed as very rare side effects of Vaxzevria (ChAdOx1 nCoV-19; AstraZeneca-Oxford).⁴⁰ The overall risk of blood clots from the vaccine is very low, and its benefits in combating the widespread threat of COVID-19 continue to outweigh the risk of side effects.⁴¹ Physicians should be aware for potential vaccine-induced prothrombotic immune thrombocytopenia (VIPIT), which might be a rare adverse event after the AstraZeneca COVID-19 vaccine. The reaction seems to be similar to heparin-induced thrombocytopenia or drug-induced cutaneous vasculitis which can have a very demonstrative cutaneous involvement.⁴²

Some findings of VIPIT are present on the skin such as a petechial eruption, erythema and edema of the extremity with pallor and coldness. This may occur together with some systemic symptoms like persistent and severe headache, focal neurologic symptoms, seizures, blurred vision, shortness of breath, and chest or abdominal pain, proving to be a valuable sign for a condition that is potentially fatal and should not be misdiagnosed.⁴³

The cutaneous adverse effects of the ChAdOx1 nCoV-19 are once again primarily injection-site reactions. No serious adverse reactions to this vaccine occurred during the trials,

and the majority of adverse events reported were mild or moderate in severity, and all were self-limiting.^{9,44} One study described only one case of rosacea as an unrelated adverse effect and moderate pruritus as a related adverse effect apart from multiple mild solicited adverse local reactions such as pain, redness, warmth, itch, swelling, induration, and tenderness.⁴⁴ The phase 2/3 trial of the study showed similar results with most of the reported local and systemic adverse events classified as mild to moderate in severity.⁹ In another study with a larger cohort combining four randomized controlled trials in Brazil, South Africa, and the United Kingdom, there was only one case of cellulitis observed.⁴⁵

DIRs are rarely reported mainly in mRNA-type vaccines such as the mRNA-1273 vaccine (Moderna) and the BNT162b2 vaccine (Pfizer-BioNTech).^{36,38} The only known case of a suspected delayed inflammatory cutaneous reaction after the ChAdOx1 nCoV-19 vaccine was described in a 68-year-old woman with a history of localized scleroderma and appearance of highly pruritic erythematous papular eruption located within the limits of the morphea lesions, subsequently spreading to different areas of the body. This started on the third day after the first administration of the ChAdOx1 nCoV-19 vaccine (Oxford-AstraZeneca) (Figure 3).⁴⁶

The only available clinical trial of Ad26.COVS.2.S (Johnson and Johnson's Janssen vaccine) showed no serious cutaneous adverse effects. The most frequent injection-site reaction was erythema followed by swelling. Both were mild and self-limiting.⁴⁷ EMA's safety committee pharmacovigilance risk assessment committee (PRAC) has initiated a review of a safety signal based on four serious cases of unusual blood clots with low blood platelets post-vaccination with this vaccine with one fatality.⁴⁰ Recently, the Centers for Disease Control and Prevention and the Food and Drug Administration have reviewed data about six potential cases of a rare and severe type of cerebral venous sinus thrombosis in combination with thrombocytopenia in individuals after receiving the Ad26.COVS.2.S vaccine. They have issued a recommendation for a pause in the use of the vaccine, pending fulfillment of further and more detailed analyses of this rare but severe adverse effect. Because there is a similarity to heparin-induced thrombocytopenia, heparin is considered potentially dangerous and should be avoided in the treatment of this condition.⁴⁸ Some authors consider the use of intravenous immunoglobulin to treat this serious reaction.⁴⁹

The Russian vaccine Gam-COVID-Vac (Gamaleya National Centre of Epidemiology and Microbiology), also known as SputnikV, is heterologous, consisting of two components: a recombinant adenovirus type 26 vector and a recombinant adenovirus type 5 vector, both carrying the gene for SARS-CoV-2 spike glycoprotein. The first phase 1/2 trial based on the data of only 76 healthy participants showed similar results to those of the other adenoviral vaccines with a good safety profile and no severe adverse reactions. Mild local adverse events were observed, such as pain and itch in the injection site, as well as hives in one patient.⁵⁰

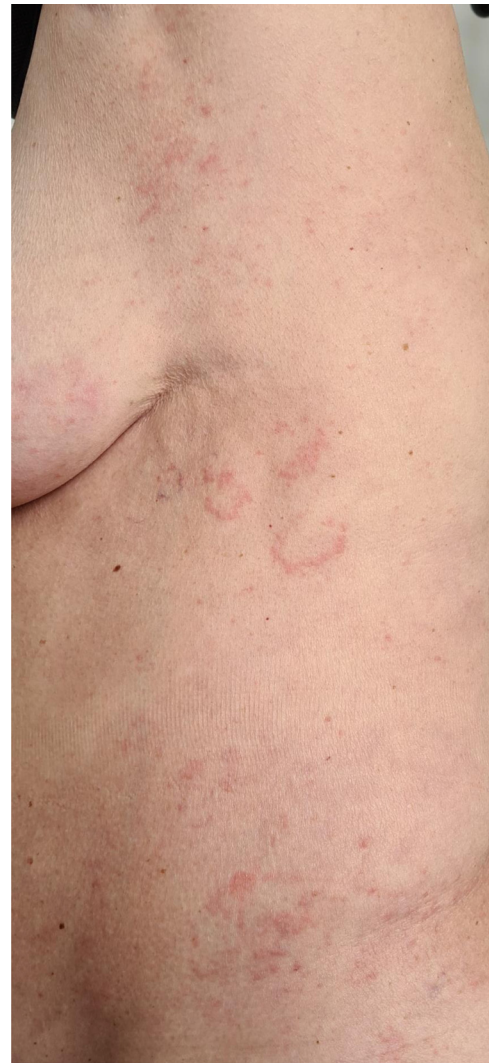

Fig. 3 DIR in a 68-year-old woman with a history of localized scleroderma and appearance of a highly pruritic erythematous papular eruption located within the limits of the morphea lesions, subsequently spreading on different areas of the body, starting on the third day after the first administration of the ChAdOx1 nCoV-19 vaccine (Oxford-AstraZeneca). The low number or absence of skin biopsies is probably due to the mild or moderate local or systemic reactions which resolve quickly only with the help of antihistamines or topical corticosteroids. In our case of “COVID arm” the patient initially agreed to give material for biopsy, but the reaction was over (dissipated) until the time and appointment for the procedure.

The phase 3 trial of the Gam-COVID-Vac vaccine gave a far more detailed picture of the safety profile. This study included a total of 21,977 healthy adult volunteers aged 18 years and older. Of those participants, only 12,296 received both doses and were included in the general safety analysis owing to violation of the restrictions imposed and lack of data verification in their case report form.⁸ In the vaccine group, they reported several cutaneous adverse reactions such as extremity abscess in one patient, allergic skin reactions in six patients, skin dermatitis in 12 patients, petechial eruptions in

one patient, itch in four patients, acneiform dermatitis in one patient, eczema in two patients, and alopecia in two patients.⁸ Four deaths occurred during this study; three in the vaccine group and one in the placebo group. None were considered related to the vaccine. Phase 1/2 and phase 3 studies do not provide detailed information on mild and moderate adverse events, which makes it difficult to evaluate the possible cutaneous side effects.

The Chinese vaccine Ad5-nCoV (CanSinoBIO) has one dose-escalation, single-center, open-label, non-randomized phase 1 trial with 195 recruited individuals, of which only 108 had been sequentially enrolled and assigned to receive the vaccine.⁵¹ In this trial, only mild injection-site adverse reactions such as pain, induration, redness, and swelling were reported with no severe adverse reactions. A subsequent randomized, double-blind, placebo-controlled phase 2 trial with 508 eligible participants found a similar safety profile as the previous trial. Apart from the mild injection-site reactions, some unsolicited cutaneous and mucosal adverse reactions had been reported such as noninfective gingivitis, buccal ulcerations, oral herpes simplex infection, lymphadenopathy, and oral hypoesthesia.¹⁰

Conclusions

Finding and describing the cutaneous adverse reactions of the available COVID-19 vaccines has proven to be a challenging and difficult task. Injection-site reactions presenting on the skin are among the most frequent adverse events, most of them mild or moderate, usually self-limited, and without serious consequences. DIRs are less frequent, but mysterious with no clear vision on the potential mechanisms leading to their appearance. Serious adverse events like VIPIT and anaphylaxis are of course the most important part of every safety and efficacy trial and the main topic of this contribution. Most of them are systemic adverse reactions with frequent cutaneous symptoms, which may be the first manifestation and the key for the diagnosis, leading to a timely and potentially lifesaving treatment. Further vigilance for severe adverse reactions is mandatory after the beginning of the worldwide spread of the vaccines. The cutaneous findings are a very important part of this vigilance because they might be the first symptoms to detect. Their importance is frequently underestimated, and sometimes they are unreported in the clinical trials or considered irrelevant.

References

- Greenwood B. The contribution of vaccination to global health: past, present and future. *Philos Trans R Soc Lond B Biol Sci.* 2014;369.
- Fritsche PJ, Helbling A, Ballmer-Weber BK. Vaccine hypersensitivity—update and overview. *Swiss Med Wkly.* 2010;140:238–246.
- Padron-Regalado E. Vaccines for SARS-CoV-2: lessons from other coronavirus strains. *Infect Dis Ther.* 2020;9:255–274.
- Kounis NG, Koniari I, de Gregorio C, Velissaris D, Petalas K, Brinia A, et al. Allergic reactions to current available COVID-19 vaccinations: pathophysiology, causality, and therapeutic considerations. *Vaccines.* 2021;9:221.
- Shen LW, Mao HJ, Wu YL, Tanaka Y, Zhang W. TMPRSS2: a potential target for treatment of influenza virus and coronavirus infections. *Biochimie.* 2017;142:1–10.
- Park KS, Sun X, Aikins ME, Moon JJ. Non-viral COVID-19 vaccine delivery systems. *Adv Drug Deliv Rev.* 2021;169:137–151.
- Pascolo S. Synthetic messenger RNA-based vaccines: from scorn to hype. *Viruses.* 2021;13:270.
- Logunov DY, Dolzhikova IV, Shcheblyakov DV, Tukhvatulin AI, Zubkova OV, Dzharullaeva AS, et al. Safety and efficacy of an rAd26 and rAd5 vector-based heterologous prime-boost COVID-19 vaccine: an interim analysis of a randomised controlled phase 3 trial in Russia. *Lancet.* 2021;397:671–681.
- Ramasamy MN, Minassian AM, Ewer KJ, Flaxman AL, Folegatti PM, Owens DR, et al. Safety and immunogenicity of ChAdOx1 nCoV-19 vaccine administered in a prime-boost regimen in young and old adults (COV002): a single-blind, randomised, controlled, phase 2/3 trial. *Lancet.* 2021;396:1979–1993.
- Zhu FC, Guan XH, Li YH, Huang JY, Jiang T, Hou LH, et al. Immunogenicity and safety of a recombinant adenovirus type-5-vectored COVID-19 vaccine in healthy adults aged 18 years or older: a randomised, double-blind, placebo-controlled, phase 2 trial. *Lancet.* 2020;396:479–488.
- Burrell CJ, Howard CR, Murphy FA. Vaccines and vaccination. In: Burrell CJ, Howard CR, Murphy FA, eds. *Fenner and White's Medical Virology* Academic Press; 2017:155–167. London, United Kingdom. ISBN-13: 978-0123751560; ISBN-10: 9780123751560.
- Centers for Disease Control and Prevention, Division of Healthcare Quality Promotion (DHQP). Vaccine safety-adjuvants. Available at: <https://www.cdc.gov/vaccinesafety/concerns/adjuvants.html>. Last accessed 20th March 2021.
- Rice SM, Ferree SD, Atanaskova Mesinkovska N, Shadi Kourosh A. The art of prevention: COVID-19 vaccine preparedness for the dermatologist. *Int J Womens Dermatol.* 2021;7:209–212.
- Baden LR, El Sahly HM, Essink B, Kotloff K, Frey S, Novak R, et al. Efficacy and safety of the mRNA-1273 SARS-CoV-2 vaccine. *N Engl J Med.* 2021;384:403–416.
- Coors EA, Seybold H, Merk HF, Mahler V. Polysorbate 80 in medical products and nonimmunologic anaphylactoid reactions. *Ann Allergy Asthma Immunol.* 2005;95:593–599.
- Banerji A, Wickner PG, Saff R, Stone Jr CA, Robinson LB, Long AA, et al. mRNA vaccines to prevent COVID-19 disease and reported allergic reactions: current evidence and suggested approach. *J Allergy Clin Immunol Pract.* 2021;9:1423–1437.
- Wenande E, Garvey LH. Immediate-type hypersensitivity to polyethylene glycols: a review. *Clin Exp Allergy.* 2016;46:907–922.
- Ozkaya E, Kilic S. Polyethylene glycol as marker for nitrofurazone allergy: 20 years of experience from Turkey. *Contact Dermatitis.* 2018;78:211–215.
- Kennard L, Rutkowski K, Mirakian R, Wagner A. Polyethylene glycol: not just a harmless excipient. *J Allergy Clin Immunol Pract.* 2018;6:2173.
- Wylon K, Dolle S, Worm M. Polyethylene glycol as a cause of anaphylaxis. *Allergy Asthma Clin Immunol.* 2016;12:67.
- Kraft M., Renaudin J.M., Ensina L.F., Kleinheinz A., Bilò M.B., Scherer Hofmeier K., et al. Anaphylaxis to vaccination and polyethylene glycol (PEG): a perspective from the anaphylaxis registry. *J Eur Acad Dermatol Venereol.* In press. doi:10.1111/jdv.17327.
- Antolin-Amerigo D, Sanchez-Gonzalez MJ, Barbarroja-Escudero J, Rodriguez-Rodriguez M, Alvarez-Perea A, Alvarez-Mon M. Allergic reaction to polyethylene glycol in a painter. *Occup Med (Lond).* 2015;65:502–504.
- Worm M, Bauer A, Wedi B, Treudler R, Pfuertner W, Brockow K, et al. Practical recommendations for the allergological risk assessment of the COVID-19 vaccination - a harmonized statement of allergy centers in Germany. *Allergol Select.* 2021;5:72–76.

24. Kato M, Oiso N, Uchida S, Yanagihara S, Sano H, Tohda Y, et al. Biologic-induced urticaria due to polysorbate 20. *J Dermatol*. 2019;46:e230–e232.
25. Palacios Castano MI, Venturini Diaz M, Lobera Labairu T, Gonzalez Mahave I, Del Pozo Gil MD, Blasco Sarramian A. Anaphylaxis due to the excipient polysorbate 80. *J Investig Allergol Clin Immunol*. 2016;26:394–396.
26. Stone Jr CA, Liu Y, Relling MV, Krantz MS, Pratt AL, Abreo A, et al. Immediate hypersensitivity to polyethylene glycols and polysorbates: more common than we have recognized. *J Allergy Clin Immunol Pract*. 2019;7:1533–1540. e8.
27. Wiley E, Romo N. The Association of Antihistamine Administration and delayed presentation for care in pediatric patients admitted with anaphylaxis. *Pediatrics*. 2020;146:236–238.
28. Sokolowska M., Eiwegger T., Ollert M., Torres M.J., Barber D., Del Giacco S., et al. EAACI statement on the diagnosis, management and prevention of severe allergic reactions to COVID-19 vaccines [e-pub ahead of print]. *Allergy*. doi:10.1111/all.14739. PMID: 33452689. Last accessed 20th March 2021.
29. CDC COVID-19 Response Team, Food and Drug Administration. Allergic reactions including anaphylaxis after receipt of the first dose of Pfizer-BioNTech COVID-19 vaccine—United States, December 14–23, 2020. *MMWR Morb Mortal Wkly Rep*. 2021;70:46–52.
30. Zhang R, ed. *FDA Presentation and Voting Questions. Food and Drug Administration (FDA) Center for Biologics Evaluation and Research (CBER) 164th Meeting of the Vaccines and Related Biological Products Advisory Committee*; February 26, 2021. <https://www.fda.gov/media/146220/download>. Last accessed 20th March 2021.
31. Beleznyay K, Carruthers JD, Carruthers A, Mummert ME, Humphrey S. Delayed-onset nodules secondary to a smooth cohesive 20 mg/mL hyaluronic acid filler: cause and management. *Dermatol Surg*. 2015;41:929–939.
32. Lowe NJ, Maxwell CA, Patnaik R. Adverse reactions to dermal fillers: review. *Dermatol Surg*. 2005;31:1616–1625.
33. Alijotas-Reig J, Esteve-Valverde E, Gil-Aliberas N, Garcia-Gimenez V. Autoimmune/inflammatory syndrome induced by adjuvants-ASIA-related to biomaterials: analysis of 45 cases and comprehensive review of the literature. *Immunol Res*. 2018;66:120–140.
34. Decates TS, Velthuis PJ, Schelke LW, Lardy N, Palou E, Schwartz S, et al. Increased risk of late-onset, immune-mediated, adverse reactions related to dermal fillers in patients bearing HLA-B*08 and DRB1*03 haplotypes. *Dermatol Ther*. 2021;34:e14644.
35. Alijotas-Reig J, Garcia-Gimenez V. Delayed immune-mediated adverse effects related to hyaluronic acid and acrylic hydrogel dermal fillers: clinical findings, long-term follow-up and review of the literature. *J Eur Acad Dermatol Venereol*. 2008;22:150–161.
36. Munavalli GG, Knutsen-Larson S, Lupo MP, Geronemus RG. Oral angiotensin-converting enzyme inhibitors for treatment of delayed inflammatory reaction to dermal hyaluronic acid fillers following COVID-19 vaccination—a model for inhibition of angiotensin II-induced cutaneous inflammation. *JAAD Case Rep*. 2021;10:63–68.
37. McLachlan CS. The angiotensin-converting enzyme 2 (ACE2) receptor in the prevention and treatment of COVID-19 are distinctly different paradigms. *Clin Hypertens*. 2020;26:14.
38. Blumenthal KG, Freeman EE, Saff RR, Robinson LB, Wolfson AR, Foreman RK, et al. Delayed large local reactions to mRNA-1273 vaccine against SARS-CoV-2. *N Engl J Med*. 2021;384:1273–1277.
39. Wise J. Covid-19: European countries suspend use of Oxford-AstraZeneca vaccine after reports of blood clots. *BMJ*. 2021;372:n699.
40. European Medicine Agency Safety Committee (PRAC). AstraZeneca's COVID-19 vaccine: EMA finds possible link to very rare cases of unusual blood clots with low blood platelets. Available at: <https://www.ema.europa.eu/en/news/astrazenecas-covid-19-vaccine-ema-finds-possible-link-very-rare-cases-unusual-blood-clots-low-blood#:~:text=EMA%20confirms%20overall%20benefit%20Drisk,COVID%2D19%20Vaccine%20AstraZeneca>. Last accessed 20th March 2021.
41. European Medicines Agency. COVID-19 vaccine AstraZeneca: benefits still outweigh the risks despite possible link to rare blood clots with low blood platelets. Available at: <https://www.ema.europa.eu/en/news/covid-19-vaccine-astrazeneca-benefits-still-outweigh-risks-despite-possible-link-rare-blood-clots>.
42. Guzman AK, Balagula Y. Drug-induced cutaneous vasculitis and anticoagulant-related cutaneous adverse reactions: insights in pathogenesis, clinical presentation, and treatment. *Clin Dermatol*. 2020;38:613–628.
43. Pai M., Grill A., Ivers N., Maltsev A., Miller K.J., Razak F., et al. Vaccine-induced prothrombotic immune thrombocytopenia (VIPIT) following AstraZeneca COVID-19 vaccination. Available at: <https://doi.org/10.47326/ocsat.2021.02.17.1.0>.
44. Folegatti PM, Ewer KJ, Aley PK, Angus B, Becker S, Belij-Rammerstorfer S, et al. Safety and immunogenicity of the ChAdOx1 nCoV-19 vaccine against SARS-CoV-2: a preliminary report of a phase 1/2, single-blind, randomised controlled trial. *Lancet*. 2020;396:467–478.
45. Voysey M, Clemens SAC, Madhi SA, Weckx LY, Folegatti PM, Aley PK, et al. Safety and efficacy of the ChAdOx1 nCoV-19 vaccine (AZD1222) against SARS-CoV-2: an interim analysis of four randomised controlled trials in Brazil, South Africa, and the UK. *Lancet*. 2021;397:99–111.
46. Bogdanov I, Bogdanov G, Tsankov N. Suspected delayed inflammatory cutaneous reaction after ChAdOx1 nCoV-19 vaccine located in preexisting morphea lesions; 2021. Unpublished data.
47. Sadoff J, Le Gars M., Shukarev G., Heerwegh D., Truyers C., de Groot A.M., et al. Interim results of a phase 1-2a trial of Ad26.COV2.S covid-19 vaccine [e-pub ahead of print]. *N Engl J Med*. doi:10.1056/NEJMoa2034201.
48. Marks P., Schuchat A. Joint CDC and FDA statement on Johnson & Johnson COVID-19 vaccine. Available at: <https://www.fda.gov/news-events/press-announcements/joint-cdc-and-fda-statement-johnson-johnson-covid-19-vaccine>.
49. Warkentin TE. High-dose intravenous immunoglobulin for the treatment and prevention of heparin-induced thrombocytopenia: a review. *Expert Rev Hematol*. 2019;12:685–698.
50. Logunov DY, Dolzhenkova IV, Zubkova OV, Tukhvatulin AI, Shcheblyakov DV, Dzharullaeva AS, et al. Safety and immunogenicity of an rAd26 and rAd5 vector-based heterologous prime-boost COVID-19 vaccine in two formulations: two open, non-randomised phase 1/2 studies from Russia. *Lancet*. 2020;396:887–897.
51. Zhu FC, Li YH, Guan XH, Hou LH, Wang WJ, Li JX, et al. Safety, tolerability, and immunogenicity of a recombinant adenovirus type-5 vectored COVID-19 vaccine: a dose-escalation, open-label, non-randomised, first-in-human trial. *Lancet*. 2020;395:1845–1854.