

Case Report

Hyperimmunoglobulin E syndrome with persistent vertebral osteomyelitis due to methicillin-resistant *Staphylococcus aureus*

Case report and review of the literature

San S. Wong^{a,*}, Peter R. Smith^b, Asim Ayaz^b, Douglas Sepkowitz^c

^a Division of Infectious Diseases, Maimonides Medical Center, Brooklyn, NY, United States

^b Division of Pulmonary Medicine, Long Island College Hospital, Brooklyn, NY, United States

^c Division of Infectious Diseases, Long Island College Hospital, Brooklyn, NY, United States

ARTICLE INFO

Article history:

Received 13 January 2014

Accepted 4 February 2014

Keywords:

Hyperimmunoglobulin E syndrome
Methicillin resistant *Staphylococcus aureus*
Vertebral osteomyelitis

ABSTRACT

We report a case of vertebral osteomyelitis due to methicillin-resistant *Staphylococcus aureus* (MRSA) with a slowly progressive, relatively asymptomatic course in a young woman with suspected hyperimmunoglobulin E syndrome (Job's syndrome).

© 2014 The Authors. Published by Elsevier Ltd. This is an open access article under the CC BY-NC-ND license (<http://creativecommons.org/licenses/by-nc-nd/3.0/>).

1. Case report

A 23-year-old African American woman developed an abscess in the right anterior chest wall just lateral to the sternum 1 month after a normal vaginal delivery under epidural anesthesia. She was admitted elsewhere and underwent incision and drainage of the abscess. A culture from the abscess grew MRSA sensitive to vancomycin (MIC less than 1), trimethoprim-sulfamethaxazole, clindamycin, tetracycline, and linezolid. She received intravenous vancomycin (MIC less than 1) for 10 days with apparent resolution. The abscess recurred in the same location 7 and 15 months after the initial episode. These recurrences were managed with incision and drainage, and oral trimethoprim-sulfamethoxazole. Cultures of the drainage consistently grew MRSA with the same susceptibility pattern. The patient reported that the wound healed with treatment each time.

Nineteen months after the initial episode, the abscess recurred and she was seen in our emergency department. Computerized tomography of the chest showed right upper and middle lobe parenchymal abnormalities suggestive of granulomatous infection, paraspinal abscess formation, periosteal thickening and osseous changes involving the 3rd to 6th vertebral bodies and right 3rd rib. She noted a mild cough. She denied back pain and neurological symptoms. Incision and drainage was performed and

she was referred to the pulmonary clinic. Multiple sputum cultures were negative for bacteria and acid fast bacilli. Magnetic resonance imaging showed changes similar to those on the CT scan. She received oral trimethoprim-sulfamethazole for 5 months but repeat CT showed minimal improvement. She was admitted to the hospital for further evaluation and management.

Her past medical history included intermittent asthma managed with albuterol inhaler as needed. She smoked one pack per day for 5 years but stopped 1 year prior to admission. She denied alcohol or drug abuse. There was no family history of recurrent infections. She was afebrile. Physical examination was normal except for a 2 cm × 2 cm fluctuant mass on the right upper chest. There was mild tenderness at the site, but no erythema. She had coarse facial features and a wide nasal bridge. Her appearance was notably different from her sister.

Complete blood count and serum chemistries were normal except for mild eosinophilia. Drainage of the abscess grew MRSA. A tuberculin skin test and HIV testing were negative. Culture for acid fast bacilli from the abscess was negative. Serum IgE level was 1489 IU/mL (normal 0–180 IU/mL). IgG and IgA levels were mildly elevated. IgG subclasses, complement CH50, hemoglobin electrophoresis, and neutrophil oxidative burst test were normal. Computerized tomography again showed a paraspinal collection now extending from the 2nd to the 8th thoracic vertebrae, with mild bone destruction also involving the right third rib (Fig. 1).

Intravenous vancomycin was started and continued for 5 weeks via PICC line on discharge, followed by oral linezolid for 6 months. The chest wall abscess resolved rapidly and she remained

* Corresponding author. Tel.: +1 2062359759.

E-mail address: sophiewong02@yahoo.com (S.S. Wong).

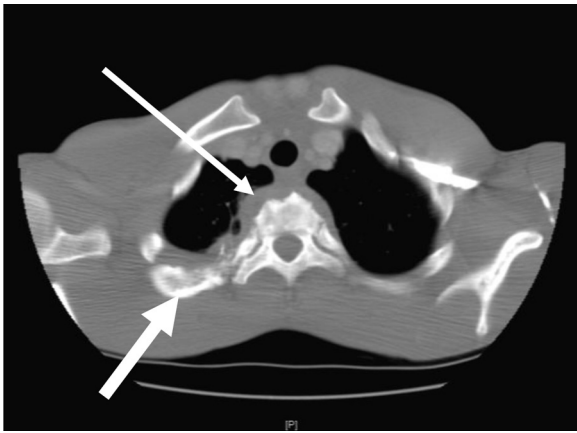


Fig. 1. Vertebral bony destruction with paraspinal collection (thin arrow) and cortical thickening and irregularity of the right 3rd rib (thick arrow).

asymptomatic, but there was no improvement in the radiographic abnormalities on CT scanning.

Six months later she was readmitted with right shoulder pain, upper back pain and fever. Computerized tomography and MRI showed enlargement of the paraspinal collection. Transesophageal echocardiography showed no evidence of endocarditis. Gallium and bone scans were normal. Under CT guidance, she underwent transcutaneous aspiration of the paraspinal collection. The drainage was grossly purulent and grew MRSA. Two weeks later, video-assisted thoracic surgery (VATS) was attempted but due to extensive adhesions was converted to open thoracotomy to permit debridement of the paravertebral collections. Her antibiotic regimen was changed to daptomycin plus rifampin for 6 weeks followed by linezolid and rifampin.

Three months postoperatively she was improved with resolution of the back pain and a weight gain of 14 pounds. Repeat MRI with gadolinium showed significant improvement with no areas of enhancement and no residual abscess formation. Therapy was continued with oral trimethoprim-sulfamethoxazole and rifampin. A study was negative for signal transducer and activator of transcription 3 (STAT3) mutation.

2. Discussion

Hyperimmunoglobulin E syndrome (HIES or Job's syndrome) is a rare condition characterized by high serum IgE levels, eczema, recurrent skin and/or pulmonary infections, and skeletal abnormalities [1,2]. The syndrome was first reported in 1966 by Davis, Schaller and Wedgwood, who described two girls with chronic dermatitis and recurrent staphylococcal abscesses and pneumonias [3]. The authors named the syndrome after the biblical character Job whose body was smitten with boils. Since the original description, approximately 250 cases have been reported [1].

Abnormal neutrophil chemotaxis due to decreased production of interferon gamma (IFN- γ) is believed to be the pathogenic mechanism. Inflammatory responses are impaired, in part due to absent IL-17 production. Mutations in the DNA-binding domain of signal transducer and activator of transcription 3 (STAT3) cause the autosomal dominant form of HIES [4,5]. A homozygous null mutation in tyrosine kinase 2 (TYK2) has been identified in two patients with autosomal recessive HIES [6].

Although HIES usually appears early in life, it may not manifest until late childhood or early adolescence. HIES usually presents with recurrent pulmonary and cutaneous infections due to staphylococci or candida. Less often *H. influenzae*, *P. aeruginosa*, *Streptococcus pneumoniae*, group A streptococci, *Cryptococcus*

neoformans, *H. capsulatum*, *Aspergillus* spp., and *P. (carinii) jirovecii* have been isolated [7–10].

Skin abscesses due to *Staphylococcus aureus* are common and typically not associated with a robust inflammatory response locally or systemically, hence the term cold abscesses. As in our patient, facial abnormalities are frequent including ocular hypertelorism, a prominent, protruding, triangular mandible, and a broad, somewhat bulbous nose. Failure of primary teeth to exfoliate is common. Many also have abnormalities of bone formation and metabolism, osteopenia, fractures, and craniosynostosis. The infectious manifestations rarely involve the deep organs, bones or joints, and documented septicemia is rare.

Serum IgE levels are usually markedly elevated. Often they exceed 2000 IU/mL, and levels of more than 50,000 IU/mL have been reported [7–9]. Infants with HIES may have IgE levels below 2000 IU/mL which then increase through childhood. In some cases, IgE levels have been reported to decline into the normal range over time [7]. Thus, some patients may lack an elevated IgE level when first evaluated. Mild to moderate eosinophilia is common. There is no direct association between IgE levels, or degree of eosinophilia and clinical manifestations [2,8,9].

The diagnosis of HIES should be suspected in the setting of the characteristic immunologic and somatic features, including elevated IgE, eczema, recurrent sinopulmonary infections, recurrent skin abscesses, failure of primary dental deciduation, scoliosis, characteristic facies, and a positive family history.

In our patient it is tempting to speculate that the initial infection was vertebral osteomyelitis resulting from epidural anesthesia during childbirth 1 month before the first appearance of the chest wall abscess. Initial infection in the epidural space could have extended to adjacent vertebrae, the paraspinal area, and the 3rd rib, then tracked anteriorly along the rib to the chest wall. The chronicity of her illness, paucity of symptoms and normal gallium and bone scans all suggest a blunted inflammatory response. Her facial features, elevated IgE levels and eosinophilia are consistent with HIES.

In summary, we believe our patient had MRSA vertebral osteomyelitis as a manifestation of HIES. The negative analysis for the STAT3 mutation does not rule out HIES since the sensitivity of the test is not well defined and there are other mutations known to be associated with the syndrome [6]. To the best of our knowledge, this is the second reported case of Job's syndrome with vertebral osteomyelitis [11].

References

- [1] Christine D, Amanda B, Bishop MS, Lucinda SB, Stephen PS, et al. Hyperimmunoglobulin E syndrome: two cases and a review of the literature. *J Am Acad Dermatol* 2006;54(5):855–65.
- [2] Tămaş MM, Baican C, Rednic S. Hyperimmunoglobulin E syndrome (Job's syndrome). *Rom J Intern Med* 2008;46(2):169–71.
- [3] Davis SD, Schaller J, Wedgwood RJ. Job's syndrome with recurrent infection: a review of current opinion and treatment. *Lancet* 1966;1:1013–5.
- [4] Minegishi Y, Saito M, Tsuchiya S, et al. Dominant-negative mutations in the DNA-binding domain of STAT3 cause hyper-IgE syndrome. *Nature* 2007;448:1058.
- [5] Holland SM, DeLeo FR, Elloumi HZ, et al. STAT3 mutations in the hyper-IgE syndrome. *N Engl J Med* 2007;357:1608.
- [6] Minegishi Y, Saito M, Morio T, et al. Human tyrosine kinase 2 deficiency reveals its requisite roles in multiple cytokine signals involved in innate and acquired immunity. *Immunity* 2006;25:745.
- [7] Buckley RH, Becker WG. Abnormalities in the regulation of human IgE synthesis. *Immunol Rev* 1978;41:288–314.
- [8] Grimbacher B, Holland SM, Gallin JI, et al. Hyper IgE syndrome with recurrent infections: an autosomal dominant multisystem disorder. *N Engl J Med* 1999;340:692–702.
- [9] Donabedian H, Gallin JI. The hyperimmunoglobulin E recurrent infection (Job's) syndrome: a review of the NIH experience and the literature. *Medicine (Baltimore)* 1983;62:195–208.
- [10] Holland SM, DeLeo FR, Elloumi HZ, et al. STAT3 mutations in the hyper-IgE syndrome. *N Engl J Med* 2007;357:1608–19.
- [11] Tan WM, Kandiah DA, Tan SB. Hyperimmunoglobulin E syndrome (job syndrome) discovered in a patient following corrective spine surgery: case report and review of the literature. *Spine (Phila PA 1976)* 2006;31(June (14)):E471–4.