

Available online at [www.sciencedirect.com](http://www.sciencedirect.com)

ScienceDirect

journal homepage: [www.elsevier.com/locate/radcr](http://www.elsevier.com/locate/radcr)

## Case Report

# Left partial anomalous pulmonary venous connection (PAPVC), a rare pulmonary venous variant<sup>☆</sup>

D. Pisola, MD<sup>1,\*</sup>, V. Bifulco, MD<sup>1</sup>

Radiology Department, Giovanni Paolo II Hospital, Via Bazzoni-Sircana 07026 Olbia, Sassari, Italy

## ARTICLE INFO

## Article history:

Received 20 May 2020

Revised 22 August 2020

Accepted 23 August 2020

## Keywords:

Partial anomalous venous connection

Hemoptysis

Pulmonary hypertension

Pulmonary vein variant

## ABSTRACT

A left partial anomalous vein connection and connection between left upper pulmonary vein and left internal thoracic vein was discovered in a 71-year-old man, with no history of previous cardiac surgery or an atrial septal defect, underwent a thorax HRCT scan without contrast media, following a chest x-ray, due to repeated bouts of smoking-related bronchitis. Left partial anomalous pulmonary vein connection is a rare venous variant, which more commonly affects the right side, resulting in a left to right shunt [9].

© 2020 The Authors. Published by Elsevier Inc. on behalf of University of Washington.

This is an open access article under the CC BY-NC-ND license (<http://creativecommons.org/licenses/by-nc-nd/4.0/>)

## Introduction

Left partial anomalous pulmonary vein connection (PAPVC), usually asymptomatic, is a rare vascular variant, where the left upper pulmonary vein drains into systemic circulation (left brachiocephalic vein). The physiology and the normal anatomy are affected by the number partial anomalous vein connection (PAPVC) shunts. Moreover, looking at a single PAPVC in a series the shunt is modest when associated with mild dilatation of the left ventricle. The left upper pulmonary vein is seen laterally to the aorta and anteriorly to the left main bronchus. This anomalous venous connection can be

mistaken for a double superior vena cava but in this case only one vein is seen at the level of the left hilum [2].

## Case report

A 71-year-old man, with no history of previous cardiac surgery or an atrial septal defect (ASD) who suffered repeated bouts of smoking-related bronchitis, was sent by his general practitioner to undergo a thorax HRCT scan without contrast media following a chest x-ray. Bilateral interstitial thickening associated with an increased lung hilum was discovered (Fig. 5).

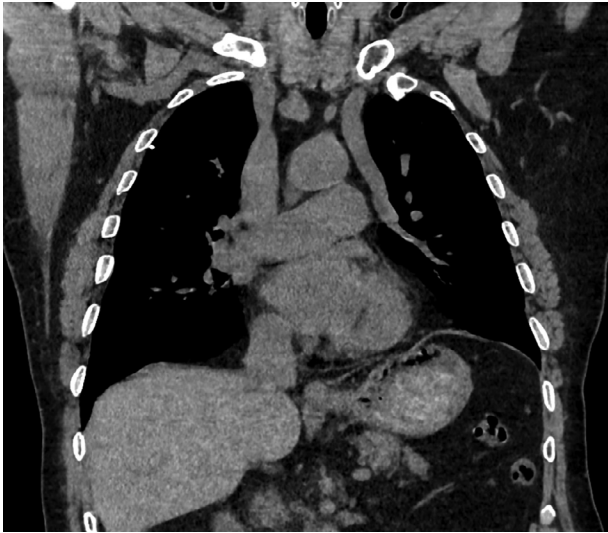
<sup>☆</sup> Conflicts of interest: No potential conflict of interest relevant to this article was reported.

\* Corresponding author.

E-mail address: [damiano\\_pisola@hotmail.com](mailto:damiano_pisola@hotmail.com) (D. Pisola).

<sup>1</sup> The authors would like to thank Michele Meloni, MD, Giulia Vacca, Anna Emilia Cau and Pietro Paschino, MD for their contribution. <https://doi.org/10.1016/j.radcr.2020.08.050>

1930-0433/© 2020 The Authors. Published by Elsevier Inc. on behalf of University of Washington. This is an open access article under the CC BY-NC-ND license (<http://creativecommons.org/licenses/by-nc-nd/4.0/>)



**Fig. 1 – Coronal view of left partial anomalous pulmonary vein connection.**

A connection between the left upper pulmonary vein and the left brachiocephalic (Fig. 1) and the left internal thoracic veins (Fig. 2a-c) were discovered. After which no therapy was deemed necessary.

## Discussion

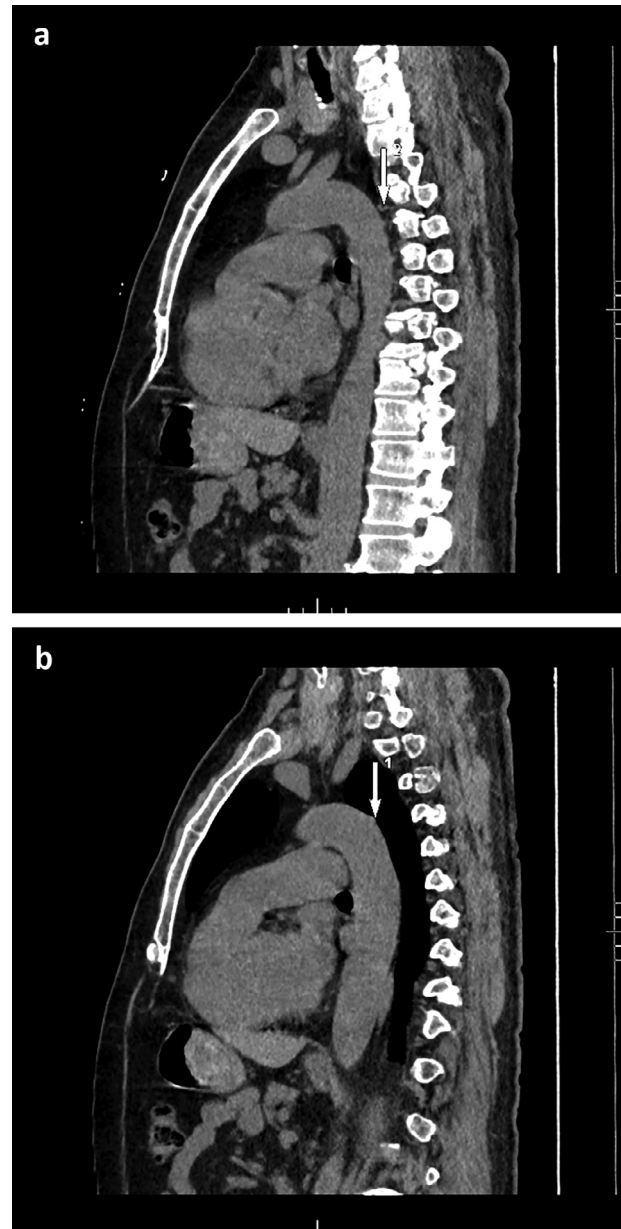
The left PAPVC belongs to a broad spectrum of congenital anomalies resulting in a left to right shunt [9] following failure of fusion of embryological pulmonary veins into the left atrium. The overall incidence is estimated between 0,4 and 0,7%. The right side is more commonly affected, whereas the left side is affected up to 18,2% [2,7].

This anomalous pulmonary venous drainage, commonly diagnosed by angioCT, can also be diagnosed by transesophageal echocardiography [1,8].

Patients often have no specific cardiac or respiratory symptoms therefore a chest x-ray test is the first step [2] but an association with hemoptysis is possible [6]. There is a frequent association with ASD and PAPVC in 80%-90% of cases [10] which further increases the volume of left to right shunt with an increase of the likelihood of pulmonary hypertension [5]. If present, ASD is asymptomatic when small in size. The morphology varies from an oval, circular, or even complex shape [9]. An intact atrial septum is extremely rare [10].

In our case the anomalous left superior pulmonary vein (15 mm) is bigger than the azygos vein (11 mm). The 2 diameters were evaluated at the connection between the azygos vein and the superior vena cava (Fig. 3). Moreover, the angle between the left pulmonary superior vein and the left brachiocephalic vein is estimated at 111° (Fig. 4). In actual fact, we think the difference may depend on the angle degree at the venous confluence. This angle had never been evaluated previously.

The left PAPVC spares the left pulmonary superior lobe from vascular congestion in left heart failure as the left upper

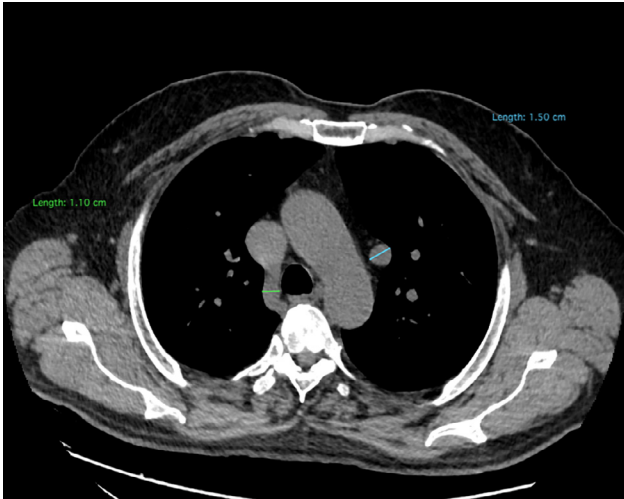


**Fig. 2 – (a-c) Connection between left superior pulmonary vein and internal thoracic vein.**

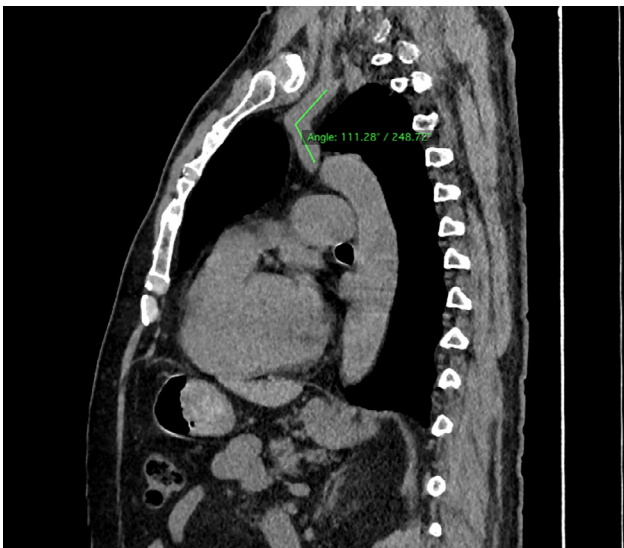
pulmonary vein does not drain into the left atria [2]. However, in the case of right heart failure and hemodynamically significant ASD [9], pulmonary edema affects the left upper pulmonary lobe [2]. Patients with hemodynamically significant ASD may present atrial arrhythmias, complete heart block or pulmonary hypertension [9].

A longstanding effect of left PAPVC can result in enlargement of the cardiac silhouette because of right ventricular dilatation, pulmonary plethora, right hilum vascular prominence, and dilatation of central pulmonary arteries [2].

As previously highlighted in the literature, PAPVC has been associated with pulmonary hypertension [4]. In our case the HRCT shows that the pulmonary artery diameter is 31 mm,



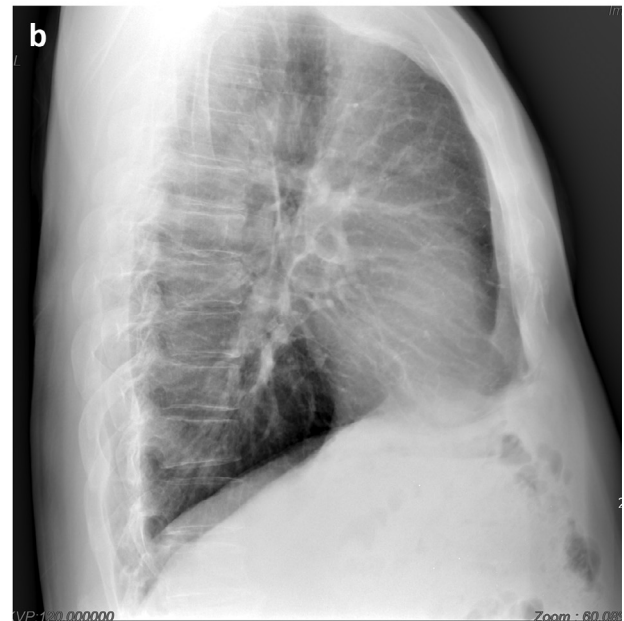
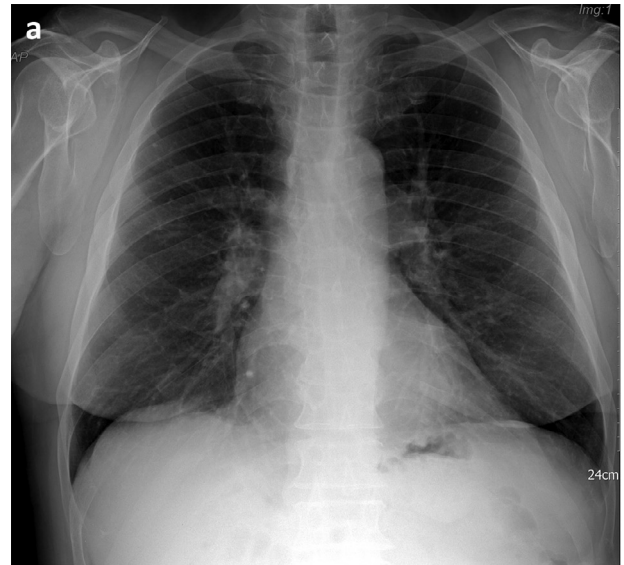
**Fig. 3 – Diameter of azygos vein and left superior pulmonary vein.**



**Fig. 4 – Angle between left superior pulmonary vein and left brachiocephalic vein.**

which is compatible with pulmonary hypertension, with a cut off of  $>29$  mm [3] (Fig. 6).

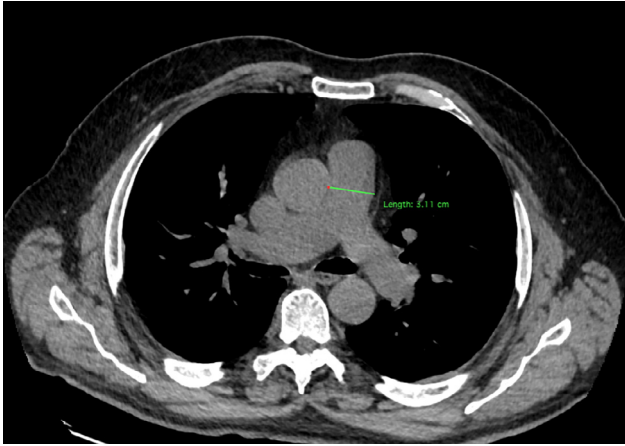
In case of necessity, the definitive treatment of PAPVC consists in the surgical separation of the pulmonary venous system from the systemic circulation [1]. In our thorax HRCT scan without contrast media the heart size was not enlarged. Thus, if present, the ASD cannot be excluded. Patient's



**Fig. 5 – (a, b) Chest x-ray. Bilateral interstitial thickening associated with increased lung hilum (Courtesy of G. De Paula).**

symptoms and pulmonary artery diameter could be related to his repeated bouts of smoking-related bronchitis, taking into account his medical history.

We consider our case worthy of attention due to the connection between the left upper pulmonary vein and the left thoracic internal vein which makes this case unique. Said connection had not been previously described in literature.



**Fig. 6 – Diameter of pulmonary artery.**

## Conclusion

The angle between the left upper pulmonary vein and the brachiocephalic vein may affect the different size between the left upper pulmonary vein and the azygos vein. We cannot formally exclude an ASD as the thorax HRCT scan had been carried out without contrast media. It is the first case which describes the connection between the left upper pulmonary vein and the internal thoracic vein.

## REFERENCES

- [1] Molinari Veloso da Silveira Lucas, Gus Miguel, Soares Torres Felipe, Danni Fuchs Flávio, Costa Fuchs Sandra. Partial anomalous pulmonary venous connection in a 72-year-old woman. A case report. *SAGE Open Med Case Rep* 2018;6:1–3. doi:[10.1177/2050313X18787646](https://doi.org/10.1177/2050313X18787646).
- [2] Lyen Stephen, Wijesuriya Shalini, Ngan-Soo Eleanor, Mathias Helen, Yeong Michael, Hamilton Mark, et al. Anomalous pulmonary vein drainage: a pictorial essay with a CT focus. *Journal of Congenital Cardiology* 2017;1(7):1–13. doi:[10.1186/s40949-017-0008-4](https://doi.org/10.1186/s40949-017-0008-4).
- [3] Troung Quynh A, Massaro Joseph M, Rogers Ian S, Mahabadi Amir A, Kriegel Matthias F, Fox Caroline S, et al. Reference values for normal pulmonary artery dimensions by noncontrast cardiac computed tomography: the Framingham Heart Study. *Circ Cardiovasc Imaging* 2012;5(1):147–54. doi:[10.1161/CIRCIMAGING.111.968610](https://doi.org/10.1161/CIRCIMAGING.111.968610).
- [4] Sandeep Sahay, Krasuski Richard A, Tonelli Adriano R. Partial anomalous venous connection and pulmonary arterial hypertension. *Respirology* 2012;17(6):957–63. doi:[10.1111/j1440-1843.2012.02180.x](https://doi.org/10.1111/j1440-1843.2012.02180.x).
- [5] Hoey Edward TD, Lewis Gareth, Yusuf Shamil. Multidetector CT of partial anomalous venous return in association with venous type atrial septal defect. *Quant Imaging in Med Surg* 2014;4(5):433–4. doi:[10.3978/j.ssn.2223-4292.2014.07.08](https://doi.org/10.3978/j.ssn.2223-4292.2014.07.08).
- [6] Li ChengCheng, Teng Peng, Yang Yanyan, Ni Yiming, Ma Liang. Partial anomalous pulmonary venous connection associated with hemoptysis. *Medicine* 2019;98:23.
- [7] Dillman Jonathan R, Yarram Sai G, Hernandez Ramiro J. Imaging of pulmonary vein anomalies. *Am J Roentgenol* 2009;192:1272–85.
- [8] Ammash Naser M, Seward James B, Warnes Carole A, Connolly Heidi M, O'Leary Patrick W, Danielson Gordon K. Partial anomalous venous connection; transesophageal echocardiography. *J Am Coll Cardiol* 1997;29:1351–8.
- [9] Rajiah Prabhakar, Kanne Jeffrey P. Cardiac MRI: part 1, cardiovascular shunts. *AJR Am J Roentgenol* 2011;197(4):W603–20. doi:[10.2214/AJR.10.7257](https://doi.org/10.2214/AJR.10.7257).
- [10] Ammannaya Ganesh Kumar K, Mishra Prashant, Khandekar Jayant V. Left sided PAPVC with intact IAS-surgically managed with vertical vein anastomosis to LA appendage: a rare case report. *Int J Surg Case Rep* 2019;59:217–19. doi:[10.1016/j.ijscr.2019.03.022](https://doi.org/10.1016/j.ijscr.2019.03.022).