



CASE REPORT

Case Report: Myelodysplastic syndrome- associated myeloid sarcoma: an unusual clinical presentation of a rare disease [version 1; referees: 2 approved]

Emoke Horvath¹, Smaranda Demian², Elod Nagy^{3,4}

¹Department of Pathology, University of Medicine and Pharmacy of Targu Mures, Targu-Mures, Romania

²Hematology Clinic 1, Emergency Clinical Hospital,, University of Medicine and Pharmacy of Targu Mures, Targu-Mures, Romania

³Department of Pharmacy and Biochemistry, University of Medicine and Pharmacy of Targu Mures, Targu-Mures, Romania

⁴, Laboratory of Medical Analysis, Clinical County Hospital Mures, Targu-Mures, Romania

v1 First published: 02 Feb 2016, 5:128 (doi: [10.12688/f1000research.7899.1](https://doi.org/10.12688/f1000research.7899.1))
 Latest published: 02 Feb 2016, 5:128 (doi: [10.12688/f1000research.7899.1](https://doi.org/10.12688/f1000research.7899.1))

Abstract

Myeloid sarcoma results from the extramedullary homing and proliferation of immature myeloid precursors. We present the timeline, events and diagnostic pitfalls related to a 66 year-old male patient’s case, admitted to the Hematology Clinic for pancytopenia, fever, weight loss and fatigue. The severe cytopenia and the few blasts observed in his blood smear indicated a bone marrow biopsy. The bone marrow showed hypercellularity and multilineage dysplasia with the presence of 15% myeloblasts. After the biopsy, he promptly developed paraplegia and nuclear magnetic resonance revealed an epidural tumour which was then resected. In the epidural tumour mass blast-like, round cells were observed with a complex immunophenotype, characterized by myeloperoxidase, CD117, CD15, CD99, leucocyte common antigen positivity and a high Ki-67 proliferation index. Considering the main differential diagnostic issues, the final diagnosis was stated as myelodysplastic syndrome-associated myeloid sarcoma. The prognosis was unfavourable, the bone marrow was quickly invaded by proliferating blast cells, and despite chemotherapy attempts, the patient died.

Open Peer Review

Referee Status:

	Invited Referees	
	1	2
version 1 published 02 Feb 2016	 report	 report

- 1 **Judit Csomor**, Semmelweis University
Hungary
- 2 **Erika Toth**, National Institute of Oncology
Hungary

Discuss this article

Comments (0)

Corresponding author: Elod Nagy (elod.nagy@umftgm.ro)

How to cite this article: Horvath E, Demian S and Nagy E. **Case Report: Myelodysplastic syndrome- associated myeloid sarcoma: an unusual clinical presentation of a rare disease [version 1; referees: 2 approved]** *F1000Research* 2016, 5:128 (doi: [10.12688/f1000research.7899.1](https://doi.org/10.12688/f1000research.7899.1))

Copyright: © 2016 Horvath E *et al.* This is an open access article distributed under the terms of the [Creative Commons Attribution Licence](https://creativecommons.org/licenses/by/4.0/), which permits unrestricted use, distribution, and reproduction in any medium, provided the original work is properly cited.

Grant information: The author(s) declared that no grants were involved in supporting this work.

Competing interests: No competing interests were disclosed.

First published: 02 Feb 2016, 5:128 (doi: [10.12688/f1000research.7899.1](https://doi.org/10.12688/f1000research.7899.1))

Introduction

Myeloid sarcoma is a rare malignant solid tumour resulting from the extramedullary proliferation of myeloblasts or immature myeloid cells, that usually precedes or accompanies acute myeloid leukaemia (AML), chronic myeloproliferative disorders, sometimes presenting as the first sign of AML¹. Every anatomical site of the body can be involved, but most common are the soft tissues of the head and neck, bone, skin and less often the genitourinary tract, the central nervous system and the spinal cord^{2,3}. We present a case with a complex clinical manifestation resulting from the unusual localization of the tumour mass, and that coincides with the MDS involving simultaneously the bone marrow tissue.

Case presentation

An otherwise healthy, 66-year-old man was admitted to the Haematology Clinic of the Emergency County Hospital (Targu-Mures, Romania) in a poor general condition, presenting fatigue, continuous fever, night sweating and weight loss (10 kg in 3 months), with symptoms occurring for a few weeks. His past medical history was unremarkable, without a known history of toxic or drug exposure. Physical examination evidenced a mucocutaneous pallor, but no lymphadenopathy or organomegaly. Acute myeloid leukaemia/myelodysplastic syndrome was suspected. Baseline laboratory data confirmed symptoms of ineffective haematopoiesis. Peripheral blood examination revealed pancytopenia: severe anaemia, thrombocytopenia and leukopenia with 2% blasts of myeloid lineage (Table 1), associated with elevated serum LDH (1250 U/L, reference range 240–480 U/L). The low-level presence of blasts in the blood smear (2%) indicated a bone marrow biopsy in order to

establish the diagnosis, which was effected on the second day of hospitalization. Post-biopsy, after a few hours he developed paraplegia. Cerebrospinal nuclear magnetic resonance was recommended and performed, which elucidated an epidural tumour mass of the thoracic spine (suspected metastasis), compressing the dural sac in the spinal channel at the T1–T3 levels. No other tumoral formation was found by complex imagistic investigation. On the same day, the patient underwent an emergent laminectomy, the tumour being totally resected. The bone marrow biopsy and the tumour fragments were submitted for histopathological examination.

Table 1. The complete blood count values of the patient.

CBC	Results	Reference range of the laboratory
Haemoglobin	74	120–160 g/L
MCV	104	80–95 fL
Platelet count	78	150–400 ×10 ⁹ /L
WBC	2.1	3.5–10.0 ×10 ⁹ /L
Neutrophils	19%	40–75%
Lymphocytes	74%	19–48%
Monocytes	5%	3–9%
Blasts	2%	0%

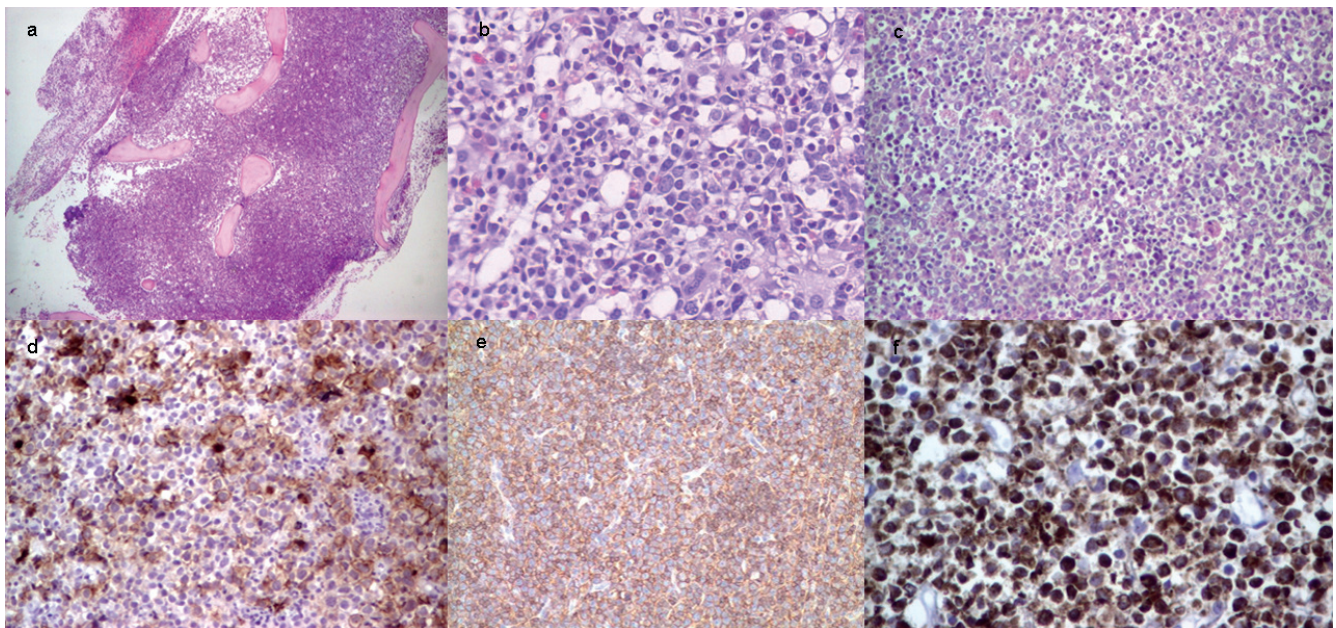


Figure 1. (a–f). Hypercellular bone marrow biopsy with reduced fatty cells, hematoxylin and eosin staining, magnification 4X (a), in the central portion of the bone marrow with foci of ALIP and dysplastic features in granulocytic lineage, hematoxylin and eosin staining, magnification 20X (b). Spinal tumor mass with diffuse and infiltrative population of large malignant cells (myeloblasts), with abundant cytoplasm and large nuclei, hematoxylin and eosin staining, magnification 10X (c), many of them with CD99, magnification 20x (d), and CD45 antigen expression, magnification 10X (e). Tumour cells showing strong MPO positivity, magnification 20X, 2', 3-diaminobenzidin (DAB) immunostaining (f).

The hypercellular bone marrow biopsy showed a multilineage dysplasia characterized by dyserythropoiesis, dysgranulopoiesis and dysmegakaryopoiesis with approximately 15% CD34/CD117 positive myeloblasts without Auer rods, associated with the presence of abnormal localisation of immature precursors (ALIP). Based on this histologic picture, according to the clinical and laboratory data, our diagnosis was refractory anaemia with excess blasts-2 (RAEB-2). The spinal tumour fragments showed a diffuse proliferation of undifferentiated myeloblast-like round tumour cells, mixed with a few neutrophil precursors.

Considering the two histological findings, myeloid sarcoma was suspected, but for a differential diagnosis lymphoblastic lymphoma, Burkitt lymphoma, diffuse large B-cell lymphoma and small round cell tumours also had to be excluded. A large immunohistochemistry panel was helpful in achieving differentiation of these conditions. The monomorphic tumour cells revealed positive stainings for Leucocyte Common Antigen (LCA), myeloperoxidase (MPO), CD15 and CD117, associated with a high Ki67 index (over 60%). Neuroendocrine and lymphoid markers, pan CK and also CD68 were negative. In contrast, a significant number of tumour cells expressed CD99 antigen.

The histopathological diagnosis has been stated on the basis of the two biopsies, being completed to “Myelodysplastic syndrome (RAEB-2) associated myeloid sarcoma” of the spinal cord.

The clinical course was unfavourable, at the end of the first week post-surgery, the peripheral blood and bone marrow suddenly showing a burst of the blast count up to 50%. Chemotherapy with high-dose cytosine arabinoside proved to be inefficient, and the patient died at 5 weeks from admission.

Discussion

The exact prognosis of myeloid sarcoma is difficult to determine, but in general is poor¹. The first description of “myeloid sarcoma” appeared in literature in 1811, and in 1904 its association with acute leukaemia was identified⁴.

The term “granulocytic sarcoma” was introduced in 1967 by Rappaport to describe only tumours of granulocytic origin, however the term is now often applied to any tumour related to acute leukaemia or myelodysplastic syndrome (MDS)⁵.

The mechanisms of extramedullary involvement are not fully understood, but it was demonstrated that leukaemic cell surface markers (CD56) are implicated in extramedullary homing⁵.

The particularity of our case consists of the unusual tumour localization with spinal compression and neurologic signs, and the

combination with the deficient haematopoiesis, that raises the suspicion of a metastasis in the bone marrow. Regarding phenotype, the positivity for CD45 and CD99 with a high Ki-67 proliferation index could suggest a lymphoma, but the morphological similarities between the extramedullary tumour cells and the bone marrow blasts are suggestive for myeloid sarcoma. For an accurate approach, a large-scale immunohistochemistry panel, containing mandatorily the CD45, MPO, CD15, CD79a, CD3, CD34, CD117, CD99, TdT and Ki-67 proved to be useful. The major diagnostic pitfalls are represented by distinction from lymphoblastic lymphomas (TdT+/CD34+/CD99+/CD45+/high Ki-67 index), and small round-cell tumours (CD99+/TdT-). Seifert *et al.* analyzed 12 cases of myeloid sarcoma and found a consistent positivity for CD117, CD43, MPO, CD68, CD34 and a sporadic reaction of leucocyte common antigen⁶. Two major issues of the correct diagnostic orientation are the recognition of a possible non-lymphoid CD45 positivity and ruling-out of the aberrant CD99 antigen from the pivotal markers in this tumour type. On the other hand, MPO positivity is a prominent feature for a tumour of myeloid origin that overrides the unusual and aberrant antigen expression (CD79a, CD99).

In conclusion, we considered, that a large panel of antibodies must be used to establish the challenging diagnosis of myeloid sarcoma. This condition that should always be considered as a diagnostic possibility in patients with MDS, AML or chronic myeloproliferative disorders complicated with a secondary tumor mass.

Consent

Written informed consent was obtained from the patient for the management and publication of clinical and laboratory data. The Ethical Committee of the Hospital approved the publication of the clinical details (no. 780/14-01-2016).

Author contributions

Demian S. managed the diagnostic and therapeutic procedures, provided details of clinical data, Horvath E performed data analysis and established the histopathological diagnosis, Nagy EE participated in data analysis, integration and performed the critical review of the manuscript.

Competing interests

No competing interests were disclosed.

Grant information

The author(s) declared that no grants were involved in supporting this work.

References

1. Yilmaz AF, Saydam G, Sahin F, *et al.*: **Granulocytic sarcoma: a systematic review.** *Am J Blood Res.* 2013; **3**(4): 265–270.
[PubMed Abstract](#) | [Free Full Text](#)
2. Joseph JR, Wilkinson DA, Bailey NG, *et al.*: **Aggressive Myeloid Sarcoma Causing Recurrent Spinal Cord Compression.** *World Neurosurg.* 2015; **84**(3): 866.e7–866.e10.
[PubMed Abstract](#) | [Publisher Full Text](#)
3. Hu X, Shahab I, Lieberman IH: **Spinal Myeloid Sarcoma “Chloroma” Presenting as Cervical Radiculopathy: Case Report.** *Global Spine J.* 2015; **5**(3): 241–246.
[PubMed Abstract](#) | [Publisher Full Text](#) | [Free Full Text](#)
4. Dock G, Warthin A: **A new case of chloroma with leukemia.** *Trans Assoc Am Phys.* 1904; **19**: 64–115.
5. Bakst RL, Tallman MS, Douer D, *et al.*: **How I treat extramedullary acute myeloid leukemia.** *Blood.* 2011; **118**(14): 3785–3793.
[PubMed Abstract](#) | [Publisher Full Text](#)
6. Seifert RP, Bulkeley W 3rd, Zhang L, *et al.*: **A practical approach to diagnose soft tissue myeloid sarcoma preceding or coinciding with acute myeloid leukemia.** *Ann Diagn Pathol.* 2014; **18**(4): 253–60.
[PubMed Abstract](#) | [Publisher Full Text](#)

Open Peer Review

Current Referee Status:



Version 1

Referee Report 22 March 2016

doi:[10.5256/f1000research.8503.r12978](https://doi.org/10.5256/f1000research.8503.r12978)



Erika Toth

Surgical and Molecular Tumour Pathology Centre, National Institute of Oncology, Budapest, Hungary

Well-structured paper. Rare case, nice demonstration of the difficult differential diagnostic process of myeloid sarcoma. The title is appropriate and represent the work. Results supports the final conclusion of the case.

I have read this submission. I believe that I have an appropriate level of expertise to confirm that it is of an acceptable scientific standard.

Competing Interests: No competing interests were disclosed.

Referee Report 14 March 2016

doi:[10.5256/f1000research.8503.r12783](https://doi.org/10.5256/f1000research.8503.r12783)



Judit Csomor

1st Department of Pathology and Experimental Cancer Research , Faculty of Medicine, Semmelweis University, Budapest, Hungary

The main aim of this short case report is to create attention for myeloid sarcoma, which can be a difficult differential diagnostic problem, first of all in cases, when the myeloid sarcoma precedes the bone marrow disease. The documentation of the presented patient illustrates well the histological work up and the diagnosis, but the paper would have been more teaching if the authors add more detail about the patients course. I would have been interested in the results of investigation of the cerebrospinal fluid, the cytogenetic findings and the neurological status after operation? Why monotherapy was chosen? What further complications did they observe? What was the cause of death?

In my experience myeloid sarcoma can be purely blastic, but frequently shows signs of myeloid differentiation. Fine cytoplasmic granulation of the immature cells, presence of eosinophilic myelocytes among the blasts, or some monocytoid features are suspicious for myeloid tumor, and can be recognised by careful examination of high quality sections and special stains. If these signs are observed a short panel containing the lineage specific markers is enough to confirm the diagnosis For differential diagnosis of a poorly differentiated tumor, the authors list a wide panel of immune stains emphasizing markers of immaturity (CD34, CD117, tdt, CD99). I think the lineage specific markers, especially CD45, MPO, CD3, CD79, Pax5 and lysozyme, are more important. To suggest a cost effective algorithm in the

report would be a valuable supplement.

And I have to add, that the diagnosis of MDS with excess of blasts and AML is first of all based on bone marrow smears and flow cytometry. If flow cytometry is not available cytochemistry is recommended for defining the cell lineage of the blasts. Bone biopsy is usually only an additional investigation (except of dry tap). Probably in the presented case smears also were elaborated, but data of smears and bone marrow biopsy is not clearly separated. The blast count is based on CD34 and CD117 immunohistochemistry without mentioning the ratio of the blast by marrow smear cytology. The authors state, that CD56 may have role in homing of the myeloid blasts, therefore additional CD56 investigation would be interesting. AML with t(8;21) is more frequently cause myeloid sarcoma, therefore applying FISH probes to test the genotype of the tumor is also recommended to get more information about these rare tumors.

I have read this submission. I believe that I have an appropriate level of expertise to confirm that it is of an acceptable scientific standard.

Competing Interests: No competing interests were disclosed.
