

Spondylectomy and lateral lumbar interbody fusion for thoracolumbar kyphosis in an adult with achondroplasia

A case report

Masashi Miyazaki, MD, PhD*, Shozo Kanezaki, MD, Naoki Notani, MD, Toshinobu Ishihara, MD, Hiroshi Tsumura, MD, PhD

Abstract

Rationale: Fixed thoracolumbar kyphosis with spinal stenosis in adult patients with achondroplasia presents a challenging issue. We describe the first case in which spondylectomy and minimally invasive lateral access interbody arthrodesis were used for the treatment of fixed severe thoracolumbar kyphosis and lumbar spinal canal stenosis in an adult with achondroplasia.

Patient concerns: A 61-year-old man with a history of achondroplastic dwarfism presented with low back pain and radiculopathy and neurogenic claudication.

Diagnoses: Plain radiographs revealed a high-grade thoracolumbar kyphotic deformity with diffuse degenerative changes in the lumbar spine. The apex was located at L2, the local kyphotic angle from L1 to L3 was 105°, and the anterior area was fused from the L1 to L3 vertebrae. MRI revealed significant canal and lateral recess stenosis secondary to facet hypertrophy.

Interventions: We planned a front-back correction of the anterior and posterior spinal elements. We first performed anterior release at the fused part from L1 to L3 and XLIF at L3/4 and L4/5. Next, the patient was placed in the prone position. Spondylectomy at the L2 vertebra and posterior fusion from T10 to L5 were performed. Postoperative radiographs revealed L1 to L3 kyphosis of 32°.

Outcomes: No complications occurred during or after surgery. Postoperatively, the patient's low back pain and neurological claudication were resolved. No worsening of kyphosis was observed 24 months postoperatively.

Lessons: Circumferential decompression of the spinal cord at the apical vertebral level and decompression of lumbar canal stenosis were necessary. Front-back correction of the anterior and posterior spinal elements via spondylectomy and lateral lumbar interbody fusion is a reasonable surgical option for thoracolumbar kyphosis and developmental canal stenosis in patients with achondroplasia.

Abbreviations: MRI = magnetic resonance imaging, XLIF = extreme lateral interbody fusion.

Keywords: achondroplastic dwarfism, adult spinal deformity, extreme lateral interbody fusion, kyphosis, spondylectomy

1. Introduction

Achondroplasia is a rare genetic disease with an estimated incidence of 1/15,000 births. Most cases arise as spontaneous mutations in the fibroblast growth factor receptor 3 (*FGFR3*) gene.^[1] The resultant defect in endochondral bone formation may lead to several spine abnormalities, including pan-spinal canal stenosis and thoracolumbar kyphosis.^[2]

Fixed thoracolumbar kyphosis with spinal stenosis in adult patients with achondroplasia presents a challenging issue. Circumferential decompression of the spinal cord at the apical level is usually required. Correction of the kyphosis is necessary for kyphosis above approximately 30°,^[3] and reconstruction of the spine for stabilization and fusion should be considered. However, few studies have been carried out on the treatment of severe thoracolumbar kyphosis and neurologic deficits in adults with achondroplasia.

In addition, symptomatic lumbar stenosis can be observed in 20% to 30% of achondroplastic adult patients, and surgical treatment is required in nearly 10% of cases. Multilevel spinal laminectomy is widely accepted as the treatment of choice. More extensive decompression to the sacrum has also been recommended.^[4] However, the higher risk associated with general anesthesia and lower tolerance for significant blood loss in patients with achondroplastic dwarfism remain challenging to treatment.

In extreme lateral interbody fusion (XLIF), the interbody cage is inserted with minimal muscle dissection and disruption to ligamentous structures using a split blade retractor, and this technique allows for minimally invasive restoration of disc height and, therefore, indirect decompression for canal stenosis. This procedure has been shown to reduce recovery time, blood loss, and tissue damage^[5] and has been increasingly used in the last decade.^[6]

Here, we report a case of spondylectomy and lateral lumbar interbody fusion for the treatment of fixed severe thoracolumbar

Editor: N/A.

The authors have no funding and conflicts of interest to disclose.

Department of Orthopaedic Surgery, Oita University, Oita, Japan.

* Correspondence: Masashi Miyazaki, Department of Orthopaedic Surgery, Faculty of Medicine, Oita University, Idaigaoka, Hasama-machi, Yufu-shi, Oita, Japan (e-mail: masashim@oita-u.ac.jp).

Copyright © 2017 the Author(s). Published by Wolters Kluwer Health, Inc. This is an open access article distributed under the terms of the Creative Commons Attribution-Non Commercial-No Derivatives License 4.0 (CCBY-NC-ND), where it is permissible to download and share the work provided it is properly cited. The work cannot be changed in any way or used commercially without permission from the journal.

Medicine (2017) 96:49(e8983)

Received: 20 September 2017 / Received in final form: 2 November 2017 /

Accepted: 8 November 2017

<http://dx.doi.org/10.1097/MD.0000000000008983>

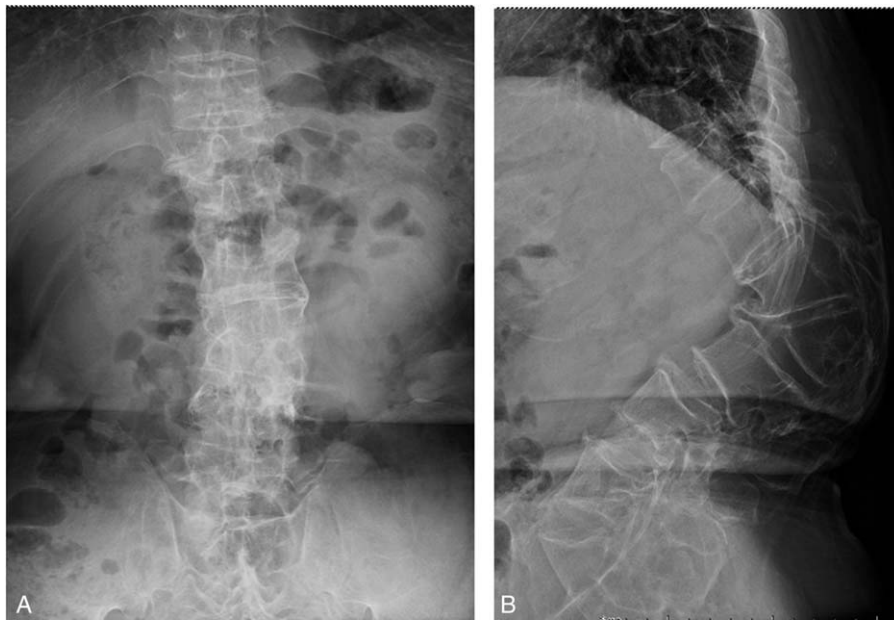

Figure 1. Preoperative anteroposterior and lateral radiographs of the thoracolumbar spine. Preoperative anteroposterior radiographs demonstrate a decreased interpedicular distance. Preoperative lateral radiographs show L2 anterior wedge deformity, fusion of the anterior area from the L1 to L3 vertebrae, and thoracolumbar kyphosis (105° , L1–L3).

kyphosis with lumbar spinal canal stenosis in an adult with achondroplasia.

2. Case report

A 61-year-old man presented with low back pain and radiculopathy and neurogenic claudication. Spinal deformity was detected at another hospital, and he was referred to our hospital for surgery. He had a history of achondroplastic

dwarfism and was unable to walk for long periods due to low back and bilateral limb pain. His muscle strength was not reduced, but he experienced numbness from the bilateral gluteal region to the lateral side of the lower extremities when in a resting position. Plain radiographs revealed a high-grade thoracolumbar kyphotic deformity with diffuse degenerative changes in the lumbar spine. The apex was located at L2, the local kyphotic angle from L1 to L3 was 105° , and the anterior region was fused from the L1 to L3 vertebrae (Fig. 1A and B, Fig. 2A and B). MRI

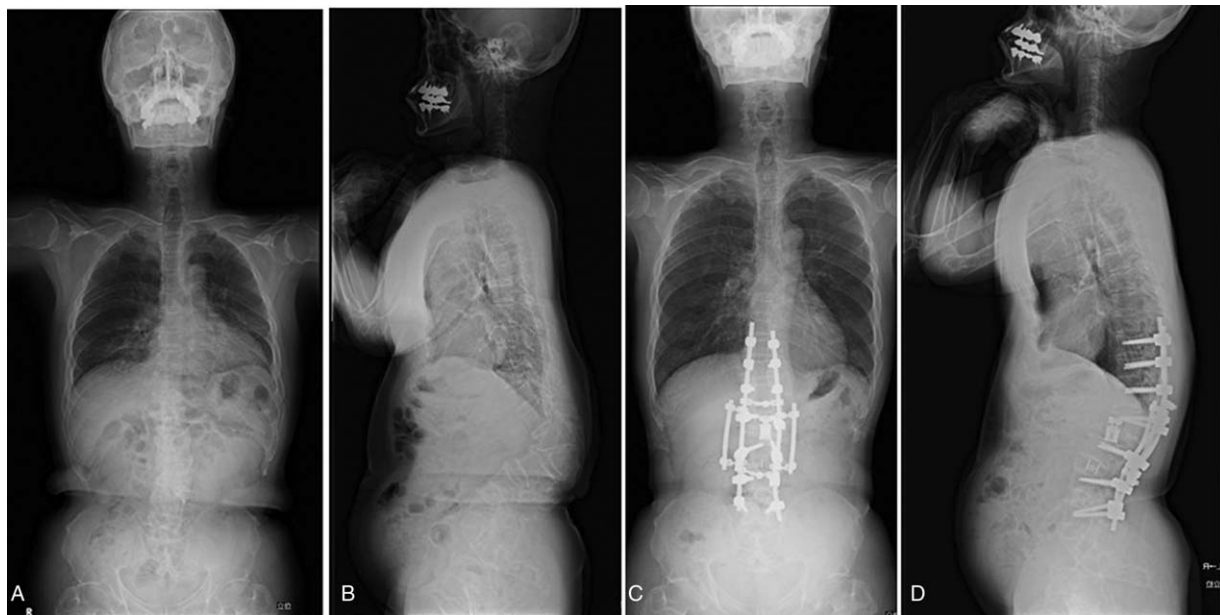


Figure 2. Preoperative and postoperative and lateral radiographs of the whole spine. Preoperative anteroposterior radiographs. Preoperative lateral radiographs show the apex at L2 and severe thoracolumbar kyphosis (105° , L1–L3). Postoperative anteroposterior radiographs. Postoperative lateral radiographs show the kyphosis corrected to 32° and nonpathologic sagittal balance of entire spine.

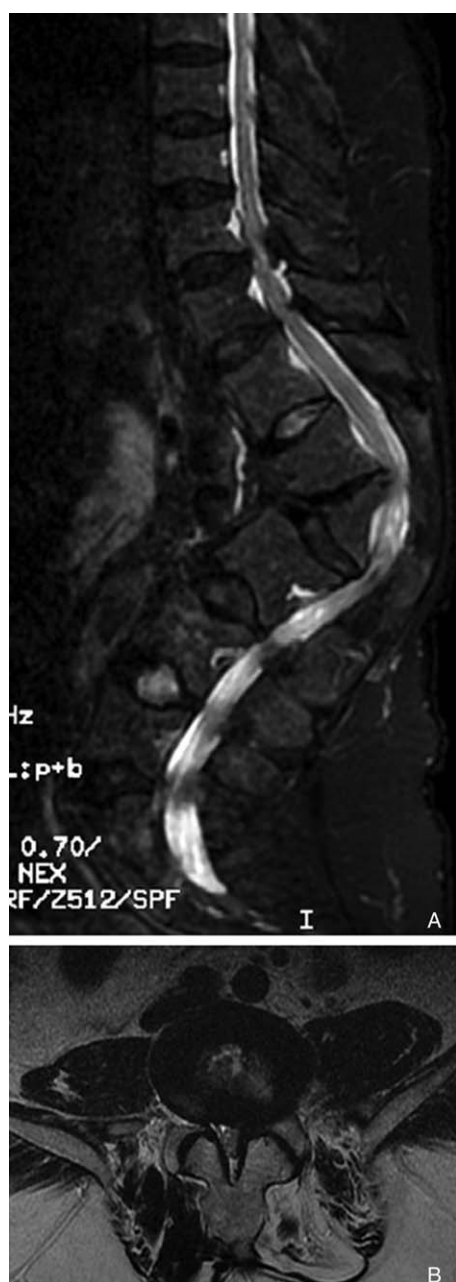


Figure 3. Preoperative magnetic resonance imaging of the thoracolumbar spine. The sagittal view demonstrates multiple-level spinal canal stenosis. The axial view shows spinal canal stenosis due to hypertrophic facet joints and ligamentum flavum.

was performed, which revealed significant canal and lateral recess stenosis at T10–11, T11–12, L1–2, L2–3, L3–4, and L4–5 secondary to facet hypertrophy (Fig. 3A and B).

We planned a front-back correction of the anterior and posterior spinal elements. We first performed anterior release at the fused area from L1 to L3, followed by XLIF at L3/4 and L4/5. A retroperitoneal approach was employed from the right decubitus position. Free running electromyography was used for the duration of the procedure. The patient underwent standard lateral access interbody fusion. No electromyographic abnormalities were encountered during the lateral stage of the procedure. After XLIF, anterior release and discectomy from L1 to L3 was performed. Fusion masses and discs were excised with

an air drill, rongeurs, and curettes. The patient was then placed in the prone position. Subperiosteal stripping was carried out to expose the posterior aspect of the spine. Pedicle screws were inserted into the vertebrae from T10 to L5, and laminectomy was performed at T10/11, T11/12, T12/L1, L1/2, and L2/3. The transverse processes of the L2 vertebra were removed. The peritoneum was then detached and stripped from the lateral side of the vertebra. Care was taken to preserve the exiting nerve roots. Thus, the entire apical vertebra was exposed circumferentially. The apical vertebra and adjacent discs were excised with a rongeur and curettes. The cortex of the apex was completely resected posteriorly by gently retracting the dural tube bilaterally. After a titanium rod, bent along the kyphotic curve, was temporally secured to the screws on one side, compression forces were applied to the pedicle screws to achieve kyphosis correction on the other side. The same procedure was repeated on the other side. Spinal cord monitoring, including motor-evoked potentials, was also used during the procedure. Four rod constructs were applied at spondylectomy levels due to the risk of rod breakage. A titanium expandable cage (T2 ALTITUDE Expandable Corpectomy Device, Medtronic Sofamor Danek, TN) packed with minced bone was placed and extended in the space created by the spondylectomy, and postoperative radiographs revealed L1 to L3 kyphosis of 32° (Fig. 2C and D).

No complications occurred during or after surgery. The patient began ambulation on postoperative day 3. He used a thoracolumbosacral orthosis for 6 months. After the operation, his low back pain and neurological claudication were resolved. No worsening of the kyphosis was observed at 24 months postoperatively. The patient signed informed consents. In our case, the patient accepted regular and proved therapy, so the ethical approval was not necessary.

3. Discussion

Previous reports regarding the treatment for thoracolumbar kyphosis in achondroplasia patients have focused mainly on immature patients. In immature patients, posterior decompression alone or in association with noninstrumented posterior fusion leads systematically to an increase of the deformity,^[7] which results in ongoing pain with neurological worsening. In cases of thoracolumbar kyphosis below approximately 30°, the addition of an *in situ* instrumentation fusion to the posterior decompressive laminectomy and foraminotomy may be performed with good outcome.^[3] For kyphosis above approximately 30°, front and back fusion is the recommended treatment.^[3] Many authors emphasize the neurological risk in cases of rigid deformity, which is increased by the congenitally narrowed spinal canal.^[8,9] A large kyphotic angle or an anteriorly compromised spinal cord at the level of the deformity sometimes requires an anterior release.^[10]

The treatment of rigid angular thoracolumbar kyphosis in skeletally mature achondroplastic patients has not been reported in detail. Qi et al. performed a single-stage posterior osteotomy in 4 skeletally mature achondroplastic patients with severe and fixed thoracolumbar kyphosis.^[11] Although the procedures were technically demanding in the achondroplastic spine, with rigid curves associated with malformation of the vertebrae, they concluded that posterior spinal osteotomy with segmental instrumentation is a reasonable surgical option for thoracolumbar kyphosis in patients with achondroplasia.

The decision on the amount of correction should be made with consideration of the sagittal balance of the patient. The sagittal

curve of the patient while standing is influenced by thoracolumbar kyphosis, lumbar hyperlordosis, and contracture of the hip joints. In aged achondroplastic patients, lumbar hyperlordosis and hip flexion are almost fixed. Therefore, correction of the kyphosis may not be compensated by the lumbar spine and hip joints in these patients. Furthermore, when the spine is overcorrected and fused, these patients may have difficulty reaching their hands below the hip. Qi et al reported a case in which the patient developed difficulty in reaching their buttock at defecation after surgery. Thus, overcorrection of kyphosis, especially in an elderly patient with a rigid spine and short limbs, may cause disability in using the upper extremities below the torso.^[11]

In patients with achondroplasia, interpedicular distance progressively decreases. This process leads to a much greater incidence of spinal stenosis in this population. The laminae in this population are so narrow that an adequate decompressive laminectomy requires marked resection of the medial facets, potentially leading to instability. Standard lumbar decompressive surgery has proven to be more difficult in patients with achondroplasia. These patients generally have much thicker and shorter laminae, which makes removal with standard hand tools much more difficult. In addition, the shape of the laminae renders posterior interbody arthrodesis much more difficult and dangerous. Lateral interbody fusion has been shown to restore foraminal height, disc angle, and overall lumbar lordosis better than standard transforaminal lumbar interbody fusion in the normal adult population, and this approach also appears to be a viable option for the achondroplastic population. Achondroplastic dwarfism leads to markedly increased incidence of neurological symptoms secondary to abnormal bony fusion during development and the subsequent degenerative cascade of the spine.

In the present case, a 61-year-old man presented with low back pain and radiculopathy and neurogenic claudication, and multiple canal stenoses were related to this neurological deficit. Circumferential decompression of the spinal cord at the apical

vertebral level and decompression of lumbar canal stenosis were necessary. We selected a front-back correction of the anterior and posterior spinal elements with spondylectomy and lateral lumbar interbody fusion. We consider these procedures to be a reasonable surgical option for thoracolumbar kyphosis and developmental canal stenosis in patients with achondroplasia. To the best of our knowledge, this is the first published case in which spondylectomy and minimally invasive lateral access interbody arthrodesis were used for the treatment of fixed severe thoracolumbar kyphosis and lumbar spinal canal stenosis in an adult patient with achondroplasia.

References

- [1] Rousseau F, Bonaventure J, Legeai-Mallet L, et al. Mutations in the gene encoding fibroblast growth factor receptor-3 in achondroplasia. *Nature* 1994;371:252–4.
- [2] Hecht JT, Butler IJ. Neurologic morbidity associated with achondroplasia. *J Child Neurol* 1990;5:84–97.
- [3] Misra SN, Morgan HW. Thoracolumbar spinal deformity in achondroplasia. *Neurosurg Focus* 2003;14:e4.
- [4] Pyeritz RE, Sack GH Jr, Udvarhelyi GB. Thoracolumbosacral laminectomy in achondroplasia: long-term results in 22 patients. *Am J Med Genet* 1987;28:433–44.
- [5] Guerin P, Obeid I, Bourghli A, et al. The lumbosacral plexus: anatomic considerations for minimally invasive retroperitoneal transpsoas approach. *Surg Radiol Anat* 2012;34:151–7.
- [6] Pawar A, Hughes A, Girardi F, et al. Lateral lumbar interbody fusion. *Asian Spine J* 2015;9:978–83.
- [7] Ain MC, Shirley ED, Pirouzmanesh A, et al. Postlaminectomy kyphosis in the skeletally immature achondroplast. *Spine (Phila Pa 1976)* 2006;31:197–201.
- [8] Lonstein JE. Treatment of kyphosis and lumbar stenosis in achondroplasia. *Basic Life Sci* 1988;48:283–92.
- [9] Tolo VT. Surgical treatment of kyphosis in achondroplasia. *Basic Life Sci* 1988;48:257–9.
- [10] Ain MC, Browne JA. Spinal arthrodesis with instrumentation for thoracolumbar kyphosis in pediatric achondroplasia. *Spine (Phila Pa 1976)* 2004;29:2075–80.
- [11] Qi X, Matsumoto M, Ishii K, et al. Posterior osteotomy and instrumentation for thoracolumbar kyphosis in patients with achondroplasia. *Spine (Phila Pa 1976)* 2006;31:E606–10.