



A case of relapsing aseptic meningitis under excellent tumor response to pembrolizumab in microsatellite instability-high recurrent endometrial cancer

Daito Noguchi, Toshiyuki Seki^{*}, Yutaro Kubonoya, Hiromi Komazaki, Hirokazu Ozone, Nozomu Yanaihara, Hirokuni Takano, Aikou Okamoto

Department of Obstetrics and Gynecology, The Jikei University School of Medicine, 3-25-8 Nishi-Shinbashi, Minato-ku, Tokyo 105-8461, Japan

ARTICLE INFO

Keywords:

Pembrolizumab
Immune checkpoint inhibitor
Immune-related adverse events
Meningitis
Endometrial cancer

1. Introduction

The use of immune checkpoint inhibitors (ICIs) for a wide range of malignant tumors is now common practice. Notably, in 2017, the FDA approved the anti-PD-1 antibody pembrolizumab for the treatment of solid tumors with a microsatellite instability-high (MSI-H)/mismatch repair deficiency (dMMR) regardless of tumor origin. It was the first approved anti-cancer drug based on tumor genetics regardless of tissue type or tumor site.

Among solid tumors, endometrial cancer has been reported to be one of the most common tumors with MSI-H/dMMR, as approximately 15%–40% of endometrial cancer is MSI-H (Bonneville et al., 2017). Consequently, patients with endometrial cancer are increasingly treated with pembrolizumab.

Despite the remarkable anti-tumor effect of these drugs, ICIs are associated with unique side effect profiles, namely, immune-related adverse events (irAEs), due to imbalances in immune tolerance.

Among irAEs, neurological complications, such as aseptic meningitis, are rare (Cuzzubbo et al., 2017). Here, we describe the first case of ICI-induced severe aseptic meningitis in a patient with endometrial cancer, who exhibited an excellent oncologic outcome after the meningitis resolved.

Case

A 56-year-old, gravida 1, para 0, Japanese woman presented to our

hospital with abdominal swelling and constipation. A gynecological examination and imaging studies revealed a bulky uterus with a thickened endometrium that had invaded the sigmoid colon without distant metastasis. Endometrial biopsy revealed a grade 3 endometrioid carcinoma. She was then diagnosed with endometrial cancer, which was localized in the pelvic area; after which, she underwent primary surgery consisting of total abdominal hysterectomy, bilateral salpingo-oophorectomy, partial small bowel resection, sigmoidectomy, and stoma formation to achieve complete resection. On the basis of surgical and pathological findings, the tumor was staged as IIIC1 (according to The International Federation of Gynecology and Obstetrics staging system), pT2N1M0 (Union for International Cancer Control, 8th edition), and the histological type was grade 1 endometrioid carcinoma. Following primary surgery, six cycles of paclitaxel and carboplatin adjuvant chemotherapy were administered; after which, an imaging study revealed no evidence of disease. Sixty days after the last chemotherapy dose, computed tomography (CT) for routine monitoring revealed a pelvic mass, which obstructed left ureter flow and caused hydro nephrosis (Fig. 1A). Urologists placed a nephrostomy tube for kidney dysfunction. To determine the best approach for managing the recurrent tumor, microsatellite instability of the tumor specimen was tested (FALCO, Kyoto, Japan) and was found to be MSI-H. Therefore, pembrolizumab (200 mg) was administered as a second-line treatment.

Thirteen days after the first dose of pembrolizumab, she presented to

^{*} Corresponding author..

E-mail address: t_seki@jikei.ac.jp (T. Seki).

<https://doi.org/10.1016/j.gore.2021.100885>

Received 20 August 2021; Received in revised form 12 October 2021; Accepted 18 October 2021

Available online 23 October 2021

2352-5789/© 2021 The Authors.

Published by Elsevier Inc.

This is an open access article under the CC BY-NC-ND license

(<http://creativecommons.org/licenses/by-nc-nd/4.0/>).

our hospital and was admitted because of a 40 °C fever, headache, and impaired consciousness (Fig. 2A). An initial physical examination showed a high fever of 40.7 °C, tachycardia (113/min), and a normotensive state (112/74 mmHg). A neurological examination revealed a stiff neck and disorientation to time, place, and person (Glasgow Coma Scale rating of E3V4M5). Blood tests showed a normal white blood cell count (6500/ μ L) and normal levels of C-reactive protein (0.08 mg/dL) and procalcitonin (0.06 ng/mL). Intravenous Tazobactam/Piperacillin (13.5 mg/day) were started as empiric antibiotics for a possible infectious disease and continued for 5 days. Body temperature decreased to a normal range over time, but there was no recovery from neurological

symptoms. Therefore, the neurologist performed a spinal tap on the 3rd day after the onset. Cerebrospinal fluid analysis demonstrated the presence of 54 nucleated cells (6% polymorphonucleocytes and 94% monocytes), an elevated protein concentration of 243 mg/dL, a decreased glucose level of 43 mg/dL, and negative cytology for neoplastic cells and bacterial culture. Brain magnetic resonance imaging and CT were unremarkable. At the 20 days after pembrolizumab, her body temperature rose again up to 40 °C. Therefore, a neurologist diagnosed this patient with aseptic meningitis due to pembrolizumab (Common Terminology Criteria for Adverse Events Ver 4.0 Grade 4), and consequently, pulsed steroid therapy of intravenous

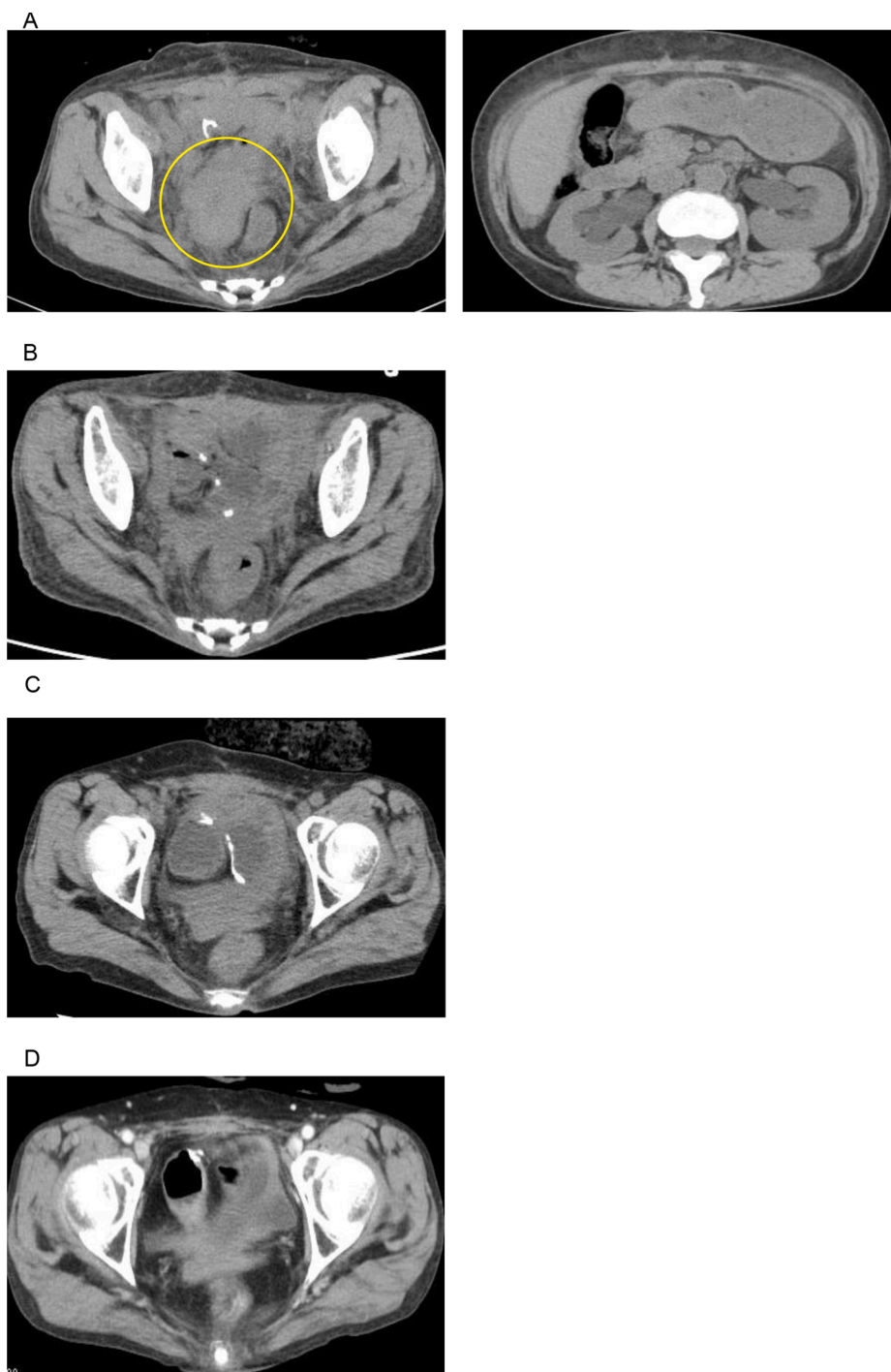


Fig. 1. Tumor imaging study. (A) Before pembrolizumab administration. A recurrent tumor is encircled. (B) Fifty-three days after pembrolizumab. The tumor was undetectable (C) After chemotherapy. (D) Twenty-two months after pembrolizumab.

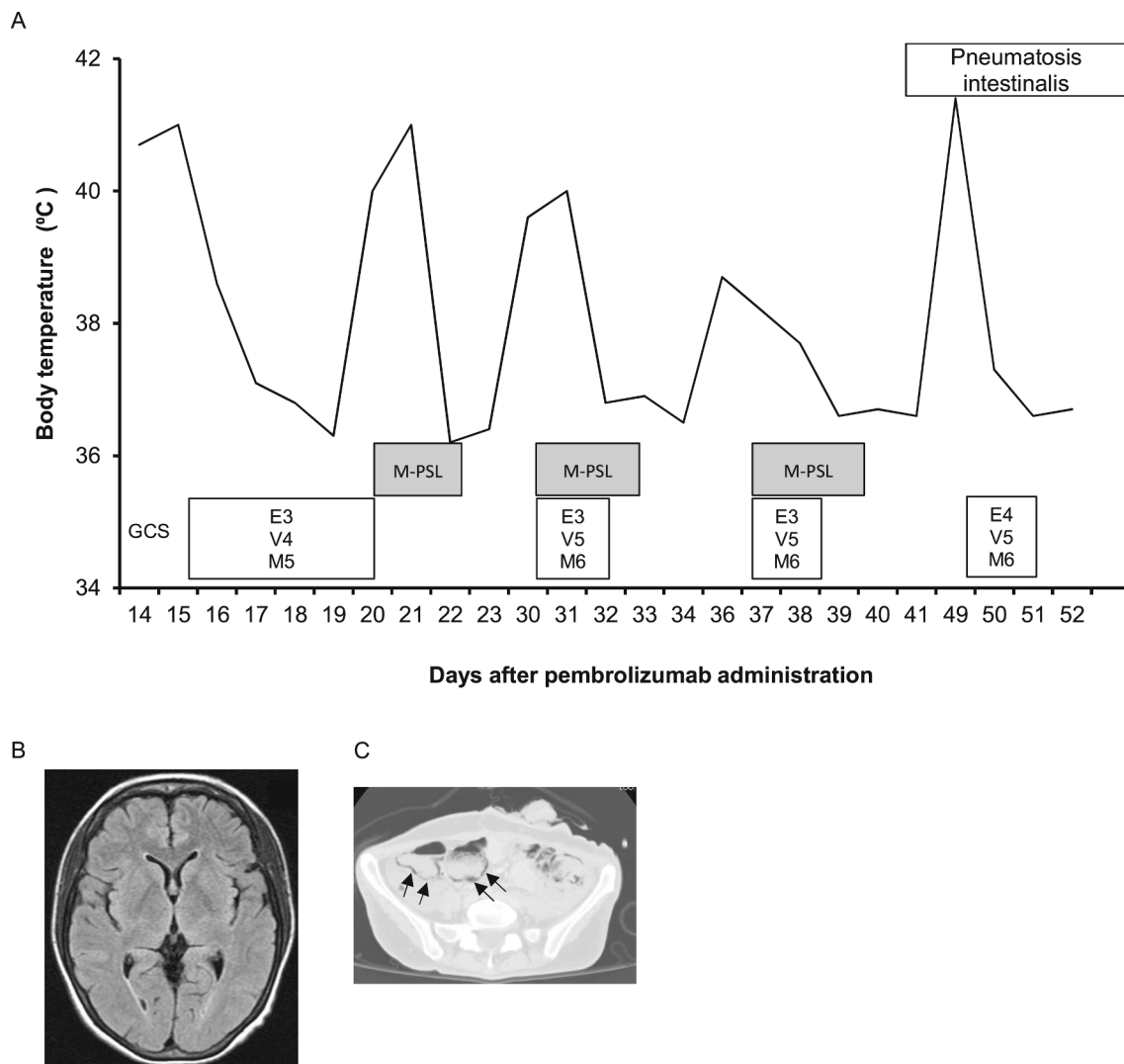


Fig. 2. (A) Clinical course after meningitis onset. M-PSL, methylprednisolone; GCS, Glasgow Coma Scale. (B) Imaging study showing pneumatosis intestinalis; arrows indicate gas in the intestinal wall.

methylprednisolone succinate (100 mg/day) was initiated. There was no sign of viral meningitis, such as brain edema, on the imaging study, and anti-viral therapy was not initiated (Fig. 2B). On day 2 of methylprednisolone treatment, her body temperature decreased to 36.2 °C and her consciousness returned to normal (Fig. 2A). When 3 planned days of steroid pulse therapy had completed and the symptoms had resolved completely, the neurologist decided to stop steroid treatment instead of tapering it, because of concerns regarding the risks of long-term steroid use, such as thrombosis, which cancer patients are at high risk of. Thirty days after pembrolizumab administration, she exhibited a high fever of 39.6 °C. With mild neurological symptoms and a normal white blood cell count, meningitis relapse was suspected. Therefore, a second cycle of the same regimen of pulsed steroid therapy was initiated, and her body temperature was normal the following day. Then, the blood culture that had been taken at the onset turned out to be negative. We diagnosed it as the recurrence of meningitis. Thirty-five days after pembrolizumab administration, meningitis recurred along with a fever of 38.7 °C, and she received the same pulsed steroid therapy, which was effective (Fig. 2A). Spinal tap was performed again, showing the presence of 7 nucleated cells, and there was an elevated protein concentration of 118 mg/dL and negative bacterial culture. Forty-eight days after pembrolizumab administration, her body temperature increased again to 41.2 °C (Fig. 2B). Because of high fever, chest and abdominal CT was

performed for surveillance of infection, which revealed pneumatosis intestinalis due to multiple doses of pulsed steroid therapy (Fig. 2B). Although it was difficult to rule out the possibility of meningitis relapse, this patient was followed up without any specific medication because this intestinal event was believed to be induced by steroid therapy (Lee et al.) Fortunately, 5 days after the onset, abdominal CT revealed no abnormal intestinal findings. Oral steroids to prevent meningitis recurrence were avoided because of this adverse event. Fifty-three days after pembrolizumab administration, CT showed a complete tumor regression, and the patient was discharged from our hospital 45 days after admission (Fig. 1B). Then, 110 days after pembrolizumab administration, chemotherapy with doxorubicin and cisplatin was initiated for consolidation therapy. After 4 cycles of doxorubicin and cisplatin, the CT scans also showed no pelvic tumors (Fig. 1C). Nineteen months after pembrolizumab administration and subsequent chemotherapy, she is still alive with no tumor recurrence or neurological complications, even though she was resistant to platinum chemotherapy (Fig. 1D).

2. Discussion

We report a patient with recurrent endometrial cancer who developed severe and relapsing aseptic meningitis after a single dose of pembrolizumab, but she eventually overcame the event in collaboration

with a neurologist and achieved an excellent oncologic outcome.

Neurological disorders caused by ICIs are rare, as they account for approximately 5% of all irAEs (Cuzzubbo et al., 2017; Spain et al., 2017). Neurological irAEs, such as encephalitis, myelitis, meningitis, meningoradiculitis, Guillen-Barre-like syndrome, peripheral neuropathy, and myasthenic syndrome, have been documented and can involve all areas of the central and peripheral nervous systems (Cuzzubbo et al., 2017; Spain et al., 2017).

The frequency of aseptic meningitis is relatively low among neurological irAEs because this accounts for 6.1% of all irAEs and is not usually severe, as < 1% meningitis cases have been reported to be grade 3 or 4 (Cuzzubbo et al., 2017). Although ICI-associated meningitis has been documented in several series and, its clinical features remain poorly understood. Therefore, to better understand this complication, we reviewed reported cases of ICI-induced aseptic meningitis. We identified 46 cases in published English language literature. No case of endometrial cancer was reported. We summarized the reports of 18 cases of ICI-related aseptic meningitis, for which detailed information was available, in Table 1. This summary indicates that meningitis was more likely to occur after 1–11 (median 2) doses of ICIs and that grade 3/4 meningitis can occur, but no patients died. Most cases were treated with steroids, which seems highly effective. After single steroid infusions, many cases with meningitis tended to recover immediately/within 10 days, and most did not experience meningitis recurrence unless ICIs were re-administered. In our case, however, the patient experienced multiple meningitis recurrences that required multiple pulsed steroid therapy, which resulted in pneumatosis intestinalis. That was probably due to the long clearance time of pembrolizumab, whose half-life in plasma is approximately 27 days (Centanni et al., 2019). Thus, although aseptic meningitis due to pembrolizumab is an essentially treatable irAE by steroid therapy, this event can be prolonged because of the long clearance time such that long-term oral steroid treatment should be carefully considered. In fact, current guidelines published by the National Comprehensive Cancer Network (NCCN) in 2021 describe, in the recommendations aseptic meningitis management due to ICIs, that a methylprednisolone dose of 1–2 mg/kg/day should be provided for moderate to severe symptoms (corticosteroid at 0.5–1 mg/

kg/day for mild case) and corticosteroids should be tapered rapidly once the symptoms resolve (over 4 weeks) (NCCN Guidelines Version 3, 2021). In our case, we did not taper steroids in each symptom of meningitis. A neurologist preferred to avoid long-term continuous steroid use, because aseptic meningitis due to ICIs should be fully recovered in reported cases, and that may lead to adverse events such as thrombosis, which cancer patients are at risk of (Johannesdottir et al., 2013). However, in retrospect, the tapering of steroids would be a better treatment option for this kind of case following a more thorough discussion with the neurologist.

Furthermore, this patient demonstrated an excellent oncologic outcome, which should be noted. Generally, the prognosis of recurrent endometrial cancer with a treatment-free interval of < 6 months is poor, and in such cases, progression-free survival and overall survival were reported to be 3.2 and 11.3 months, respectively (Nagao et al., 2013). However, a single dose of pembrolizumab plus 4 cycles of chemotherapy led to a long-term cancer-free survival in this case. It is known that the occurrence of irAE is a therapeutic biomarker of ICIs (Rogado et al., 2019). From this perspective, overcoming irAE leads to favorable oncologic outcomes. Therefore, it is imperative to provide patients access to multidisciplinary medical services in case of various types of severe irAEs. Moreover, sharing information on rare irAEs among gynecologic oncologists will enable appropriate communication with physicians in other departments who may not be familiar with ICIs. This will result in appropriate management of irAEs and eventually satisfactory oncologic outcomes.

In conclusion, we report the first case of severe aseptic meningitis as an irAE in uterine endometrial cancer. Although meningitis usually resolves quickly with steroid treatment, it may recur as found in this case. Because the use of pembrolizumab for uterine endometrial cancer is expected to increase, gynecologic oncologists should be aware of ICI-induced aseptic meningitis and provide appropriate management with multidisciplinary care.

3. Informed consent and patient details

Written informed consent was obtained from the patient for

Table 1

Cases reported with aseptic meningitis due to ICIs. NA: not available, IV: intravenous infusion, ICI: immune checkpoint inhibitor.

Cases	Author	Year	Tumor	Regimen	Cycles to onset	Grades	Treatment	Recurrence of meningitis	Time to recovery	Re-administration of ICI
1	Yang et al.	2007	Renal cell cancer	ipilimumab	4	3 or 4	IV dexamethasone	–	NA	NA
2	Ilja Bot et al.	2013	Malignant melanoma	ipilimumab	1	NA	Oral prednisolone	–	2 days	NA
3	Vokens et al.	2013	Malignant melanoma	ipilimumab	1	3	steroid	–	NA	No
4	Stein et al.	2015	Ocular melanoma	ipilimumab	4	3 or 4	IV dexamethasone → Oral	–	N/A	NA
5	Oishi et al.	2016	Breast cancer	ipilimumab	3	3	IV Methylprednisolone → Oral	–	rapidly recovered	No
6	Nanda et al.	2016	Malignant melanoma	pembrolizumab	NA	3	Oral steroid	–	NA	Yes
7	Spain et al.	2017	Malignant melanoma	ipilimumab	2	3	No specific treatment	–	10 days	NA
8	Spain et al.	2017	Malignant melanoma	ipilimumab	2	3	Oral prednisolone	–	8 weeks	NA
9	Spain et al.	2017	Malignant melanoma	ipilimumabnivolumab	1	2	No treatment	–	4 weeks	Yes
10	Feng et al.	2017	Lung Ca	pembrolizumab	2	NA	IV dexamethasone → Oral	–	3 days	NA
11	Takamatsu et al.	2019	Renal cell carcinoma	Ipilimumab nivolumab	2	3	IV prednisolone → Oral	+	50 days	Given but meningitis recurred
12	Lima et al.	2019	lung adenocarcinoma	pembrolizumab	11	3	IV dexamethasone → Oral	–	1 day	No
13	This case	2019	Endometrioid carcinoma	pembrolizumab	1	4	IV dexamethasone	+	50 days	No

publication of this case report and accompanying images. A copy of the written consent is available for review by the Editor-in-Chief of this journal on request.

CRediT authorship contribution statement

Daito Noguchi: Writing – original draft, Resources. **Toshiyuki Seki:** Writing – original draft, Writing – review & editing. **Yutaro Kubonoya:** Resources. **Hiromi Komazaki:** Resources. **AHirokazu Ozone:** . **Nozomu Yanaihara:** Supervision. **Hirokuni Takano:** Supervision. **Aikou Okamoto:** Supervision.

Declaration of Competing Interest

The authors declare that they have no known competing financial interests or personal relationships that could have appeared to influence the work reported in this paper.

Acknowledgement

This research was supported by The Jikei University Research Fund Grant number 2021-016SR.

References

Bonneville, R., Krook, M.A., Kautto, E.A., Miya, J., Wing, M.R., Chen, H.-Z., Reeser, J.W., Yu, L., Roychowdhury, S., 2017. Landscape of Microsatellite Instability Across 39 Cancer Types. *JCO Precis. Oncol.* (1), 1–15. <https://doi.org/10.1200/PO.17.00073>.

Centanni, M., Moes, D.J.A.R., Trocóniz, I.F., Ciccolini, J., van Hasselt, J.G.C., 2019. Clinical Pharmacokinetics and Pharmacodynamics of Immune Checkpoint Inhibitors. *Clin. Pharmacokinet.* 58 (7), 835–857. <https://doi.org/10.1007/s40262-019-00748-2>.

Cuzzubbo, S., Javeri, F., Tissier, M., Roumi, A., Barlog, C., Doridam, J., Lebbe, C., Belin, C., Ursu, R., Carpentier, A.F., 2017. Neurological adverse events associated with immune checkpoint inhibitors: Review of the literature. *Eur. J. Cancer* 73, 1–8. <https://doi.org/10.1016/j.ejca.2016.12.001>.

Johannesdottir, S.A., Horváth-Puhó, E., Dekkers, O.M., Cannegieter, S.C., Jørgensen, J.O. L., Ehrenstein, V., Vandenbroucke, J.P., Pedersen, L., Sørensen, H.T., 2013. Use of Glucocorticoids and Risk of Venous Thromboembolism: A Nationwide Population-Based Case-Control Study. *JAMA Intern. Med.* 173 (9), 743. <https://doi.org/10.1001/jamainternmed.2013.122>.

Nagao, S., Nishio, S., Michimae, H., Tanabe, H., Okada, S., Otsuki, T., Tanioka, M., Fujiwara, K., Suzuki, M., Kigawa, J., 2013. Applicability of the concept of “platinum sensitivity” to recurrent endometrial cancer: The SGSG-012/GOTIC-004/Intergroup study. *Gynecol. Oncol.* 131 (3), 567–573. <https://doi.org/10.1016/j.ygyno.2013.09.021>.

National Comprehensive Cancer Network. 2021. NCCN Clinical Practice Guidelines in Oncology: Management of immunotherapy-related toxicities. Version 3. 2021. <https://www.nccn.org/guidelines/guidelines-detail> (accessed 25 September 2021).

Rogado, J., Sánchez-Torres, J.M., Romero-Laorden, N., Ballesteros, A.I., Pacheco-Barcia, V., Ramos-Leví, A., Arranz, R., Lorenzo, A., Gullón, P., Donnay, O., Adrados, M., Costas, P., Aspa, J., Alfranca, A., Mondéjar, R., Colomer, R., 2019. Immune-related adverse events predict the therapeutic efficacy of anti-PD-1 antibodies in cancer patients. *Eur. J. Cancer* 109, 21–27. <https://doi.org/10.1016/j.ejca.2018.10.014>.

Spain, L., Walls, G., Julve, M., O'Meara, K., Schmid, T., Kalaitzaki, E., Turajlic, S., Gore, M., Rees, J., Larkin, J., 2017. Neurotoxicity from immune-checkpoint inhibition in the treatment of melanoma: a single centre experience and review of the literature. *Ann. Oncol.* 28 (2), 377–385. <https://doi.org/10.1093/annonc/mdw558>.