

Oncology

An Adult Paratesticular Malignant Ectomesenchymoma With Post-operative Flare-up of Lung Metastasis

Wei-Tang Kao, Yi-Te Chiang, Kai-Yi Tzou*

Department of Urology, Taipei Medical University, Shuang Ho Hospital, New Taipei, Taiwan, ROC



ARTICLE INFO

Article history:

Received 16 June 2015

Accepted 25 June 2015

Available online 15 July 2015

Keywords:

Ectomesenchymoma

Paratesticular tumor

Lung metastasis

ABSTRACT

Malignant ectomesenchymoma (MEM) which is derived from the remnants of migratory neural crest cells (ectomesenchyme) is a rare and rapidly progressing tumor consisting of neuroectodermal and mesenchymal neoplastic elements. This tumor occurs mostly in children and adolescents, but rarely in adults. We report a 34-year-old male with left paratesticular malignant ectomesenchymoma who received radical orchiectomy and was followed by post-operative flare-up of lung metastasis within 2 weeks. We present the overall treatment strategies for this extremely rare tumor and related findings.

© 2015 The Authors. Published by Elsevier Inc. This is an open access article under the CC BY-NC-ND license (<http://creativecommons.org/licenses/by-nc-nd/4.0/>).

Introduction

Malignant ectomesenchymoma (MEM) which is derived from the remnants of migratory neural crest cells (ectomesenchyme) is a rare and rapidly progressing tumor consisting of neuroectodermal and mesenchymal neoplastic elements.¹ This tumor has been reported to occur mostly in children and adolescents, with its origin from brain, face and neck, abdomen, retroperitoneal space, pelvic cavity, perineum, scrotum, and limbs.¹ To date, only seven scrotal malignant ectomesenchymomas have been reported. Here we report the eighth case of paratesticular malignant ectomesenchymoma and emphasize its occurrence in an adult with post-operative flare-up of lung metastasis.

Case presentation

A 34-year-old male visited our out-patient clinic with the painless left testicular mass for 1 month. Prior to this, he did not have any history of scrotal trauma, scrotal surgery, infection, and cryptorchidism. Physical examination revealed a swollen left scrotum with a painless solid mass. Ultrasound examination showed a heterogenous solid mass of 75 × 40 mm in size. The levels of lactic dehydrogenase (120 U/mL), alpha-fetoprotein (0.92 ng/mL), and beta human chorionic gonadotropin (0.19 mIU/mL) were

all within normal limits. The contrast-enhanced computed tomography demonstrated the presence of a heterogenous tumor in the left scrotum area (Fig. 1). Chest x-ray showed no evidence of lung tumor. A radical orchiectomy was performed. After an uneventful post-operative period, the patient was discharged from hospital. Over a two-week post-operative follow-up, multiple lung tumors were found on chest x-ray. CT-guided lung mass biopsy was performed. The pathology revealed a metastatic malignant ectomesenchymoma that was compatible with the previous scrotum lesion. He was referred to the medical oncology department to receive further chemotherapy treatment.

Histopathological examination showed a yellowish white and elastic tumor measuring 7.5 × 4.0 × 3.6 cm in size was found to be located in the para-testicular soft tissue. The testis was not involved. The tumor had two components connecting with each other. The main component was composed of an alternating area of hypercellularity and myxoid tissues. The compact hypercellular area was composed of hyperchromatic cells with moderately pleomorphic nuclei and scattered multinucleated giant tumor cells. The myxoid area exhibited scattered spindle cells in mucoid stroma with increased mitotic activity. The other components of the tumor were composed of spindle cells with wavy nuclei arranged in loose, irregularly oriented bundles and scattered ganglion cells. Immunohistochemical staining showed the main component of the tumor cells were positive for desmin, myogenin, and myoglobin, and negative for SMA, S100, cytokeratin, EMA, synaptophysin and CD34. Thus, anaplastic embryonal rhabdomyosarcoma was considered. The other components of the tumor showed that the spindle cells were positive for S100, and negative for desmin, myoglobulin, myogenin and SMA. The ganglion cells

* Corresponding author. Department of Urology, Taipei Medical University, Shuang Ho Hospital, No. 291 Jhongjheng Rd., Jhonghe District, New Taipei City 23561, Taiwan, ROC. Tel.: +886 2 2249 0088x8111; fax: +886 2 2249 0088x8760.
E-mail address: Kaietzou@gmail.com (K.-Y. Tzou).

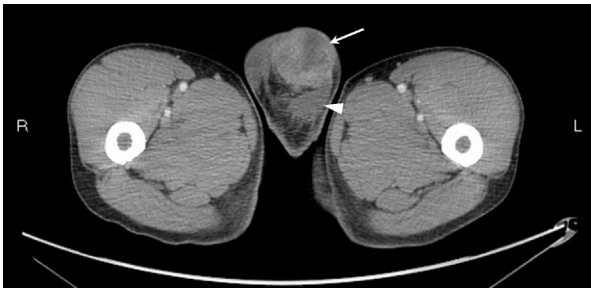

Figure 1. Pelvic CT scan showing heterogenous tumor in left scrotum (arrow) and left testis (arrowhead).

were positive for synaptophysin. Ganglioneuroma was taken into consideration. Consequently, a malignant ectomesenchymoma was more likely based on the combined pathologic findings mentioned above (Fig. 2).

Discussion

Malignant ectomesenchymomas (MEMs) are extremely rare tumors with about 50 cases, mostly involving children and infants, having been reported to date. Characterized by merged features of neuroectodermal and mesenchymal components,² the most common neuroectodermal component is ganglioneuroblastoma, or neuroblastoma,² whereas the most common mesenchymal components are embryonal rhabdomyosarcoma or other malignant mesenchymal components.³ Some MEMs have been diagnosed as pure rhabdomyosarcoma in the beginning.⁴

Only seven cases of MEM involving the scrotum region have been noted (Table 1)^{3,11} and six of these were localized tumors followed by surgical resection and post-operative chemotherapy or radiotherapy.^{3,11} The prevalence age for these seven cases ranged from 2 months to 20 year old and mostly involved infants and children below the age of three. Our patient would appear to be the eldest patient observed after a review of the related literature. MEMs usually spread en route circulation to lung or bone, or en route through the lymphatic system to retroperitoneal lymph nodes.¹² To the best of our knowledge, our case is the first with the characteristic of flare-up of lung metastatic lesions after surgical excision of the primary tumor.

Due to the rarity of these cancers, the standard therapeutic strategy that should be employed is ambiguous. To date, the most favorable therapeutic strategy for scrotal ectomesenchymoma is surgical resection to be as complete as possible and most of cases received complete tumor resection at diagnosis. Anatomically, it would be easier to perform complete resection of scrotal MEMs than other MEMs which originate from other organs and the outcomes certainly would be better. According to certain reports, chemotherapy also plays an important role in the treatment of MEMs.² The fact that most mesenchymal components of ectomesenchymomas are rhabdomyosarcoma actually facilitates the selection of various chemotherapeutic agents by referring to the therapies for rhabdomyosarcoma.

A poor prognosis was speculated in our case based on the prognosis-affected factors of MEM. Two considerations affect the prognosis of MEM predominately. The first point is the flare-up of lung metastasis post radical orchiectomy, which could be considered as the crucial indicator of prognosis. The second point is the age of the patient. Age factor may be also relate to survival, as

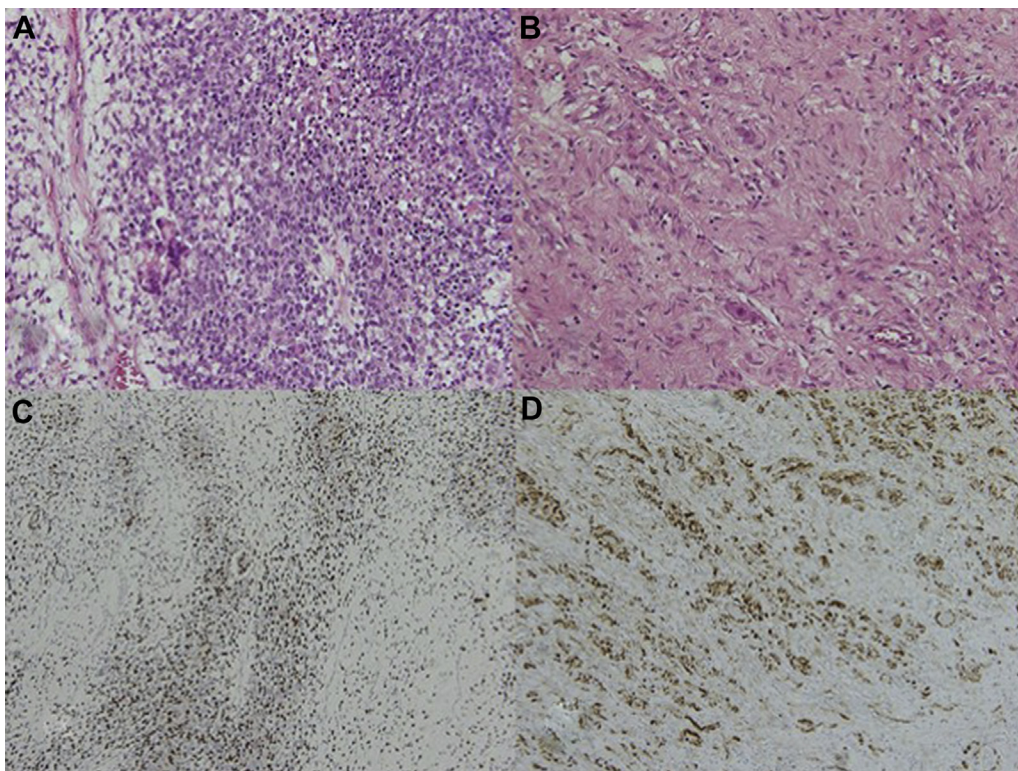


Figure 2. Histological features of MEM. A) The rhabdomyosarcoma component showed alternating cellular and myxoid area, hyperchromatic cells associated with moderately pleomorphic nuclei, and scattered multinucleated tumor cells (H&E $\times 200$). B) The ganglioneuroma component showed spindle cells with wavy nuclei arranged in loose irregularly oriented bundles with scattered ganglion cells (H&E $\times 200$). C) The rhabdomyosarcoma component was positive for *Myogenin* (Immunohistochemical stain for *Myogenin*, $\times 100$). D) The ganglioneuroma component was positive for *S100* (Immunohistochemical stain for *S100* $\times 100$).

Table 1
Literature review of scrotal MEM

Reference	Year	Age	Origin site	Histology	Treatment	Follow-up
Cozzuto et al. ⁵	1982	3 y/o	Paratesticular	Ganglion cells, Rhabdomyosarcoma	S + C	No recurrence after 3 years
Kodet et al. ⁶	1986	7 m/o	Paratesticular	Ganglioneuroma, Rhabdomyosarcoma	S + R + C	No recurrence after 12 years
Kasantikul et al. ⁷	1987	20 y/o	Scrotum	Ganglioneuroma, Rhabdomyosarcoma	ND	ND
Kilpatrick ⁸	1994	10 m/o	Scrotum	Mature ganglion cell, Rhabdomyosarcoma	ND	Alive 9.5 years
Mouton et al. ⁹	1996	7 m/o	Scrotum	Ganglion cells, Rhabdomyoblast, miscellaneous cells	S + C	No recurrence 7 months
Mouton et al. ⁹	1996	2 m/o	Scrotum	Neural components, miscellaneous cells	C + S	No recurrence 32 months
Edwards et al. ¹⁰	1999	13 y/o	Paratesticular	T: Rhabdomyosarcoma, RP: Ganglion cell + Rhabdomyosarcoma	S + R + C	RP Meta at 2 years
	Present	34 y/o	Paratesticular + Lung meta	Embryonal rhabdomyosarcoma Ganglioneuroma	S + C	Alive 6 months

C, Chemotherapy; Meta, Metastasis; ND, No data available; R, Radiotherapy; RP, Retroperitoneum; S, Surgery; T, Testis.

patients at an age higher than 10 years old could show a worse prognosis in cases of rhabdomyosarcoma,⁸ and the prognosis of MEM is known to be worse than rhabdomyosarcoma.⁴

Conclusion

We report a rare case of paratesticular MEMs which shows flare-up lung metastasis after radical orchiectomy.

Conflicts of interests

The authors declare they have no conflicts of interest.

References

- Patil CN, Cyriac S, Majhi U, et al. Malignant ectomesenchymoma of the nasal cavity. *Indian J Med Paediatr Oncol*. 2011;32(4):242–243.
- Dantonello TM, Leuschner I, Vokuhl C, et al. Malignant ectomesenchymoma in children and adolescents: report from the Cooperative Weichteilsarkom Studiengruppe (CWS). *Pediatr Blood Cancer*. 2013;60(2):224–229.
- Oppenheimer O, Athanasian E, Meyers P, et al. Malignant ectomesenchymoma in the wrist of a child: case report and review of the literature. *Int J Surg Pathol*. 2005;13(1):113–116.
- Howley S, Stack D, Morris T, et al. Ectomesenchymoma with t(1;12)(p32;p13) evolving from embryonal rhabdomyosarcoma shows no rearrangement of ETV6. *Hum Pathol*. 2012;43(2):299–302.
- Cozzuto C, Comelli A, Bandelloni R. Ectomesenchymoma. Report of two cases. *Virchows Arch A Pathol Anat Histopathol*. 1982;398(2):185–195.
- Kodet R, Kasthuri N, Marsden HB, Coad NA, Raafat F. Ganglioneuroma-rhabdomyosarcoma: a histopathological and immunohistochemical study of three cases. *Histopathology*. 1986;10(2):181–193.
- Kasantikul V, Shuangshoti S, Cutchavaree A, Bunyaphiphat P. Parapharyngeal malignant ectomesenchymoma: combined malignant fibrous histiocytoma and primitive neuroectodermal tumour with neuroglial differentiation. *J Laryngol Otol*. 1987;101(5):508–515.
- Kilpatrick SE, Teot LA, Geisinger KR, et al. Relationship of DNA ploidy to histology and prognosis in rhabdomyosarcoma. Comparison of flow cytometry and image analysis. *Cancer*. 1994;74(12):3227–3233.
- Mouton SC, Rosenberg HS, Cohen MC, Drut R, Emms M, Kaschula RO. Malignant ectomesenchymoma in childhood. *Pediatric Pathol Lab Med*. 1996;16(4):607–624.
- Edwards V, Tse G, Doucet J, Pearl R, Phillips MJ. Rhabdomyosarcoma metastasizing as a malignant ectomesenchymoma. *Ultrastruct Pathol*. 1999;23(4):267–273.
- Freitas AB, Aguiar PH, Miura FK, et al. Malignant ectomesenchymoma. Case report and review of the literature. *Pediatr Neurosurg*. 1999;30(6):320–330.
- Paikos P, Papathanassiou M, Stefanaki K, et al. Malignant ectomesenchymoma of the orbit in a child: case report and review of the literature. *Surv Ophthalmol*. 2002;47(4):368–374.