



Case Report

Idiopathic Lumbosacral Neuropathy Syndrome: Case Report

Aylin Ayyildiz, Beril Dogu, Selda Ciftci, Figen Yilmaz, Banu Kuran

Department of Physical Medicine and Rehabilitation, University of Health Sciences Turkey, Sisli Hamidiye Etfal Teaching and Resarch Hospital, Istanbul Turkey

Abstract

Idiopathic lumbosacral plexitis or lumbosacral radiculoplexus neuropathy is a disease characterized by nerve damage in lumbar and/or sacral plexus without trauma, mass effect or diabetic complications. A 47-year-old male patient with right groin pain and loss of right leg muscle strength is presented in this case report. Neuropathy was detected in the L4 nerve root by electromyography and magnetic resonance neurographic imaging. The underlying cause was investigated; however, it is linked to the idiopathic outcome. Idiopathic lumbosacral neuropathy is a lumbosacral plexus disease in which no underlying pathology plays a role in causing severe pain and muscle weakness. Patients should be avoided urgently operation because of the sudden onset symptoms.

Keywords: Femoral neuropathy; neuritis; pelvic pain.

Please cite this article as "Ayyildiz A, Dogu B, Ciftci S, Yilmaz F, Kuran B. Idiopathic Lumbosacral Neuropathy Syndrome: Case Report. Med Bull Sisli Etfal Hosp 2020;54(3):384–387".

Idiopathic lumbosacral plexitis or lumbosacral radiculoplexus neuropathy is a disease that is characterized by nerve damage due to pathologies of lumbar and/or sacral plexus observed not related to trauma, mass effect or diabetic complications.^[1–3] The prevalence of lumbosacral plexopathy is not known; it is less common than brachial plexopathies. While in the etiology of lumbosacral plexopathy, trauma, birth, hip surgery, retroperitoneal hematoma or abscess, compression effect that arises from metastatic cancers, radiation-induced nerve damage, diabetes mellitus or paraneoplastic syndromes can be enumerated; it can be observed idiopathically without the presence of any of these etiologies.^[4, 5]

Idiopathic lumbosacral plexitis is characterized by acute onset leg pain. Later on, a decrease in muscle strength and mass and sensory loss are observed.^[1–3] Frequently unilateral plexopathies are observed unilaterally, but there are also bilateral cases reported in the literature.^[4, 5] The diagno-

sis is made by clinical and electrophysiological evaluation of the affected nerves. In addition, Magnetic Resonance Imaging (MRI) is also helpful.^[4, 6]

In this case study, we aimed to present our case that was admitted to our outpatient clinic with severe pain in the right thigh and diagnosed as lumbosacral neuropathy/neuritis with idiopathic femoral nerve involvement. Enlightened consent was obtained from the patient for the presentation of this case report.

Case Report

A 47-year-old male patient with no known chronic disease had pain that spread from the right groin to the anterior aspect of the right knee for two months. The patient's pain was of the mechanical character and decreased with leaning forward. The patient who did not describe morning stiffness, numbness and tingling had no history of trauma. The patient described his pain as nine during ambulation,

Address for correspondence: Aylin Ayyildiz, MD. Sisli Hamidiye Etfal Egitim ve Arastirma Hastanesi, Istanbul, Turkey

Phone: +90 538 503 36 93 **E-mail:** aylin.mrt93@gmail.com

Submitted Date: October 25, 2018 **Accepted Date:** April 27, 2019 **Available Online Date:** August 24, 2020

©Copyright 2020 by The Medical Bulletin of Sisli Etfal Hospital - Available online at www.sislietfaltip.org

OPEN ACCESS This is an open access article under the CC BY-NC license (<http://creativecommons.org/licenses/by-nc/4.0/>).



five at rest and five at night, based on the Visual Analogue Scale (VAS). The walking distance was about 20 meters.

It was learnt that she had undergone “left L3-L4, L4-L5, L5-S1 foraminotomy” 15, “left-approach L5-S1 microdiscectomy” operation 3; and right inguinal hernia repair 25 years ago.

During the physical examination of the patient performed by us, thoracic kyphosis, flattened lumbar lordosis and pili asymmetry were detected. Bilateral paravertebral muscle spasm was detected in the lumbar region of the patient without processus spinosus sensitivity. Extension and right lateral flexion were minimally limited in the lumbar joint range of motion assessment, and the patient felt pain radiating to the right leg.

While the patient's hand- ground distance was 5 cm, the modified Shober test result was 5 cm. The femoral stretch test was positive on the right leg. Hip joint range of motion was within normal limits. According to the Medical Research Council grading system ranging from Grade 5 (normal) to Grade 0 (no visible contraction) muscle strengths of the hip and lower extremities were as follows: hip flexors (m. iliopsoas): right 3/5, left 5/5; knee extensors (m. quadriceps femoris): right 3/5, left 5/5; foot plantar flexors (m. gastrocnemius): right 4/5, left 5/5; knee flexors (hamstring muscle group): right 4/5, left 5/5; hip extensors (m. gluteus maximus): right 3/5, left 5/5; hip abductors (m. gluteus medius): right 4/5, left 5/5. Since in daily examinations of full strengths of other muscles, except for muscle innervated by L4 root, were evaluated, at first assessment, these unfavourable results were attributed to the very severe pain felt by the patients at first assessment. The patella reflex was hypoactive on the right, normoactive on the left, while Achilles reflex was bilaterally hypoactive.

Examination of the foot sole skin yielded a bilateral flexor plantar reflex. In the sensory evaluation performed by light touch and pinprick test, allodynia rather than hypoesthesia was detected on the L4 dermatome area of the anterior aspect of the thigh.

In the requested lumbar and pelvic MRI of the patient, the contrast enhancement pattern and edematous appearance in the perineural areas extending from the right neural foramen level to the psoas muscle level at the L4-L5 disc level and foraminal level were observed which was found to be compatible with neuritis (Figs. 1, 2). Then patient Electromyography (EMG) and MR Neurography were requested from the patient, In EMG, “Intense denervation potentials were observed in the right M.vastus lateralis and M. rectus femoris muscles at rest, while the voluntary muscle and the right M.vastus lateralis, M. rectus femoris and M. Iliopsoas muscles have varying degrees of high amplitude, long-lasting, polyphasic MUPs, and rarefactions were observed.

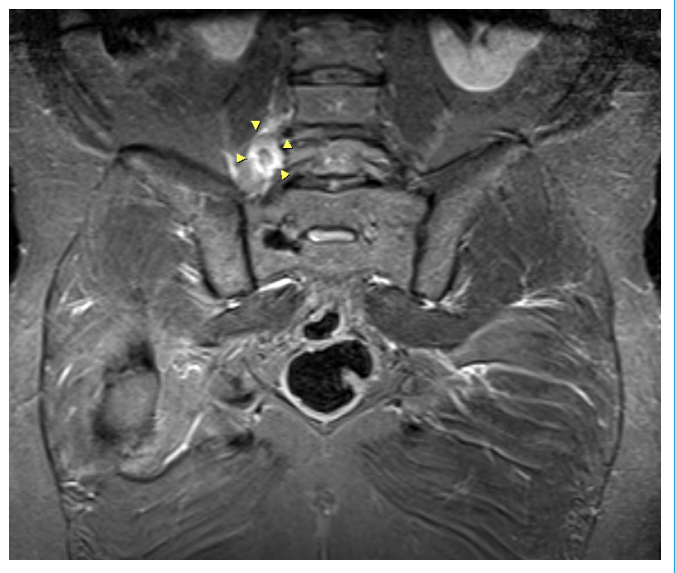


Figure 1. Iv-contrast pelvis MR T1 sequence.

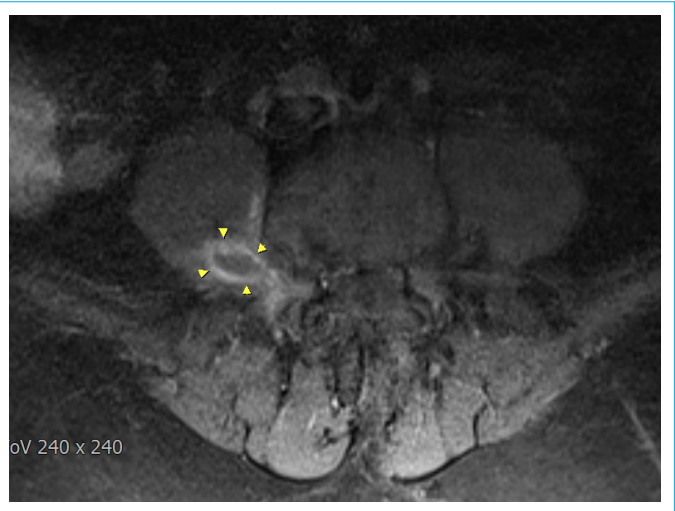

Figure 2. Lumbar MR axial section T1 Fat-suppressed imaging.

These findings were evaluated to be compatible with acute-subacute neurogenous involvement of the muscles innervated by the L2-L3-L4 segment on the right. As a result of MR neurography; there were peripheral T2 hyperintense edema areas around the right L4 nerve and it was found to be compatible with neuritis.

Serology, tumor markers, Borrelia IgM/IgG and paraneoplastic panel were requested to investigate the etiologies that could cause this picture. No pathology was detected in all these laboratory tests of the patient. Despite the use of tramadol at the maximum dose in medical treatment, 60 mg/day methylprednisolone was started in the patient whose pain persisted. After using the full dose of 60mg/day for 10 days, the dose was discontinued by decreasing the dose in about 30 days. Vitamin D and calcium replacement

were performed to protect the patient from osteoporosis. During steroid therapy, the dose of tramadol was reduced and continued at 200mg/day. After the pain of the patient subsided, isometric, stretching and joint range of motion exercises for the hip and knee circumference muscles, especially lower extremity strengthening exercises for iliopsoas and quadriceps femoris muscles, balance and core stabilization exercises.

No auxiliary devices were required. In control MRI performed before the patient's discharge, shrinkage was detected in the region compatible with the old neuritis. The patient was determined to be five at rest, two at rest and three at night on the VAS assessment during discharge. According to the muscle strength assessment during discharge, hip flexors (m. iliopsoas): right 4/5; knee extensors (m. quadriceps femoris): right 4/5; foot plantar flexors (m. Gastrocnemius): right 5/5; knee flexors (hamstring muscle group): right 5/5; hip extensors (m. Gluteus maximus): right 5/5; hip abductors (m. Gluteus medius): right 5/5 detected. Patient's consent was obtained for this case study.

Discussion

Diagnosis of the lumbosacral plexus neuropathy, loss of muscle strength, presence of asymmetric hyporeflexia, and sensory loss are determined when additional symptoms cannot be explained by a single peripheral nerve lesion. To be diagnosed with idiopathic lumbosacral plexus neuropathy, there should be no bed-triggering cause below to explain the patient's signs and symptoms.^[2, 7] Lumbosacral plexus has many diseases that caused pain. It has causes, such as hereditary, vascular, trauma, space-occupying lesions and infections. However, after these conditions are ruled out, a diagnosis of idiopathic lumbosacral plexus neuropathy can be made.

Generally, the disease starts with pain, and loss of muscle strength is observed between 5-10 days after.^[2, 7] While sensory loss as a sensory symptom is less frequent in patients presenting with lower limb strength loss and pain, neuropathic pain and allodynia are more common.^[3] Rarely, muscle atrophy can be added to the picture. In some patients, one or more of the autonomic symptoms, such as orthostatic hypotension, urinary dysfunction, change in sexual function, diarrhea or constipation, sweating, have been observed.^[3]

Lumbosacral plexus neuropathy is seen in three different clinical courses. The first is in a monophasic course. Patients can return to their normal activities functionally within a few years. In the second form, relapsing form; a few years after the acute picture, a picture in which the loss of motor power is more pronounced and even the unaffected limb

is retained in the first attack. The third is an atypical chronic progressive form, and, in this form, the picture progresses more heavily.^[8-10] It was evaluated for the first time in our patient because of such symptoms and whether they responded to treatment or not. The incidence of idiopathic lumbosacral plexus neuropathy is estimated to be less than 1 in 100.000 patients.^[1, 3, 8] Idiopathic lumbosacral radiculoplexus neuropathy is seen much less frequently than brachial plexus neuropathy and diabetic lumbosacral plexus neuropathy. This is due to its involvement with radiculopathy due to disc pathologies, especially when it occurs in the form of lower plexus involvement.^[2, 3] With this phenomenon, we wanted to emphasize and prevent overlook of a disease that is so rare and whose diagnosis is often confused with other similar symptoms.

In patients with plexus neuropathy, various laboratory tests should be requested after history and physical examination. Since the most common group of the patients with this clinical picture is diabetic patients, hemoglobin A1c, fasting blood glucose and glucose tolerance tests should be performed when necessary.^[1] While no increase in acute phase reactants is generally detected, only a few cases have detected sedimentation height.^[11] Evaluation of patients by electromyography is significant in the diagnosis and determination of the location of the lesion. While lumbosacral MRI helps in detecting the underlying cause with imaging, it has been reported that MR neurography can also show hyperintensity and enlargement in the nerve segment in contrast-enhanced T2 images in the nerve segment.^[10]

As a result of our patient's MR neurography; peripheral T2 hyperintense edema areas were present around the right L4 nerve. Although the presence of a properly limited lesion around the psoas muscle in our patient's lumbar and pelvic MRI imaging suggests a preliminary diagnosis of psoas abscess, our patient had removed us from the diagnosis of psoas abscess because of the absence of a laboratory finding that could be considered in the etiology of psoas abscess. In addition, although the involvement of muscles other than L4 root innervation may be caused by previous surgical operations, no significant loss of muscle strength was detected in the patient's previous examinations before the neuritis symptoms started, and the evaluation of muscle strengths other than L4 root could not be performed correctly due to the patient's severe pain. However, in the evaluation of daily muscle strength during his hospitalization, loss of muscle strength was not detected except for L4 root. The neurogenic involvement in the L2-L3-L4 root observed in the electromyographic evaluation suggested that there may be plexopathy, which is observed in other roots with involvement, even though magnetic resonance imaging is not observed.

The pathogenesis of lumbosacral plexus neuropathy is not fully known and has been found compatible with microvasculitis in biopsy studies.^[3] Having a history of upper respiratory tract infection or vaccination before other case reports and responding well to immunomodulatory therapy led to its evaluation concerning immune-mediated neuropathy due to microvasculitis in autoimmune etiology.^[3, 10, 11]

In this direction, it is thought that immunotherapy can be effective in treatment.^[2] Tarulli et al.^[1] preferred to discontinue oral steroid treatment using oral steroid therapy for 60 months/60 days, then gradually decreasing the dose gradually. It has been reported that oral steroid therapy can be used as well as intravenous immunoglobulin and plasmapheresis may be among the treatment options.^[1,2] In this period, it is appropriate to administer non-steroidal anti-inflammatory drugs and opioids in symptomatic treatment. We also achieved a 50% reduction in the patient's pain with the use of tramadol and diclofenac in our patient.

Conclusion

Idiopathic lumbosacral neuropathy is a lumbosacral plexus disease in which no underlying pathology plays a role, causing severe pain and muscle weakness. Due to sudden onset symptoms, patients should be avoided from the emergency operation and their diagnosis should be confirmed before electromyography and MRI neurography.

Disclosures

Informed Consent: Written informed consent was obtained from the patient for the publication of the case report and the accompanying images.

Peer-review: Externally peer-reviewed.

Conflict of Interest: None declared.

Authorship Contributions: Concept – A.A.; Design – S.C.; Supervision – F.Y.; Materials – B.D.; Data collection &/or processing – A.A.; Analysis and/or interpretation – B.K.; Literature search – B.D.; Writing – A.A.; Critical review – B.K.

References

1. Tarulli A, Rutkove SB. Lumbosacral plexitis. *J Clin Neuromuscul Dis* 2005;7:72–8.
2. Dyck PJ, Windebank AJ. Diabetic and nondiabetic lumbosacral radiculoplexus neuropathies: new insights into pathophysiology and treatment. *Muscle Nerve* 2002;25:477–91.
3. Dyck PJ, Norell JE, Dyck PJ. Non-diabetic lumbosacral radiculoplexus neuropathy: natural history, outcome and comparison with the diabetic variety. *Brain* 2001;124:1197–207.
4. Laughlin RS, Dyck PJ. Electrodiagnostic Testing in Lumbosacral Plexopathies. *Physical Medicine and Rehabilitation Clinics of North America* 2013;24:93–105.
5. Jaeckle KA. Neurological manifestations of neoplastic and radiation-induced plexopathies. *Semin Neurol* 2004;24:385–93.
6. Planner AC, Donaghy M, Moore NR. Causes of lumbosacral plexopathy. *Clin Radiol* 2006;61:987–95.
7. Donaghy M. Lumbosacral plexus lesions. In: Dyck PJ, Thomas PK, Griffin JW, Low PA, Podusio JF, editors. *Peripheral Neuropathy*. 3rd ed. Philadelphia: W.B. Saunders; 1993. p. 951–8.
8. Awerbuch GI, Nigro MA, Sandyk R, Levin JR. Relapsing lumbosacral plexus neuropathy. Report of two cases. *Eur Neurol* 1991;31:348–51.
9. Yee T. Recurrent idiopathic lumbosacral plexopathy. *Muscle Nerve* 2000;23:1439–42.
10. Höllinger P, Sturzenegger M. Chronic progressive primary lumbosacral plexus neuritis: MRI findings and response to immunoglobulin therapy. *J Neurol* 2000;247:143–5.
11. Bradley WG, Chad D, Verghese JP, Liu HC, Good P, Gabbai AA, et al. Painful lumbosacral plexopathy with elevated erythrocyte sedimentation rate: a treatable inflammatory syndrome. *Ann Neurol* 1984;15:457–64.
12. Triggs WJ, Young MS, Eskin T, Valenstein E. Treatment of idiopathic lumbosacral plexopathy with intravenous immunoglobulin. *Muscle Nerve* 1997;20:244–6.