

Case Report

Minimally invasive treatment of femoral head avascular necrosis in a beta thalassemia carrier. A case-report.

Dimitrios G. Economopoulos¹, Ioannis K. Triantafyllopoulos²¹Hygeia Hospital, Athens, Greece; ²Laboratory for the Research of Musculoskeletal Disorders, Medical School, National & Kapodistrian University of Athens, Greece**Abstract**

Avascular necrosis (AVNFH) of the femoral head is a relatively rare condition linked with numerous causes. If not treated promptly then arthritis may be inevitable, making hip replacement the only treatment option. In this case report we present a young AVNFH patient with history of heterozygous beta thalassemia. To our knowledge this is the second case where a thalassemia carrier presents AVNFH. Due to his age and pre-collapse stage, we elected to use a minimally invasive, femoral head sparing technique. Therefore, the patient underwent arthroscopy and fluoroscopy assisted core decompression followed by autograft and demineralized bone matrix application. Recovery was uneventful and a year after surgery femoral collapse did not progress. Moreover, the patient was pain free and capable of participating in sport activities. Even though it is difficult to describe a pathway linking heterozygous beta thalassemia with AVNFH, a possible relation between them cannot be discarded.

Keywords: Avascular Necrosis, Femoral Head, Thalassemia Beta, Orthobiologics, Arthroscopy**Introduction**

Avascular necrosis of the femoral head (AVNFH) is a condition causing bone remodeling disorders and cell death due to compromised blood supply. If left untreated, it is associated with high risk for femoral head collapse and joint destruction¹.

It mostly affects patients aged 20-40 years² and can be either an outcome of direct trauma or various medical conditions. Non-traumatic AVNFH risk factors include radiation therapy³, hematologic disorders⁴, chronic glucocorticoid use⁵, excessive alcohol intake⁶, autoimmune diseases, malignancies and metabolic disorders⁷.

When not resulting from direct vascular damage, AVNFH can be attributed to intraosseous microcirculation disorders. It appears that the latter trigger a series of events leading

to retrograde arterial occlusion. Extravascular compression has also been described as a pathogenic mechanism⁸. Nevertheless, there are still cases where it is difficult to fully describe a pathway leading to AVNFH⁹.

Non-traumatic AVNFH may appear in more than one site of the human skeleton. Due to its frequent bilateral presentation (50-70%)¹⁰ and 3% multifocal¹¹ involvement, when diagnosed, thorough radiographic assessment should be obtained.

The demographics of AVNFH are not well documented. Studies from the U.S. and Japan indicate that newly diagnosed patients range from 2,500 to 20,000 per year^{12,13} and that there is a clear male predominance¹⁴. Early presentation may be asymptomatic, thus making diagnosis a difficult task. However, insidious onset of groin pain, restricted range of motion and referred knee pain are very common manifestations and should be undertaken as "red flags" by the attending physician.

The main objective of AVNFH treatment is to avoid femoral head collapse and hip joint deterioration. In early stages, non-operative treatment, orthobiologics and surgical interventions bar arthroplasty, provide good results. Single or multiple drills core decompression as well as distribution of bone morphogenetic proteins, bone marrow containing mononuclear/stromal cells, autologous adipose

The authors have no conflict of interest.

Corresponding author: Dimitrios G. Economopoulos MD, MSci, PhD,
Georgiou Papandreou 22 Avenue, 15773, Athens, Greece
E-mail: economopoulosdim@gmail.com

Edited by: G. Lyrakis

Accepted 28 February 2019



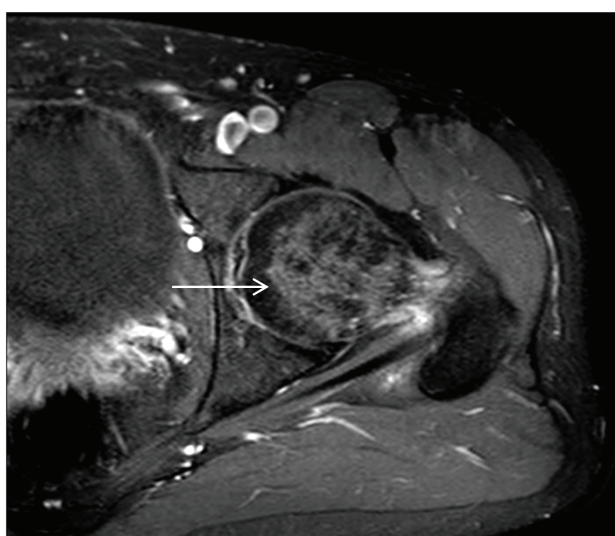
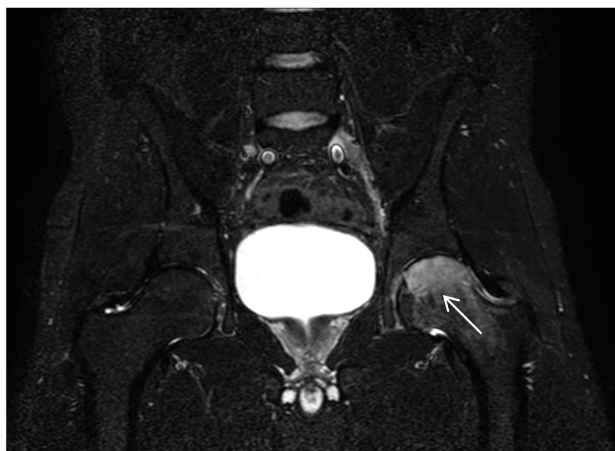


Figure 1. MRI images demonstrating excessive bone edema in the femoral head and neck as shown with arrow marks.

tissue derived stem cells, platelet rich plasma and various combinations of the above, are some of the described interventional treatment options. All above-mentioned techniques offer comparable results and good satisfaction scores when femoral head integrity is maintained^{12,15-17}.

However, there is a consensus regarding hip replacement as the best option, when pain persists, congruency is not preserved and arthritis progresses. Recent studies from the U.S. indicated that regardless of our alertness, 10% of total hip replacements are still performed in patients with post-AVNFB arthritis¹⁸. Therefore, a significant number of patients either remain undiagnosed until AVNFB has progressed or do not benefit from other therapy options.

Even though AVNFB is a typical finding in blood disorders such as sickle cell anemia¹⁹, it is not very common in patients with beta thalassemia.

After a thorough literature search we found only one study

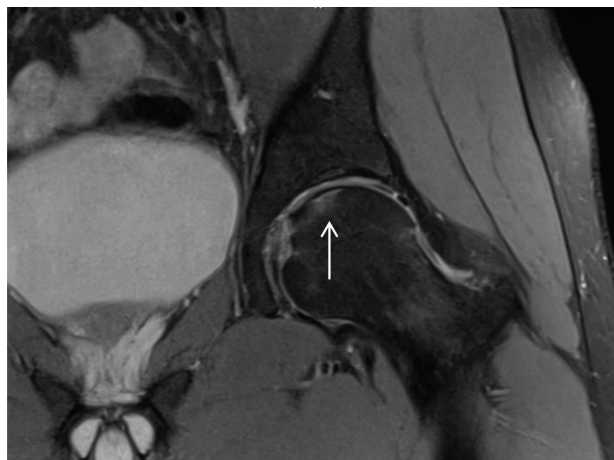


Figure 2. New MR images taken a month after the patient remained non-weight bearing. Subchondral abnormalities and bone marrow edema are evident (arrow mark).

and a small number of case reports with AVNFB presentation in beta thalassemia major patients²⁰⁻²³. Moreover, to our knowledge there is only one case report where AVNFB was described in a beta thalassemia carrier²⁴.

Case report

In this report we present the resolution of aseptic avascular necrosis in a beta thalassemia carrier. Our patient was a 32-year old Caucasian male who visited our outpatient's clinic complaining of pain in his left groin for over a month.

At the time of his visit he was employed in a sedentary job and had no recollection of recent injuries. Moreover, he had not participated in high-energy or full contact sports for more than a year. The onset of his symptoms was sudden and their intensity was proportional to his overall physical activity.

A detailed medical history was obtained and his medical records were investigated. We confirmed that apart from heterozygous beta thalassemia the patient had no other health issues. The former diagnosis was verified with significantly elevated HbA2 values after blood sampling. He had no allergies, did not smoke and considered himself a social drinker. His BMI was 27.

During examination, severe pain was elicited with flexion, internal rotation and adduction of his left hip. Restricted range of motion compared to the contralateral side was also noted. Trendelenburg sign was negative, whilst the patient presented antalgic gait on his left side.

Radiographic assessment with plain X-Rays demonstrated a small osteopenic lesion around the fovea capitis. Initial MRI assessment exhibited low signal intensity on T1 weighted images of the left femoral head. T2 weighted images demonstrated bone edema of the femoral neck and femoral head (Figure 1). Imaging differential considerations included

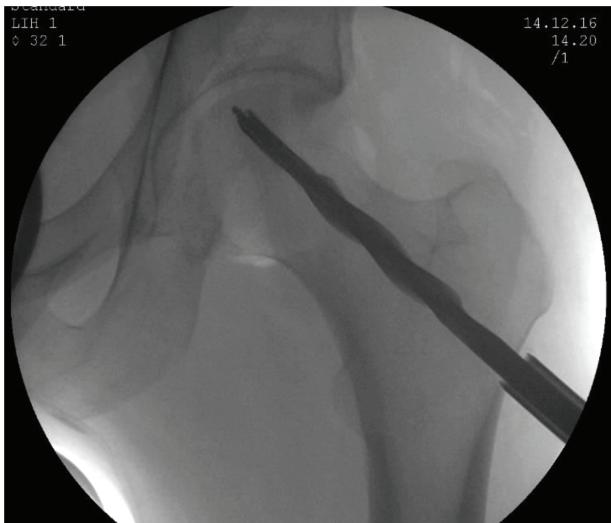

Figure 3. C-arm image taken intraoperatively. A guide pin was forwarded to the site of osteonecrosis and reaming commenced.

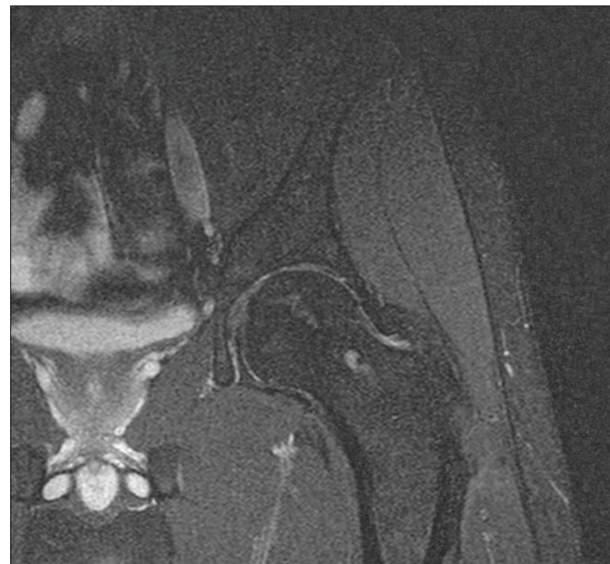


Figure 4. MR images taken a year after surgery. Femoral head maintained its sphericity, bone marrow edema subsided and bone graft integration was achieved.

transient osteoporosis and avascular necrosis. The plan was to keep the patient non-weight bearing and arrange a full review after a period of 4 weeks. During that period no clinical improvement was noted, while pain management with NSAIDs was not effective. New MR images taken 30 days later, revealed diffuse bone marrow edema at the femoral neck, linear subchondral bone abnormalities and subtle collapse of the femoral head superolaterally as shown in Figure 2 (Steinberg stage 3²⁵). These findings were consistent with avascular necrosis of the left femoral head, while no additional defects of the acetabulum were noted.

After discussing his options, the patient decided that conservative treatment was no longer an option for him. He therefore, elected to undergo arthroscopically assisted femoral head core decompression and biological support of the necrotic defect with a combination of autologous cancellous bone and demineralized bone matrix. Due to his young age we decided to use a minimally invasive femoral head sparing technique.

Surgical technique

In theatre, under general anesthesia, the patient was put in supine position. Hip arthroscopy preceded in order to assess the congruency of the hip joint and the integrity of the femoral head. After the integrity of the femoral head was verified, an incision of approximately 2 cm was made over the ipsilateral anterior iliac crest. A small trocar was inserted multiple times into the ilium and unicortical bone autograft was harvested. Then, a 1 cm incision was made on the side of the left femur extending distal to the vastus ridge. With the assistance of fluoroscopy, a guide wire was inserted above the level of the lesser trochanter pointing towards the necrotic lesion. When anterior and lateral views confirmed it was directed

at the desired position, the length of the inserted guide pin was measured. A cannulated reamer of 1 cm diameter was passed through the guide pin in order to decompress the necrotic lesion (Figure 3). Care was taken not to ream deeper than the measured length of the inserted guide and penetrate the cartilage of femoral head. After reaming, both guide-wire and reamer were removed and a 6 mm trocar was advanced towards the lesion. The harvested bone autograft along with demineralized bone matrix were tapped until the reamed area was filled. The remaining area, corresponding to the lateral cortex of the femur and the insertion point of the reamer, was packed with trabecular bone allograft. Before wound closure the hip joint was arthroscopically reassessed. Once femoral head integrity was confirmed, all incisions were closed in standard fashion.

Aftercare and postoperative rehabilitation

The patient was discharged a day after surgery with instructions to start mild kinesiotherapy and restrict to toe-touch bearing for a month. Wound healing was uneventful and sutures were removed on the 15th postoperative day.

A month after surgery the patient was reviewed. He had already returned to his day job and during examination no pain was elicited with passive motion of his hip. He was urged to progressively put more weight on his operated extremity and make the transition to full weight bearing within a 30-day period.

On his 3-month follow up the patient was fully weight bearing and generally happy with his operation. He rarely experienced episodes of sharp pain, even though he could not

describe a specific pattern generating the latter. In addition, during examination external rotation was reduced, compared to the contralateral side.

During his 12-month review, the patient was totally pain free and fully functional. He no longer had symptoms from his left hip and resumed daily and sport activities. Moreover, postoperative MRIs demonstrated bone graft integration, while there was no further deterioration or femoral head collapse 12 months after surgery (Figure 4).

Discussion

Avascular necrosis of the femoral head can be a devastating complication of various hematologic disorders. It is very common in sickle cell anemia, due to the peculiar shape that sickle red cells take in a hypoxic environment¹⁹. However, the number of AVNFB reports in thalassemic patients is considerably lower^{20-24,26-27}.

Beta thalassemia is an inherited blood disorder related with abnormal or reduced hemoglobin production. There is a well-documented heterogeneity of mutations causing it²⁶. To date, more than 30 mutations have been identified, while thalassemia carriers are estimated at 80 million globally. There is a clear geographic variation concerning its prevalence. The Mediterranean, North Africa, India and the Middle East are areas where the incidence of beta thalassemia is significantly higher. The prevalence of beta thalassemia trait in Greece is 7.4%²⁷.

Even though bone disease in thalassemia is very common, the pathogenesis of this heterogeneous condition is still not fully understood. This is probably because numerous factors related with beta thalassemia have an impact on bone metabolism²⁸.

AVNFB is among those heterogeneous manifestations described in thalassemic patients. Some attribute AVNFB to recurring chronic hypoxia deriving from infrequent transfusions that promotes bone marrow hyperplasia and low blood flow through the medial femoral circumflex artery. Others raise a question about the role of osteoporosis in the incidence of AVNFB and argue that low bone mineral density, that is very common in thalassemics, could be associated with increased risk for microfractures. In this case, AVNFB could be a result of microcirculation impairment^{20,29}. However, since plain radiographs and MRI remain the gold standard for the diagnosis and treatment of early stage AVNFB, we elected not to investigate our patient further with dual X-ray absorptiometry³⁰.

In contrast to patients with beta thalassemia major, most beta-thalassemia carriers are relatively asymptomatic. They develop only mild anemia and have no need of blood transfusions. In addition, bone disease due to hormonal deficiency, marrow expansion, increased bone turnover and iron toxicity is uncommon in people with thalassemia trait.

The patient presented in this case report, was a healthy young male with no recollection of recent trauma. Our plan was to achieve the best possible result with the least invasive

method. He was treated successfully with arthroscopy and fluoroscopy assisted core decompression combined with biologic enhancement of the necrotic subchondral area and preservation of the adjacent articular cartilage. Since thalassemia minor was his only known disorder, we had no other option but to highlight it and review the literature for similar cases. However, our difficulty describing a pathway that links thalassemia minor and AVNFB may indicate that the latter is not a result of secondary nature.

References

1. Mont MA, Hungenford DS. Non traumatic osteonecrosis of the femoral head: ten year later-current concepts review. *J Bone Joint Surg Am* 2006;88(5):1117-32.
2. Shannon BD, Trousdale RT. Femoral osteotomies for avascular necrosis of the femoral head. *Clin Orthop Relat Res* 2004;418:34-40.
3. Rueda C, Duque MAQ, Mantilla RD, Iglesias-Gamarra A. Osteonecrosis and antiphospholipid syndrome. *J Clin Rheumatol* 2009;15:130-132.
4. Akinyoola AL, Adediran IA, Asaley CM, Bolarinwa AR. Risk factors for osteonecrosis of the femoral head in patients with sickle cell disease. *International Orthopaedics (SICOT)* 2009;33:923.
5. Sakaguchi M, Tanaka T, Fukushima W, Kubo T, Hirota Y. Impact of oral corticosteroid use for idiopathic osteonecrosis of the femoral head: a nationwide multicenter case-control study in Japan. *J Orthop Sci*. 2010;15(2):185-91.
6. Wang Y, Li Y, Mao K, Li J, Cui Q, Wang GJ. Alcohol-induced adipogenesis in bone and marrow: a possible mechanism for osteonecrosis. *Clin Orthop Relat Res* 2003;(410):213-24.
7. Shah KN, Racine J, Jones LC, Aaron RK. Pathophysiology and risk factors for osteonecrosis. *Curr Rev Musculoskelet Med* 2015;8(3):201-9.
8. Aaron RK, Gray R. Osteonecrosis: etiology, natural history, pathophysiology, and diagnosis. In: Callaghan JJ, Rosenberg AG, Rubash HE, editors. *The adult hip*. Philadelphia: Lippincott Williams & Wilkins; 2007. pp. 465-76.
9. Sen RK. Management of avascular necrosis of femoral head at pre-collapse stage. *Indian J Orthop* 2009; 43(1):6-16.
10. Boettcher WG, Bonfiglio M, Hamilton HH, Sheets RF, Smith K. Non-traumatic necrosis of the femoral head. I. Relation of altered hemostasis to etiology. *J Bone Joint Surg Am* 1970; 52:312-321.
11. LaPorte DM, Mont MA, Mohan V, Jones LC, Hungerford DS. Multifocal osteonecrosis. *J Rheumatol* 1998; 25(10):1968-74.
12. Aldridge JM, Urbaniak JR. Avascular necrosis of the femoral head: Etiology, pathophysiology, classification, and current treatment guidelines. *Am J Orthop (Belle Mead NJ)* 2004;33:327-32.
13. Hirota Y, Hotokebuchi T, Sugioka Y. Idiopathic

- osteonecrosis of the femoral head: Nationwide epidemiologic studies in Japan. In: Urbaniak JR, Jones JP, editors. *Osteonecrosis Etiology, Diagnosis, and Treatment*. 1st ed. Chicago (Ill): American Academy of Orthopaedic Surgeons; 1997. P 51.
14. Nori M, Marupaka SK, Alluri S, Md N, Irfan KA, Jampala V, Apsingi S, Eachempati KK. MRI Evaluation of Post Core Decompression Changes in Avascular Necrosis of Hip. *J Clin Diagn Res* 2015;9(12):TCO4-8.
 15. Hernigou P, Trousselier M, Roubineau F, Bouthors C, Chevallier N, Rouard H, Flouzat-Lachaniette CH. Stem Cell Therapy for the Treatment of Hip Osteonecrosis: A 30-Year Review of Progress. *Clin Orthop Surg* 2016; 8(1):1-8.
 16. Lieberman JR, Berry DJ, Mont MA, Aaron RK, Callaghan JJ, Rajadhyaksha AD, Urbaniak JR. Osteonecrosis of the hip: management in the 21st century. *Instr Course Lect* 2003; 52:337-55. Review.
 17. Papavasiliou AV, Triantafyllopoulos I, Paxinos O, Tsoukas D, Kostantoulakis C. The role of cell therapies and hip arthroscopy in the management of osteonecrosis: an update. *Journal of Hip Preservation Surgery* 2018; 5(3):202-208.
 18. Moya-Angeler J, Gianakos AL, Villa JC, Ni A, Lane JM. Current concepts on osteonecrosis of the femoral head. *World J Orthop* 2015;6(8):590-601.
 19. Poignard A, Flouzat-Lachaniette CH, Amzallag J, Galacteros F, Hernigou P. The natural progression of symptomatic humeral head osteonecrosis in adults with sickle cell disease. *J Bone Joint Surg Am* 2012; 94(2):156-62.
 20. Thulasidhar AN, Kumar S, Aroor S, Mundkur S. Avascular Necrosis of Femoral Head in a Child with Beta Thalassaemia Major. *J Clin Diagn Res* 2016;10(9):SLO3.
 21. Orzincolo C, Castaldi G, Scutellari PN, Bariani L, Pinca A. Aseptic necrosis of femoral head complicating thalassemia. *Skeletal Radiol* 1986;15(7):541-4.
 22. Behera SK, Jena RK, Sethy S, Nayak RK, Panigrahi A. Transfusion Dependent Beta-Thalassemia Developing Avascular Necrosis of Femoral Head: A Rare Case. *Indian J Hematol Blood Transfus* 2017;33(3):421-422.
 23. Mandhani G, Kalra M, Narasimhan R, Khanna VK, Mahajan A. A Case of Non-Traumatic Avascular Necrosis of Femur in Case of Transfusion-Dependent Thalassemia. *J Orthop Case Rep* 2017;7(3):38-40.
 24. Madhar M, Latifi M, Aziz S, Essadki B, Fikry T. [Aseptic osteonecrosis of the femoral head in thalassemia minor: a case report]. *Rev Chir Orthop Reparatrice Appar Mot* 2005;91(2):170-2.
 25. Steinberg DR, Steinberg ME. The University of Pennsylvania classification of osteonecrosis. In: Koo KH, Mont MA, Jones LC, editors. *Osteonecrosis*. Heidelberg: Springer; 2014. p. 201-6.
 26. Cao A, Galanello R. Beta-thalassemia. *Genet Med* 2010;12(2):61-76.
 27. De Sanctis V, Kattamis C, Canatan D, Soliman AT, Elsedfy H, Karimi M, Daar S, Wali Y, Yassin M, Soliman N, Sobti P, Al Jaouni S, El Kholy M, Fiscina B, Angastiniotis M. β -Thalassemia Distribution in the Old World: An Ancient Disease Seen from a Historical Standpoint. *Mediterr J Hematol Infect Dis* 2017;20:9(1): e2017018.
 28. Wong P, Fuller PJ, Gillespie MT, Milat F. Bone Disease in Thalassemia: A Molecular and Clinical Overview. *Endocr Rev* 2016;37(4):320-46.
 29. Katz K, Horev G, Goshen J, Tamary H. The pattern of bone disease in transfusion-dependent thalassemia major patients. *Isr J Med Sci* 1994;30(8):577-80.
 30. Imhof H, Breitensteiner M, Trattning S, Kramer J, Hofmann S, Plenk H, Schneider W, Engel A. Imaging of avascular necrosis of bone. *Eur Radiol* 1997;7(2):180-6.