

# Kyphoplasty for occult and non-occult osteoporotic vertebral fractures: a retrospective study

Journal of International Medical Research

48(4) 1–8

© The Author(s) 2019

Article reuse guidelines:

[sagepub.com/journals-permissions](http://sagepub.com/journals-permissions)

DOI: 10.1177/0300060519894764

[journals.sagepub.com/home/imr](http://journals.sagepub.com/home/imr)



Zhangzhe Zhou\*, Zhiyong Sun\*,  
Yimeng Wang\*, Xiaoyu Zhu and  
Zhonglai Qian

## Abstract

**Objective:** To compare the safety and efficacy of kyphoplasty in the treatment of occult and non-occult osteoporotic vertebral compression fractures (OOVF).

**Material and Methods:** From 2015 to 2017, 82 OOVF and 105 non-occult osteoporotic vertebral compression fractures (N-OOVF) were evaluated with the Visual Analog Scale (VAS), Oswestry Disability Index (ODI), and vertebral height preoperatively, immediately postoperatively, and one year postoperatively. Operative time, fluoroscopy time, and cement injection volume were recorded.

**Results:** Compared with the preoperative VAS and ODI scores, the scores of both groups were significantly improved after surgery. Preoperative ODI and VAS scores of the OOVF were lower than those of the N-OOVF. The operative time, fluoroscopy time, and bone cement injection volume of the OOVF were significantly lower than those of the N-OOVF. Vertebral height of the N-OOVF improved significantly after surgery. There were differences in cement leakage and adjacent vertebral fractures between the two groups.

**Conclusion:** Compared with N-OOVF, OOVF are safer with kyphoplasty, and it is necessary to diagnose OOVF in a timely manner.

## Keywords

Kyphoplasty, occult osteoporotic vertebral fractures, vertebral compression fractures, osteoporosis, functional outcomes, safe and effective

Date received: 4 July 2019; accepted: 22 November 2019

\*These authors contributed equally to this work.

### Corresponding author:

Zhonglai Qian, Department of Orthopedic Surgery, The First Affiliated Hospital of Soochow University, 188 Shizi Street, Suzhou, Jiangsu 215006, China.

Email: [qzldoctor@163.com](mailto:qzldoctor@163.com)

The Department of Orthopedic Surgery, The First Affiliated Hospital of Soochow University, Suzhou, Jiangsu, China



Creative Commons Non Commercial CC BY-NC: This article is distributed under the terms of the Creative Commons Attribution-NonCommercial 4.0 License (<https://creativecommons.org/licenses/by-nc/4.0/>) which permits non-commercial use, reproduction and distribution of the work without further permission provided the original work is attributed as specified on the SAGE and Open Access pages (<https://us.sagepub.com/en-us/nam/open-access-at-sage>).

## Introduction

Osteoporosis is a metabolic disease characterized by reduced bone mineral density, which is more common in postmenopausal women.<sup>1</sup> As one of the most common complications of osteoporosis in older adults, there are about 1.7 million osteoporotic vertebral compression fractures (OVCF) in the United States and Europe every year.<sup>2</sup> OVCF can cause severe pain, spinal deformities, impaired lung function, and even death.<sup>3</sup> Therefore, OVCF plays an important role in societal economy and human health.

Accurate diagnosis of OVCF in a timely manner is a worldwide issue.<sup>4</sup> Li et al.<sup>5</sup> showed that the false negative rate of imaging diagnosis accuracy for vertebral fractures was 34%. For occult osteoporotic vertebral compression fractures (OOVF), there is no deformation and collapse of the vertebral body, which may lead to a higher missed diagnosis rate.<sup>6</sup> Schoenfeld et al.<sup>7</sup> found through meta-analysis that although computed tomography (CT) was very sensitive in identifying bone abnormalities, the meta-analysis supported obtaining magnetic resonance imaging (MRI) in patients with negative CT scan results. Nakano et al.<sup>8</sup> found that the sensitivity and specificity of MRI for the diagnosis of vertebral fractures was 99.0% and 98.7%, respectively. Therefore, MRI is important to screen patients without shape changes of the vertebral body.

Open surgery and conservative treatment are not the best choices for OVCF. This is because patients are generally older and it is difficult to achieve fixation of osteoporotic bones, and patients can suffer from side effects of long-term high doses of painkillers, risk of vertebral collapse, and poor quality of life.<sup>9</sup> Kyphoplasty (KP) is one of the primary methods for the treatment of OVCF.<sup>10</sup> Currently, the treatment of OOVF has been only rarely described due

to the high missed diagnosis rate. Many patients do not receive treatment until collapse of the vertebral body (non-occult osteoporotic compression fracture, N-OOVF) occurs or severe symptoms develop. Therefore, we evaluated the safety and efficacy of KP in the treatment of OOVF and N-OOVF to determine whether KP is safer and more effective in the treatment of OOVF without vertebral deformation.

## Material and methods

This study was approved by the Ethics Committee of the First Affiliated Hospital of Soochow University. From January 2015 to December 2017, patients who were treated in our hospital and met the following criteria were included in our study. For inclusion criteria, all cases met the following criteria: 1) Frankel spinal cord injury grade D-E; 2) a physical examination that showed tenderness and pain with percussion; 3) bone mineral density was measured by dual-energy X-ray absorptiometry preoperatively, with a T score of  $-2.5$  or lower; 4) MRI showed low signal on T1 images and a high signal on T2 and STIR images. For exclusion criteria, only one of the following criteria needed to be satisfied: 1) patients with potential malignant diseases and an expected survival of less than 1 year; 2) infections, psychiatric disorders, coagulation disorders; 3) patients who were lost to follow-up; 4) OOVF occurred in three or more vertebral bodies to avoid evaluation of the efficacy of patients after surgery.

## Grouping

X-ray or CT showed that patients with complete vertebral morphology were placed in the OOVF group, and patients with morphological changes were placed in the N-OOVF group.

### **Radiographic and clinical evaluation**

All operations were performed by the senior spine surgeon in our department, and the operative time, fluoroscopy time, and cement volume were recorded during the operation. Visual Analog Scale (VAS) was used to evaluate the degree of pain, and Oswestry Disability Index (ODI) was used to evaluate the physical dysfunction of patients preoperatively, 3 days postoperatively, and 1 year postoperatively. The anterior vertebral height (AVH) and middle vertebral height (MVH) were measured by lateral X-ray before the surgery, 3 days after surgery, and 1 year after surgery. The cement leakage and adjacent vertebral fractures were recorded.

### **Statistical analysis**

The average deviation and standard deviation of the AVH, MVH, VAS, and ODI scores were calculated and analyzed by SPSS software (SPSS 19.0, Armonk, NY, USA). The basic characteristics and results evaluation parameters of the two groups of data were compared by a t-test of the group design data. A Chi-square test was used to compare the leakage of bone cement and postoperative re-fractures of the vertebral body. When  $P < 0.05$ , the difference was considered statistically significant.

### **Results**

From January 2015 to December 2017, after screening for inclusion and exclusion criteria, 199 patients met our requirements. Among these patients, 4 died of potential diseases within 1 year, and 8 failed to complete follow-up for other reasons. A total of 187 patients completed the 1-year follow-up. Eighty-two patients with OOVF (50 females and 32 males) received KP 103 times, and 105 patients with N-OOVF (66 females and 39 males) received KP 132 times, as shown in Table 1. Imaging data

for a typical patient with an OOVF are shown in Figure 1 and Figure 2.

### **Radiographic and clinical evaluation**

In the OOVF group, the operative time was  $23.91 \pm 4.22$  minutes, the fluoroscopy time was  $10.18 \pm 1.67$  minutes, and the volume of bone cement was  $3.49 \pm 0.92$  mL. The VAS score decreased from  $7.21 \pm 0.97$  preoperatively to  $2.80 \pm 0.89$  postoperatively ( $P < 0.01$ ), and was maintained at  $2.70 \pm 1.07$  at 1 year after surgery. The ODI score decreased from  $65.15 \pm 8.91$  preoperatively to  $26.07 \pm 4.38$  postoperatively ( $P < 0.01$ ), and was maintained at  $26.57 \pm 6.37$  at 1 year after surgery. There was no significant change in the anterior and middle vertebral heights at 1 year after surgery ( $P > 0.05$ ).

In the N-OOVF group, the operative time was  $27.15 \pm 5.05$  minutes, the fluoroscopy time was  $12.10 \pm 2.64$  minutes, and the volume of bone cement was  $4.06 \pm 1.10$  mL. The VAS score decreased from  $7.95 \pm 1.02$  preoperatively to  $2.65 \pm 0.81$  postoperatively ( $P < 0.01$ ), and remained at  $2.58 \pm 0.85$  at 1 year after surgery. The ODI score decreased from  $70.38 \pm 6.31$  preoperatively to  $26.87 \pm 4.39$  postoperatively ( $P < 0.01$ ), and remained at  $27.14 \pm 5.48$  at 1 year after surgery. The anterior vertebral height increased from  $17.49 \pm 4.17$  mm preoperatively to  $24.05 \pm 3.74$  mm postoperatively ( $P < 0.01$ ), and remained at  $23.31 \pm 3.67$  mm at 1 year after surgery. The height of the middle vertebral body changed from  $16.94 \pm 4.34$  mm preoperatively to  $23.38 \pm 3.04$  mm postoperatively ( $P < 0.01$ ), and was maintained at  $23.85 \pm 3.25$  mm at 1 year after surgery.

During the 1-year follow-up period, 22 patients suffered from vertebral fractures postoperatively, including 4 patients in the OOVF group and 18 patients in the N-OOVF group ( $P < 0.05$ ). Ten patients

**Table 1.** Patient characteristics.

| Parameters                                | OOVF          | N-OOVF        | P-value |
|---|---------------|---------------|---------|
| <b>Patient</b>                            |               |               |         |
| Number                                    | 82            | 105           |         |
| Age (years)                               | 68.71 ± 9.27  | 69.03 ± 8.03  |         |
| Gender (F/M)                              | 50/32         | 66/39         |         |
| Follow-up (months)                        | 12            | 12            |         |
| Diseased time                             | 8.92 ± 3.60   | 16.58 ± 4.18  | <0.01   |
| Bone mineral density                      | -3.26 ± 0.48  | -3.57 ± 0.51  | <0.01   |
| <b>Kyphoplasty operation</b>              |               |               |         |
| Operative time per vertebrae (minutes)    | 23.91 ± 4.22  | 27.15 ± 5.05  | <0.01   |
| Fluoroscopy time per vertebrae (minutes)  | 10.18 ± 1.67  | 12.10 ± 2.64  | <0.01   |
| Injected cement volume (mL)               | 3.49 ± 0.92   | 4.06 ± 1.10   | <0.01   |
| Cement leakage                            | 0             | 10            | <0.05   |
| Vertebral body fracture after kyphoplasty | 4             | 18            | <0.05   |
| <b>Visual Analog Scale</b>                |               |               |         |
| preoperatively                            | 7.21 ± 0.97   | 7.95 ± 1.02   | <0.01   |
| 3 days postoperatively                    | 2.80 ± 0.89*  | 2.65 ± 0.81*  | >0.05   |
| 1 year postoperatively                    | 2.70 ± 1.07*  | 2.58 ± 0.85*  | >0.05   |
| <b>Oswestry Disability Index</b>          |               |               |         |
| preoperatively                            | 65.15 ± 8.91  | 70.38 ± 6.31  | <0.01   |
| 3 days postoperatively                    | 26.07 ± 4.38* | 26.87 ± 4.39* | >0.05   |
| 1 year postoperatively                    | 26.57 ± 6.37* | 27.14 ± 5.48* | >0.05   |
| <b>Anterior vertebral height</b>          |               |               |         |
| preoperatively                            | 24.31 ± 4.07  | 17.49 ± 4.17  | <0.01   |
| 3 days postoperatively                    | 24.68 ± 4.42  | 24.05 ± 3.74* | >0.05   |
| 1 year postoperatively                    | 23.91 ± 4.18  | 23.31 ± 3.67* | >0.05   |
| <b>Middle vertebral height</b>            |               |               |         |
| preoperatively                            | 24.02 ± 3.66  | 16.94 ± 4.34  | <0.01   |
| 3 days postoperatively                    | 23.62 ± 4.01  | 23.38 ± 3.04* | >0.05   |
| 1 year postoperatively                    | 23.64 ± 4.32  | 23.85 ± 3.25* | >0.05   |

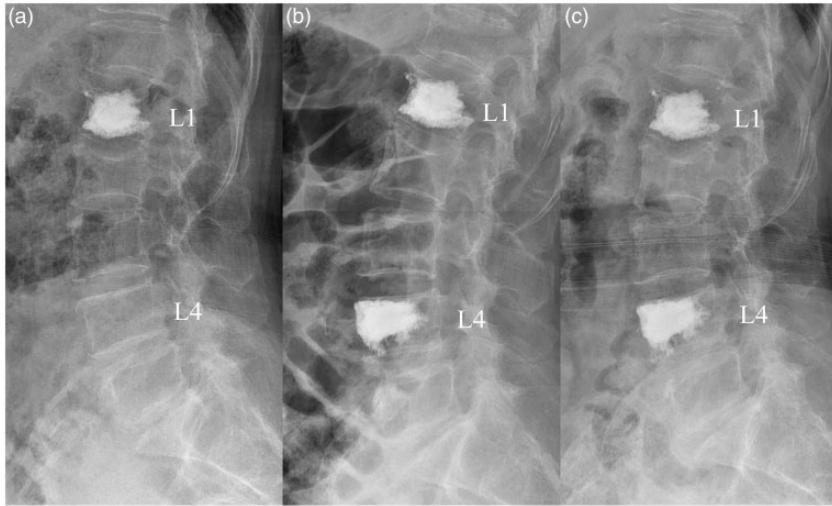
\*P<0.01 compared with the preoperative value.

with cement leakage were all in the N-OOVF group (P < 0.05).

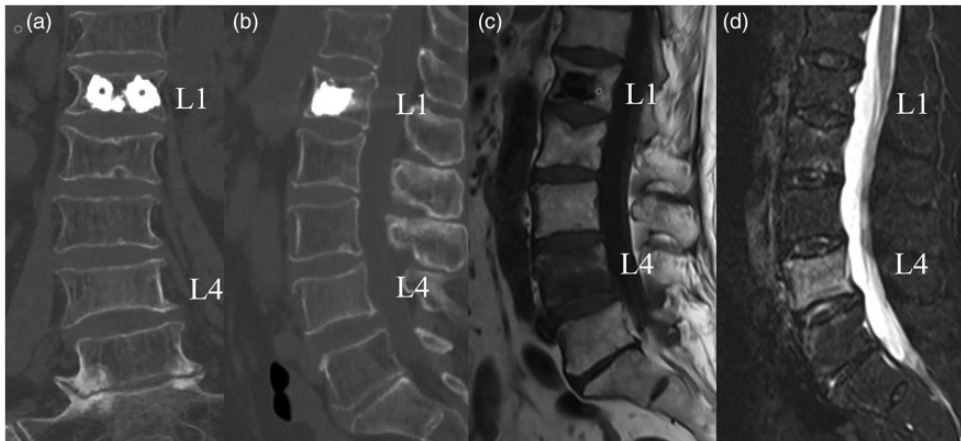
## Discussion

Spiegel et al.<sup>11</sup> found that in a prospective study of 28 patients with OVCF, 8 patients had new signs of vertebral edema on preoperative MRI, which was not detected on previous X-rays and CT scans. Terakado et al. reported that the vertebral body of occult fractures can be detected in time by preoperative MRI examination. For microfractures, bleeding, and edema, MRI is the

best way to detect lesions, which showed low signal on T1 images and high signal on T2 and STIR images.<sup>12</sup> Compared with the N-OOVF group, the OOVF group had better preoperative ODI and VAS scores, which may be owing to the timely MRI examination of occult vertebral fractures and intervention treatment, resulting in no collapse of the vertebral body and no serious complications. Therefore, MRI is necessary for elderly patients with low back pain with suspected osteoporotic vertebral compression fractures, even if X-ray and CT examinations are normal.



**Figure 1.** A typical case of an occult osteoporotic vertebral fracture. The patient had a history of osteoporotic vertebral fracture and recovered well after KP treatment. A year ago, the patient came to the clinic with symptoms of back pain. (a) From the preoperative lateral X-ray films of the patients, we can find the changes after L1 KP and no radioactive deformation of the L4 vertebral body and (b, c) From the lateral X-ray films 3 days and 1 year postoperatively, we can find that the vertebral morphology remained intact and no radiological collapse of the L1 and L4 vertebral bodies occurred. KP, kyphoplasty.



**Figure 2.** (a, b) From the preoperative CT three-dimensional reconstruction of the patient, we can find that the changes after L1 KP and no radioactive deformation of the L4 vertebral body. (c, d) From the preoperative MRI images of the patient, we observed changes after L1 KP, including low signal on T1 sequence and high signal on stir sequence of the L4 vertebral body, demonstrating an extensive bone marrow edema in the vertebral body. KP, kyphoplasty; MRI, magnetic resonance imaging; CT, computed tomography.

According to Mao et al.,<sup>13</sup> OOVF can eventually lead to three outcomes: 1) the vertebral body can completely heal; 2) owing to a decrease in the mechanical strength of the vertebral body, collapse deformation can occur during the healing; 3) affected by the distribution of vertebral blood vessels, the collapsed vertebral body can cause the rupture of the arterioles, which can ultimately lead to the failure of the fracture to heal or even ischemic osteonecrosis. The duration of disease in OOVF was less than that of N-OOVF, indicating that the patients with OOVF were in the early stage of vertebral fracture. According to the progression of the disease, if there is no intervention, then it may progress to N-OOVF or even bone non-union. Pham et al.<sup>14</sup> reported that about 79% of OOVF patients had vertebral fracture collapse within 3 months, although the first X-ray examination was negative. Therefore, it is necessary to relieve pain and strengthen vertebral bodies to prevent collapse. Patients with OOVF and N-OOVF showed a significant improvement in postoperative ODI and VAS scores compared with preoperative scores and postoperative pain and quality of life were significantly improved. The height of the vertebral body was restored in the N-OOVF group, and remained unchanged during the 1-year follow-up period. Therefore, it is necessary to relieve pain and strengthen the vertebral body to prevent collapse. The exact mechanism of pain relief by cement remains controversial. It may be that the cement stabilizes the vertebral body to relieve the pain. Another explanation is that the monomeric toxicity and exotherm of bone cement leads to osteonephrosis receptor necrosis.<sup>15</sup>

Bone cement leakage is one of the most common complications of KP, and it has been reported that the leakage rate of bone cement is 7%.<sup>16</sup> The comparison showed that the cement leakage in the N-OOVF group was significantly higher

than in the OOVF group, probably because the vertebral cortical bone remained intact in OOVF patients.<sup>17</sup> In addition, the amount of bone cement injected in patients with OOVF was significantly lower than in the N-OOVF group. Studies have shown that bone cement leakage is related to the volume of bone cement.<sup>18</sup> Excellent cement injection technology can reduce the leakage rate. Yang et al.<sup>19</sup> summarized the current situation of KP in China, and proposed several methods of injecting bone cement, such as the graded infusion technique and the incremental temperature cement delivery system. The time between the operative time and the fluoroscopy time was shorter in the OOVF group than in the N-OOVF group, mainly due to the reduction of the step of recovering vertebral height with inflatable balloons during the operation.

Whether kyphoplasty increases the fracture rate of adjacent vertebral bodies after surgery remains controversial. Li et al.<sup>20</sup> reported that high levels of bone density can protect adjacent vertebral bodies from fractures after surgery. Ahn et al.<sup>21</sup> found that differences in vertebral body strength caused by bone cement augmentation resulted in fractures of adjacent vertebral bodies, while the difference in segmental mobility caused fractures of non-adjacent vertebral bodies. Recently, Zhang et al.<sup>22</sup> showed that vertebral body augmentation does not increase untreated vertebral fractures. Compared with the patients in the OOVF group, the preoperative bone mineral density of patients in the N-OOVF group was worse, and the postoperative adjacent vertebral fracture rate in the OOVF group was lower than in the N-OOVF group. This may be due to the timely detection of OOVF by MRI and early anti-osteoporosis treatment, so the patients with OOVF had fewer vertebral fractures after surgery.

This study had some limitations. First, the study was retrospective and produced



less evidence than prospective studies, and therefore requires further prospective studies to confirm the findings. Second, our study included only patients who received KP without control or replacement therapy, such as vertebroplasty and conservative treatment. Finally, we only studied the efficacy up to 1 year after KP. Further research is needed to determine the safety and efficacy of KP in the treatment of OOVF and N-OOVF.

## Conclusion

It is safer to perform kyphoplasty in patients with OOVF compared with patients with N-OOVF. Therefore, it is important to diagnose OOVF in a timely manner.

## Acknowledgements

Thanks are extended to all patients involved in this study from the First Affiliated Hospital of Soochow University.

## Consent

The study received written/verbal consent from the patients or patients' parents.

## Declaration of conflicting interest

The authors declare that there is no conflict of interest.

## Funding

This research received no specific grant from any funding agency in the public, commercial, or not-for-profit sectors.

## References

1. Aghebati-Maleki L, Dolati S, Zandi R, et al. Prospect of mesenchymal stem cells in therapy of osteoporosis: a review. *J Cell Physiol* 2019; 234: 8570–8678.
2. Zhou XS, Meng XT, Zhu HT, et al. Early versus late percutaneous kyphoplasty for treating osteoporotic vertebral compression fracture: a retrospective study. *Clin Neurol Neurosur* 2019; 180: 101–105.
3. Cheng JJ, Muheremu A, Zeng XM, et al. Percutaneous vertebroplasty vs balloon kyphoplasty in the treatment of newly onset osteoporotic vertebral compression fractures: a retrospective cohort study. *Medicine* 2019; 98: e14793.
4. Delmas PD, van de Langerijt L, Watts NB, et al. Underdiagnosis of vertebral fractures is a worldwide problem: the IMPACT study. *J Bone Miner Res* 2005; 20: 557–563.
5. Li YZ, Yan LS, Cai SQ, et al. The prevalence and under-diagnosis of vertebral fractures on chest radiograph. *Bmc Musculoskel Dis* 2018; 19: 235.
6. Wu CT, Lee SC, Lee ST, et al. Classification of symptomatic osteoporotic compression fractures of the thoracic and lumbar spine. *J Clin Neurosci* 2006; 13: 31–38.
7. Schoenfeld AJ, Bono CM, McGuire KJ, et al. Computed tomography alone versus computed tomography and magnetic resonance imaging in the identification of occult injuries to the cervical spine: a meta-analysis. *J Trauma* 2010; 68: 109–113.
8. Spuentrup E, Buecker A, Adam G, et al. Diffusion-weighted MR imaging for differentiation of benign fracture edema and tumor infiltration of the vertebral body. *Am J Roentgenol* 2001; 176: 351–358.
9. Tang H, Zhao J and Hao C. Osteoporotic vertebral compression fractures: surgery versus non-operative management. *J Int Med Res* 2011; 39: 1438–1447.
10. Cheng X, Long HQ, Xu JH, et al. Comparison of unilateral versus bilateral percutaneous kyphoplasty for the treatment of patients with osteoporosis vertebral compression fracture (OVCF): a systematic review and meta-analysis. *Eur Spine J* 2016; 25: 3439–3449.
11. Spiegl UJA, Beisse R, Hauck S, et al. Value of MRI imaging prior to a kyphoplasty for osteoporotic insufficiency fractures. *Eur Spine J* 2009; 18: 1287–1292.
12. Qaiyum M, Tyrrell PNM, McCall IW, et al. MRI detection of unsuspected vertebral injury in acute spinal trauma: incidence and significance. *Skeletal Radiol* 2001; 30: 299–304.

13. Mao HQ, Zou J, Geng DC, et al. Osteoporotic vertebral fractures without compression: key factors of diagnosis and initial outcome of treatment with cement augmentation. *Neuroradiology* 2012; 54: 1137–1143.
14. Pham T, Azulay-Parrado J, Champsaur P, et al. “Occult” osteoporotic vertebral fractures – Vertebral body fractures without radiologic collapse. *Spine* 2005; 30: 2430–2435.
15. Sun ZY, Li XF, Zhao H, et al. Percutaneous balloon kyphoplasty in treatment of painful osteoporotic occult vertebral fracture: a retrospective study of 89 cases. *Med Sci Monitor* 2017; 23: 1682–1690.
16. Denaro L, Longo UG and Denaro V. Vertebroplasty and kyphoplasty: reasons for concern? *Orthop Clin N Am* 2009; 40: 465–471.
17. Liu T, Li Z, Su QJ, et al. Cement leakage in osteoporotic vertebral compression fractures with cortical defect using high-viscosity bone cement during unilateral percutaneous kyphoplasty surgery. *Medicine* 2017; 96: e7216.
18. Lin DS, Hao JM, Lin L, et al. Effect of bone cement volume fraction on adjacent vertebral fractures after unilateral percutaneous kyphoplasty. *Clin Spine Surg* 2017; 30: E270–E275.
19. Yang H, Liu H, Wang S, et al. Review of percutaneous kyphoplasty in China[J]. *Spine (Phila Pa 1976)* 2016; 41: B52–B58.
20. Li H, Yang DL, Ma L, et al. Risk factors associated with adjacent vertebral compression fracture following percutaneous vertebroplasty after menopause: a retrospective study. *Med Sci Monitor* 2017; 23: 5271–5276.
21. Ahn Y, Lee JH, Lee HY, et al. Predictive factors for subsequent vertebral fracture after percutaneous vertebroplasty. *J Neurosurg-Spine* 2008; 9: 129–136.
22. Zhang L, Wang Q, Wang L, et al. Bone cement distribution in the vertebral body affects chances of recompression after percutaneous vertebroplasty treatment in elderly patients with osteoporotic vertebral compression fractures. *Clin Interv Aging* 2017; 12: 431–436.