

Unique mitral valve mass: Think beyond vegetation

Mahmoud Farhoud, Husam Bakdash

Department of Internal Medicine, University of Kansas School of Medicine, Wichita, Kansas, United States

Access this article online

Website: www.avicennajmed.com

DOI: 10.4103/2231-0770.140661

Quick Response Code:



ABSTRACT

Osteosarcoma is a rare cardiac malignant tumor. This case of cardiac osteosarcoma presented with atrial fibrillation. Initial echocardiogram demonstrated mitral valve echodensity and mitral valve regurgitation. Surgery and histopathological examination identified the tumor as an osteosarcoma. Tumor grade appeared to be prognostically important in cardiac sarcoma, with poor prognosis in high-grade tumors.

Key words: Atrial fibrillation, cardiac osteosarcoma, mitral valve, vegetation

INTRODUCTION

A primary cardiac malignant tumor is very rare. About 75% of primary cardiac tumors are benign, and 75% of these are atrial myxomas.^[1] Most cardiac malignant tumors are metastatic tumors from melanoma, lung carcinoma, and breast carcinoma.^[2] Primary cardiac osteosarcomas usually originate in the left atrium.^[3] In contrast, osteosarcomas metastatic to the heart most commonly involve the right cardiac chambers.^[4] We present a patient who had atrial fibrillation (AF) and mitral valve mass. Surgery and histopathological examination identified the mass as an osteosarcoma.

CASE REPORT

A 50-year-old man with a medical history of hypertension was referred to our hospital due to palpitation and lightheadedness. He denied chest pain or shortness of breath. He was in AF with rapid ventricular response (RVR). His blood pressure was 110/75 mmHg, the pulse was irregular with a rate of 160/min, and his breathing rate was 32/min. He had normal heart sounds and a clear chest. Laboratory results showed troponin, a complete blood count, and basic metabolic panel and liver function tests were within normal limits. C reactive protein: 8.3 mg/L (normal range <0.8) and erythrocyte sedimentation rate: 29 mm/h (normal range 0-7).

Video 1 available on www.avicennajmed.com

An electrocardiogram showed AF with RVR and no specific ST segment or T wave abnormalities. The patient was admitted to the telemetry ward and started on diltiazem drip.

Transthoracic echocardiography demonstrated normal systolic function and the anterior mitral valve leaflet was severely thickened, with extensive vegetation/mass involving the whole leaflet [Figure 1 and Video 1]. There were severe mitral regurgitation and moderate mitral stenosis. Blood cultures and serologies for cat scratch disease, brucella, Q-fever, HIV, and hepatitis were negative. The patient was started on vancomycin and ceftriaxone empirically.

The patient was scheduled for mitral valve replacement on day 11 of hospitalization. Intraoperatively, the mitral valve showed no evidence of endocarditis, there was a thickened calcified anterior leaflet. The valve leaflets were removed, and mitral valve was replaced with a mechanical mitral valve. Macroscopically, the resected mass was 4 cm × 3.5 cm × 1.8 cm and weighed 5.5 g. The mass was aggregate of yellow-white, irregular valve-like fragments of tissue with dense fibrous nodularity. Calcifications were identified.

Microscopically, the lesion is composed of malignant pleomorphic spindle with several mitotic figures with associated with osteoid production [Figures 2 and 3]. These features further supported a diagnosis of malignancy as high-grade osteosarcoma.

Address for correspondence: Dr. Mahmoud Farhoud, University of Kansas School of Medicine, 1010 N Kansas St., Wichita, Kansas 67214, USA. E-mail: d.mfarhoud@hotmail.com

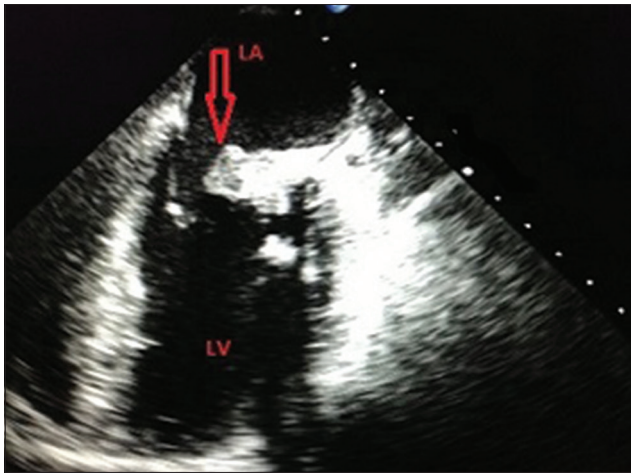


Figure 1: Transesophageal echocardiogram shows mitral valve mass (arrows). LV: Left ventricle, LA: Left atrium

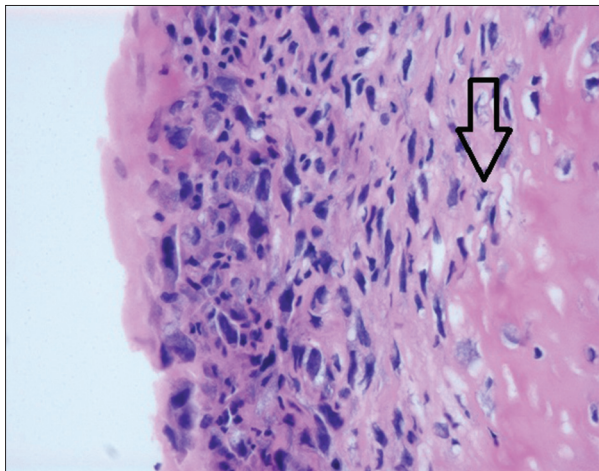


Figure 2: The cells are associated with osteoid production (arrow)

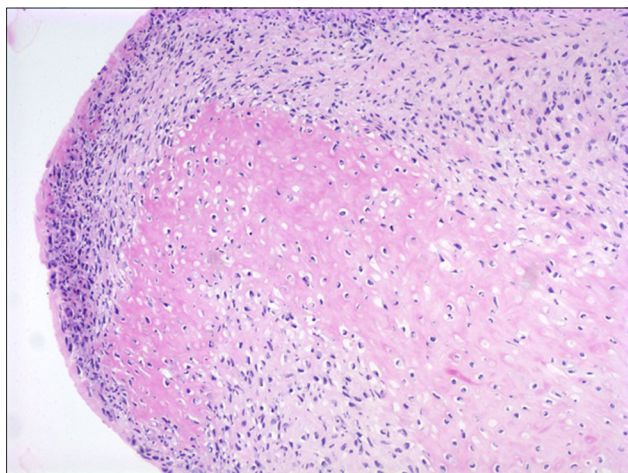


Figure 3: The cells are atypical and pleomorphic

Computed tomography (CT) of the head did not demonstrate any primary lesion. CT of the chest, abdomen, and pelvis showed questionable third lumbar vertebra lesion. Biopsy showed no evidence of malignancy. The patient was

discharged on warfarin. At 1-week follow-up with the oncologist; the patient was started on doxorubicin and cisplatin. At the 3-month follow-up visit, the patient was asymptomatic. A repeat CT of the chest, abdomen, and pelvis showed multiple liver lesions. The patient died after 3-month.

DISCUSSION

Metastases to the heart are 20-40 times more common than primary tumors.^[1] In a series of 27 cardiac sarcomas removed at surgery, only one case was osteosarcoma.^[2] Osteosarcomas in the heart comprise a heterogeneous group of tumors that contain malignant, bone-producing cells. A malignant cardiac tumor mass can interfere with valve function. Local invasion can lead to arrhythmias, embolization, or pericardial effusion with tamponade.^[3] Cardiac osteosarcoma may arise from any portion of the heart, but most commonly from the left atrium.^[4] In our case, the patient had mitral valve osteosarcoma, on first presentation full body CT scan showed questionable third lumbar vertebra, the biopsy did not show any evidence of malignancy and no other lesions were found.

The mechanism of AF in this case is likely associated with mitral valve regurgitation and left atrial wall stretch. The left atrial dilatation is associated with structural and functional atrial tissue alterations that facilitate the disturbed impulse propagation of AF.

Echocardiography is the modality of choice for the diagnosis of intracardiac tumor. Primary osteosarcoma frequently has calcification, and CT may reveal the dense calcification.

Most of these tumors require excision. The surgery is necessary as soon as possible. Doxorubicin-based adjuvant chemotherapy appears to improve time significantly to local and distant recurrence and overall recurrence-free survival in adults with localized resectable soft tissue sarcoma.^[5]

The prognosis of cardiac osteosarcoma is very poor.^[1] In a series of 27 cardiac sarcomas, tumor grade appeared to be prognostically important in cardiac sarcoma; long survival was achieved in patients who survived the initial surgery well with a 15-month median disease free survival for patients with high-grade cardiac sarcoma.^[2]

SUMMARY

Malignant tumors should be distinguished from vegetation and benign tumors like myxoma because of the early resection. Cardiac tumors interact with valve function and

local invasion can lead to arrhythmia. Tumor grade appeared to be prognostically important in cardiac sarcoma, with poor prognosis in high-grade tumors.

REFERENCES

- 1 Burke A, Virmani R. Tumors of the Heart and Great Vessels. Atlas of Tumor Pathology Fasc 16 ser3. Washington DC: Armed Forces Institute of Pathology; 2006. p. 124-40.
- 2 Zhang PJ, Brooks JS, Goldblum JR, Yoder B, Seethala R, Pawel B, *et al*. Primary cardiac sarcomas: A clinicopathologic analysis of a series with follow-up information in 17 patients and emphasis on long-term survival. *Hum Pathol* 2008;39:1385-95.
- 3 Koçak H, Karapolat S, Gündođdu C, Bozkurt E, Unlü Y. Primary cardiac osteosarcoma in a pregnant woman. *Heart Vessels* 2006;21:56-8.
- 4 Dell'Amore A, Asadi N, Caroli G, Dolci G, Bini A, Stella F. Recurrent primary cardiac osteosarcoma: A case report and literature review. *Gen Thorac Cardiovasc Surg* 2014;62:175-80.
- 5 Sarcoma Meta-analysis Collaboration (SMAC). Adjuvant chemotherapy for localised resectable soft tissue sarcoma in adults. *Cochrane Database Syst Rev* 2000:CD001419.

Cite this article as: Farhoud M, Bakdash H. Unique mitral valve mass: Think beyond vegetation. *Avicenna J Med* 2014;4:102-4.

Source of Support: Nil, **Conflict of Interest:** None declared.