

Teaching Case

Adrenocorticotrophic Hormone Secreting Pituitary Carcinoma: Rare, Durable Response to Concurrent Chemotherapy and Reirradiation With a Review of the Literature



Megan Orr, MD,* James Findling, MD, Nathan Zwagerman, MD, Jennifer Connelly, MD, Katherine Albano, MS, and Joseph Bovi, MD

Department of Radiation Oncology, Medical College of Wisconsin, Milwaukee, Wisconsin.

Received February 17, 2021; revised August 12, 2021; accepted September 8, 2021

Introduction

Pituitary adenomas (PA) are a common, benign tumor managed with combinations of surgery, radiation therapy, and medication. Although uncommon, there are atypical PA with aggressive behaviors that are refractory to treatment. In rare instances, pituitary tumors can metastasize or spread. These malignant behaving tumors are called pituitary carcinomas (PC). PC is challenging to manage as they metastasize early and have a poor response to treatment. In reported PC cases, malignant transformation of atypical adrenocorticotrophic hormone (ACTH) secreting PA is a common pathogenesis.¹ Features of PC include functional ACTH production and resistance to radiation. Due to the aggressive nature and systemic spread, the prognosis is poor with a high mortality rate of 66% at 1 year.² Prospective studies and observable data are scarce. Prior reports of treatment include a combination of surgical resection, radiation therapy, and medication with inconsistent responses. Due to the poor treatment response rate and rapid progression, treatment is often palliative. This report describes a complete

resolution of severe Cushing disease due to an ACTH secreting pituitary carcinoma followed by the development of pituitary hypoadrenalism after reirradiation with concurrent temozolomide.

Case Description

A 53-year woman presented with complaints of blurry vision, right-sided cranial nerve (CN) III palsy, diffuse edema of her face and extremities, and a 15 pound weight gain over 2 weeks. Visual field testing revealed bitemporal hemianopsia which prompted imaging. Magnetic resonance imaging (MRI) demonstrated a large intracranial sellar mass (4.0 × 4.3 cm) invading the suprasellar cistern and compressing the optic chiasm. ACTH and cortisol were elevated, which combined with radiographic evidence, established a diagnosis of an ACTH-secreting pituitary macroadenoma and Cushing disease (CD). The patient underwent a transsphenoidal tumor debulking, followed by CyberKnife stereotactic radiosurgery 2 months after surgery (treated to 24 Gy; Table 1). Pathology revealed an atypical PA, positive for p53 and with a low Ki-67 index.

After 3 years in remission, she experienced worsening symptoms associated with cortisol excess. Medical management of cabergoline (D2 receptor agonist) followed by pasireotide (somatostatin analog) was tried without clinical improvement. Imaging demonstrated the mass had

Sources of support: This work had no specific funding.

Disclosures: Dr Findling reports grants, personal fees and other from Novartis, personal fees and other from Concept Therapeutics, personal fees from Recordati, outside the submitted work.

Research data are stored in an institutional repository and will be shared upon request to the corresponding author.

*Corresponding author: Megan Orr, MD; E-mail: meorr@mcw.edu

<https://doi.org/10.1016/j.adro.2021.100813>

2452-1094/© 2021 The Authors. Published by Elsevier Inc. on behalf of American Society for Radiation Oncology. This is an open access article under the CC BY-NC-ND license (<http://creativecommons.org/licenses/by-nc-nd/4.0/>).

Table 1 CyberKnife radiation treatment plan

CyberKnife Feb 2010 Target/OAR	Volume (cm ³)	Max dose (cGy)	Min dose (cGy)	Mean dose (cGy)	SD (cGy)
CTV	7	2817	1214	2403	240
PTV	6	2817	1323	2457	204
Brainstem	34	1023	28	250	160
Left eye	7	65	16	29	7
Left Optic Nerve	2	1069	39	233	223
Optic chiasm	1	845	194	448	164
Right eye	7	164	16	31	12
Right Optic Nerve	2	1267	48	298	216

Abbreviations: CTV = clinical target volume; OAR = organ at risk; PTV = planning target volume; SD = standard deviation.

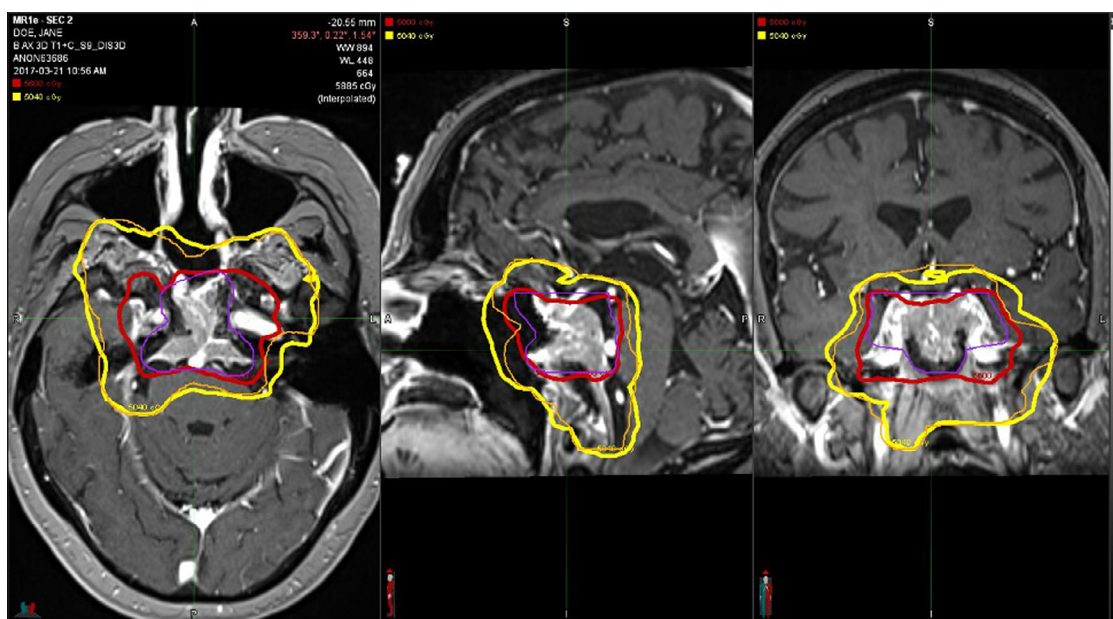


Figure 1 Image-guided intensity modulated radiotherapy planning images. Radiation therapy Planning session magnetic resonance imaging T1-weighted images with contrast (March 2017) showing planning target volumes and prescribed isodose lines. Red lines = 5600 cGy, dose 1; yellow lines = 5040 cGy, dose 2; orange lines = PTV1; purple lines = PTV2.

recurred with noncongruent intracranial spread. This noncontiguous intracranial growth met the criteria for PC. A second transsphenoidal subtotal resection was performed. Pathology revealed atypical ACTH secreting adenoma with a similarly low Ki-67, but with a new loss of p53 signaling. Despite debulking, she had biochemical persistence of hypercortisolism. Over the next 2 months, the patient declined rapidly with weakness, and worsening Cushing symptoms. She was enrolled in a phase 3 clinical trial with osilodrostat (11-beta hydroxylase inhibitor); however, could not tolerate the investigational drug and was taken off. Subsequent MRI showed evidence of progression with gross residual disease and interval growth.

She was referred to radiation oncology. She completed a course of image-guided intensity modulated radiation therapy (IG-IMRT) with concurrent temodar (TMZ) radiosensitization. TMZ was dosed at 75 mg/m² per day for 42 days during radiation. Her IG-IMRT plan consisted

of a gross tumor volume (GTV); drawn for MR defined gross disease and a clinical target volume (CTV) encompassing gross disease and at risk areas of microscopic disease extension (Fig. 1). These volumes were then expanded to 2 planning target volumes (PTV). The first, and larger, PTV was created by expanding the clinical target volume to PTV1 and treated to 50.4 Gy in 28 fractions (180 cGy/fraction). The GTV alone was expanded to PTV2 (integrated boost) and was treated to a total dose of 56 Gy in 28 fractions (200 cGy/fraction; Table 2). Throughout the next 2 years, the patient had a steady decline in ACTH and cortisol levels and experienced a significant improvement in CD symptoms (Table 3). She developed hypocortisolemia. After concurrent chemo-RT, her leg strength and walking improved, and she endorsed improvements in vision. Surveillance images taken a year and a half after chemo-RT showed stable size and configuration of the residual sella and parasellar lesion with

Table 2 IG-IMRT radiation treatment plan

IG-IMRT May 2017 Target/OAR	Volume (cm ³)	Max dose (cGy)	Min dose (cGy)	Mean dose (cGy)	SD (cGy)	EqD2 (cGy)
GTV	83	6091	4922	5621	233	
CTV	24	6083	5292	5793	102	
PTV 1	241	6118	4753	5423	270	
PTV 2	51	6118	5074	5779	106	
Brainstem	32	5784	2374	4701	586	4324
CHIASM PRV	5	5640	4881	5266	171	5109
Eye L	8	3173	537	1355	574	841
Eye R	7	3680	542	1551	644	990
Eye lens L	0.1	997	614	765	81	435
Eye lens R	0.1	830	626	719	41	406
Inner ear L	0.5	5088	4235	4687	164	4305
Inner ear R	0.4	5673	4853	5165	112	5175
Lacrimal gland L	0.7	2207	734	1313	382	810
Lacrimal gland R	0.8	2518	1064	1736	340	1137
Opti chiasm	0.8	5367	4881	5177	89	4981
Optic nerve L	0.5	5325	2742	4723	592	4353
Optic nerve R	0.6	5327	3149	4799	493	4456

Abbreviations: CHIASM PRV = chiasm planning organ at risk volume; CTV = clinical target volume; EqD2 = equivalent dose in 2 Gy fractions; IG-IMRT = image-guided intensity modulated radiotherapy; L = left; OAR = organ at risk; PTV =planning target volume; R = right.

Table 3 Clinical course

Date	Condition	24 h urinary cortisol*	Late salivary cortisol*	Serum morning cortisol*	ACTH*
November 2009	Before first debulking surgery	3,192	N/A	N/A	635
February 2010	CyberKnife	6.9	1.5	9.6	134
May 2014	Redo debulking	40.2	5.5	11.8	190.0
August 2017	3 mo post-RT	20.1	5.5	39.4	240.8
May 2018	1 y post-RT	16.0	5.9	12.6	199.8
February 2019	1 y and 6 mo post-RT	2.1	3.6	6.8	111.8
Jan 2020	Post third debulking	N/A	N/A	8.4	88.5

* Twenty-four-hour urinary cortisol (NR: 30-310 ug/24 h). Late salivary cortisol (NR < 0.13 ug/dL). Serum morning cortisol (NR: 5-25 ug/dL). ACTH (NR <46 pg/dL).

Abbreviations: ACTH = adrenocorticotrophic hormone; CS = Cushing syndrome; GC = glucocorticoids; RT = radiation therapy.

obvious shrinkage of the residual PC compared with prior scans.

Two years after concurrent chemo-RT, a new clival nodule was noted on imaging. Biopsy confirmed pituitary carcinoma. This was managed with single fraction GammaKnife delivering a margin dose of 16 Gy (Fig. 2) to the biopsied area of recurrence. She remains in clinical remission with stable tumor appearance on recent imaging (Fig. 3).

Discussion

During a 10-year history of persistent symptoms and aggressive tumor behavior, this patient's diagnosis evolved from an atypical ACTH secreting pituitary macroadenoma to an invasive ACTH secreting PC that was managed by fractionated IG-IMRT with concurrent TMZ. Approximately 2 years post-IG-IMRT, ACTH/cortisol

labs had declined, and the lesion was reduced radiographically. Remarkably, she developed hypocortisolemia mandating hydrocortisone replacement therapy despite an elevated plasma ACTH. It is postulated that the remission of CD was likely related to chemoradiation therapy-induced alterations in the posttranslation processing of proopiomelanocortin with the production of biologically inactive ACTH and significant decreases in cortisol biosynthesis.⁴ To date, the patient endorses substantial strength, visual, and cognitive improvement.

The mainstay of PC treatment begins with surgical transsphenoidal resection, followed by radiation therapy for residual tumor growth, and adjuvant medical treatment. Studies show in the case of atypical PA that progress to PC, early and aggressive treatment provides the longest survival.³ Surgical resection is the initial intervention to avoid morbidity and mortality related to mass effect of these large aggressive tumors, however, it is rarely complete.⁵ As a result, the residual disease progresses, and

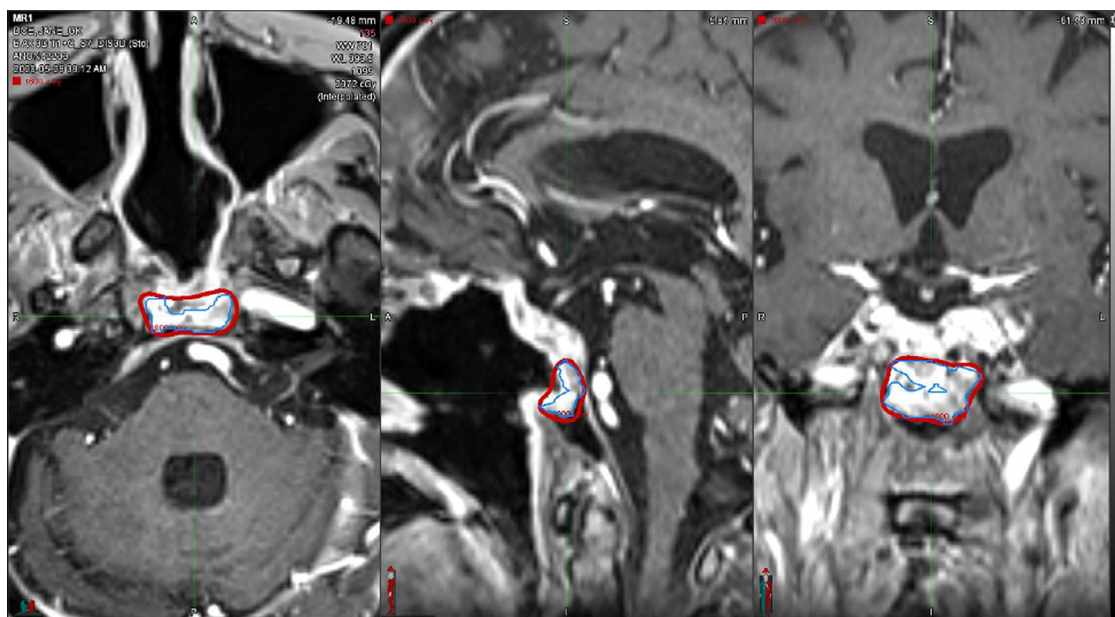


Figure 2 GammaKnife radiation therapy planning images. GammaKnife planning session magnetic resonance imaging T1-weighted images with contrast (May 2020) showing gross tumor volume and prescribed isodose line. Red lines = 1600 cGy prescribed dose; blue lines = GTV.

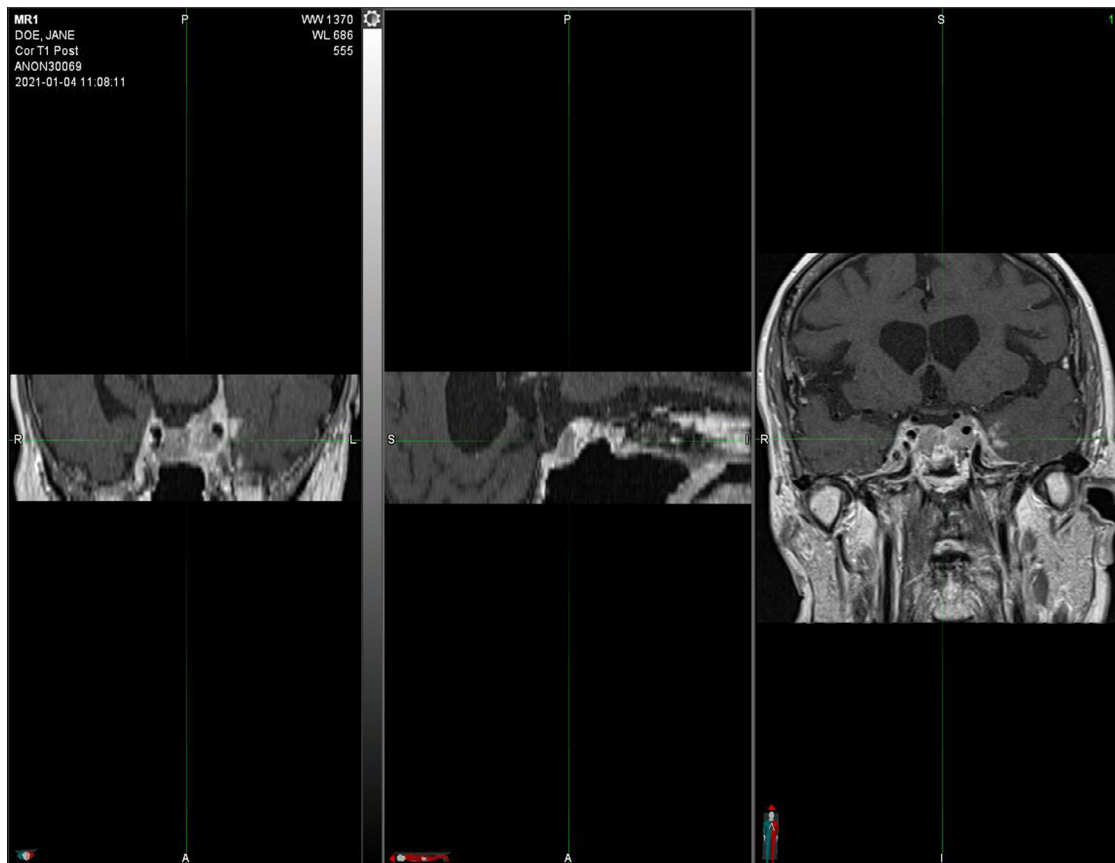


Figure 3 Follow-up magnetic resonance imaging (Jan 2021) showing stable tumor appearance at 8 months after GammaKnife, and 46 months after image-guided intensity modulated radiotherapy with temodar.

multiple surgeries may be performed after a recurrence of disease. Primary pituitary tumors that present with metastases at diagnosis are termed PC. If no metastases are present, histologic evaluation can aid in the management of the tumor.³ Tumors with a high mitotic index, high Ki-67 index >3%, or p53 immunoreactivity are termed atypical PA for their aggressive growth and tendency to recur after resection.³ In both PC and atypical PA guidelines, evidence of postsurgical growth is treated with radiation therapy. In general, radiation therapy provides a modest benefit of local tumor control, especially when administered before distant metastases arise in atypical PA with malignant potential.³ Focal stereotactic treatment has shown mostly palliative benefit with little prognostic improvement.³

Finally, medical therapy is used to combat tumor growth and hypersecretory function. Nonchemotherapy biotherapy includes somatostatin analogs, particularly in the case of GH and TSH-producing tumors, with variable tumor reduction and a limited period of control. Chemotherapy agents such as doxorubicin, cisplatin, and etoposide-based chemotherapy have been implicated in the treatment of PC.³ Responses are variable and not widely replicated, but observational studies indicated prolonged survival in cases of distant metastases, and in aggressive atypical PA before malignant transformation.¹⁻³ One report demonstrated significant regression of an ACTH-secreting PC and distant metastases induced with cisplatin and etoposide, 2 cytotoxic platinum-based chemotherapy drugs.⁴ These agents have variable CNS penetrance, unlike TMZ, but have potential benefit in cases of PC with high mitotic indices. Without prospective, randomized studies, significant conclusions on the benefits of chemotherapeutic agents have yet to be made. Current guidelines for PC that demonstrate progression after primary tumor debulking and radiation therapy include further surgery (alpha), focused radiation therapy (beta), chemotherapy (gamma), and treatment with radionuclides (delta).³

In this case, a complex PC/recurrent atypical PA had a stable positive response to combined fractionated IG-IMRT and TMZ, demonstrating radiologic decrease in tumor volume, clinical improvement, and endocrine remission status post 1 year and 8 months. The lasting results of a combined therapy approach in treating PC have been illustrated in other literature examples. In a similar case, an ACTH secreting PC was treated with a course of concurrent radiation therapy, TMZ, and bevacizumab, an anti-VEGF monoclonal antibody.⁵ The multimodality course was implemented 6 weeks postresection. At 8 weeks, the resolution of a distant metastasis helped established a positive outcome. The patient followed up this course with a year of adjuvant TMZ. Five years post treatment, there has been no evidence of recurrent disease on imaging or with ACTH monitoring.⁵

Another report found that an aggressive, functional ACTH-producing pituitary adenoma was managed with concurrent TMZ and radiation therapy after failing maximal conventional therapy. As in the presented PC case, this PA was recurrent after surgical, medical, and radiation therapy interventions. It rapidly progressed biochemically, radiologically, and clinically. After initiating the combined concurrent TMZ and radiation, a rapid biochemical response was observed with cortisol normalization and regression of intracranial tumor volume on MRI at 3 and 6 months. The TMZ therapy was stopped after the sixth cycle, and at 22 months out from treatment, the patient continues to have stable tumor volume and biochemical remission. Although the patient did not have metastasis necessary for classification of PC, the recurrent clinical course and aggressive functional nature of the tumor demonstrate the lasting positive outcome of a combined modal approach on tumor growth and endocrine remission.⁶

Conclusions

In presenting this case, fractionated IG-IMRT with TMZ was effective in achieving stable endocrine remission and partial tumor regression for several years' duration. The recurrent clival PA is ACTH nonsecreting after IG-IMRT and concurrent TMZ, which has improved the patient's clinical condition. Although this mass recurred after treatment, it is quite remarkable that her tumor has remained hormonally nonfunctional, and the patient continues to have a resolution of CD symptoms. Limited clinical information exists on successful treatment options for PC. Recurrence, metastasis, and mortality are high after exhausting conventional treatment. The alternative combined therapeutic approach of current TMZ and radiation has shown rare, and lasting effects in this patient. These findings may further support the use of combined fractionated radiation therapy with concurrent TMZ treating in patients with ACTH-secreting PC who fail standard surgical and medical interventions.

References

1. Joehlin-Price AD, Hardesty DA, Arnold CA, Kirschner LS, Prevedello DM, Lehman NL. Case report: ACTH-secreting pituitary carcinoma metastatic to the liver in a patient with a history of atypical pituitary adenoma and Cushing's disease. *Diag Pathol.* 2017;12:1-8.
2. Borba CG, Batista RL, Musolino NR, et al. Progression of an invasive ACTH pituitary macroadenoma with Cushing's disease to pituitary carcinoma. *Case Rep Oncol Med.* 2015:1-4.
3. Kaltsas GA, Nomikos P, Kontogeorgos G, Buchfelder M, Grossman AB. Clinical review: Diagnosis and management of pituitary carcinomas. *J Clin Endocrinol Metab.* 2005;90:3089-3099.
4. Cornell RF, Kelly DF, Bordo G, et al. Chemotherapy-induced regression of an adrenocorticotropin-secreting pituitary carcinoma accompanied by secondary adrenal insufficiency. *Case Rep Endocrinol.* 2013;2013: 675298.

5. Touma W, Hoostal S, Peterson RA, Wiernik A, SantaCruz KS, Lou E. Successful treatment of pituitary carcinoma with concurrent radiation, temozolomide, and bevacizumab after resection. *J Clin Neurosci*. 2017;41:75–77.
6. Misir Krpan A, Dusek T, Rakusic Z. A rapid biochemical and radiological response to the concomitant therapy with temozolomide and radiotherapy in an aggressive ACTH pituitary adenoma. *Case Rep Endocrinol*. 2017:1–5.