

## Case Report

# Jackstone in the Kidney: An Unusual Calculus

**Serozsha Goonewardena, Umesh Jayarajah , Sanka Nalinda Kuruppu, and Manoj Hilary Fernando**

*Department of Urology, National Hospital of Sri Lanka, Colombo, Sri Lanka*

Correspondence should be addressed to Umesh Jayarajah; [umeshe.jaya@gmail.com](mailto:umeshe.jaya@gmail.com)

Received 26 September 2020; Accepted 11 January 2021; Published 16 January 2021

Academic Editor: Claudio Simeone

Copyright © 2021 Serozsha Goonewardena et al. This is an open access article distributed under the Creative Commons Attribution License, which permits unrestricted use, distribution, and reproduction in any medium, provided the original work is properly cited.

Jackstones are stones in the urinary tract that have the characteristic appearance resembling six-pointed toy jacks. They are nearly always reported to occur in the urinary bladder, and the occurrence in less capacious renal pelvis is unusual. We report a solitary, typical jackstone in the renal pelvis without significant outflow obstruction that was successfully treated with retrograde intrarenal surgery followed by extracorporeal shockwave lithotripsy. This highlights the complex pathophysiological mechanisms in stone formation which needs to be further studied. It is important to recognize the characteristic shape of the renal calculi on the radiological investigation in the diagnosis of the jackstones.

## 1. Introduction

Jackstones are stones in the urinary tract that have the characteristic appearance resembling six-pointed toy jacks. They are nearly always reported to occur in the urinary bladder [1, 2]. Interestingly, the first probable case of jackstone in the kidney was reported in 1906. Fowler in his paper described a similar stone and stated that “They occur in the renal pelvis, cysts of the kidney, or, as freely movable calculi, in the bladder” [3]. Fowler used words almost identical to those of Ord and Shattock way back in 1895 [4]. However, there is very limited literature about this rare type of calculus. Therefore, we report an unusual case of a jackstone in the kidney.

## 2. Case Presentation

A 63-year-old woman presented with painless intermittent visible haematuria of 4 months duration with no history of flank pain, fever, or vomiting. She had type 2 diabetes mellitus for 18 years. Clinical examination was unremarkable. X-ray KUB showed a typical jackstone in the right kidney (Figure 1(a)). Noncontrast computerized tomography KUB (NCCT-KUB) confirmed the presence of jackstone in the renal pelvis of the right kidney with mild hydronephrosis

and no proximal hydronephrosis (Figures 1(b) and 1(c)). The stone size was 2.4 cm × 2.3 cm, and the stone density was 1355 Hounsfield units. A 99m Technetium-DTPA (Diethylenetriamine Penta-acetic Acid) diuretic renography ruled out significant obstruction with a differential function of 45% in the right kidney. She underwent cystoscopy which excluded bladder pathology accounting for visible haematuria. Right retrograde intrarenal surgery using a 7.5 Fr semi-rigid ureteroscope and Holmium:YAG lasertripsy completely fragmented the jackstone in the kidney (Figure 1(d)). A retrograde JJ stent was placed, and subsequent extracorporeal shockwave lithotripsy rendered her stone-free before the stent was removed. She had an unremarkable recovery. Facilities were not available for stone analysis.

## 3. Discussion

Jackstone in the kidney is exceedingly rare, and our review of the literature revealed only few previous reports [3, 5]. Grases et al. reported a 33-year-old man with two stones in the kidney of which the smaller stone (15 mm) was a jackstone. It had a nucleus of organic matter on which calcium oxalate monohydrate (COM) crystals have grown in a columnar

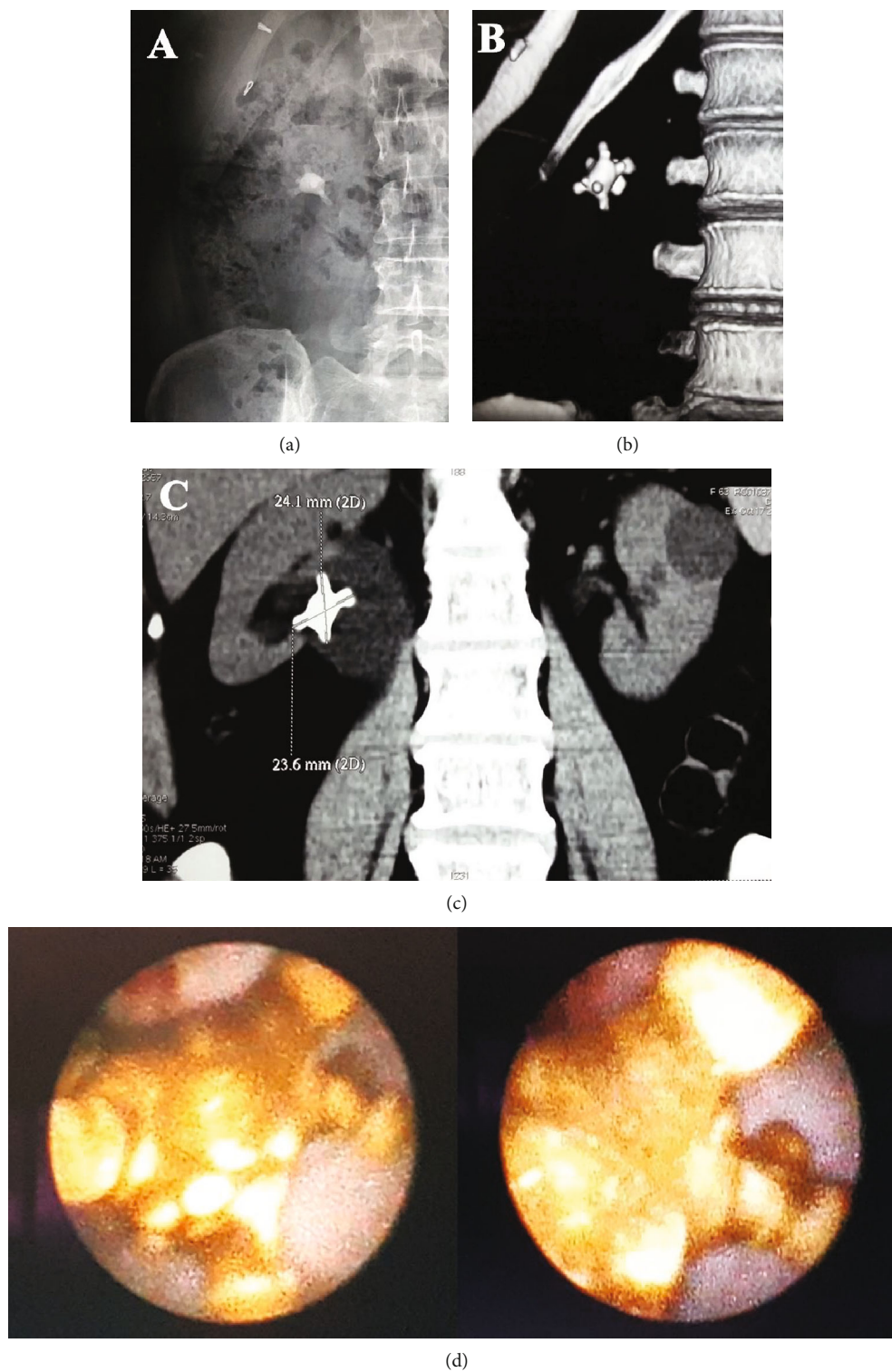


FIGURE 1: (a) X-ray: typical jackstone in the right kidney. (b) Reconstructed image of noncontrast computerized tomography (NCCT) confirming the presence of jackstone. (c) NCCT showing the right renal jackstone with mild hydronephrosis and no proximal hydroureter. (d) Endoscopic images showing a jackstone.

concentric structure. The presence of organic matter in the urine acting as a nidus was postulated as a possible reason for the formation of the jackstone found in this patient. However, jackstones in the bladder may be composed of COM or calcium oxalate dihydrate (COD). COM (whewellite) stones are usually smooth, whereas those composed of COD (Weddellite) tend to be irregular and yellow [2, 6].

Our case is unique as the patient presented with a solitary large jackstone (2.3 × 2.4 cm) that had a typical appearance as that of jackstones found in the bladder. In the previous case report by Grases et al., the typical appearance as seen with bladder jackstones was absent. The possible reason for the typical appearance in our patient may be the capacious renal pelvis that may have facilitated the formation of the jackstone. The composition of the jackstone in our patient is most likely COM. This is because the stone density was rather high (1355 HU), and its surface was relatively smooth (Figure 1(d)). In such a jackstone, Rao et al. found that COM is the main constituent [6]. Unfortunately, facilities were not available for stone analysis.

The exact pathophysiology of development of jackstone is poorly understood. Outflow obstruction remains the most common cause of bladder calculi in adults which was also seen with jackstones in the bladder [2]. However, interestingly in our patient, there was no significant obstruction at the pelviureteric junction demonstrated in the renogram curve.

We report a solitary, large, typical jackstone in the renal pelvis without significant outflow obstruction. This highlights the complex pathophysiological mechanisms in stone formation within the urinary system which needs to be further studied. It is important to recognize the characteristic shape of the renal calculi on the radiological investigation in the diagnosis of the jackstones.

## Abbreviations

KUB: Kidney-ureter-bladder  
 NCCT: Noncontrast computed tomography  
 DTPA: Diethylenetriamine pentaacetic acid  
 COM: Calcium oxalate monohydrate  
 COD: Calcium oxalate dihydrate.

## Data Availability

All data generated or analysed during this study are included in this published article.

## Consent

Informed written consent was obtained from the patient for publication of this manuscript, including images or other personal or clinical details of the patient.

## Disclosure

The case report was presented as an abstract in the annual conference of the Sri Lanka Medical Association, “133rd Anniversary International Medical Congress in 2020”,

<https://slma.lk/wp-content/uploads/2020/08/SLMA-Abstract-Book-2020.pdf>.

## Conflicts of Interest

The authors declare that they have no competing interests.

## Authors' Contributions

SASG and UJ conceived and designed the report and collected and organized the data. UJ, MHF, SASG, and SNK wrote the initial and final draft of the article and provided logistic support. All authors have critically reviewed and approved the final draft and are responsible for the content and similarity index of the manuscript. Serozsha Goonewardena and Umesh Jayaraja have equal contribution.

## References

- [1] D. Subasinghe, S. Goonewardena, and V. Kathiragamathamby, “Jack stone in the bladder: case report of a rare entity,” *BMC Urology*, vol. 17, no. 1, p. 40, 2017.
- [2] K. J. Singh, A. Tiwari, and A. Goyal, “Jackstone: A rare entity of vesical calculus,” *Indian Journal of Urology*, vol. 27, no. 4, p. 543, 2011.
- [3] H. A. Fowler, “The microscopic structure of urinary calculi of oxalate of lime, with special reference to the spiculated variety,” *Johns Hopkins Hospital Reports*, vol. 13, pp. 507–556, 1906.
- [4] W. M. Ord and S. G. Shattock, *On the microscopic structure of urinary calculi of oxalate of lime*, Adlar and Son, Bartholomew Close, 1895.
- [5] F. Grases, A. Costa-Bauza, R. M. Prieto et al., “Rare calcium oxalate monohydrate calculus attached to the wall of the renal pelvis,” *International Journal of Urology*, vol. 18, no. 4, pp. 323–325, 2011.
- [6] M. V. Rao, J. S. Agarwal, and N. Chhotray, “Scanning electron microscopic studies of the ultrastructure of Jack stone calculi,” *The Indian Journal of Medical Research*, vol. 77, pp. 288–294, 1983.