



Since January 2020 Elsevier has created a COVID-19 resource centre with free information in English and Mandarin on the novel coronavirus COVID-19. The COVID-19 resource centre is hosted on Elsevier Connect, the company's public news and information website.

Elsevier hereby grants permission to make all its COVID-19-related research that is available on the COVID-19 resource centre - including this research content - immediately available in PubMed Central and other publicly funded repositories, such as the WHO COVID database with rights for unrestricted research re-use and analyses in any form or by any means with acknowledgement of the original source. These permissions are granted for free by Elsevier for as long as the COVID-19 resource centre remains active.

Rotavirus infection in adults

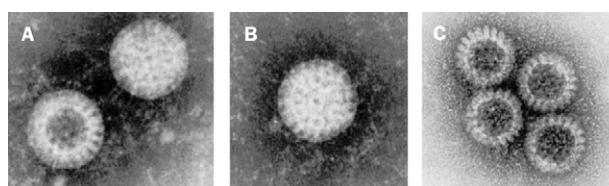
Evan J Anderson and Stephen G Weber

Rotavirus has been recognised for 30 years as the most common cause of infectious gastroenteritis in infants and young children. By contrast, the role of rotavirus as a pathogen in adults has long been underappreciated. Spread by faecal-oral transmission, rotavirus infection in adults typically manifests with nausea, malaise, headache, abdominal cramping, diarrhoea, and fever. Infection can also be symptomless. Rotavirus infection in immunocompromised adults can have a variable course from symptomless to severe and sustained infection. Common epidemiological settings for rotavirus infection among adults include endemic disease, epidemic outbreak, travel-related infection, and disease resulting from child-to-adult transmission. Limited diagnostic and therapeutic alternatives are available for adults with suspected rotavirus infection. Because symptoms are generally self-limiting, supportive care is the rule. Clinicians caring for adults with gastroenteritis should consider rotavirus in the differential diagnosis. In this review we intend to familiarise clinicians who primarily provide care for adult patients with the salient features of rotavirus pathophysiology, clinical presentation, epidemiology, treatment, and prevention.

Lancet Infect Dis 2004; **4**: 91–99

Infective gastroenteritis causes substantial morbidity and mortality worldwide. Although various bacterial species have long been associated with gastrointestinal disease,¹ specific viral causes of these infections were not delineated until the early 1970s. However, with the discovery of Norwalk virus in 1972² and rotavirus in 1973,³ the causative agents for most non-bacterial gastroenteritis infections were identified. Almost immediately, the spectrum of viruses causing gastrointestinal infection in adults was recognised as differing from that in children. Among children younger than 2 years, nearly half of all cases of diarrhoea requiring admission to hospital can be attributed to rotavirus infection.⁴ By contrast, among adults most non-bacterial outbreaks of gastroenteritis can be linked to the Norwalk-like viruses.⁵

The important part played by viral pathogens besides the Norwalk-like viruses in adults with gastroenteritis is not yet fully appreciated. Specifically, the contribution of pathogens that typically affect children is not recognised by most clinicians who take care of adults. Such is the case for adult infections caused by the common paediatric pathogen rotavirus. Here we review important features of rotavirus microbiology and pathophysiology, along with relevant clinical and epidemiological features of rotavirus infection.



Electron micrographs of a human strain of rotavirus B. (A,B) Complete virus; (A,C) stages in the breakdown of virus particles as seen in preparations of stool samples (courtesy of Cornelia Büchen-Osmond, ICTVdB, the universal virus database of the International Committee on Taxonomy of Viruses).

Structure

In 1973, Bishop and colleagues³ described unique viral particles obtained from the duodenal mucosa of children with gastroenteritis. Viruses with similar morphological appearance had been seen in 1963 in the intestinal tissue of mice with diarrhoea.⁶ Under the electron microscope, the 70 nm diameter viral particles first described in these reports had a wheel-like appearance, prompting the name rotavirus, from the Latin *rota* (figure).⁷

Rotavirus is a non-enveloped virus now classified within the Reoviridae family. 11 segments of double-stranded RNA reside within the core. The RNA encodes six viral proteins (VP) that make up the viral capsid, and six non-structural proteins (NSP). The core is surrounded by an inner capsid, composed mostly of VP6, the primary group antigen,^{1,8} and includes the epitope detected by most common diagnostic assays. Other structural proteins also seem to confer some degree of group specificity.⁹ The outer capsid is primarily composed of VP4 and VP7.¹⁰ VP4 contributes the spoke-like projections to the wheel-shaped appearance of rotavirus. This VP is cleaved by trypsin *in vitro* to yield VP5* and VP8*, which appear to play an important part in cellular attachment.⁹ The inner and outer capsids give the viral particle the double-layered icosahedral structure visualised on negative-stain electron microscopy.¹⁰

EJA is at the Division of Infectious Diseases, Northwestern Memorial Hospital and Children's Memorial Hospital, Chicago, IL; and SGW is at the Department of Medicine, Section of Infectious Diseases, Infection Control Program, University of Chicago Hospitals, Chicago, IL, USA.

Correspondence: Dr Stephen G Weber, Department of Medicine, Section of Infectious Diseases, Infection Control Program, University of Chicago Hospitals, MC 5065, 5841 South Maryland Avenue, Chicago, IL 60637, USA. Tel +1 773 702 6776; fax: +1 773 702 8998; email: sgweber@medicine.bsd.uchicago.edu

Panel 1. Potential mechanisms by which rotavirus might induce diarrhoea¹⁴**Reduced absorptive surface**

Denudation of microvilli; shortening, flattening, and atrophy of villi; invasion of villi by rotavirus causing ischaemia and shortening^{3,18,19}

Functionally impaired absorption

Depressed disaccharidase concentrations; impaired co-transport of glucose and sodium; decreased sodium-potassium ATPase activity impairing electrochemical gradient^{3,18,19,23-25}

Cellular damage impairing absorption

Mitochondrial swelling; distension of endoplasmic reticulum; mononuclear cell infiltration^{3,13,18,19}

Enterotoxigenic effects of rotavirus protein NSP4

Induces increased intracellular calcium concentrations; in murine models, acts like a toxin to induce diarrhoea^{21,22}

Stimulation of enteric nervous system

Stimulation of intestinal secretion of fluid and electrolytes; stimulation of intestinal motility resulting in decreased intestinal transit time^{14,20}

Altered epithelial permeability

Increased paracellular permeability by weakening tight junctions between cells²⁶⁻²⁸

Seven distinct groups of rotavirus (named A to G) have been shown to infect various animal species. Of these, only groups A, B, and C have been reported as human pathogens.⁹ Group A is the primary pathogen worldwide and is the group detected by commercially available assays. Additional subgroups and serotypes can be identified by further characterisation of VP4, VP6, and VP7 antigens.¹⁰ Group B seems to be limited to causing epidemic infection in Asia and the Indian subcontinent, whereas group C rotavirus causes endemic infections that frequently go unrecognised.

Pathogenesis

Rotavirus spreads from person to person, mainly by faecal-oral transmission. Although rotavirus has been detected in urine and upper-respiratory samples,^{11,12} these body fluids are not believed to be commonly associated with transmission. After ingestion, rotavirus particles are carried to the small intestine where they enter mature enterocytes¹³ through either direct entry or calcium-dependent endocytosis.¹⁴

After cytolitic replication in the mature enterocytes of the small intestine, new rotavirus particles can infect distal portions of the small intestine or be excreted in the faeces. More than 10¹⁰–10¹¹ viral particles per gram of faeces are excreted by children during infection.^{8,15} The amount of rotavirus excreted by adults might be more variable. In at least one study shedding was 10–100-fold lower in travellers' diarrhoea.¹⁶ Symptom-free adults can shed rotavirus in quantities so low as to be undetectable by most routine assays.¹⁷

The mechanism by which rotavirus induces diarrhoea is poorly understood. Few investigations have incorporated the study of human mucosal samples. The reports that are

available describe various findings: villous shortening, flattening, and atrophy, denudation of microvilli, mitochondrial swelling, distension of the endoplasmic reticulum, depressed disaccharidase concentrations, and infiltration of mononuclear cells.^{14,18,19}

Additional hypotheses about the pathophysiology of rotavirus gastroenteritis have been generated from animal studies. In one review the diminished ability of the intestinal epithelium to absorb fluid and nutrients,¹⁴ stimulation of the enteric nervous system,²⁰ and local villous ischaemia and shortening resulting in impaired nutrient absorption were noted. A murine model of rotavirus infection suggests that rotavirus NSP4 acts as an enterotoxin, potentially by increasing calcium-dependent signalling of chloride secretion.^{21,22} The diarrhoea induced by rotavirus is unlikely to be completely explained by any one process, rather that several mechanisms contribute simultaneously.¹⁴ These mechanisms are summarised in panel 1.^{3,13,14,18-28}

Immunity to rotavirus

Resolution of rotavirus gastroenteritis depends greatly on the immunological response of the host. In a normal host, rotaviral antigens are transported to Peyer's patches, undergo processing by B cells, macrophages, or dendritic cells and are presented to helper T cells. This cascade culminates in stimulation of rotavirus-specific B cell and cytotoxic T-lymphocyte-precursor expansion.²⁹ Bernstein and colleagues³⁰ noted that stool rotavirus IgA concentrations peaked 14–17 days after infection and persisted for longer than 1 year, but at declining concentrations. The researchers suggested that serum rotavirus IgA is a more consistent marker of rotavirus immunity than other antibody measurements.³⁰ However, rotavirus-specific IgA is frequently undetectable in duodenal fluid or faeces in the first week of infection, although symptoms might resolve within that time.²⁹ This pattern suggests a mechanism independent of humoral immunity. Offit²⁹ notes that infected mature villous epithelial cells are steadily replaced by less-mature enterocytes, which may be less susceptible to rotavirus invasion. Increased peristalsis improves clearance of viral particles and the non-specific activity of interferons can prevent VP translation.²⁹ De Bouissieu³¹ has reported that interferon α concentrations correlate with a trend towards shorter duration of diarrhoea among patients who have rotavirus infection.

Although many physicians presume that rotavirus infection will confer lifelong immunity, multiple investigations show that re-infection can occur. Bishop and colleagues³² noted that infection with rotavirus during the neonatal period did not protect against developing rotavirus infection during the first 3 years of life but did lessen the severity of such infections. In a prospective study of 200 Mexican infants followed up from birth, Valazquez and colleagues³³ noted that by age 2 years 96% of infants had experienced a primary rotavirus infection. During the same period, nearly 70% of the infants experienced a second infection. More than 10% of the children studied had five or more rotavirus infections during the first 2 years of life. Yolken and colleagues³⁴ had previously noted that by age

2 years, more than 85% of children had antibodies to two different rotavirus serotypes. Therefore, although nearly all adults have antibodies to rotavirus,³⁵ they might still be susceptible to infection.

Rotavirus can elude host defences and induce repeat infection through several mechanisms. There are multiple groups, subgroups, and serotypes of rotavirus. Initial antibody response to infection is serotype specific, with limited production of cross-reactive antibodies.³⁶ Subsequent rotavirus infections increase antibodies that cross-react with multiple serotypes.³⁶

Additionally, certain elements of the rotavirus-specific immune response are short-lived. Rotavirus-specific secretory IgA is sometimes not detectable in faeces as early as 1 year after infection.³⁷ Elias³⁸ reported that rotavirus fluorescent antibody titres peaked in children at age 1–3 years but subsequently fell to almost undetectable concentrations in individuals older than 70 years.³⁸ In a review of multiple studies, Jiang and colleagues³⁶ noted that serum concentrations of rotavirus-specific antibodies were a marker for protection against future infection. Correlates of protection from studies of natural infection, challenge studies, and vaccine studies are detailed in panel 2.^{29,35–37,39–50}

Clinical presentation

An appreciation of the typical presentation of rotavirus infection in children is critical to understanding the spectrum of disease among adults. Primary infection with rotavirus typically occurs in infants between ages 6 months and 2 years, although infection in neonatal intensive-care units and severe infection in infants younger than 6 months are well documented.^{51,52} In all age-groups, the classic presentation of rotaviral infection is fever and vomiting for 2–3 days, followed by non-bloody diarrhoea.⁵³ The diarrhoea may be profuse, and 10–20 bowel movements per day are common. When examined, the stool from affected patients is generally devoid of faecal leucocytes. Especially when associated with vomiting, the diarrhoea of rotavirus infection can precipitate severe and even life-threatening dehydration. Infants with repeat rotavirus infections are generally less-severely affected than those with primary disease.³³

Among adults, rotavirus infection has been associated with a wide spectrum of disease severity and manifestations. As such, it is difficult to provide a concise description of a typical clinical presentation. Nevertheless, prospective studies of voluntary rotavirus ingestion have provided some insight, although the participants in these studies were primarily young healthy adults. Data from several such trials are summarised in the table.^{35,46–48,54} For these volunteers, illness most frequently began 2–6 days after ingestion and continued for 1–4 days. About two-thirds of study participants had an antibody response, with more than half of all participants eventually shedding rotavirus. Symptoms were less common than evidence of infection, but most frequently included diarrhoea, fever, headache, malaise, nausea, or cramping. One participant passed 11 stools in 1 day.³⁵ Among the volunteers, rotavirus particles were detectable in the stool

Panel 2. Correlates of protection against rotavirus^{29,36,39}

Natural infection

Quantity of cross-reactive neutralising antibody responses against multiple serotypes,^{40–42} of virus-specific secretory IgA at intestinal mucosa surface,^{37,43} and of virus-specific IgA and IgG in serum^{41,44}

Challenge studies

Serum serotype specific neutralising antibody;^{35,45} intestinal neutralising antibody;^{46,47} serum rotavirus IgG, but not necessarily with large doses;^{46–48} and raised prechallenge titres of antibody to specific epitope of rotavirus VP7⁴⁹

Vaccine studies

Vaccine-induced serum antibodies might be important in protection from natural infection, but interpretation is complicated because of differences in methods of existing studies;³⁶ and heterotypic antibody response to rotavirus vaccination might be protective against usual infecting serotypes^{36,50}

from the start of symptom onset and persisted for more than 10 days in some. Three studies document rotavirus readministration to volunteers, noting that symptoms and antibody response were much less common.^{35,47,54}

In several reports of rotavirus outbreaks among adults similar symptoms have been described. In a prospective study of 98 families with neonates followed up from shortly after birth, only 17 of 43 adults who had serological evidence of rotavirus infection were symptomless.⁵⁵ 14 had diarrhoea and 11 had abdominal cramping. None had symptoms that necessitated medical care or absence from work. In a separate study, 14 parents of children with rotavirus gastroenteritis developed serological evidence of infection, but only three had diarrhoea.⁵⁶ Grimwood and colleagues⁵⁷ found, in a study of children with rotavirus in 28 families, that 18 of 54 adult family members exposed to rotavirus developed evidence of infection, and all but four were symptomatic. In a study of college students during a rotavirus outbreak, of the 83 individuals who met the criteria for rotavirus infection, 93% had diarrhoea, 90% abdominal pain or discomfort, 83% loss of appetite, 81% nausea, and more than 50% had fatigue, vomiting, headache, chills, subjective or low-grade fever, or myalgia.⁵⁸

Patients with underlying immunodeficiency are at risk of sustained symptoms and rotavirus dissemination, a phenomenon already recognised among children. This pattern was first described in 1980 when two of four children with underlying primary immunodeficiency who had rotavirus infection developed chronic diarrhoea that at least temporarily responded to administration of human milk containing a high titre of rotavirus antibodies.⁵⁹ A geriatric patient with impaired natural-killer-cell activity and impaired cellular and humoral immunity had rotavirus shedding for at least 35 days.⁶⁰ Gilger and colleagues⁶¹ noted that in four children who had various immune deficits and chronic diarrhoea from rotavirus, rotavirus was identified in the liver and kidney. Whether the involvement of liver or kidney was important is unclear.

Symptoms of adult volunteers after rotavirus ingestion

Study	Dose administered	Evidence of infection			Proportion of patients with specific rotavirus-related symptoms								
		Symptoms	Antibody response	Shed rotavirus	Diarrhoea	Vomiting	Headache	Anorexia	Malaise	Cramping or gas	Temperature >37.2°C	Chills	Nausea
Middleton et al, 1974 (n=1) ⁵⁴	1 × 10 ⁸ viral particles	0	0	0	0	0	0	0	0	0	0	0	0
Kapikian et al, 1983 (n=18) ⁵⁵	1 mL 0.2% stool filtrate	22%	67%	28%	22%	11%	22%	22%	17%	11%	17%	NR	NR
Ward et al, 1986 (n=36) ^{56*}	>9 ffu	50%	64%	58%	36%	8%	14%	NR	17%	17%	19%	11%	22%
Ward et al, 1989 (n=38) ^{56†}	9 × 10 ¹ to 9 × 10 ³ ffu	39%	66%	58%	NR	NR	NR	NR	NR	NR	NR	NR	NR
Ward et al, 1990 (n=4) ^{57‡}	9 × 10 ³ ffu	25%	75%	50%	NR	NR	NR	NR	NR	NR	NR	NR	NR
Summary percentages§	..	39%	65%	52%	31%	9%	16%	21%	16%	15%	18%	11%	22%

ffu=focus forming unit. NR=data not recorded in original paper and taken as not having occurred in calculation of summary percentages. *Data included when >50% infectious dose ingested (>9 ffu). †15 of 38 patients had mild illness (including one patient with no antibody response or shedding). ‡One of four volunteers experienced illness but no specific symptoms were recorded. §Summary percentages after rotavirus ingestion calculated only from data from studies in which full clinical syndrome of illness described. All percentages have been rounded to the nearest whole percentage point.

Other investigators have assessed the course of rotavirus infection in patients with malignant disease. A wide spectrum of clinical manifestations and severity of illness have been reported. Bolivar⁶² screened 90 adults who had various solid tumours and leukaemia, with and without diarrhoea. He noted that two patients had rotavirus infection, both of whom had undergone bone-marrow transplantation and had developed graft-versus-host disease. Diarrhoea lasted for 10 days before resolution.

In three subsequent studies in bone-marrow-transplant patients results varied. Yolken and colleagues⁶³ prospectively assessed patients undergoing bone-marrow transplantation for infectious gastroenteritis and found that rotavirus occurred less frequently than *Clostridium difficile* or adenovirus, but still occurred in nine of 78 patients. In one patient, adenovirus occurred concomitantly with rotavirus infection. Of the eight remaining patients, all developed vomiting, seven had abdominal cramps, six had respiratory illness (infiltrates on chest radiography with appropriate clinical signs and symptoms) and four had diarrhoea. Five of the eight rotavirus-infected patients eventually died. Troussard and colleagues⁶⁴ also prospectively assessed patients undergoing bone-marrow transplantation and noted rotavirus infection in eight of 94 patients. Adenovirus occurred concomitantly in two patients. Seven of the patients had isolates positive for rotavirus in the winter months, with acute onset, vomiting, and diarrhoea. In a later study of the same topic, rotavirus was noted in four of 60 adult asymptomatic stem-cell-transplant patients followed up prospectively.⁶⁵ No patient with gastroenteritis had rotavirus isolated.

Rotavirus infections in adult patients infected with HIV-1 frequently present as a chronic diarrhoea with sustained viral shedding in stools. Albrecht and colleagues,⁶⁶ between 1987 and 1991, detailed a retrospective assessment of 106 samples from 66 patients infected with HIV-1 who

had otherwise unexplained diarrhoea. 35 samples from patients without diarrhoea served as controls. 13 samples from nine case patients were positive for rotavirus; two of these samples were rotavirus recurrences 6 months after the initial episode. No symptom-free patients had rotavirus infection. Rotavirus was associated with diarrhoea of 2–8 weeks' duration in all patients and with abdominal cramping in eight patients. Thomas and colleagues⁶⁷ looked prospectively at 862 samples from 377 UK HIV-1-positive patients with diarrhoea. Rotavirus was third in frequency to adenovirus and coronavirus, occurring in 11 (2.4%) samples. The median CD4 count of patients with rotavirus infection was nine.

Epidemiology

Hrdy⁶⁸ described five typical settings for rotavirus infections in adults. We propose modification of these classifications to the following: endemic disease, epidemic outbreaks, travel-related gastroenteritis, and infections transmitted from children to adults. Although substantial overlap exists between the groups, our classifications clarify separate risk factors and clinical features.

Endemic disease

Rotavirus infection in children is seasonal, with peak incidence in winter months in temperate climates. Iturriza-Gomara and colleagues⁶⁹ noted that, in the UK between 1995 and 1998, notable numbers of infections began in December or January, peaking in March or April and falling to almost zero by July. In the USA, Kapikian and colleagues⁵⁶ found that rotavirus cause 59% of diarrhoea cases necessitating admission to hospital in children between November and April, but could not be linked to cases from May to October.

In several studies findings suggest that adult disease is not as season-specific as childhood disease. Cox and Medley⁷⁰ noted that IgM antibodies to group A rotavirus in

adult serum in routine hospital samples are present throughout the year. IgM concentrations increased with older age, and antibodies reached 20% in March and fell to 10–11% during the summer months. Cox and Medley attributed the high rates to IgM persistence, IgM cross-reactivity, or possibly to non-seasonal high infection rates in adults. Other researchers have also found that rates of adult disease do not mirror the winter seasonality of infection in paediatric patients.⁷¹ These studies suggest that endemic disease in adults may not arise solely from unrecognised transmission of rotavirus from children to adults.

The contribution of rotavirus as a cause of endemic gastrointestinal disease varies according to geographic distribution and characteristics of patients. In a small prospective study in the UK, rotavirus caused 4.1% of acute diarrhoea in adults admitted to hospital.⁷² Similarly, 3% of acute diarrhoea in Switzerland,⁷³ 3% of infectious diarrhoea pathogens in a Swedish clinic for infectious diseases,⁷⁴ 5% of adults with gastroenteritis requiring admission in Thailand,⁷⁵ 2–4% of adults older than 15 years with gastroenteritis presenting to their family physician in the Netherlands,⁷⁶ and nearly 4% of individuals older than 45 years in Michigan⁷⁷ were due to rotavirus.

In studies in other geographic areas even higher rates of infection have been seen. In Japan, Nakajima and colleagues⁷¹ reported that group A rotavirus had a role in 14% of patients with diarrhoea. Pryor and colleagues⁷⁸ noted that rotavirus was second only to *Campylobacter* spp as a cause of diarrhoea among Australian adults, accounting for 17% of all cases. In Indonesia, 42% of patients presenting with diarrhoea had rotavirus-positive stools compared with 11% of control samples.⁷⁹ In a study of Mexican adults, 63% of patients presenting with acute gastroenteritis during winter months were positive for rotavirus.⁸⁰

Even these results might underestimate the true prevalence of endemic rotavirus infection. Group C rotavirus is not routinely detected by commercial assays but it does contribute to endemic rotavirus infection worldwide. In a study in the UK, 43% of patients were seropositive for group C rotavirus.⁸¹

Epidemic outbreaks

Among adults, clusters of rotavirus infections most frequently occur in communities that are otherwise sheltered from more routine exposure to rotavirus-infected children.⁸² One of the largest outbreaks involved nearly 3500 people in 1964, in an isolated area of Micronesia.⁸³ Since then, other outbreaks have occurred among closed communities, including a Finnish military base,⁸⁴ an Israeli kibbutz,⁸⁵ and an isolated South American Indian community.⁸⁶

Outbreaks of rotavirus infection have also occurred in long-term health-care facilities, particularly those with close living quarters; compromised host immunity and multiple comorbid disorders might help facilitate the spread of infection.^{87–91} Cubitt and colleagues⁸⁸ described an epidemic of rotavirus among staff and patients in an extended-stay geriatric hospital, in which 15 of 39 residents developed symptoms and seven had confirmed rotavirus infection. Halvorsrud and Orstavik⁹² described an outbreak of 92 cases

of acute gastroenteritis among nursing-home patients with identification of rotavirus by comparing acute and convalescent antibody titres. Rotavirus has been suggested as the causal pathogen in 5% of diarrhoea outbreaks in a study of institutions caring for elderly residents.⁹³

Among adults, rotavirus outbreaks are not confined to geriatric populations. Group A rotavirus was associated with an outbreak of gastroenteritis among college students in the District of Columbia.⁵⁸ Rotavirus also caused a waterborne outbreak of gastroenteritis in 1981 in Eagle-Vail and Avon, CO, USA in which severity of symptoms correlated with the amount of tap water consumed.⁹⁴ Finally, Griffin and colleagues⁹⁵ screened 263 outbreaks of gastroenteritis in the USA between 1998 and 2000 and found that rotavirus was implicated in three outbreaks. Uniquely affecting Asia, group B rotavirus has been associated with outbreaks affecting large numbers of adults in broad geographic distributions of China and India.^{96,97}

Travel-related gastroenteritis

Rotavirus has been implicated as an important contributor to travellers' diarrhoea among adults, especially among those visiting Central America and the Caribbean. In a study of travellers returning from Jamaica, rotavirus was identified in 9% of individuals with diarrhoea, making the virus second only to enterotoxigenic *Escherichia coli* as a cause.⁹⁸ In two studies of US students travelling in Mexico, electron microscopy identified rotavirus in about 25% of patients who had diarrhoea, compared with 3% and 15%, respectively, of symptom-free patients.^{99,100} In a third study, a substantial rise of antibodies to rotavirus was seen in 17% of two student groups travelling to Mexico.¹⁰¹ By contrast, only 5–6% seroconverted to Norwalk virus.¹⁰¹ Ryder and colleagues¹⁰² found rotavirus in 26% of Panamanian travellers to Mexico who had diarrhoea. Sheridan and colleagues¹⁰³ similarly found that 36% of US Peace Corps volunteers and 30% of Panamanian travellers visiting Mexico had at least a four-fold increase in rotavirus antibody titres. Adult travellers with rotavirus shed 10–100 times less rotavirus than do paediatric patients.^{99,100}

Infection transmitted from children to adults

Although rotavirus can be linked to adult gastroenteritis in each of the other settings, adults who are in contact with children are at particularly high risk of infection. Transmission of rotavirus within families from children to parents seems to be a common event. Wenman and colleagues⁵⁵ showed prospectively that rotavirus infection occurred in 36 of 102 adults caring for children with rotavirus infection. By contrast, only four of 86 adults whose children had no documented rotavirus infection became infected.⁵⁵ Grimwood and colleagues⁵⁷ confirmed this finding in a report that a third of adult family members in New Zealand developed evidence of rotavirus infection. The same phenomenon has been seen among parents of more severely ill children. Kim and colleagues¹⁰⁴ found evidence of rotavirus infection in 55% of adult contacts of children who were admitted to hospital with rotavirus, compared with 17% of adult contacts whose children were

not infected. More casual contact might also be sufficient to facilitate rotavirus transmission from children to adults. Rodriguez and colleagues¹⁰⁵ reported that nine of 12 adults experienced illness after exposure to children infected with rotavirus in a playgroup. Although substantial evidence is lacking, child-to-adult transmission of rotavirus is accepted to occur with some frequency on paediatric wards. Many paediatric nurses, medical students, and house officers experience symptoms of gastroenteritis during the winter months when most paediatric rotavirus infections are encountered. Von Bonsdorff and colleagues¹⁰⁶ described paediatric nurses at several different locations with acute gastroenteritis caused by rotavirus. Among seven hospital staff that developed diarrhoea after direct contact with children with diarrhoea staying in hospital, a rise in antibody titres was detected in three.¹⁰⁴ Interestingly, in the same study, six of 45 medical students reported gastroenteritis. Three of the students had rotavirus particles present on electron microscopy and were noted to be more ill than the parents of the children who were infected. All had diarrhoea for 3–6 days and two of the three had low-grade fever and vomiting. Another case report supports transmission of rotavirus from children to hospital caretakers.¹⁰⁷

Diagnosis

Electron microscopy, which permits visualisation of the pathognomonic wheel-like appearance, was initially used for diagnostic purposes, but ELISA or EIA have become more commonly used. Commercial assays are reliable, convenient, and inexpensive, but require at least 10^4 – 10^7 virions to generate a positive result.^{108,109} The false-positive rate of commercial assays is 3–5%.⁶⁹ One of the biggest limitations of most commercial assays is that they do not detect non-group-A rotavirus.^{68,110} Other more sensitive and newer methods are being used in research. One such method is PCR, which is up to 1000 times more sensitive than immunoassays.¹⁰⁹ In one study using PCR, 30% of otherwise healthy children shed virus for 25–57 days after symptoms developed.¹¹¹

Although stool cultures are routinely tested for bacterial pathogens, the low frequency of detecting a positive result calls the usefulness of this practice into question. Rotavirus infection can occur in a similar number of patients to some bacterial pathogens. Sending a sample of rotavirus antigen for testing by ELISA or EIA could potentially cut costs if by doing so either hospital stay or procedures could be avoided. Such a cost-benefit analysis in adult patients has not been published. One limitation is that adults might shed less rotavirus in faeces than do children, further hampering diagnosis.¹⁰⁰ We suggest that obtaining rotavirus antigen testing for patients admitted to hospital with risk factors for rotavirus infection will be cost effective if additional inpatient studies can be avoided. Determination of rotavirus infection may also be beneficial if infectious patients can be isolated to prevent nosocomial spread. A positive rotavirus antigen test might also allow physicians to avoid prescribing antibiotics for travel-related rotavirus infections.

Treatment

Treatment of rotavirus infections is primarily directed at symptom relief and restoration of normal physiological function. Oral rehydration should be attempted initially. In most developing countries, oral rehydration salt solutions are used extensively in children. Most adults can be managed by encouraging them to drink fluids. An additional intervention that has been used is administration of *Lactobacillus* spp bacteria to shorten the duration of diarrhoea.^{112,113} Although seldom used in children, codeine, loperamide, and diphenoxylate can help with symptom relief and control of the volume of diarrhoea.¹¹⁴ Bismuth salicylate, in a placebo-controlled double-blinded trial, was efficacious in treating the symptoms of rotavirus diarrhoea.¹¹⁵ Trial use of bismuth salicylate can be considered in adults when other coexistent infectious causes have been ruled out.

If symptoms cannot be controlled and the patient becomes dehydrated, administration of intravenous fluids and hospital admission might be necessary. Rarely, extraordinary measures have been attempted to help resolve rotavirus infections. For example, human breastmilk has been provided to immunodeficient infected children to help resolve chronic diarrhoea.⁵⁹ This option, however, is not practical in adults. Several groups report oral administration of human serum immunoglobulins possessing antirotavirus activity to bind free rotavirus antigen. Guarino and colleagues¹¹⁶ noted a mean duration of diarrhoea of 76 h in children who received one oral dose of 300 mg/kg human serum immunoglobulin, compared with 131 h in children who did not. In a study involving three immunocompromised children with chronic rotavirus diarrhoea, oral administration of human serum immunoglobulins (IgG 150 mg/kg) cleared rotavirus antigen in all three, but rotavirus antigen recurred in two.¹¹⁷ Among adults, oral immunoglobulin administration of 5–6 g daily for 5 days to bone-marrow-transplant recipients has been successful.¹¹⁸

Prevention

Prevention of rotavirus infection can be facilitated by avoiding exposures and faecal-oral spread. Contact with sick children and potentially contaminated food and water should be avoided. Since 43% of rotavirus virions placed on human fingers survive for 60 min, thorough hand washing is critical in prevention.¹¹⁹ Contact isolation for patients diagnosed with rotavirus infection is necessary, generally for the duration of hospital stay, because of sustained faecal shedding of low concentrations of virus.¹²⁰ Gloves, gowns, isolation, and rigorous hand washing should be used in the care of individuals infected with rotavirus.¹²¹

Sattar and colleagues¹²² reported that rotavirus survives best in low humidity on non-porous surfaces at room temperature or cooler. Phenolic disinfectants do not inactivate rotavirus; instead hypochlorite or sodium dichloroisocyanurate tablets with a free chlorine concentration of at least 20 000 parts per million are recommended.¹¹⁰ A 70% ethanol solution is also effective in inactivation of rotavirus and can help to prevent environmental spread.¹²⁰ Rotavirus infection in adults has been successfully prevented by use of a commercially available

Search strategy and selection criteria

We identified sources for this review by searches of Medline with use of the key words "rotavirus infection" and "adult." The search strategy and selection criteria included all English and human studies from the year 1970 until the present. We further reviewed the abstracts for relevance before inclusion. Review of the references of the papers retrieved by the initial search allowed for additional studies to be identified and considered for inclusion.

disinfectant spray on rotavirus contaminated fomites under experimental conditions.¹²³

Given the substantial disease-related morbidity and mortality associated with rotavirus, the development of an effective vaccine is a priority. Although multiple vaccines were under development, the tetravalent rhesus-human reassortant rotavirus vaccine (RRV-TV) seemed to produce the best results. The RRV-TV vaccine prevented about half of rotavirus infections, but was much more effective in preventing severe disease.^{124,125} Shortly after the vaccine was approved, the vaccine adverse-event monitoring system noted by mid-1999 an excess of cases of intussusception among recently vaccinated infants, eventually prompting the vaccine to be withdrawn. Two sharply differing perspectives on the risk and benefits of the RRV-TV vaccine and the Advisory Committee on Immunization Practices' confirmation of its decision to withdraw its recommendation for the vaccine have been put forward.^{126,127} Other vaccines are under development.

Vaccines have been primarily developed to attempt to decrease the severity of rotavirus infections in children. Although vaccines seem to be fairly safe in adults from the vaccine trials, we are unaware of any plan to consider vaccination in adult patients. Vaccination could theoretically be used in adult patients considering travel to Central America or the Caribbean or among immunocompromised patients to prevent or lessen the severity of rotavirus diarrhoea.

Salient points

Despite recognition as an important cause of gastroenteritis in children, rotavirus's role in adult gastroenteritis is underappreciated. Immunity to rotavirus is incomplete and most people have multiple infections over their lifetime. Adults with rotavirus can be asymptomatic, but the most common symptoms are nausea, malaise, headache, abdominal cramping, diarrhoea, and fever. Adults at particular risk of rotavirus infection are travellers, adults exposed to infected children, and immunocompromised people. Group A rotavirus, the most common human pathogen, can be diagnosed with many different commercial assays, but all have limited sensitivity. Rotavirus testing might be beneficial in certain clinical settings if detecting rotavirus would change management of patients or prevent nosocomial spread. Treatment is primarily symptomatic. Rotavirus should be considered in the differential diagnosis of adult infectious gastroenteritis.

Conflicts of interest

We have no conflicts of interest.

References

- Parashar UD, Bresee JS, Gentsch JR, Glass RI. Rotavirus. *Emerg Infect Dis* 1998; **4**: 561–70.
- Kapikian AZ, Wyatt RG, Dolin R, Thornhill TS, Kalica AR, Chanock RM. Visualization by immune electron microscopy of a 27-nm particle associated with acute infectious nonbacterial gastroenteritis. *J Virol* 1972; **10**: 1075–81.
- Bishop RF, Davidson GP, Holmes IH, Ruck BJ. Virus particles in epithelial cells of duodenal mucosa from children with acute non-bacterial gastroenteritis. *Lancet* 1973; **2**: 1281–83.
- Kapikian AZ. Viral gastroenteritis. *JAMA* 1993; **269**: 627–30.
- Fankhauser RL, Noel JS, Monroe SS, Ando T, Glass RI. Molecular epidemiology of "Norwalk-like viruses" in outbreaks of gastroenteritis in the United States. *J Infect Dis* 1998; **178**: 1571–78.
- Adams WR, Kraft LM. Epizootic diarrhea of infant mice: identification of the etiologic agent. *Science* 1963; **141**: 359–60.
- Flewett TH, Bryden AS, Davies H, et al. Relationship between viruses from acute gastroenteritis of children and newborn calves. *Lancet* 1974; **2**: 61–63.
- Desselberger U. Rotavirus infections: guidelines for treatment and prevention. *Drugs* 1999; **58**: 447–52.
- Estes MK. Rotaviruses and their replication. In: Knipe DM, Howley PM, eds. *Fields' virology*, 4th edn. Philadelphia: Lippincott Williams and Wilkins, 2001: 1747–85.
- Kapikian AZ, Hoshino Y, Chanock RM. Rotaviruses. In: Knipe DM, Howley PM, eds. *Fields' virology*, 4th edn. Philadelphia: Lippincott Williams and Wilkins, 2001: 1787–83.
- Vollet JJ 3rd, DuPont HL, Pickering LK. Nonenteric sources of rotavirus in acute diarrhea. *J Infect Dis* 1981; **144**: 495.
- Zheng BJ, Chang RX, Ma GZ, et al. Rotavirus infection of the oropharynx and respiratory tract in young children. *J Med Virol* 1991; **34**: 29–37.
- Holmes IH, Ruck BJ, Bishop RF, Davidson GP. Infantile enteritis viruses: morphogenesis and morphology. *J Virology* 1975; **16**: 937–43.
- Lundgren O, Svensson L. Pathogenesis of rotavirus diarrhea. *Microbes Infect* 2001; **3**: 1145–56.
- Anon. Rotaviruses of man and animals. *Lancet* 1975; **1**: 257–59.
- Vollet JJ, Ericsson CD, Gibson G, et al. Human rotavirus in an adult population with travelers' diarrhea and its relationship to the location of food consumption. *J Med Virol* 1979; **4**: 81–87.
- Barnes GL, Callaghan SL, Kirkwood CD, Bogdanovic-Sakran N, Johnston LJ, Bishop RF. Excretion of serotype G1 rotavirus strains by asymptomatic staff: a possible source of nosocomial infection. *J Pediatr* 2003; **142**: 722–25.
- Barnes GL, Townley RR. Duodenal mucosal damage in 31 infants with gastroenteritis. *Arch Dis Child* 1973; **48**: 343–49.
- Davidson GP, Barnes GL. Structural and functional abnormalities of the small intestine in infants and young children with rotavirus enteritis. *Acta Paediatr Scand* 1979; **68**: 181–86.
- Lundgren O, Peregrin AT, Persson K, Kordasti S, Uhnou I, Svensson L. Role of the enteric nervous system in the fluid and electrolyte secretion of rotavirus diarrhea. *Science* 2000; **287**: 491–95.
- Ball JM, Tian P, Zeng CQ, Morris AP, Estes MK. Age-dependent diarrhea induced by a rotaviral nonstructural glycoprotein. *Science* 1996; **272**: 101–04.
- Horie Y, Nakagomi O, Koshimura Y, et al. Diarrhea induction by rotavirus NSP4 in the homologous mouse model system. *Virology* 1999; **262**: 398–407.
- Halaihel N, Lievin V, Alvarado F, Vasseur M. Rotavirus infection impairs intestinal brush-border membrane Na⁺-solute cotransport activities in young rabbits. *Am J Physiol Gastrointest Liver Physiol* 2000; **279**: G587–96.
- Keljo DJ, MacLeod RJ, Perdue MH, Butler DG, Hamilton JR. D-Glucose transport in piglet jejunal brush-border membranes: insights from a disease model. *Am J Physiol* 1985; **249**: G751–60.
- MacLeod RJ, Hamilton JR. Absence of a cAMP-mediated antiabsorptive effect in an undifferentiated jejunal epithelium. *Am J Physiol* 1987; **252**: G776–82.
- Dickman KG, Hempson SJ, Anderson J, et al. Rotavirus alters paracellular permeability and energy metabolism in Caco-2 cells. *Am J Physiol Gastrointest Liver Physiol* 2000; **279**: G757–66.
- Johansen K, Stintzing G, Magnusson KE, et al. Intestinal permeability assessed with polyethylene glycols in children with diarrhea due to rotavirus and common bacterial pathogens in a developing community. *J Pediatr Gastroenterol Nutr* 1989; **9**: 307–13.
- Obert G, Peiffer I, Servin AL. Rotavirus-induced structural and functional alterations in tight junctions of polarized intestinal Caco-2 cell monolayers. *J Virol* 2000; **74**: 4645–51.
- Offit PA. Host factors associated with protection against rotavirus disease: the skies are clearing. *J Infect Dis* 1996; **174**: S59–64.
- Bernstein DI, McNeal MM, Schiff GM, Ward RL. Induction and persistence of local rotavirus antibodies in relation to serum antibodies. *J Med Virology* 1989; **28**: 90–95.
- De Boissieu D, Lebon P, Badoual J, Bompard Y, Dupont C. Rotavirus induces alpha-interferon release in children with gastroenteritis. *J Pediatr Gastroenterol Nutr* 1993; **16**: 29–32.
- Bishop RF, Barnes GL, Cipriani E, Lund JS. Clinical immunity after neonatal rotavirus infection: a prospective longitudinal study in young children. *N Engl J Med* 1983; **309**: 72–76.
- Velazquez FR, Matson DO, Calva JJ, et al. Rotavirus infections in infants as protection against subsequent infections. *N Engl J Med* 1996; **335**: 1022–28.
- Yolken RH, Wyatt RG, Zissis G, et al. Epidemiology of human rotavirus Types 1 and 2 as studied by enzyme-linked immunosorbent assay. *N Engl J Med* 1978; **299**: 1156–61.
- Kapikian AZ, Wyatt RG, Levine MM, et al. Oral administration of human rotavirus to volunteers: induction of illness and correlates of resistance. *J Infect Dis* 1983; **147**: 95–106.
- Jiang B, Gentsch JR, Glass RI. The role of serum antibodies in the protection against rotavirus disease: an overview. *Clin Infect Dis* 2002; **34**: 1351–61.

- 37 Coulson BS, Grimwood K, Hudson IL, Barnes GL, Bishop RF. Role of coproantibody in clinical protection of children during reinfection with rotavirus. *J Clin Microbiol* 1992; **30**: 1678–84.
- 38 Elias MM. Distribution and titres of rotavirus antibodies in different age groups. *J Hyg* 1977; **79**: 365–72.
- 39 Ward RL. Mechanisms of protection against rotavirus in humans and mice. *J Infect Dis* 1996; **174** (suppl 1): S51–58.
- 40 Chiba S, Yokoyama T, Nakata S, et al. Protective effect of naturally acquired homotypic and heterotypic rotavirus antibodies. *Lancet* 1986; **2**: 417–21.
- 41 O’Ryan ML, Matson DO, Estes MK, Pickering LK. Anti-rotavirus G type-specific and isotype-specific antibodies in children with natural rotavirus infections. *J Infect Dis* 1994; **169**: 504–11.
- 42 Ward RL, Bernstein DI. Protection against rotavirus disease after natural rotavirus infection: US Rotavirus Vaccine Efficacy Group. *J Infect Dis* 1994; **169**: 900–04.
- 43 Matson DO, O’Ryan ML, Herrera I, Pickering LK, Estes MK. Fecal antibody responses to symptomatic and asymptomatic rotavirus infections. *J Infect Dis* 1993; **167**: 577–83.
- 44 Velazquez FR, Matson DO, Guerrero ML, et al. Serum antibody as a marker of protection against natural rotavirus infection and disease. *J Infect Dis* 2000; **182**: 1602–09.
- 45 Kapikian AZ, Wyatt RG, Levine MM, et al. Studies in volunteers with human rotaviruses. *Dev Biol Stand* 1983; **53**: 209–18.
- 46 Ward RL, Bernstein DI, Shukla R, et al. Effects of antibody to rotavirus on protection of adults challenged with a human rotavirus. *J Infect Dis* 1989; **159**: 79–88.
- 47 Ward RL, Bernstein DI, Shukla R, et al. Protection of adults rechallenged with a human rotavirus. *J Infect Dis* 1990; **161**: 440–45.
- 48 Ward RL, Bernstein DI, Young EC, Sherwood JR, Knowlton DR, Schiff GM. Human rotavirus studies in volunteers: determination of infectious dose and serological response to infection. *J Infect Dis* 1986; **154**: 871–80.
- 49 Green KY, Kapikian AZ. Identification of VP7 epitopes associated with protection against human rotavirus illness or shedding in volunteers. *J Virol* 1992; **66**: 548–53.
- 50 Green KY, Taniguchi K, Mackow ER, Kapikian AZ. Homotypic and heterotypic epitope-specific antibody responses in adult and infant rotavirus vaccinees: implications for vaccine development. *J Infect Dis* 1990; **161**: 667–79.
- 51 Sharma R, Hudak ML, Premachandra BR, et al. Clinical manifestations of rotavirus infection in the neonatal intensive care unit. *Pediatr Infect Dis J* 2002; **21**: 1099–105.
- 52 Crawley JM, Bishop RF, Barnes GL. Rotavirus gastroenteritis in infants aged 0–6 months in Melbourne, Australia: implications for vaccination. *J Paediatr Child Health* 1993; **29**: 219–21.
- 53 Grimwood K, Lund JC, Coulson BS, Hudson IL, Bishop RF, Barnes GL. Comparison of serum and mucosal antibody responses following severe acute rotavirus gastroenteritis in young children. *J Clin Microbiol* 1988; **26**: 732–38.
- 54 Middleton PJ, Szymanski MT, Abbott GD, Bortolussi R. Orbivirus acute gastroenteritis of infancy. *Lancet* 1974; **1**: 1241–44.
- 55 Wenman WM, Hinde D, Feltham S, Gurwith M. Rotavirus infection in adults. Results of a prospective family study. *N Engl J Med* 1979; **301**: 303–06.
- 56 Kapikian AZ, Kim HW, Wyatt RG, et al. Human reovirus-like agent as the major pathogen associated with “winter” gastroenteritis in hospitalized infants and young children. *N Engl J Med* 1976; **294**: 965–72.
- 57 Grimwood K, Abbott GD, Fergusson DM, Jennings LC, Allan JM. Spread of rotavirus within families: a community based study. *BMJ* 1983; **287**: 575–77.
- 58 Foodborne outbreak of Group A rotavirus gastroenteritis among college students: District of Columbia, March–April 2000. *MMWR Morb Mortal Wkly Rep* 2000; **49**: 1131–33.
- 59 Saulsbury FT, Winkelstein JA, Yolken RH. Chronic rotavirus infection in immunodeficiency. *J Pediatr* 1980; **97**: 61–65.
- 60 Mori I, Matsumoto K, Sugimoto K, et al. Prolonged shedding of rotavirus in a geriatric inpatient. *J Med Virol* 2002; **67**: 613–15.
- 61 Gilger MA, Matson DO, Conner ME, Rosenblatt HM, Finegold MJ, Estes MK. Extraintestinal rotavirus infections in children with immunodeficiency. *J Pediatr* 1992; **120**: 912–17.
- 62 Bolivar R. Rotavirus screening in adult cancer patients. *South Med J* 1983; **76**: 418.
- 63 Yolken RH, Bishop CA, Townsend TR, et al. Infectious gastroenteritis in bone-marrow-transplant recipients. *N Engl J Med* 1982; **306**: 1010–12.
- 64 Troussard X, Bauduer F, Gallet E, et al. Virus recovery from stools of patients undergoing bone marrow transplantation. *Bone Marrow Transplant* 1993; **12**: 573–76.
- 65 van Kraaij MG, Dekker AW, Verdonck LF, et al. Infectious gastroenteritis: an uncommon cause of diarrhoea in adult allogeneic and autologous stem cell transplant recipients. *Bone Marrow Transplant* 2000; **26**: 299–303.
- 66 Albrecht H, Stellbrink HJ, Fenske S, Ermer M, Raedler A, Greten H. Rotavirus antigen detection in patients with HIV infection and diarrhoea. *Scand J Gastroenterol* 1993; **28**: 307–10.
- 67 Thomas PD, Pollok RC, Gazzard BG. Enteric viral infections as a cause of diarrhoea in the acquired immunodeficiency syndrome. *HIV Med* 1999; **1**: 19–24.
- 68 Hrdy DB. Epidemiology of rotaviral infection in adults. *Rev Infect Dis* 1987; **9**: 461–69.
- 69 Iturriza-Gomara M, Green J, Brown DW, Ramsay M, Desselberger U, Gray JJ. Molecular epidemiology of human group A rotavirus infections in the United Kingdom between 1995 and 1998. *J Clin Microbiol* 2000; **38**: 4394–401.
- 70 Cox MJ, Medley GF. Serological survey of anti-group A rotavirus IgM in UK adults. *Epidemiol Infect* 2003; **131**: 719–26.
- 71 Nakajima H, Nakagomi T, Kamisawa T, et al. Winter seasonality and rotavirus diarrhoea in adults. *Lancet* 2001; **357**: 1950.
- 72 Jewkes J, Larson HE, Price AB, Sanderson PJ, Davies HA. Aetiology of acute diarrhoea in adults. *Gut* 1981; **22**: 388–92.
- 73 Loosli J, Gyr K, Stalder H, Stalder GA, et al. Etiology of acute infectious diarrhea in a highly industrialized area of Switzerland. *Gastroenterology* 1985; **88**: 75–79.
- 74 Svenungsson B, Lagergren A, Ekwall E, et al. Enteropathogens in adult patients with diarrhea and healthy control subjects: a 1-year prospective study in a Swedish clinic for infectious diseases. *Clin Infect Dis* 2000; **30**: 770–78.
- 75 Echeverria P, Blacklow NR, Cukor GG, Vibulbandhikit S, Changchawalit S, Boonthai P. Rotavirus as a cause of severe gastroenteritis in adults. *J Clin Microbiol* 1983; **18**: 663–67.
- 76 de Wit MA, Koopmans MP, Kortbeek LM, van Leeuwen NJ, Vinje J, van Duynhoven YT. Etiology of gastroenteritis in sentinel general practices in the Netherlands. *Clin Infect Dis* 2001; **33**: 280–88.
- 77 Koopman JS, Monto AS. The Tecumseh Study. XV: Rotavirus infection and pathogenicity. *Am J Epidemiol* 1989; **130**: 750–9.
- 78 Pryor WM, Bye WA, Curran DH, Grohmann GS. Acute diarrhoea in adults: a prospective study. *Med J Aust* 1987; **147**: 490–93.
- 79 Oyofo BA, Subekti D, Gary GW Jr, et al. Enteropathogens associated with acute diarrhea in community and hospital patients in Jakarta, Indonesia. *FEMS Immunol Med Microbiol* 2002; **34**: 139–46.
- 80 del Refugio Gonzalez-Losa M, Polanco-Marin GG, Manzano-Cabrera L, Puerto-Solis M. Acute gastroenteritis associated with rotavirus in adults. *Arch Med Res* 2001; **32**: 164–67.
- 81 James VL, Lambden PR, Caul EO, Cooke SJ, Clarke IN. Seroepidemiology of human group C rotavirus in the UK. *J Med Virol* 1997; **52**: 86–91.
- 82 von Bonsdorff CH, Hovi T, Makela P, Morttinen A. Rotavirus infections in adults in association with acute gastroenteritis. *J Med Virol* 1978; **2**: 21–28.
- 83 Foster SO, Palmer EL, Gary GW Jr, et al. Gastroenteritis due to rotavirus in an isolated Pacific island group: an epidemic of 3,439 cases. *J Infect Dis* 1980; **141**: 32–39.
- 84 Meurman OH, Laine MJ. Rotavirus epidemic in adults. *N Engl J Med* 1977; **296**: 1298–99.
- 85 Friedman MG, Galil A, Sarov B, et al. Two sequential outbreaks of rotavirus gastroenteritis: evidence for symptomatic and asymptomatic reinfections. *J Infect Dis* 1988; **158**: 814–22.
- 86 Linhares AC, Pinheiro FP, Freitas RB, Gabbay YB, Shirley JA, Beards GM. An outbreak of rotavirus diarrhoea among a nonimmune, isolated South American Indian community. *Am J Epidemiol* 1981; **113**: 703–10.
- 87 Marrie TJ, Lee SH, Faulkner RS, Ethier J, Young CH. Rotavirus infection in a geriatric population. *Arch Intern Med* 1982; **142**: 313–16.
- 88 Cubitt WD, Holzel H. An outbreak of rotavirus infection in a long-stay ward of a geriatric hospital. *J Clin Pathol* 1980; **33**: 306–08.
- 89 Dupuis P, Beby A, Bourgoin A, Lussier-Bonneau MD, Agius G. Epidemic of viral gastroenteritis in an elderly community. *Presse Med* 1995; **24**: 356–58.
- 90 Abbas AM, Denton MD. An outbreak of rotavirus infection in a geriatric hospital. *J Hosp Infect* 1987; **9**: 76–80.
- 91 Lewis DC, Lightfoot NF, Cubitt WD, Wilson SA. Outbreaks of astrovirus type 1 and rotavirus gastroenteritis in a geriatric inpatient population. *J Hosp Infect* 1989; **14**: 9–14.
- 92 Halvorsrud J, Orstavik I. An epidemic of rotavirus-associated gastroenteritis in a nursing home for the elderly. *Scand J Infect Dis* 1980; **12**: 161–64.
- 93 Ryan MJ, Wall PG, Adak GK, Evans HS, Cowden JM. Outbreaks of infectious intestinal disease in residential institutions in England and Wales 1992–1994. *J Infect* 1997; **34**: 49–54.
- 94 Hopkins RS, Gaspard GB, Williams FP Jr, Karlin RJ, Cukor G, Blacklow NR. A community waterborne gastroenteritis outbreak: evidence for rotavirus as the agent. *Am J Public Health* 1984; **74**: 263–65.
- 95 Griffin DD, Fletcher M, Levy ME, et al. Outbreaks of adult gastroenteritis traced to a single genotype of rotavirus. *J Infect Dis* 2002; **185**: 1502–05.
- 96 Fang ZY, Ye Q, Ho MS, et al. Investigation of an outbreak of adult diarrhoea rotavirus in China. *J Infect Dis* 1989; **160**: 948–53.
- 97 Krishnan T, Sen A, Choudhury JS, Das S, Naik TN, Bhattacharya SK. Emergence of adult diarrhoea rotavirus in Calcutta, India. *Lancet* 1999; **353**: 380–81.
- 98 Steffen R, Collard F, Tornieporth N, et al. Epidemiology, etiology, and impact of traveler’s diarrhea in Jamaica. *JAMA* 1999; **281**: 811–17.
- 99 Bolivar R, Conklin RH, Vollet JJ, et al. Rotavirus in travelers’ diarrhea: study of an adult student population in Mexico. *J Infect Dis* 1978; **137**: 324–27.
- 100 Vollet JJ, Ericsson CD, Gibson G, et al. Human rotavirus in an adult population with travelers’ diarrhea and its relationship to the location of food consumption. *J Med Virol* 1979; **4**: 81–87.
- 101 Keswick BH, Blacklow NR, Cukor GC, DuPont HL, Vollet JL. Norwalk virus and rotavirus in travellers’ diarrhoea in Mexico. *Lancet* 1982; **1**: 109–10.
- 102 Ryder RW, Oquist CA, Greenberg H, et al. Travelers’ diarrhea in panamanian tourists in Mexico. *J Infect Dis* 1981; **144**: 442–48.
- 103 Sheridan JF, Aurelian L, Barbour G, Santosham M, Sack RB, Ryder RW. Traveler’s diarrhea associated with rotavirus infection: analysis of virus-specific immunoglobulin classes. *Infect Immun* 1981; **31**: 419–29.
- 104 Kim HW, Brandt CD, Kapikian AZ, et al. Human reovirus-like agent infection: occurrence in adult contacts of pediatric patients with gastroenteritis. *JAMA* 1977; **238**: 404–07.
- 105 Rodriguez WJ, Kim HW, Brandt CD, et al. Common exposure outbreak of gastroenteritis due to type 2 rotavirus with high secondary attack rate within families. *J Infect Dis* 1979; **140**: 353–57.
- 106 von Bonsdorff CH, Hovi T, Makela P, Hovi T, Tevalvoto-Aarnio M. Rotavirus associated with acute gastroenteritis in adults. *Lancet* 1976; **2**: 423.
- 107 Orstavik I, Haug KW, Sovde A. Rotavirus-associated gastroenteritis in two adults probably caused by virus reinfection. *Scand J Infect Dis* 1976; **8**: 277–78.
- 108 Yolken RH, Wilde J. Assays for detecting human rotavirus. In: Kapikian AZ, ed. *Viral infections of the gastrointestinal tract*, 2nd edn. New York: M Dekker, 1994: 251–78.
- 109 Wilde J, Yolken R, Willoughby R, Eiden J. Improved detection of rotavirus shedding by polymerase chain reaction. *Lancet* 1991; **337**: 323–26.
- 110 Rao GG. Control of outbreaks of viral diarrhoea in hospitals: a practical approach. *J Hosp Infect* 1995; **30**: 1–6.
- 111 Richardson S, Grimwood K, Gorrell R, Palombo E, Barnes G, Bishop R. Extended excretion of rotavirus after severe diarrhoea in young children. *Lancet* 1998; **351**: 1844–48.
- 112 Guarino A, Canani RB, Spagnuolo MI, Albano F, Di Benedetto L. Oral bacterial therapy reduces the duration of symptoms and of viral excretion in children with mild diarrhoea. *J Pediatr Gastroenterol Nutr* 1997; **25**: 516–19.
- 113 Shornikova AV, Casas IA, Mykkanen H, Salo E, Vesikari T. Bacteriotherapy with *Lactobacillus reuteri* in rotavirus gastroenteritis. *Pediatr Infect Dis J* 1997; **16**: 1103–07.
- 114 Desselberger U. Rotavirus infections: guidelines for treatment and prevention. *Drugs* 1999; **58**: 447–52.

- 115 Soriano-Brucher H, Avendano P, O’Ryan M, et al. Bismuth subsalicylate in the treatment of acute diarrhea in children: a clinical study. *Pediatrics* 1991; **87**: 18–27.
- 116 Guarino A, Canani RB, Russo S, et al. Oral immunoglobulins for treatment of acute rotaviral gastroenteritis. *Pediatrics* 1994; **93**: 12–16.
- 117 Losonsky GA, Johnson JP, Winkelstein JA, Yolken RH. Oral administration of human serum immunoglobulin in immunodeficient patients with viral gastroenteritis: a pharmacokinetic and functional analysis. *J Clin Invest* 1985; **76**: 2362–67.
- 118 Kanfer EJ, Abrahamson G, Taylor J, Coleman JC, Samson DM. Severe rotavirus-associated diarrhoea following bone marrow transplantation: treatment with oral immunoglobulin. *Bone Marrow Transplant* 1994; **14**: 651–52.
- 119 Ansari SA, Sattar SA, Springthorpe VS, Wells GA, Tostowaryk W. Rotavirus survival on human hands and transfer of infectious virus to animate and nonporous inanimate surfaces. *J Clin Microbiol* 1988; **26**: 1513–18.
- 120 American Academy of Pediatrics. Rotavirus infections. In: Pickering LK, ed. Red book: 2003 report of the Committee on Infectious Diseases, 26th edn. Elk Grove Village, IL: American Academy of Pediatrics, 2003: 536.
- 121 American Academy of Pediatrics. Infection control for hospitalized children. In: Pickering LK, ed. Red book: 2003 report of the Committee on Infectious Diseases, 26th edn. Elk Grove Village, IL: American Academy of Pediatrics, 2003: 150.
- 122 Sattar SA, Lloyd-Evans N, Springthorpe VS, Nair RC. Institutional outbreaks of rotavirus diarrhoea: potential role of fomites and environmental surfaces as vehicles for virus transmission. *J Hyg* 1986; **96**: 277–89.
- 123 Ward RL, Bernstein DI, Knowlton DR, et al. Prevention of surface-to-human transmission of rotaviruses by treatment with disinfectant spray. *J Clin Microbiol* 1991; **29**: 1991–96.
- 124 Joensuu J, Koskenniemi E, Pang XL, Vesikari T. Randomised placebo-controlled trial of rhesus-human reassortant rotavirus vaccine for prevention of severe rotavirus gastroenteritis. *Lancet* 1997; **350**: 1205–09.
- 125 Perez-Schael I, Guntinas MJ, Perez M, et al. Efficacy of the rhesus rotavirus-based quadrivalent vaccine in infants and young children in Venezuela. *N Engl J Med* 1997; **337**: 1181–87.
- 126 Murphy BR, Morens DM, Simonsen L, Chanock RM, La Montagne JR, Kapikian AZ. Reappraisal of the association of intussusception with the licensed live rotavirus vaccine challenges initial conclusions. *J Infect Dis* 2003; **187**: 1301–08.
- 127 Murphy TV, Smith PJ, Gargiullo PM, Schwartz B. The first rotavirus vaccine and intussusception: epidemiological studies and policy decisions. *J Infect Dis* 2003; **187**: 1309–13.

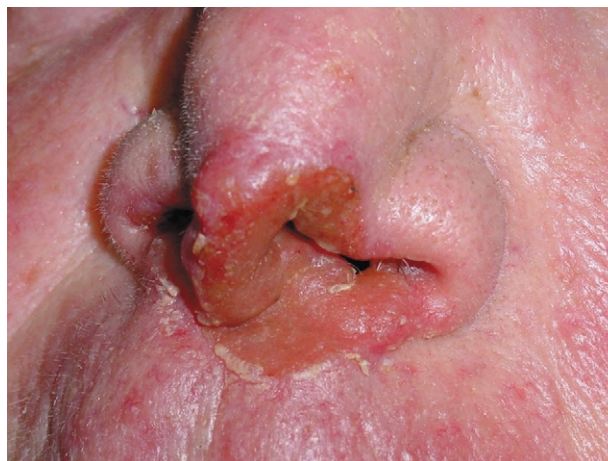Clinical picture

Nasal tuberculosis in an elderly patient

Ana María Bravo Blanco, Carmen Santos, and Quinteiros Manuel Blanco Labrador

A 73-year-old woman presented with a 2-year history of persistent ulcerous nasal injury that had progressed slowly and without fever, respiratory, or any general symptoms, until the upper lip was affected. A painless ulcero-vegetating injury was seen but the patient was otherwise normal; chest radiographs did not show abnormalities. Further examination showed soft tissue attenuation and an ulcerated mass lesion in the nasal cavity (figure). The definitive diagnosis was made by isolating *Mycobacterium tuberculosis* from tissue removed during biopsy and antituberculous therapy was started. The lesion had resolved at completion of treatment.

Tuberculosis of head and neck occurs infrequently and involvement of the nose is rare. Granulomatous lesions within the nasal cavity may represent either local disease or a manifestation of a systemic disorder and the differential diagnosis must include tuberculosis. Although almost forgotten in industrialised countries, this unusual form of tuberculosis can appear mainly in females and the elderly. It is not thought to be contagious, or to produce noticeable symptoms or physical signs.



All authors are at the Department of Internal Medicine and Otorhinolaryngology, Complejo Hospitalario de Ourense, Ourense, Spain.

Correspondence: Dr Ana María Bravo Blanco, Rúa Nuño de Ousende 13B, 32004, Ourense, Spain. Tel +34 988 240805; email anabravob@yahoo.es