

CASE REPORT

Nagoya J. Med. Sci. **81**. 165–169, 2019
doi:10.18999/nagjms.81.1.165

Lobectomy for subsegmental lymph node metastasis of unknown origin

Gaku Yamaguchi^{1,2}, Osamu Uchida¹, Shuji Ichinose¹, and Norihiko Ikeda³

¹*Department of Respiratory Surgery, Funabashi Municipal Medical Center, Chiba, Japan*

²*Department of Respiratory Surgery International University of Health and Welfare, Ichikawa Hospital, Chiba, Japan*

³*Department of Respiratory and Thyroid Surgery, Tokyo Medical University Hospital, Tokyo, Japan*

ABSTRACT

We report a very rare case of resected subsegmental lymph node metastasis of unknown origin. Hilar (N1) lymph node metastasis of unknown origin has previously been reported, but intrapulmonary lymph node metastasis has not been reported to date. At this patient's first visit to our hospital, an abnormal nodule was found on the upper lung lobe on a chest radiograph. After 4 years' follow-up, the nodule vanished, but a tiny nodule had emerged. 2-Fluoro-2-deoxy-D-glucose positron-emission tomography (FDG-PET) computed tomography was performed, and abnormal accumulation was observed only in the newly emerged intrapulmonary nodule. Right upper lobectomy was performed and a metastatic subsegmental lymph node, but no primary lesion, was found. Our observations suggest that evanescence of a suspicious primary lesion indicates the possibility of metastasis. FDG-PET was useful in this case for detecting lymph node metastases and demonstrating that the primary and further metastatic lesions were absent.

Keywords: 2-Fluoro-2-deoxy-D-glucose positron emission tomography (FDG-PET), Primary unknown cancer, Subsegmental lymph node metastasis

This is an Open Access article distributed under the Creative Commons Attribution-NonCommercial-NoDerivatives 4.0 International License. To view the details of this license, please visit (<http://creativecommons.org/licenses/by-nc-nd/4.0/>).

INTRODUCTION

Lymph node metastases are the source of most cancers with an unknown primary site. However, cancers involving subsegmental lymph node metastasis from an unknown primary site have not yet been reported. Herein, we present a case involving subsegmental lymph node metastasis from an unknown primary site as determined by 2-fluoro-2-deoxy-D-glucose positron emission tomography (FDG-PET).

A right upper lobectomy was performed because we suspected that the primary site was located on the same lobe. However, no malignancy was found in the excised tissue, except in the subsegmental lymph node. We thus assumed that the primary cancer had evanesced and that the subsegmental metastasis had emerged afterwards or that the primary cancer was too small to detect.

Received: January 30, 2018; accepted: July 25, 2018

Corresponding Author: Gaku Yamaguchi, MD, PhD

Department of Respiratory Surgery, Funabashi Municipal Medical Center, Nanasughi, Funabashi-shi 273-8588, Chiba, Japan

Tel: +81-3-3342-6111, Fax: +81-3-3345-1437, E-mail: ugaku@hotmail.com

CASE PRESENTATION

A 58-year-old man without any symptoms, and with no past history other than hypertension, was referred to our hospital for the evaluation and possible treatment of an abnormal shadow that was noted on a chest radiograph at an annual medical checkup. The patient had smoked a pack of cigarettes daily for 38 years. The abnormal shadow was present in the right upper lung lobe; chest computed tomography (CT) findings had been followed-up for the past 4 years and showed that the abnormal mass in the upper lobe was evanescent. However, a small pulmonary nodule (1.2 cm in size) had recently emerged and was gradually growing (Figure 1). Tumor markers—carcinoembryonic antigen, CYFRA 21.1, and neuron-specific enolase—were not elevated. As he had no complaints or history of infection, we suspected a malignant tumor and ordered an FDG-PET scan, which revealed abnormal accumulation ($SUV_{max} = 2.0$) of FDG only in the nodule that had recently emerged in the right upper lobe (Figure 2). Transbronchial needle aspiration cytology findings of the lung nodule from right B3, obtained using bronchoscopy, indicated adenocarcinoma. The patient was clinically diagnosed with cT1aN0M0 stage 1A primary lung cancer. Lobectomy of the right upper lobe and mediastinal lymph node dissection by complete video-assisted thoracic surgery was performed.

Pathological examination of the intrapulmonary nodule revealed a metastatic lymph node, although no other malignancies were found among the mediastinal lymph nodes (6 resected lymph nodes) and intrapulmonary lymph nodes (8 nodes), and only atelectasis was observed in the apex lung tumor (Figure 3).

Immunohistochemical studies of the resected lymph node were positive for thyroid transcription factor-1¹ and cytokeratin 7, but negative for napsin A, cytokeratin 20, and CD56. These findings suggest that the lung was the primary site of the lymph node metastasis.² The presumptive diagnosis was poorly differentiated adenocarcinoma, originating from subsegmental lymph node (node number 14) metastasis from the lung.

The patient was considered a high-risk patient because he experienced atelectasis on post-operative day 2, which did not recover, and refused any chemotherapy after the operation. The

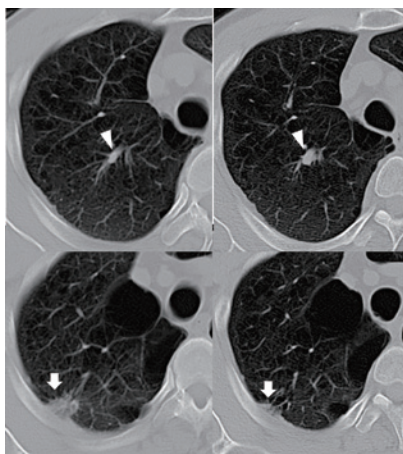


Fig. 1 Chest CT findings

Chest computed tomography scan showing an abnormal shadow in the upper lobe, which emerged over a period of 4 years (arrowheads). Additionally, the nodule in the apex of the lung evanesced (arrows). The left figures are on his first visit and right figures are on 4 years after.

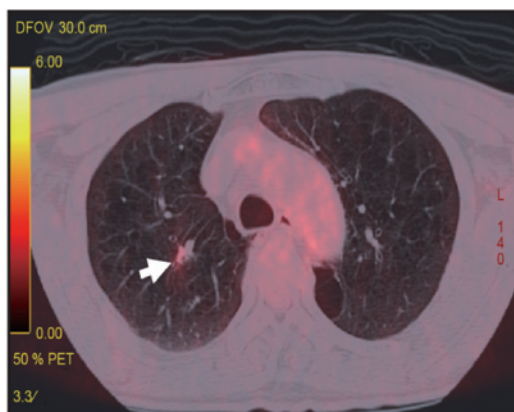


Fig. 2 FDG-PET findings

A 2-fluoro-2-deoxy-D-glucose positron emission tomography scan showing abnormal accumulation in the right upper lobe of the lung (arrow).

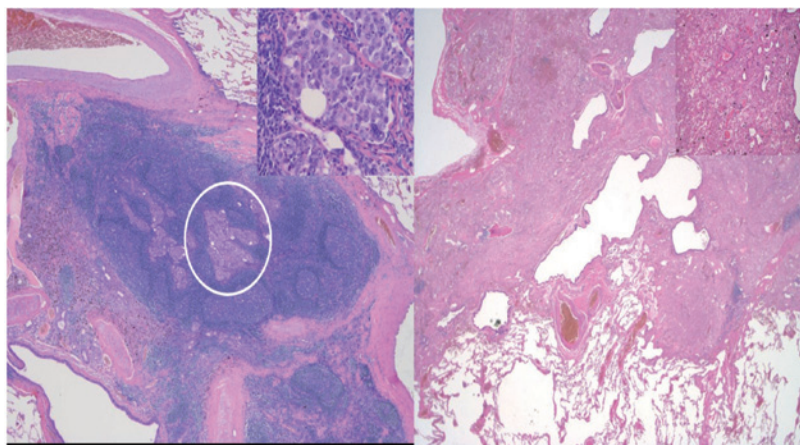


Fig. 3 Pathological findings

Pathological findings showing malignant cells in lymph node number 14 (circle) (left panel). The inset figure shows island-like growth and cancer metastasis consisting of large cells with eosinophilic cytoplasm. A possible primary lesion showed only atelectasis (right panel). Both sections are stained with hematoxylin and eosin.

follow-up examinations consisted of a monthly X-ray scan for the first year and every 3 months thereafter. We also performed a whole-body CT scan every 6 months and a brain magnetic resonance imaging every year, without administering any adjuvant therapy. The patient recovered well and showed no cancer recurrence during 60 months after the surgery. The middle lobe atelectasis did not recover, but his dyspnea recovered gradually.

The patient provided informed consent for publication of this case report, which was approved by the Ethics Committee of the Funabashi Municipal Medical Center.

DISCUSSION

Kohdono et al suggested three explanations for how the primary origin of metastatic cancers can remain undetected.³ First, the primary tumor may be too small for detection in clinical, radiological, or pathological examinations. Second, the primary tumor may have been eradicated in a previous treatment. Lastly, the primary tumor may have spontaneously disappeared because of host defense mechanisms, such as the immune system, hormone effects, trauma, and changing blood supply.^{3,4} As the patient in this case had not undergone prior treatment, we suggest that the primary site was too small to detect or had disappeared.

In the present case, the FDG-PET scan did not show significant accumulation other than in the resected lymph node, and there was no evidence of malignancy in the resected specimen containing lung tissue and other lymph node tissue. Hence, we concluded that this case had a primary unknown lung cancer and that the suspicious primary lesion had disappeared or was too small for detection.

FDG-PET is useful for detecting unknown primary lesions and metastases.⁵ To the best of our knowledge, this is the first report of an unknown primary cancer with subsegmental lymph node metastasis, although mediastinal lymph node metastasis of an unknown primary cancer has been reported previously. A TON1 lung cancer case has been reported,⁶ but in that case, the N1 was interlobar lymph node number 11, and FDG-PET was not performed. In the present case, immunohistochemical staining indicated that the probable primary site was the lung. FDG-PET helped us in that no possible primary site was identified. We therefore suggest that the tumor metastasized from the same pulmonary lobe. It should be noted that while FDG-PET is useful for clarifying indeterminate primary cancer, the primary site can be difficult to detect if the lesion is too small. Indeed, a previous study had showed that the primary carcinoma cannot be detected with FDG-PET in 25.6% of patients.⁵

Treatment of an unknown primary cancer is controversial. However, detection of the primary site is the best approach to achieve a good prognosis.⁷ Therefore, we chose to perform lobectomy in this case on the basis that the primary carcinoma was lung cancer, and the course of our patient was uneventful for 60 months after surgery, without the use of any adjuvant chemotherapy. In our case, adjuvant chemotherapy for a putative TON1 lung cancer was indicated, but the patient refused the treatment. With the increasing availability of FDG-PET technology, detection of cases such as the one described here will likely increase in the future, and deciding on the appropriate treatment plan will become a progressively more important issue.

ACKNOWLEDGEMENTS

We would like to thank Editage (www.editage.com) for their help with English language editing.

CONFLICTS OF INTERESTS

None to declare.

REFERENCES

- 1 Stenhouse G, Fyfe N, King G, et al. Thyroid transcription factor 1 in pulmonary adenocarcinoma. *J Clin*

Lobectomy for T0 lung cancer

- Pathol.* 2004;57:383–387.
- 2 Chhieng DC, Cangiarella JF, Zakowski MF, et al. Use of thyroid transcription factor 1, PE-10, and cytokeratins 7 and 20 in discriminating between primary lung carcinomas and metastatic lesions in fine-needle aspiration biopsy specimens. *Cancer.* 2001;93:330–336.
 - 3 Kohdono S, Ishida T, Fukuyama T, et al. Lymph node cancer of the mediastinal or hilar region with an unknown primary site. *J Surg Oncol.* 1995;58:196–200.
 - 4 Lopez-Pastorini A, Plönes T, Brockmann M, et al. Spontaneous regression of non-small cell lung cancer after biopsy of a mediastinal lymph node metastasis: a case report. *J Med Case Rep.* 2015;9:217.
 - 5 Yu X, Li X, Song X, et al. Advantages and disadvantages of F-18 fluorodeoxyglucose positron emission tomography/computed tomography in carcinoma of unknown primary. *Oncol Lett.* 2016;12:3785–3792.
 - 6 Izumi Y, Mukai M, Kikuchi K, et al. Long-term survival after incomplete resection of immunohistochemically diagnosed T0N1 lung cancer: report of a case. *Surg Today.* 2006;36:270–273.
 - 7 Chorost MI, Lee MC, Yeoh CB, et al. Unknown primary. *J Surg Oncol.* 2004;87:191–203.