

Catecholamine-induced Takotsubo syndrome: a case series

Nicola Campana *[†], Alessandra Gioi[†], Maria Francesca Marchetti, Martina Giusti, Simone Angius, Ludovica Caggiari, Mattia Biddau, and Roberta Montisci 

Department of Medical Sciences and Public Health, Cardiology Unit, University Hospital Duilio Casula—Azienda Ospedaliero-Universitaria di Cagliari, University of Cagliari, SS 554 4,5 km, Cagliari 09042, Italy

Received 13 December 2022; first decision 5 February 2023; accepted 22 June 2023; online publish-ahead-of-print 28 June 2023

Background

Catecholamine-induced Takotsubo Syndrome (cat-TS) is a type of secondary Takotsubo syndrome, characterized by rapid onset of symptoms, high rate of complications during the acute phase, good short-term prognosis, and frequent apical sparing at echocardiogram. We present two clinical cases of cat-TS treated in our department.

Case summary

Case one: 78-year-old man, admitted to Ear Nose and Throat Unit for surgical removal of oral squamous cellular carcinoma. During surgery, the occurrence of hypotensive episode was treated with catecholamines. After surgery, the occurrence of atrial fibrillation was followed by evidence of phasic increase of troponin levels and akinesia of midventricular segments. Angiography showed the absence of significant coronary stenoses, and during hospital stay, we observed rapid recovery of wall motion abnormalities. Case two: 64-year-old woman, admitted for hysterectomy surgery, during which cardiac arrest occurred, treated with epinephrine i.v. 1 mg and DC shock. Two hours after resuscitation, the patient developed pulmonary oedema, troponin levels increased progressively, and the echocardiogram demonstrated hypokinesia in all midventricular segments with apical sparing. Afterwards, an urgent angiography highlighted normal coronary anatomy. Cardiac magnetic resonance imaging (MRI) revealed oedema corresponding to hypokinetic areas. On the seventh day, echocardiogram showed a complete remission of wall motion abnormalities.

Discussion

These cases warn the physicians about the importance of routinely screening myocardial impairment through clinical assessment, electrocardiogram (ECG) monitoring, and serial cardiac troponin testing after catecholamine i.v. bolus administration. In case of alterations of these exams, performing a prompt echocardiogram allows early detection of cat-TS, to provide immediate suitable medical support and avoid complications.

Keywords

Takotsubo syndrome • Catecholamines • Echocardiography • Case series

ESC Curriculum

2.2 Echocardiography • 2.3 Cardiac magnetic resonance • 6.5 Cardiomyopathy

Learning points

- Catecholamine Takotsubo syndrome is characterized by rapid onset of symptoms, good short-term prognosis, and frequent apical sparing at the echocardiogram.
- After catecholamine i.v. bolus administration, in case of suspected myocardial damage, performing a prompt echocardiogram allows early diagnosis of catecholamine-induced TS.

* Corresponding author. Tel: +3487447148, Email: nicolacampana93@gmail.com

[†] The first two authors are sharing lead authorship as they contributed equally to this article.

Handling Editor: Sadaf Raza/Andreas Giannopoulos

Peer-reviewers: Deborah Cosmi; Sarandeep Kaur Marwaha

Compliance Editor: Marta Peverelli

Supplementary Material Editor: Raffaella Siang

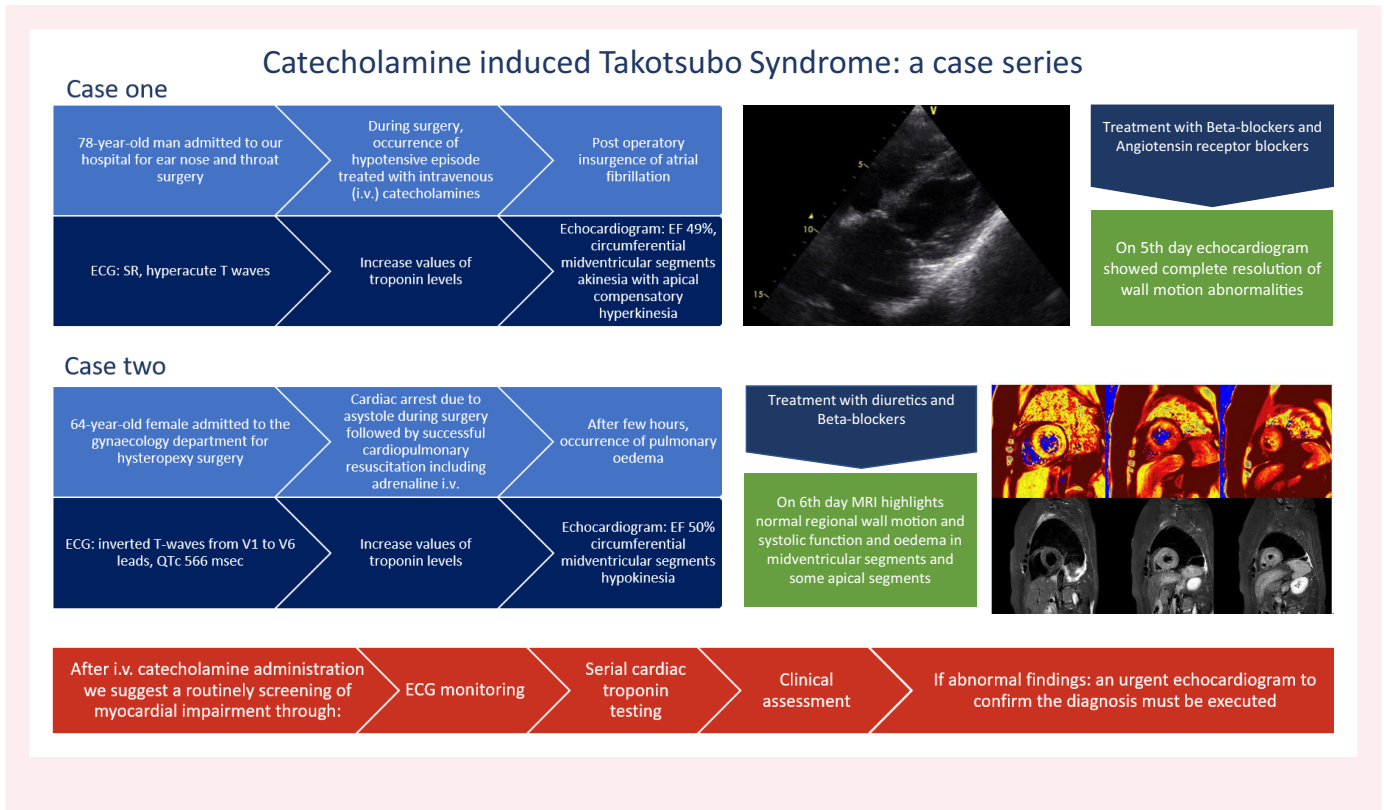
© The Author(s) 2023. Published by Oxford University Press on behalf of the European Society of Cardiology.

This is an Open Access article distributed under the terms of the Creative Commons Attribution-NonCommercial License (<https://creativecommons.org/licenses/by-nc/4.0/>), which permits non-commercial re-use, distribution, and reproduction in any medium, provided the original work is properly cited. For commercial re-use, please contact journals.permissions@oup.com

Introduction

Takotsubo syndrome (TS) is an acute and reversible form of cardiac impairment characterized by ventricular wall motion abnormalities, usually involving apical segments. Albeit clinical presentation and electrocardiogram (ECG) may vary, TS commonly mimics myocardial infarction in the absence of obstructive coronary disease to account for left ventricular (LV) systolic dysfunction.

Summary figure



TS predominantly affects women between the age of 60–70 years, 1–3% of all patients with STEMI, and 5–6% of women with a clinical context of STEMI.^{1–3}

The most frequent symptoms are chest pain, dyspnoea, and syncope, which are often related to changes in ECG findings and myocardial-cytonecrosis index levels typical of myocardial ischaemia.^{3,4}

A peculiar feature is the presence of a specific detectable trigger capable of determining TS. If the trigger is a situation of intense emotional stress, in a context of relative clinical well-being, TS is classified as primary. In secondary forms, the trigger is represented by a physical stress such as drug abuse, surgery, infection, acute neurologic syndromes, and/or metabolic disorders.⁵

Historically, TS was diagnosed on the basis of the Mayo criteria.⁶ Based on the latest knowledge and the largest international INTERTAK register, new diagnostic criteria have been identified.⁴ According to these criteria, imaging methods [echocardiogram/magnetic resonance imaging (MRI)] are used to detect ventricular dysfunction. In most cases, wall motion abnormalities selectively affect the apical ventricular segments; however, variants such as a midventricular TS or focal TS have also been described. The diagnosis of TS requires an angiographic study, which either shows the absence of

coronary lesions or identifies lesions, whose anatomical location cannot be responsible for the altered wall motion segments found on imaging exams. MRI, in addition to being useful for detecting wall motion changes, allows other causes (such as myocarditis and ischaemic events) to be excluded.

In the past, TS was considered a benign syndrome with a favourable prognosis. However, recent data suggest that the long-term prognosis of TS and acute coronary syndrome are comparable. Patients with acute complications and extensive myocardial damage have worse short- and long-term outcomes, but rapid recovery of ejection fraction (EF) does not exclude the persistence of structural changes that ad-

versely affect long-term cardiac function.^{4,7–10} New scientific evidence has shown that in-hospital mortality of secondary TS patients is higher than in primary TS patients.^{10–12}

Catecholamine-induced TS (cat-TS) is a specific secondary form of TS characterized by rapid onset of symptoms, high rate of complications during the acute phase, good short-term prognosis, and frequent apical sparing on echocardiogram.¹³

We present two cases of cat-TS related to elective surgery treated in our department between January and February 2022.

Case report 1

We studied a 78-year-old man with a history of hypertensive cardiopathy, paroxysmal atrial fibrillation (AF), and squamous cell cancer of the oral cavity, having had to undergo multiple surgeries and radiotherapy. He has been treated with nebivolol 5 mg and olmesartan/hydrochlorothiazide 10/12.5 mg, amlodipine 10 mg, and apixaban 5 mg b.i.d.

He was admitted to the Ear Nose and Throat (ENT) unit for surgical removal of a recurrence of squamous cell cancer of the oral cavity. During induction of anaesthesia, the patient developed AF with rapid

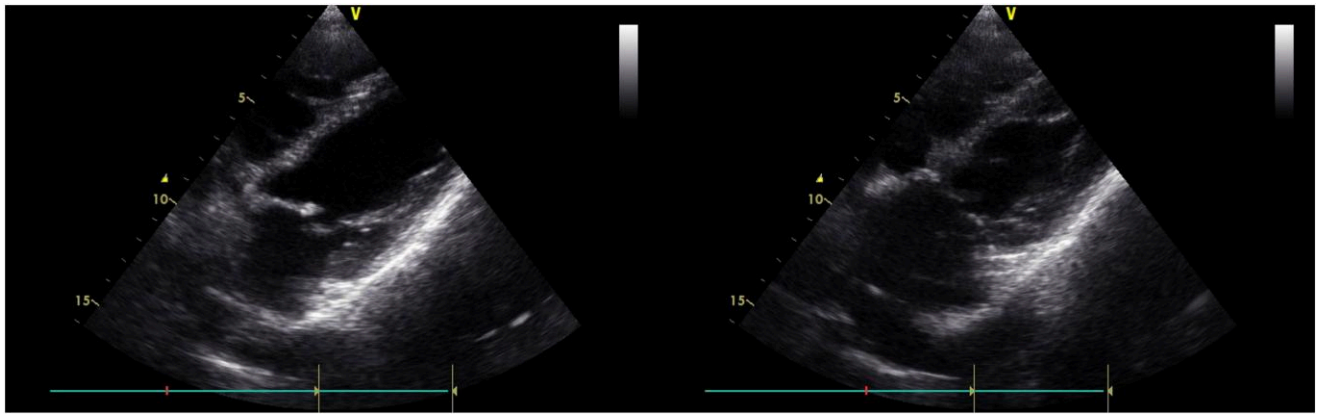


Figure 1 Transthoracic echocardiogram highlighting midventricular segments akinesia with apical compensatory hyperkinesia.

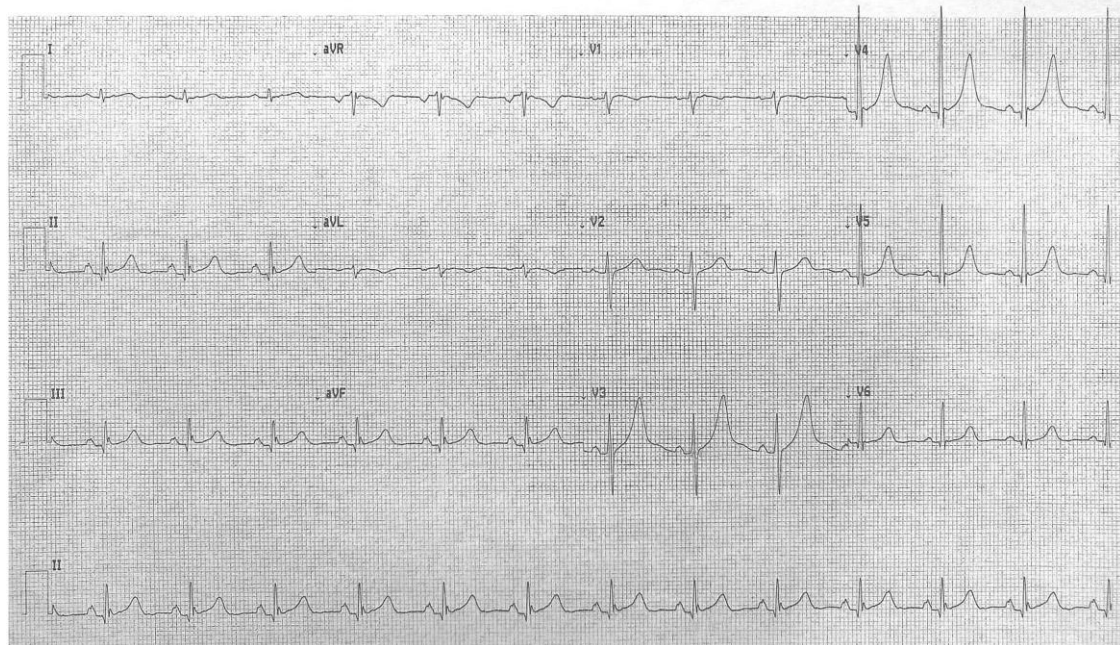


Figure 2 The ECG showed SR, HR 75/min, and hyperacute T-waves from V3 to V5.

ventricular rate, treated with metoprolol 3 mg i.v. with restoration of sinus rhythm (SR). After that, an hypotensive episode [blood pressure (BP) 95/60 mmHg] occurred, so ephedrine 17.5 mg and norepinephrine 5 mcg were administered i.v. Due to the persistence of low BP values (75/50 mmHg), i.v. bolus of adrenaline 0.3 mg was administered, which resolved the hypotensive episode (BP 130/70 mmHg), and a continuous infusion of noradrenaline 0.2 mcg/kg/min was maintained throughout the intervention. At the end of the surgery, the patient was asymptomatic, and his vital parameters were stable. Later that day, the patient had a recurrence of AF with rapid ventricular rate that was treated with i.v. amiodarone restoring SR. Serial troponin levels increased from 677 to 1503 ng/L in 4 h, and transthoracic echocardiogram revealed mildly reduced LV systolic function (EF 49%) with circumferential midventricular segment akinesia and apical

compensatory hyperkinesia in the absence of LV outflow tract (LVOT) obstruction (Figure 1). The patient was then transferred to our Cardiovascular Intensive Care Unit (CICU). He was asymptomatic, vital parameters were stable, and physical examination was normal. The ECG showed SR, heart rate (HR) 75/min, and hyperacute T-waves from V3 to V5 (Figure 2). Coronary angiography revealed normal coronary arteries, free from significant atherosclerotic lesions. Hence, diagnosis of cat-TS was assumed. During the hospital stay, the patient did not present any complications and was treated with beta-blocker therapy and angiotensin receptor blockers (ARBs). The echocardiogram performed on the fifth day observed a complete resolution of the wall motion abnormalities with normal LV systolic function (EF 61%). The patient was then transferred to the ENT unit for further treatments.

Case report 2

A 64-year-old female patient affected by hypercholesterolaemia and uterine prolapse was admitted to the gynaecology department for hysteropexy surgery. After induction of anaesthesia, at the time of pinching the uterine cervix, asystole was observed on the monitor. After two cycles of cardiopulmonary resuscitation and the administration of adrenaline 1 mg bolus i.v., a shockable rhythm was observed, and 300 J DC shock was delivered with return of spontaneous circulation (ROSC). Surgery was then interrupted, and the patient was awakened. Patient's clinical examination and vital parameters were normal, and the ECG showed SR with prolonged QTc (485 ms) and normal morphology. After 2 h, the patient developed sudden dyspnoea with oxygen saturation of 88%, dry cough, frank haemoptysis, nausea, and vomiting. Emergency chest computed tomography (CT) showed ground glass opacification extended to the upper fields and airspace consolidation. Echocardiogram revealed circumferential mid-ventricular hypokinesia with mild reduction of LV ejection fraction (EF 50%), with no evidence of LVOT obstruction. We also observed an increase in troponin levels from 307.50 ng/L to 5611.53 ng/L in 6 h. In suspicion of an acute coronary syndrome, urgent coronary angiography was performed, which did not reveal any obstructive coronary lesions, so the patient was transferred to our CICU, where diuretic therapy was administered. Blood tests showed a slight increase in CRP values with rapid and spontaneous normalization in the following days, so we attribute this finding to the inflammation resulting from recent surgery.

On the second day in our unit, ECG showed inverted T-waves from V1 to V6 leads, and further prolongation of the QTc (566 ms) (Figure 3) and chest X-ray was normal without any lung consolidation. Cardiac MRI performed on Day 3 showed normal biventricular function (LV EF 64%, RV EF 60%) without wall motion abnormalities and increased T1 and T2 relaxation times, suggestive of oedema, at midventricular segments circumferentially and at apical segments of the anterior,

inferior, and septal walls (Figures 4 and 5). The medical therapy was then optimized with bisoprolol 1.25 mg and rosuvastatin 5 mg. On the sixth day of hospitalization, the ECG was normal, and echocardiography showed full recovery of LV function (EF 66%) in the absence of regional wall motion abnormalities. Consequently, the patient was discharged the next day.

Discussion

Our case series highlights typical aspects of cat-TS. In both cases, the acute event was triggered by the intravenous administration of catecholamines during elective surgery. In contrast to classic TS, no patient was affected by psychiatric and/or neurological illnesses nor had metabolic or endocrine disorders. However, both patients may have been psychologically stressed because of the surgery,¹⁴ and in this situation, the administration of exogenous catecholamines may have triggered the TS by enhancing the effect of the endogenous catecholamines.¹⁵ In our patients, the echocardiogram showed apical sparing, in agreement with previous literature.¹⁶ The ECG findings of acute T-waves but not typical deep T-wave inversion are in line with literature, which associates these findings more frequently with the cat-TS forms.¹³ However, there were also some atypical aspects: first of all, chest pain was not the presenting symptom; additionally, none of our patients developed LV dysfunction but only wall motion abnormalities, even though the echocardiography evaluation in our patient was undertaken several hours after the onset of symptoms; therefore, we are unable to exclude the presence of a more marked cardiac dysfunction in the acute phase with a rapid recovery. In TS, a multitude of mechanisms underlying the alterations of myocardial kinetics have been described such as direct myocardial damage by catecholamines, vasospasm of the coronary microcirculation, and reduced myocardial perfusion in the course of LVOTO forms.^{17,18} In addition, Lyon et al. demonstrated that high doses of catecholamines can unexpectedly lead to a negative inotropic effect, inducing a switch in

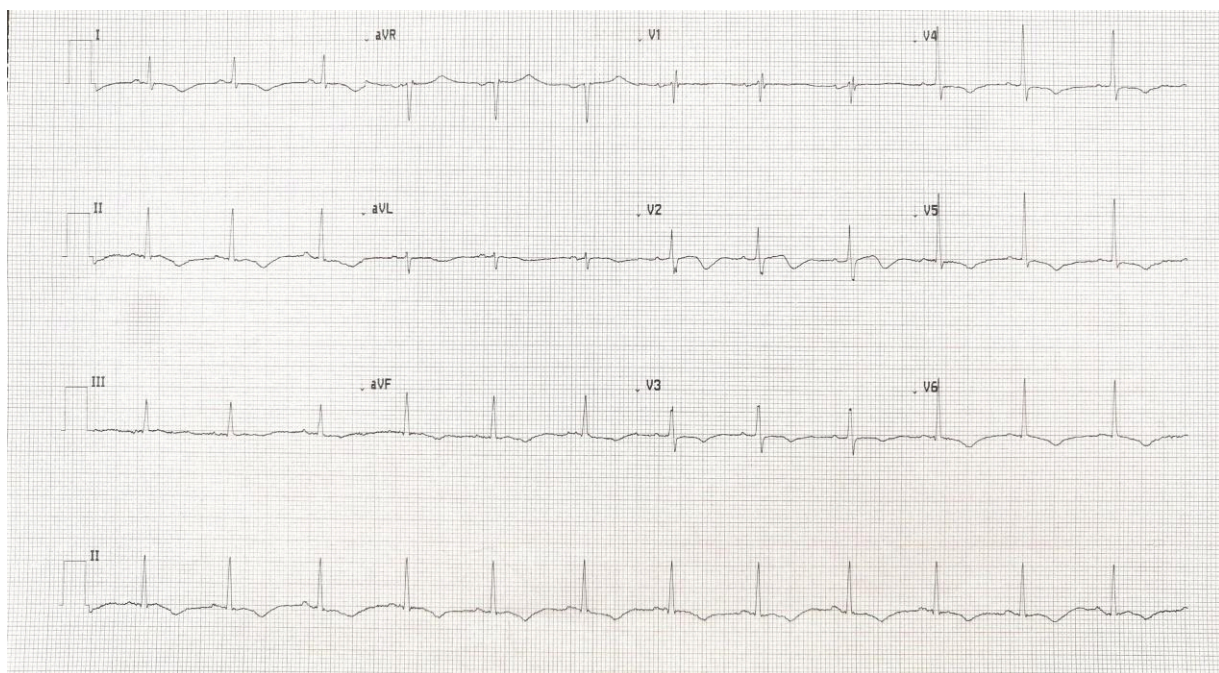


Figure 3 ECG showing inverted T-waves from V1 to V6 leads, corrected QT interval according to Bazett's formula of 566 ms.

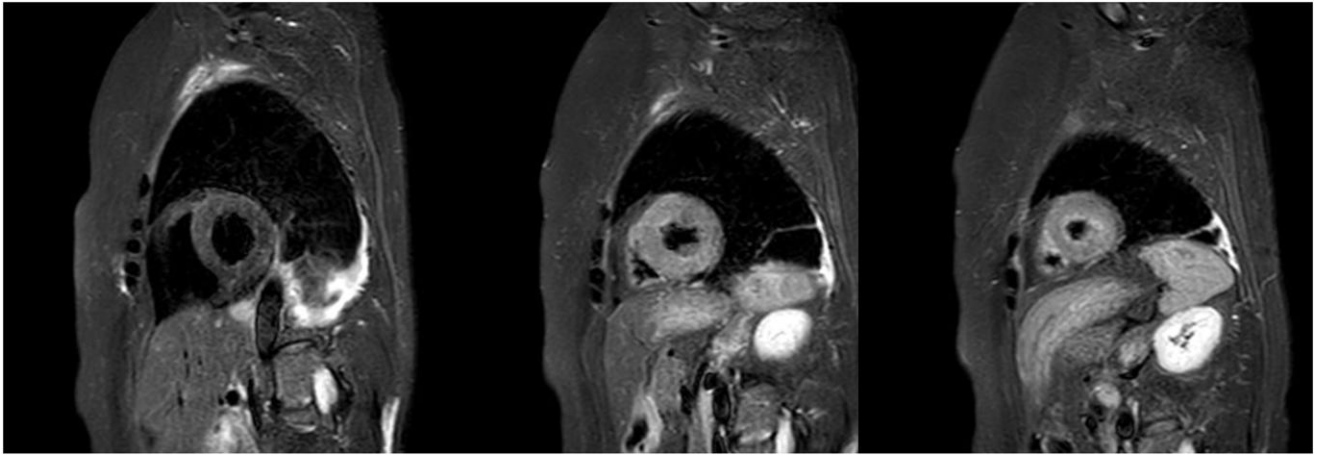


Figure 4 MRI T2 stir sequences showing hyperintensity of signal at midventricular and apical segments.

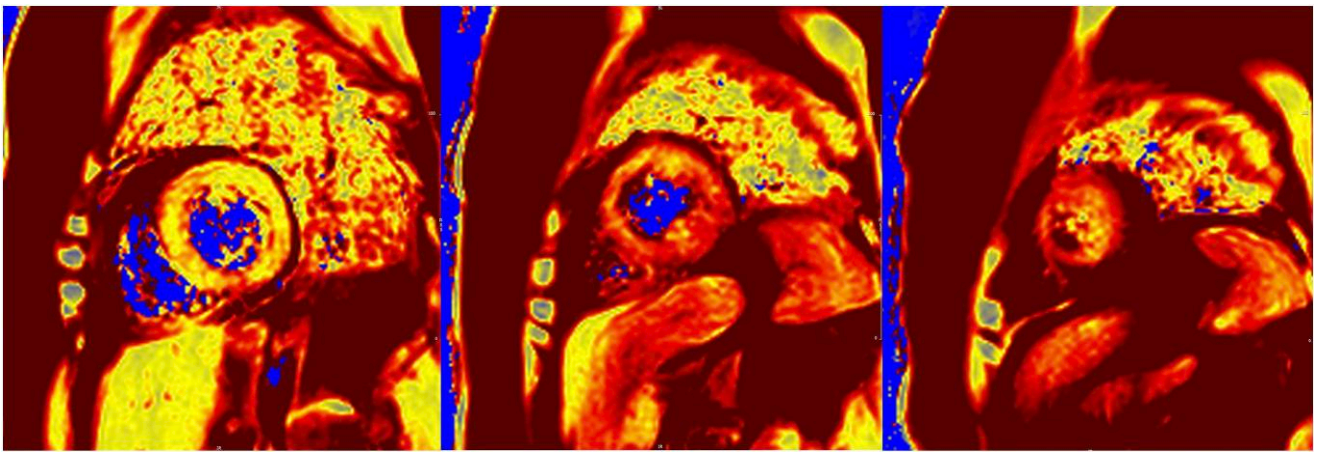


Figure 5 Prolongation of relaxation times in MRI T2 mapping sequences, compatible with oedema.

beta-2 adrenoceptor coupling from Gs protein to the Gi protein signalling pathway.¹⁹ This effect is greater at the apical myocardium, as the beta-2 receptor concentration is higher in this myocardial segment.²⁰ This theory does not explain high prevalence of apical sparing in cat-TS, so further studies regarding pathophysiology of midventricular TS are required.

In the second case, symptoms appeared rapidly following the catecholamine administration, confirming data found in a retrospective cohort study.¹³ The onset symptom was dyspnoea associated with coughing and haemoptysis, which in all probability was caused by severely increased mean arterial pressure and pulmonary backflow due to significant LV dysfunction. This hypothesis is reinforced by the reduced blood oxygen saturation values and the radiological features compatible with acute pulmonary oedema, rapidly normalized after intravenous diuretic administration without any antibiotic therapy. This finding is typical of cat-TS and can be found in recent literature.^{13,16}

Conclusion

Cat-TS is characterized by a good short-term prognosis. This can be explained by in-hospital onset of symptoms, allowing immediate medical care. However, this theory does not explain the high rate of complications during the acute phase. We hypothesize that the rapid increase in plasma epinephrine due to exogenous catecholamines administration, followed by a rapid decrease due to metabolism, may influence both the higher incidence of acute complications and the rapid resolution of the clinical impairment, leading to a better short-term prognosis. This would justify the main differences between cat-TS and classical TS, in which, in contrast, plasma catecholamine values follow a slower and more gradual rising curve that could affect clinical and instrumental findings and prognosis. Further studies focusing on in-series evaluations of catecholamine values in cat-TS and classical TS patients may provide important information to clarify the pathophysiological mechanism underlying the main differences between the two TS types.

In light of the above, it is essential that all physicians are aware of the possible occurrence of cat-TS following the administration of catecholamines, in order to provide early diagnosis and recognition of possible complications, allowing timely treatment and the achievement of a good prognosis.

Lead author biography



Dr Nicola Campana is a Cardiology Resident currently working at Policlinico Duilio Casula Hospital in Cagliari, Italy. He successfully completed his medical degree through the University of Cagliari, with additional educational experience through Karolinska Universitet in Stockholm, Sweden, and through Hospital Italiano in Buenos Aires, Argentina. He has a special interest in heart failure, arrhythmias, and echocardiography.

Supplementary material

Supplementary material is available at *European Heart Journal – Case Reports*.

Acknowledgements

Thanks to Ms Barbara Hildenbrand, Department of Cardiac Thoracic Vascular Sciences and Public Health, University of Padua, Via Giustiniani, 2, for editing in English.

Slide sets: A fully edited slide set detailing this case and suitable for local presentation is available online as [Supplementary data](#).

Consent: In accordance with the Committee on Publication Ethics (COPE) guidelines, both patients gave their informed consent, for the data related to their medical history to appear, in a completely anonymous manner, in the publication above and in related publications.

Conflict of interest: None declared.

Funding: None declared.

Data availability

The data underlying this article are available in the article and in its online [supplementary material](#).

References

1. Deshmukh A, Kumar G, Pant S, Rihal C, Murugiah K, Mehta JL. Prevalence of Takotsubo cardiomyopathy in the United States. *Am Heart J* 2012;**164**:66–71.e1.

2. Prasad A, Dangas G, Srinivasan M, Yu J, Gersh BJ, Mehran R, et al. Incidence and angiographic characteristics of patients with apical ballooning syndrome (Takotsubo/stress cardiomyopathy) in the HORIZONS-AMI trial: an analysis from a multicenter, international study of ST-elevation myocardial infarction. *Catheter Cardiovasc Interv* 2014;**83**:343–348.
3. Templin C, Ghadri JR, Diekmann J, Napp LC, Bataiosu DR, Jaguszewski M, et al. Clinical features and outcomes of Takotsubo (stress) cardiomyopathy. *N Engl J Med* 2015;**373**:929–938.
4. Ghadri JR, Wittstein IS, Prasad A, Sharkey S, Dote K, Akashi YJ, et al. International expert consensus document on Takotsubo syndrome (part I): clinical characteristics, diagnostic criteria, and pathophysiology. *Eur Heart J* 2018;**39**:2032–2046.
5. Lyon AR, Bossone E, Schneider B, Sechtem U, Citro R, Underwood SR, et al. Current state of knowledge on Takotsubo Syndrome: a position statement from the Taskforce on Takotsubo Syndrome of the Heart Failure Association of the European Society of Cardiology. *Eur J Heart Fail* 2016;**18**:8–27.
6. Madhavan M, Prasad A. Proposed Mayo Clinic criteria for the diagnosis of Tako-Tsubo cardiomyopathy and long-term prognosis. *Herz* 2010;**35**:240–243.
7. Dawson DK. Takotsubo: the myth of rapid and complete recovery. *Eur Heart J* 2018;**39**:3762–3763.
8. Ghadri JR, Wittstein IS, Prasad A, Sharkey S, Dote K, Akashi YJ, et al. International expert consensus document on Takotsubo Syndrome (part II): diagnostic workup, outcome, and management. *Eur Heart J* 2018;**39**:2047–2062.
9. Tornvall P, Collste O, Ehrenborg E, Järnbert-Petterson H. A case-control study of risk markers and mortality in Takotsubo stress cardiomyopathy. *J Am Coll Cardiol* 2016;**67**:1931–1936.
10. Brinjikji W, El-Sayed AM, Salka S. In-hospital mortality among patients with Takotsubo cardiomyopathy: a study of the national inpatient sample 2008 to 2009. *Am Heart J* 2012;**164**:215–221.
11. Sobue Y, Watanabe E, Ichikawa T, Koshikawa M, Yamamoto M, Harada M, et al. Physically triggered Takotsubo cardiomyopathy has a higher in-hospital mortality rate. *Int J Cardiol* 2017;**235**:87–93.
12. Yerasi C, Koifman E, Weissman G, Wang Z, Torguson R, Gai J, et al. Impact of triggering event in outcomes of stress-induced (Takotsubo) cardiomyopathy. *Eur Heart J Acute Cardiovasc Care* 2017;**6**:280–286.
13. Y-Hassan S. Clinical features and outcome of epinephrine-induced Takotsubo syndrome: analysis of 33 published cases. *Cardiovasc Revasc Med* 2016;**17**:450–455.
14. Sancassiani F, Carta MG, Montisci R, Preti A, Machado S, Moro MF, et al. Takotsubo syndrome is associated with mood disorders and antidepressants use, not with anxiety and impairment of quality of life due to the psychiatric disorder. *Clin Pract Epidemiol Ment Health* 2018;**14**:26–32.
15. Nazir S, Lohani S, Tachamo N, Ghimire S, Poudel DR, Donato A. Takotsubo cardiomyopathy associated with epinephrine use: a systematic review and meta-analysis. *Int J Cardiol* 2017;**229**:67–70.
16. Y-Hassan S, Falhammar H. Clinical features, complications, and outcomes of exogenous and endogenous catecholamine-triggered Takotsubo syndrome: a systematic review and meta-analysis of 156 published cases. *Clin Cardiol* 2020;**43**:459–467.
17. Pelliccia F, Sinagra G, Elliott P, Parodi G, Basso C, Camici PG. Takotsubo is not a cardiomyopathy. *Int J Cardiol* 2018;**254**:250–253.
18. Lyon AR, Rees PSC, Prasad S, Poole-Wilson PA, Harding SE. Stress (Takotsubo) cardiomyopathy—a novel pathophysiological hypothesis to explain catecholamine-induced acute myocardial stunning. *Nat Clin Pract Cardiovasc Med* 2008;**5**:22–29.
19. Paur H, Wright PT, Sikkil MB, Tranter MH, Mansfield C, O’Gara P, et al. High levels of circulating epinephrine trigger apical cardiodepression in a β_2 -adrenergic receptor/Gi-dependent manner: a new model of Takotsubo cardiomyopathy. *Circulation* 2012;**126**:697–706.
20. Kimura S, Mitsuima W, Ito M, Suzuki H, Hosaka Y, Hirayama S, et al. Inverted Takotsubo contractile pattern caused by pheochromocytoma with tall upright T-waves, but not typical deep T-wave inversion. *Int J Cardiol* 2010;**139**:e15–e17.