

## Orthosurgical Management of a Patient with Cleft Lip and Palate

### Abstract

A 31-year-old male patient reported with a chief complaint of a forwardly placed lower jaw. Oral examination revealed Angle's Class III relationship bilaterally and cephalometrically; the patient presented with a small-sized retrognathic maxilla and normal mandible. Orthosurgical treatment was carried out with 4 mm of maxillary advancement and 4 mm of mandibular setback to achieve ideal overjet, overbite, and intercuspation of teeth. The ANB angle showed a drastic change from  $-9.5^\circ$  to  $1^\circ$  and a successful conversion of the skeletal profile from Class III to Class I. Orthosurgical treatment can thus be an effective means of treating a patient with cleft lip and palate but requires a detailed understanding of the case and a sound diagnosis to attain a successful outcome.

**Keywords:** Cleft lip, orthosurgical, palates

### Introduction

Evidence shows that among the various craniofacial anomalies, cleft lip and palate (CLP) occurs most commonly affecting 1 in 700 live births. Living life with a change in appearance of one's face as a result of injury or disease is a difficult task, thus making the treatment of such patients a much more complex and sensitive issue.<sup>[1]</sup>

Patients with CLP are commonly included under the realm of Class III malocclusions. These patients often present with restricted maxillary growth, postsurgically resulting in a typical skeletal Class III malocclusion.<sup>[2]</sup> Maxillary deficiency in such patients normally occurs in all three planes, an important fact to be remembered during treatment planning.

There are different methods for advancing the hypoplastic maxilla which could be surgical such as LeFort I maxillary advancement either by itself or combined with a mandibular setback or nonsurgical approaches such as orthopedic maxillary protraction along with the use of rapid maxillary expansion. Other methods include the alternating maxillary expansion and constriction technique by Liou and Tsai, 2005, to loosen the circummaxillary sutures to aid in maxillary advancement.<sup>[3]</sup> These decisions will

This is an open access journal, and articles are distributed under the terms of the Creative Commons Attribution-NonCommercial-ShareAlike 4.0 License, which allows others to remix, tweak, and build upon the work non-commercially, as long as appropriate credit is given and the new creations are licensed under the identical terms.

For reprints contact: reprints@medknow.com

depend on the stage at which the patient is brought to orthodontist.

The management of such patients is a process that starts in infancy and continues on into adulthood. Problems in these patients are complex and therefore best managed through a team of experts which usually consists of a plastic surgeon, oral and maxillofacial surgeon, orthodontist, pediatric dentist, prosthodontist, speech therapist, psychologist, nutritionist, and a social worker to assist in the facilitation of services.<sup>[4]</sup> The following case report will illustrate the orthosurgical treatment of a patient with CLP while laying emphasis on the special precautions that were taken during the treatment.

### Case Report

Case 1: A 31-year-old male patient reported with a chief complaint of forwardly placed lower jaw. The patient had a history of CLP surgeries performed at 6 months and 1 year, 6 months.

Clinical frontal examination revealed nasal columellar distortion, cleft lip surgery scars on the left side, an increased lower facial height, competent lips, and a nonconsonant smile. At rest, the patient displayed about no incisal show with 50% incisal show on smile. At rest, lower incisors were seen.

Clinical profile examination revealed a concave profile. The patient presented

**How to cite this article:** Martires S, Kamat NV, Dhupar V. Orthosurgical management of a patient with cleft lip and palate. *Contemp Clin Dent* 2020;11:171-8.

**Sergio Martires,  
Nandini V. Kamat,  
Vikas Dhupar<sup>1</sup>**

*Departments of Orthodontics and Dentofacial Orthopaedics and <sup>1</sup>Oral and Maxillofacial Surgery, Goa Dental College and Hospital, Bambolim, Goa, India*

**Submitted :** 15-Mar-2018  
**Revised :** 23-Aug-2018  
**Accepted :** 04-Sep-2018  
**Published :** 07-Aug-2020

#### Address for correspondence:

*Dr. Sergio Martires,  
Zodiac Park, Aries Block,  
Ground Floor, Alto-Porvorim,  
Bardez - 403 202, Goa, India.  
E-mail: sergio.bds@gmail.com*

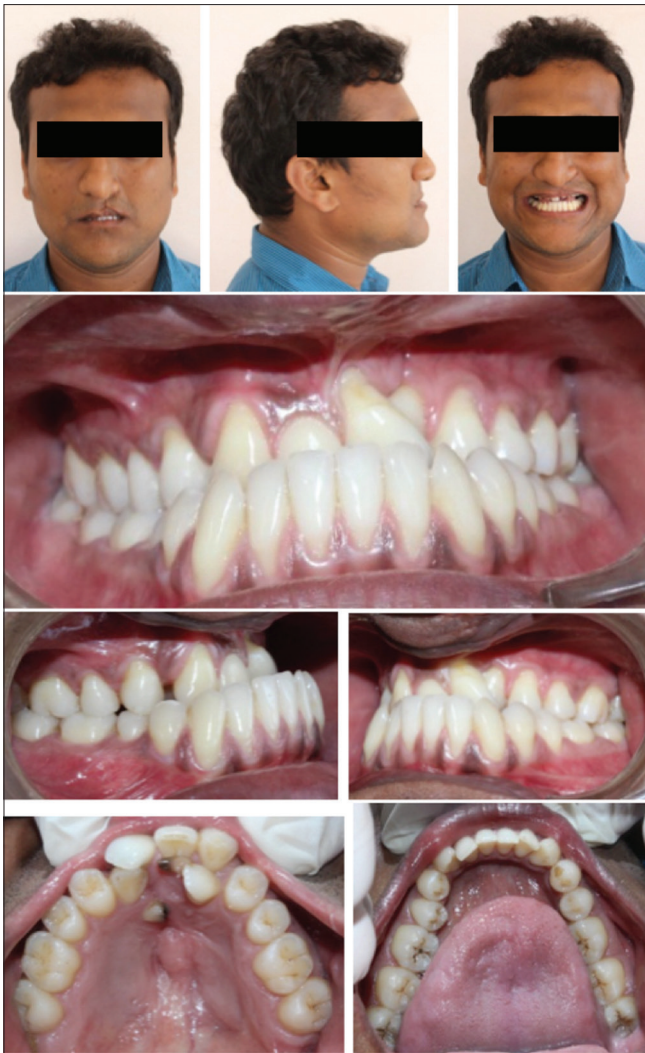#### Access this article online

**Website:**  
[www.contempclindent.org](http://www.contempclindent.org)

**DOI:** 10.4103/ccd.ccd\_200\_18

#### Quick Response Code:

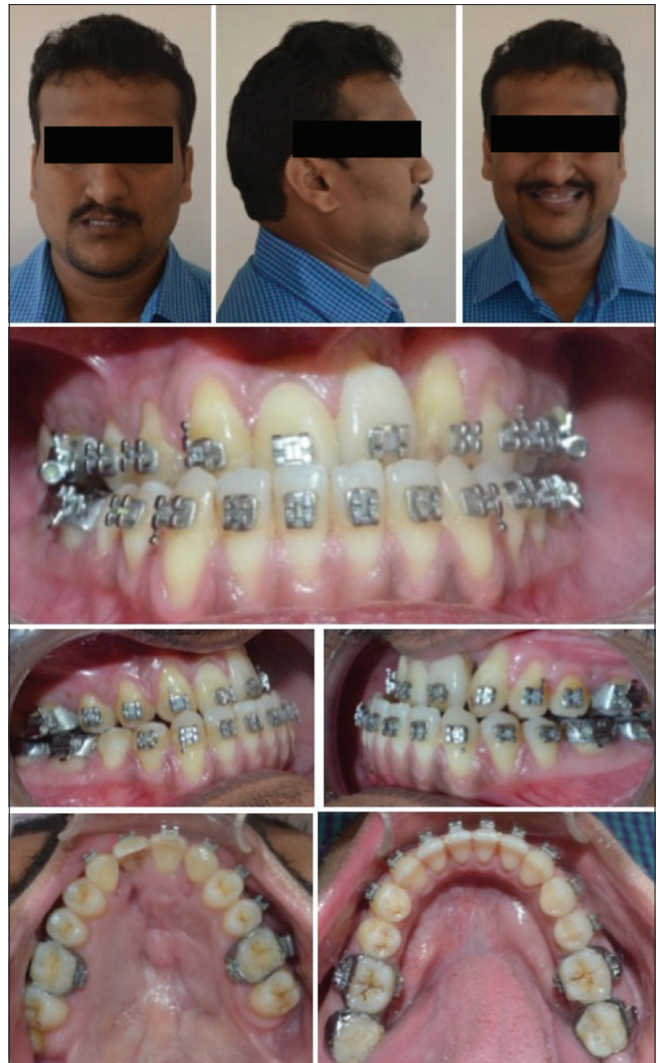



**Figure 1:** Pretreatment extraoral (frontal, profile, smiling view) and intraoral (frontal, right lateral, left lateral, maxillary and mandibular occlusal views)

with midface deficiency, flat cheekbone contour, and subpupil region. Other features seen were acute nasolabial angle, hypotonic upper lip with normal lip length, retrusive lips, positive lip step, prominent chin form, average mandibular plane angle, and increased throat length [Figure 1].

Oral examination revealed good oral health with no periodontal problems. Repaired CLP were seen on the left side with supernumerary teeth in the palate. 22 was missing in the maxillary arch, while 21 was malformed and distally tipped. 23 and 12 were palatally placed due to the constricted maxillary arch. Mild crowding was seen in the lower arch due to retroclination of the lower incisors. Anterior and posterior crossbites were seen and no open fistula was present. The maxillary arch was asymmetrical, while the mandibular arch was symmetrical. Interarch relationship showed a reverse overjet of 6 mm and a reverse overbite of 10 mm with overclosure. Maxillary dental midline was deviated to




**Figure 2:** Presurgical extraoral (frontal, profile, smiling view) and intraoral (frontal, right lateral, left lateral, maxillary and mandibular occlusal views)

the left by 2 mm. Class III molar relationships were seen bilaterally [Figure 1].

Temporomandibular joint examination revealed no centric relation–centric occlusion discrepancy with no associated pain.

Bolton’s analysis revealed 7.21-mm overall mandibular excess and 5.31-mm mandibular anterior excess.

Cephalometric examination revealed a Class III skeletal pattern with a small-sized retrognathic maxilla and a normal-sized orthognathic mandible with an average growth pattern. Maxillary and mandibular incisors were retroclined. Soft-tissue profile showed a concave profile with an acute nasolabial angle, no incisal show, and retrusive upper and lower lips. The orthopantomograph revealed no temporomandibular pathology. The diagnostic summary of this postpubertal male was skeletal Class III malocclusion with a small-sized retrognathic maxilla and a



**Figure 3:** Facial bow transfer, mock surgery, composite superimposition of SN plane at “S,” Superimposition of the mandible using Basion-Nasion plane at CC point, superimposition of the maxilla using Basion-Nasion plane at “N” point

normal-sized orthognathic mandible with an average growth pattern. Intraorally, the patient presented with Angle’s Class III malocclusion with reverse overjet, individual tooth malpositions, and supernumerary teeth. Soft-tissue examination revealed a concave profile, acute nasolabial angle, and retrusive upper and lower lips [Figure 1].

**Treatment objectives**

The objectives were to:

- Attain a pleasing profile by correcting the deficient midface and reducing the prominence of the lower jaw, thus improving facial balance and profile
- Align the arches and achieve ideal inclinations and angulations of teeth
- Substitute canine for the missing lateral incisor
- Achieve an acceptable occlusion.

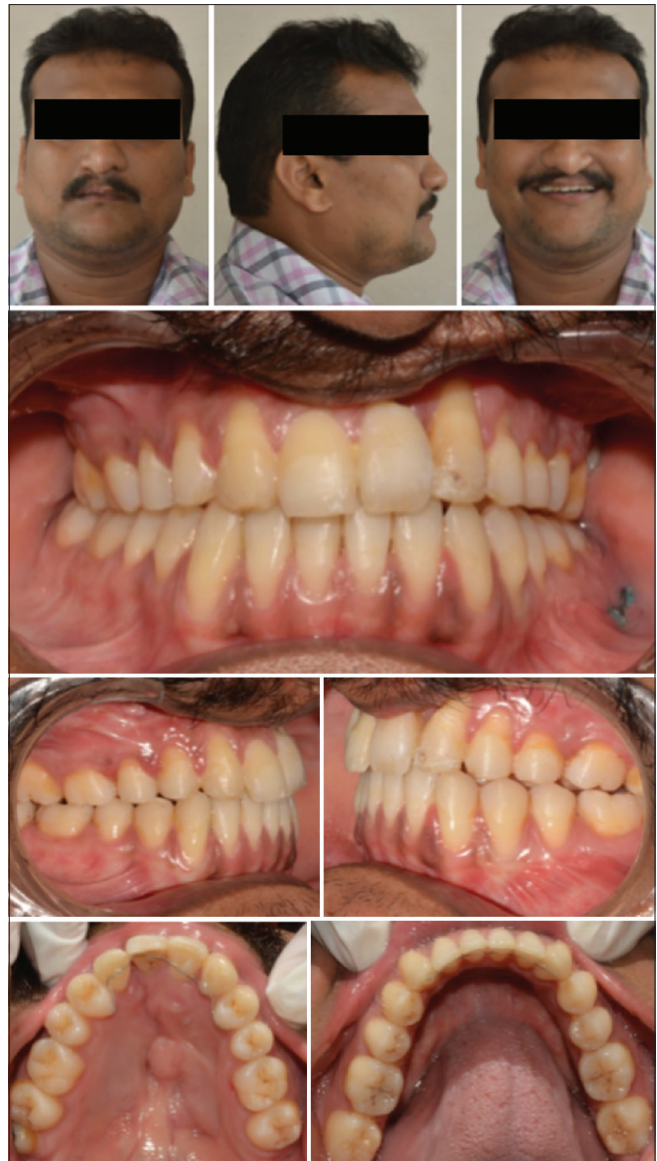**Treatment alternatives**

Considering the severity of the jaw discrepancy, camouflage treatment with solely orthodontics could not satisfactory address the problem at hand.

Orthosurgical treatment was considered as a suitable option of treatment for the patient in order to obtain the desired results both skeletally and dentally with precision.

Distraction osteogenesis was also offered as an option to the patient for a slower and slightly more protracted advancement of the maxilla while monitoring for the occurrence of hypernasal speech. However, as the patient was posted out station and could visit the clinic only at 6-week intervals, he preferred to opt for orthosurgical treatment which could be carried out at one point in time rather than over a period of time.

Like most cleft patients, the patient displayed a maxilla deficient in all the three planes of space along with mid-face deficiency. However, considering the fact that



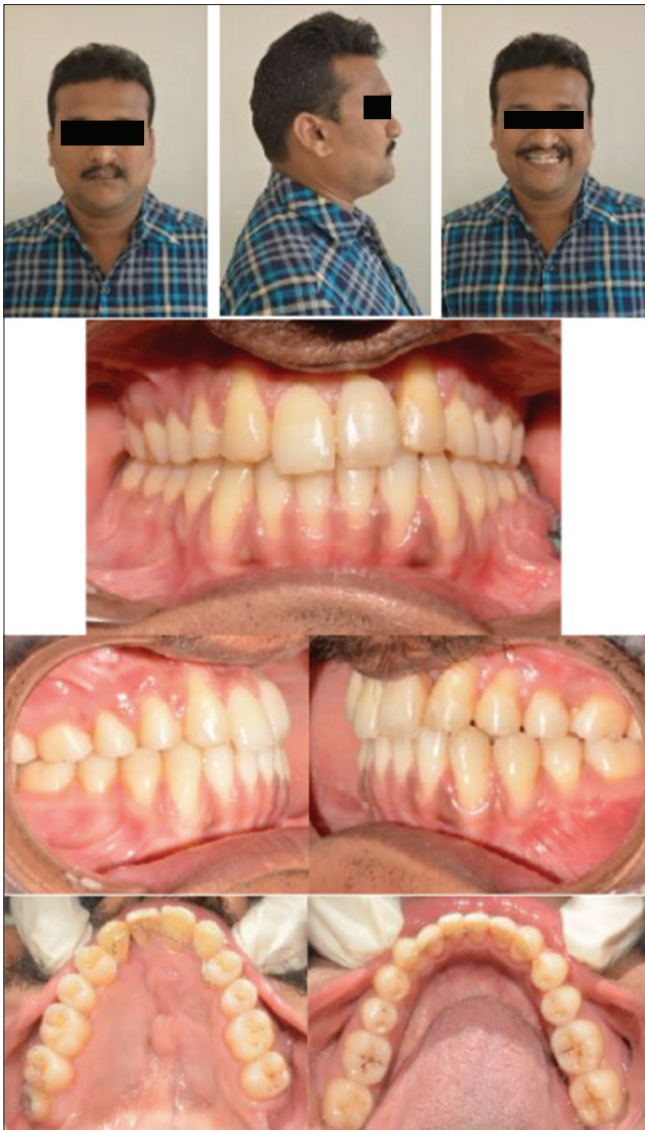**Figure 4:** Posttreatment extraoral (frontal, profile, smiling view) and intraoral (frontal, right lateral, left lateral, maxillary and mandibular occlusal views)

the velopharyngeal mechanism does not have sufficient adaptive capacity in a cleft patient and the reverse overjet achieved presurgically was 8 mm, bi-jaw surgery consisting of 4 mm of maxillary advancement and 4 mm of mandibular setback was decided as the suitable option.

**Treatment plan**

The patient in this case was classified under the index of orthognathic functional treatment need and was categorized under the Grade 5 category, i.e., very great need for treatment after fulfilling the criteria 5.1 – defects of CLP and other craniofacial abnormalities and 5.3 – reverse overjet  $\geq 3$  mm and hence required intervention by orthosurgical treatment.<sup>[5,6]</sup>

Presurgical orthodontics was carried out to align the arches and correct the inclination of the teeth in relation to their



**Figure 5:** One-year retention photographs (frontal, profile, smiling view) and intraoral (frontal, right lateral, left lateral, maxillary and mandibular occlusal views)

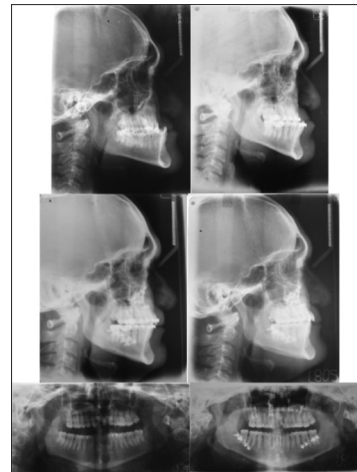
individual jaw bases. It was decided to substitute the canines for the lateral incisors in this case. Proclination of the lower anteriors was required [Figure 2].

A LeFort I osteotomy with 4-mm maxillary advancement and a mandibular setback of 4 mm by bilateral sagittal-split osteotomy were carried out, followed by a short phase of postsurgical orthodontics in order to achieve ideal interdigitation of teeth.

### Treatment progress

#### Presurgical orthodontic phase

The presurgical phase of orthodontics was initiated with 0.022" MBT preadjusted edge-wise appliance following the extraction of 12 and the supernumerary teeth. 0.016" nickel titanium was used for initial alignment including correction of rotations. 0.018" stainless steel (SS) was utilized in the



**Figure 6:** Lateral cephalograms (pretreatment, presurgical, postsurgical, and posttreatment), orthopantomograph (pretreatment and posttreatment)

maxillary arch with an open coil spring to create space for 21. This was followed by the usage of 0.020" SS wires to coordinate the dentition to their respective skeletal bases. 0.019" × 0.025" SS wires were then placed to create stabilized arches to facilitate surgical movements. These coordinated wires were left passively for 4 weeks, following which presurgical records were made [Figure 2].

Facebow transfer was done for the patient. For this surgery, intermediate and final splints were fabricated. Reference lines and cuts were decided as per the model surgery explained by Epker, Stella, and Fish [Figure 3].

### Surgical phase

During surgery, LeFort I osteotomy was used to advance the maxilla by 4 mm followed by placement of the intermediate splint. The mandible was then setback by 4 mm using bilateral sagittal-split osteotomy and was held in position with the final splint. Stabilization of the jaws was carried out using surgical plates.

### Postsurgical phase

This phase was directed at achieving final settling of the occlusion with ideal intercuspatation of the maxillary and mandibular dentitions.

### Treatment results

The treatment objectives were achieved. Marked improvement in the facial profile was seen. The reverse overjet was corrected. Class II molar relationship was achieved bilaterally. The patient was given fixed retention in the upper and lower arches [Figures 4 and 5].

Cephalometric superimpositions made evident a marked improvement in the facial profile with facial balance between the lip, nose, and chin projections. An esthetic balance between the hard and soft tissues was achieved [Figure 6].

Table 1 displays the various hard- and soft-tissue cephalometric analysis and compares the pre- and

**Table 1: Comparison of pre- and post-treatment values**

<b>Parameter</b>	<b>Pretreatment</b>	<b>Posttreatment</b>
<b>Steiners analysis</b>		
SNA (°)	69.5	78
SNB (°)	79	77
ANB (°)	-9.5	1
SN- Go Gn (mandibular plane angle) (°)	30	30
Maxillary incisor to NA (°)	27	32
Maxillary incisor to NA (mm)	9	9
Mandibular incisor to NB (°)	14	22
Mandibular incisor to NB (mm)	4	4
Interincisal angle (°)	130	129
E line to upper lip (mm)	-12	-8
E line to lower lip (mm)	-4	-9
Wits (mm)	-12.5	-1
<b>Downs analysis</b>		
FMA (mandibular plane angle) (°)	19	20
Y-axis (°)	54	55
IMPA (°)	84	93
<b>Mcnamara analysis</b>		
Nasolabial angle (°)	20	77
N perpendicular to point A (mm)	-10	-1
N perpendicular to Pog (mm)	6	3
Effective maxillary length (Co-Pt A) (mm)	90	92
Effective mandibular length (Co-Gn) (mm)	128	129
Maxillomandibular differential (mm)	38	37
Lower anterior facial height (ANS-Me) (mm)	68	71
Facial axis angle (°)	1	1
Mandibular plane angle (°)	19	20
Maxillary incisor to point A (mm)	5	8
Mandibular incisor to A -Pog (mm)	8	2
Upper pharynx (mm)	19	20
Lower pharynx (mm)	15	14
<b>COGS</b>		
B perpendicular (mandibular plane) to Pog (mm)	11	12
NB to Pog (mm)	6	7
Maxillary incisor to nasal floor (perpendicular vertical distance) (mm)	27	24
Maxillary molar to nasal floor (perpendicular vertical distance) (mm)	27	27
Mandibular incisor to mandibular plane (perpendicular vertical distance) (mm)	47	44
Mandibular molar to mandibular plane (perpendicular vertical distance) (mm)	31	33
<b>Arnett's analysis</b>		
Maxillary occlusal plane to TVL (°)	92	90
Maxillary incisor to TVL (mm)	-5	-4
Mandibular incisor to TVL (mm)	4.5	-8
Maxillary incisor to OP (°)	64	57
Mandibular incisor to OP (°)	67	64
Overjet (mm)	-6.5	3.5
Overbite (mm)	10	2
Upper lip angle (°)	49	24
Upper lip length (mm)	20	20
G-Sn-Pog (°)	213	170
Maxillary incisor to SN (inclination) (°)	97	103
<b>Functional analysis</b>		
Saddle angle (°)	127	125
Articular angle (°)	138	138

*Contd...*

Table 1: Contd...

Parameter	Pretreatment	Posttreatment
Gonial angle (°)	127	130
Jarabak's ratio (%)	64.06	64.56
Base plane angle (°)	14	16
Inclination angle (°)	77	80

COGS: Cephalometric analysis for orthognathic surgery; TVL: True vertical line; OP: Occlusal plane

post-treatment values to display the improvement that occurred skeletally as well as dentally. Arnett's analysis revealed a change in the maxillary incisor to occlusal plane from 64° to 57° and mandibular incisor to occlusal plane from 67° to 64°. These values helped ensure that a satisfactory presurgical treatment was carried out.

SNA, SNB, and ANB showed significant improvements from 69.5° to 78°, 79° to 77° and -9.5° to 1°, respectively. Eastman correction was carried out for the ANB angle. The ANB and SNA pretreatment angle values were found to be -9.5° and 69.5°, respectively. The SN-maxillary plane angle was found to be 8°. Hence, the correction was applied such that for every degree that the SNA angle was <81°, 0.5° was added to the value resulting in an ANB value of -15°.

## Discussion

In most cases of severe skeletal Class III malocclusion, orthosurgical treatment becomes a must not only to achieve ideal occlusion, but also to provide the patient with ideal esthetics and facial harmony.

It is seen that surgery has a deep psychological impact on the patient which helps his/her interactions in the society.<sup>[1]</sup> Changes in the profile following surgery may be quite dramatic and may benefit the patient immensely by improving his/her self-esteem. Diagnosis should be specific and reveal if the problems are related to mandibular prognathism, maxillary retrognathism, or a combination of both.<sup>[7,8]</sup> These complex cases require careful treatment planning with an integrated approach and tremendous patient cooperation. Therefore, accurate diagnosis and treatment planning becomes crucial to the treatment of such malocclusions.<sup>[9]</sup>

There exists a paradigm shift in diagnosis with treatment no longer being occlusion centric but more emphasis being laid on soft tissues with analysis in all the three planes of space. Clinical facial and dental planning is now used as a sophisticated tool in accurately diagnosing a case.<sup>[10-13]</sup> In such patients with CLP, the maxilla is generally deficient in all the three planes of space. This could be as a result of the original embryologic defect of the oral, palatal, and/or pharyngeal tissues or as a result of lip-and-palate repairs during infancy.<sup>[14,15]</sup>

Various longitudinal studies have confirmed that the growth of the maxilla was affected negatively in patients who had hard palatal closures.<sup>[3]</sup>

In the absence of anteroposterior and vertical maxillary growth, normal mandibular growth can produce a significant jaw discrepancy. The absence of vertical maxillary growth leads to the forward projection of the mandibular growth with anterior and superior rotation resulting in overclosure.<sup>[16]</sup> Patients with CLP also present with other defects which may be a concern from a dental standpoint such as posterior crossbites (quadrant or single tooth), maxillary incisor rotations, retroclined or lingually positioned incisors, excessive spacing for the lateral incisor for the cleft region, midline deviations, and arch asymmetries.<sup>[17]</sup> Therefore, unlike decompensation in other skeletal Class III patients, anterior dental decompensation is not the major presurgical goal as excessive proclination of the maxillary anteriors is restricted by the presence of scar tissue from previous surgeries carried out on these patients. Extractions, if any, are carried out to eliminate overretained and supernumerary teeth like in this case and all the above-mentioned problems must be addressed in the presurgical phase.<sup>[16]</sup>

Following the presurgical phase, the patient may be posted for surgery as long as all permanent teeth have erupted, the maxillary and mandibular arches are orthodontically coordinated, and the complete maxillofacial growth is attained.<sup>[18]</sup> This can be best assessed using serial lateral cephalographs. The only exception in which surgery may be done earlier is if psychosocial implications exist.

In CLP patients, the most common surgery performed is maxillary advancement. This may be associated with benefits such as better articulation of certain sounds due to the establishment of maxillomandibular equilibrium as well as improved breathing due to increased nasopharyngeal space. However, ill effects such velopharyngeal insufficiency are also associated with anterior movement of the soft palate.<sup>[19,20]</sup>

Due to the probable lower adaptive capacity of the velopharyngeal mechanism in this patient, it was decided to carry out a bi-jaw surgery of 4-mm maxillary advancement with LeFort I osteotomy and 4-mm mandibular setback with bilateral sagittal-split osteotomy. At the end of presurgical treatment, the patient displayed a reverse overjet of 8 mm. There exists evidence in literature that suggests that in cases with a reverse overjet of 8 mm or more, performing a bi-jaw surgery is advisable even in cases where the mandible is orthognathic.<sup>[14]</sup> Saelen *et al.* reported that in patients with CLP requiring a maxillary advancement of more than 6 mm, simultaneous maxillary

advancement and mandibular setback could be carried out as a treatment of choice.<sup>[21]</sup>

Chanchareonsook *et al.* have reviewed 39 studies and 750 case reports to assess the effect of maxillary advancement on speech. Results revealed 12 studies with no deterioration, 15 studies with deterioration of velopharyngeal status and resonance, and 5 studies which showed only deterioration in cases in which pretreatment velar insufficiency was present. The results of this study reinforced our decision to perform a bi-jaw surgery.<sup>[22]</sup>

Residual scar tissue from previous surgeries may also restrict the amount of maxillary advancement and this has to be taken into account when the treatment plan is being decided. A moderate amount of overcorrection of up to 2 mm is advised in such cases in order to counter the problem of scar tissue-related relapse. However, in our case, no overcorrections were carried out, but the results were stable.<sup>[16]</sup> Distraction osteogenesis was also presented as an alternative to the patient. Some of the advantages cited in literature for this modality are a more gentle skeletal advancement without downfracture of the maxilla and the ability to monitor hypernasal speech while advancing the maxilla.<sup>[4]</sup>

However, studies conducted by Ladeira *et al.* and Chanchareonsook *et al.* to compare the effects of LeFort I versus distraction osteogenesis on velopharyngeal insufficiency show no significant differences between the two groups.<sup>[23]</sup> Chua *et al.* conducted a study to assess the effects of orthognathic surgery and distraction osteogenesis on speech and velopharyngeal function and found no significant differences between the two groups.<sup>[24]</sup> Considering the above-mentioned factors, it is important that all patients undergoing procedures such as maxillary advancement should have a detailed examination of speech and velopharyngeal function pre- and post-operatively. This should include medical and speech history, subjective impression of nasality, articulation analysis, nasal airflow studies, neuromotor assessment of speech mechanism, and radiologic evaluation of velopharyngeal mechanism.<sup>[25]</sup> This ensures ideal results without compromising the speech and articulation of the patient.

Treatment outcomes and stability have been repeatedly compared between distraction osteogenesis and orthognathic surgery. There are several factors which contribute to the increased possibility of relapse in CLP patients which include larger amount of advancement to attain a normal dimension, more marked maxillary deficiency and occlusal changes, anatomic variations, more complicated orthodontic treatment, as well as scarring from previous surgeries.<sup>[26]</sup> Cheung *et al.* and Chua *et al.* found that distraction osteogenesis was more stable in the long run, with orthognathic surgery showing a relapse in an upward and backward direction, while Baek *et al.* have found that although the amount of maxillary advancement that could be carried out in distraction osteogenesis was

higher, the amount of anteroposterior relapse seen was almost the same in both groups.<sup>[27-29]</sup> Occlusal disharmony is an important cause of relapse, especially in CLP patients.<sup>[28]</sup> In the current case, a decent stable occlusion was achieved posttreatment which would help prevent relapse. Studies have proven that despite skeletal relapse, results may still hold good especially in cases where sufficient dental compensation has been achieved. This could be assessed cephalometrically.<sup>[26]</sup>

Age is an important consideration while deciding between the two procedures. In younger patients, in whom further mandibular growth is still present, distraction osteogenesis can be considered. If orthognathic surgery is performed prior to growth completion, relapse can occur from further mandibular growth.<sup>[29,30]</sup> As this was an adult patient who lived elsewhere and visited the clinic every 2 months, we considered orthognathic surgery as a more suitable option and performed a bi-jaw surgery.

Postoperative care is almost similar in both procedures; however, distraction osteogenesis would require a second surgery to remove the distractors. Postsurgical complications may occur in either of the procedures and utmost care must be taken to avoid them.<sup>[30]</sup>

The above-mentioned factors should be considered in order to achieve successful long-term treatment results.

## Conclusion

The selection of the ideal treatment for a patient with a CLP is dependent on a number of factors such as the amount of surgical advancement needed, the severity of discrepancy, impact on speech, relapse/stability relationships, esthetic outcome, and consideration of possible complications. This necessitates the close coordination of all the members on the CLP team in order for the treatment to be successful.

## Declaration of patient consent

The authors certify that they have obtained all appropriate patient consent forms. In the form the patient(s) has/have given his/her/their consent for his/her/their images and other clinical information to be reported in the journal. The patients understand that their names and initials will not be published and due efforts will be made to conceal their identity, but anonymity cannot be guaranteed.

## Financial support and sponsorship

Nil.

## Conflicts of interest

There are no conflicts of interest.

## References

1. Sousa AD, Devare S, Ghanshani J. Psychological issues in cleft lip and cleft palate. *J Indian Assoc Pediatr Surg* 2009;14:55-8.
2. Thornton JB, Nimer S, Howard PS. The incidence, classification,

- etiology, and embryology of oral clefts. *Semin Orthod* 1996;2:162-8.
3. Borzabadi-Farahani A, Lane CJ, Yen SL. Late maxillary protraction in patients with unilateral cleft lip and palate: A retrospective study. *Cleft Palate Craniofac J* 2014;51:e1-10.
  4. Takigawa Y, Uematsu S, Takada K. Maxillary advancement using distraction osteogenesis with intraoral device. *Angle Orthod* 2010;80:1165-75.
  5. Ireland AJ, Cunningham SJ, Petrie A, Cobourne MT, Acharya P, Sandy JR, *et al.* An index of orthognathic functional treatment need (IOFTN). *J Orthod* 2014;41:77-83.
  6. Borzabadi-Farahani A, Eslamipour F, Shahmoradi M. Functional needs of subjects with dentofacial deformities: A study using the index of orthognathic functional treatment need (IOFTN). *J Plast Reconstr Aesthet Surg* 2016;69:796-801.
  7. Vig KD, Ellis E 3<sup>rd</sup>. Diagnosis and treatment planning for the surgical-orthodontic patient. *Dent Clin North Am* 1990;34:361-84.
  8. Sinclair PM. Orthodontic considerations in adult surgical orthodontic cases. *Dent Clin North Am* 1988;32:509-28.
  9. Mendiratta A, Mesquita AM, Kamat NV, Dhupar V. Orthosurgical management of a severe class III malocclusion. *J Indian Orthod Soc* 2014;48:273-9.
  10. Arnett GW, McLaughlin R, editors. Facial treatment planning. In: *Facial and Dental Planning for Orthodontists and Oral Surgeons*. 1<sup>st</sup> ed. London: Mosby; 2004. p. 223-36.
  11. Arnett GW, Bergman RT. Facial keys to orthodontic diagnosis and treatment planning. Part I. *Am J Orthod Dentofacial Orthop* 1993;103:299-312.
  12. Arnett GW, Bergman RT. Facial keys to orthodontic diagnosis and treatment planning – Part II. *Am J Orthod Dentofacial Orthop* 1993;103:395-411.
  13. Arnett GW, Jelic JS, Kim J, Cummings DR, Beress A, Worley CM Jr., *et al.* Soft tissue cephalometric analysis: Diagnosis and treatment planning of dentofacial deformity. *Am J Orthod Dentofacial Orthop* 1999;116:239-53.
  14. Adlam DM, Yau CK, Banks P. A retrospective study of the stability of midface osteotomies in cleft lip and palate patients. *Br J Oral Maxillofac Surg* 1989;27:265-76.
  15. Ewing M, Ross RB. Soft tissue response to orthognathic surgery in persons with unilateral cleft lip and palate. *Cleft Palate Craniofac J* 1993;30:320-7.
  16. Bailey LT, Sarver D, Turvey T. Class III problems. In: *Proffit W, White R, Sarver D, editors. Contemporary Treatment of Dentofacial Deformity*. 1<sup>st</sup> ed. St. Louis: Mosby; 2003. p. 543-55.
  17. Long RE Jr, Semb G, Shaw W. Orthodontic treatment of the patient with complete clefts of lip, alveolus and palate: Lessons of the past 60 years. *Cleft Palate Craniofac J* 2000;37:533.
  18. Posnick JC, Ricalde P. Cleft-orthognathic surgery. *Clin Plast Surg* 2004;31:315-30.
  19. Altug-Atac AT, Bolatoglu H, Memikoglu UT. Facial soft tissue profile following bimaxillary orthognathic surgery. *Angle Orthod* 2008;78:50-7.
  20. Kamat NV. Team management of a young adult with a traumatic cleft repair. *J Indian Orthod Soc* 2011;45:140-6.
  21. Saelen R, Tornes K, Halse A. Stability after LeFort I osteotomy in cleft lip and palate patients. *Int J Adult Orthodon Orthognath Surg* 1998;13:317-23.
  22. Chanchareonsook N, Samman N, Whitehill TL. The effect of cranio-maxillofacial osteotomies and distraction osteogenesis on speech and velopharyngeal status: A critical review. *Cleft Palate Craniofac J* 2006;43:477-87.
  23. Chanchareonsook N, Whitehill TL, Samman N. Speech outcome and velopharyngeal function in cleft palate: Comparison of LeFort I maxillary osteotomy and distraction osteogenesis – Early results. *Cleft Palate Craniofac J* 2007;44:23-32.
  24. Chua HD, Whitehill TL, Samman N, Cheung LK. Maxillary distraction versus orthognathic surgery in cleft lip and palate patients: Effects on speech and velopharyngeal function. *Int J Oral Maxillofac Surg* 2010;39:633-40.
  25. Witzel MA, Munro IR. Velopharyngeal insufficiency after maxillary advancement. *Cleft Palate J* 1977;14:176-80.
  26. Hochban W, Ganss C, Austermann KH. Long-term results after maxillary advancement in patients with clefts. *Cleft Palate Craniofac J* 1993;30:237-43.
  27. Cheung LK, Chua HD, Hägg MB. Cleft maxillary distraction versus orthognathic surgery: Clinical morbidities and surgical relapse. *Plast Reconstr Surg* 2006;118:996-1008.
  28. Chua HD, Hägg MB, Cheung LK. Cleft maxillary distraction versus orthognathic surgery – Which one is more stable in 5 years? *Oral Surg Oral Med Oral Pathol Oral Radiol Endod* 2010;109:803-14.
  29. Baek SH, Lee JK, Lee JH, Kim MJ, Kim JR. Comparison of treatment outcome and stability between distraction osteogenesis and LeFort I osteotomy in cleft patients with maxillary hypoplasia. *J Craniofac Surg* 2007;18:1209-15.
  30. Cheung LK, Chua HD. A meta-analysis of cleft maxillary osteotomy and distraction osteogenesis. *Int J Oral Maxillofac Surg* 2006;35:14-24.