

Comprehensive Treatment and Reconstructive Algorithm for Functional Restoration after Ballistic Facial Injury

Kongkrit Chaiyasate, MD, FACS*†

Rohun Gupta, BA*

Elizabeth M. Boudiab, MD‡

Daniella Vega, MD†

Justin Hart, DO†

Farid Nossoni, DO†

Stephen Lu, MD§

Jeremy M. Powers, MD¶

Gregory Hobson, DO||

Neil S. Sachanandani, MD*†

Background: Ballistic facial injuries are rare, with most trauma centers reporting 1–20 cases annually. These patients present significant management challenges to reconstructive surgeons, not only due to their rarity but also due to the complex decision-making process that is involved. The aim of this study was to review our experience with the application of craniofacial microsurgery in management of facial gunshot wounds.

Methods: A retrospective review of a single-surgeon experience at a level I trauma center from 2011 to 2020 for patients sustaining self-inflicted gunshot wounds to the face requiring microsurgical reconstruction was performed. Outcomes included reconstructive techniques, free flap type and indication, airway evolution, feeding modality, respective timing of interventions, and complications.

Results: Between 2012 and 2021, 13 patients presented for microsurgical reconstruction at our institution for gunshot wounds to the face. The majority (90%) of patients were men, and the average age at time of injury was 26. The median from the time of injury to first free flap was 93 days. Thirteen patients represented 23 free flaps. On average, patients underwent a total of two free flaps. The most common microsurgical flap was the fibula flap (14) followed by the radial forearm flap (6).

Conclusions: Based on our findings, we describe a novel algorithm for function restoration and aesthetic revisions based on injury location. Underlying principles include avoiding early use of reconstruction plates, establishing occlusion early, and aligning bony segments using external fixation. An algorithmic approach to these injuries can improve outcomes. (*Plast Reconstr Surg Glob Open* 2022;10:e4453; doi: 10.1097/GOX.0000000000004453; Published online 27 July 2022.)

INTRODUCTION

Firearm-related injury, self-inflicted or otherwise, affects over 99,000 individuals per year in the United States.¹ Of these, 67,000 survive and are medically evaluated. Twenty-one percent of these patients sustain injuries involving the head or neck and 9% of this subset present

with facial injuries.^{1,2} The rarity of this patient presentation has been frequently discussed in the literature.^{3–6} In one multi-institutional study, eight participating trauma centers averaged between one and 20 patients per year with a postpresentation mortality rate of 26%.⁷ Although these patients' injuries represent a minority of gunshot wounds (GSWs), their complicated needs require a unique multidisciplinary approach that takes a profound toll on involved health care systems, with costs averaging greater than \$100,000 per patient.² Due to the complex series of critical management decisions made while caring for these individuals, an algorithmic approach to their care may provide a level of standardization needed to attain the best outcome in these rare cases.

Historically, surgical management has relied on delayed definitive reconstruction by using serial debridement and local tissue advancement flaps. Today, there is a trend toward an earlier approach to reconstruction.⁴ Although existing literature supports immediate debridement and skeletal fixation following blast firearm injuries, the timing and sequence of craniofacial skeletal

From the *Oakland University William Beaumont School of Medicine, Auburn Hills, Mich.; †Department of Plastic Surgery, Beaumont Health Sciences, Royal Oak, Mich.; ‡Department of General Surgery, Beaumont Health Sciences, Royal Oak, Mich.; §Department of Plastic Surgery, University of Pittsburgh Medical Center, Pittsburgh, Pa.; ¶Department of Plastic Surgery, East Tennessee State University, Johnson City, Tenn.; and ||Department of Plastic Surgery, University of Utah, Salt Lake City, Utah.

Received for publication April 9, 2022; accepted June 3, 2022.

Copyright © 2022 The Authors. Published by Wolters Kluwer Health, Inc. on behalf of The American Society of Plastic Surgeons. This is an open-access article distributed under the terms of the [Creative Commons Attribution-Non Commercial-No Derivatives License 4.0 \(CCBY-NC-ND\)](#), where it is permissible to download and share the work provided it is properly cited. The work cannot be changed in any way or used commercially without permission from the journal.

DOI: 10.1097/GOX.0000000000004453

Disclosure: The authors have no financial interest to declare in relation to the content of this article.

reconstruction remain controversial.^{3-6,8-10} With the evolution of microsurgical techniques, free tissue transfers have become more common in the reconstruction of these complex injuries. However, the ideal technique and timing to minimize complications, optimize restoration of function, and achieve the best aesthetic outcomes are also unclear in this group of patients.^{4,10}

The aim of this study was to review our institutional experience with the application of craniofacial microsurgery to the management of blast injuries sustained from facial GSWs and delineate a comprehensive algorithmic approach to the treatment and reconstruction of these complex injuries.

METHODS

A retrospective review of a single surgeon's experience at a level I trauma center from 2011 to 2021 was performed for all patients sustaining ballistic facial trauma involving composite craniofacial defects. Only patients who underwent aesthetic microsurgical osseous and soft tissue reconstruction were included. The study design was approved by the institutional review board, and individual patient consent was obtained. Outcomes of interest for all patients included demographics, facial injuries and

Takeaways

Question: What is the appropriate approach and timing of reconstruction after ballistic injury to the face?

Findings: An algorithm composed of avoiding the use of early reconstruction plates, establishing early occlusion, and aligning bony segments through external fixation can improve outcomes.

Meaning: Aggressive early reduction of the fracture and reestablishment of the facial buttress followed by delayed free flap reconstruction is the preferred method of facial reconstruction.

associated defects, injury severity, timing and description of initial debridement and bony stabilization, free flap reconstructive technique and timing, postoperative complications, flap failure rates, number of revision procedures, and length of follow-up.

Charts were also reviewed to analyze the interplay of airway evolution, feeding, and additional reconstructive techniques. Timing of debridement and reconstruction was adapted from definitions proposed in a recent review by Vaca et al.⁴ Debridement was defined as immediate if

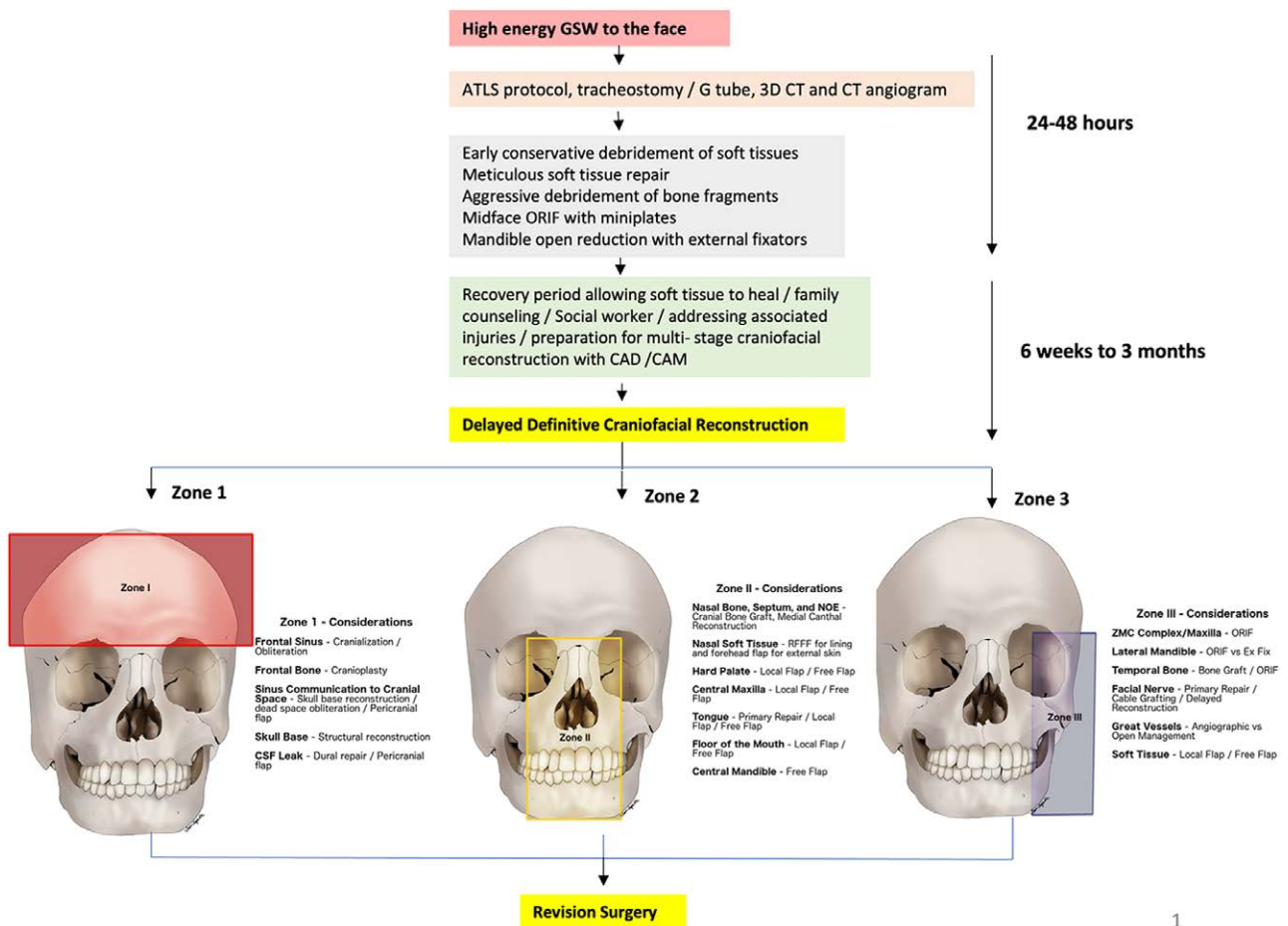


Fig. 1. Comprehensive algorithm for management of high-energy ballistic facial injuries taking into account early stabilization, intermediate recovery, and delayed multistage definitive reconstruction.

performed within 48 hours of presentation. Timing of definitive reconstruction was defined as immediate if performed at the time of debridement, early if performed within 30 days of injury, and delayed if performed after 30 days of injury. These data were combined with a literature review to establish an optimal algorithm for management of this patient population. Finally, a classification based on common bullet trajectory and craniofacial reconstruction was created (Fig. 1).

RESULTS

Thirteen patients who required microsurgical reconstruction for ballistic facial injuries sustained from ballistic facial trauma were identified (Table 1). The majority of patients (90%) were men, and the median age at time of injury was 21 [interquartile range (IQR), 17–37]. The most common etiology of the injury was self-inflicted (90%) followed by assault (10%). Soft tissue debridement and bony fixation were performed within 48 hours in all cases. The median time from injury date to the date of first free flap was 53 days (IQR, 85–165 days).

In addition, 13 patients represented 23 free flaps that were utilized. On average, patients underwent a total of two free flaps. The microsurgical flaps included were the fibular free flap (n = 14), followed by the radial forearm free flap (n = 6), scapula free flap (n = 2), and medial femoral condyle flap (n = 1). All patients required a revision surgery, and the average rate of revisions was 3.5 surgeries.

DISCUSSION

Early stabilization and debridement of GSWs are supported in literature, but there is controversy that remains with the timing of definitive reconstruction and flap selection.⁴ In our institution’s experience, we have determined that early definitive reconstruction (occurring within 30 days) is not ideal. Besides clear physical injuries, many of our patients required extensive psychiatric evaluation, social worker evaluation, and family intervention.

Table 1. GSW Patient Demographics

N	13
Sex (n)	
M	12
F	1
Mechanism of injury (n)	
Self-inflicted	11
Assault	2
Zone of injury (n)	
Zone 1	2
Zone 2	8
Zone 3	3
Time to debridement and fixation (n)	
<12 h	6
12–24 h	4
24–48 h	3
Days to definitive microsurgical reconstruction [median (IQR)]	53 (45–125)
No. free flaps [median (IQR)]	2 (1–3)
No. revision surgeries [median (IQR)]	3.5 (2–5)
Length of follow-up in years [median (IQR)]	3.3 (1.3–3.9)

In addition, utilization of computer-aided design (CAD)/computer-aided manufacturing (CAM) technology for skeleton reconstruction took from 7 to 14 days to complete. We determined that CAD/CAM is an essential component of this process, as it is essential to understand not only what free flap should be used but also what structures are needed for reconstruction. Furthermore, studies have demonstrated that there is an association between blast injury and vascular endothelial injuries, which can last up to 30 days after the inciting event.^{11,12} This furthers the support for “delayed” definitive reconstruction.

The author proposed a new classification of craniofacial GSW focusing on the common bullet paths. Although Gussack and Jurkovich¹³ have classified GSW into three zones based on the anatomical location of the injury, their classification fails to help with surgical planning of such injuries.

Proposed Classification

The author applies a defect-oriented approach using the common bullet paths. Based on the author’s experience, the complex blast-related facial injuries can be classified into different zones based on bullet trajectory (Fig. 2). Zone I injuries involve the upper third of the face, including the frontal bone, frontal sinus, anterior cranial fossa, skull base, and orbital roof (Fig. 3). Zone

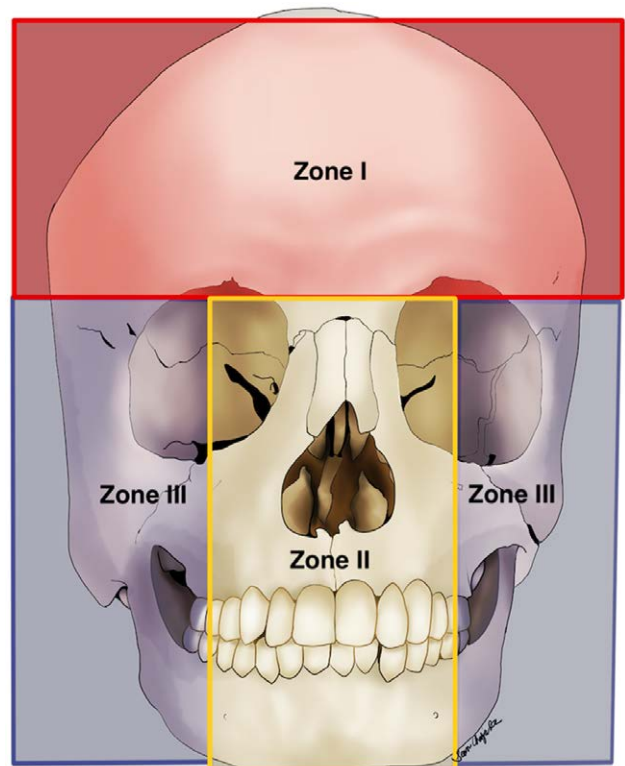
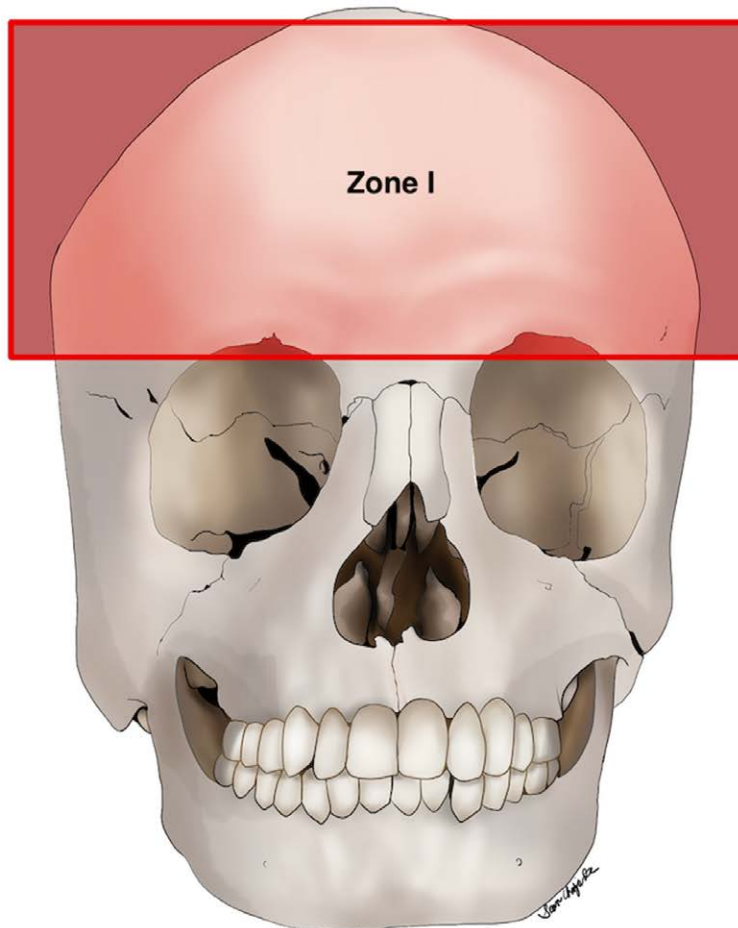


Fig. 2. Proposed classification using defect-oriented approach. Zone 1 includes frontal bone, frontal sinus, and temporal bone. Zone 2 includes medial orbit, naso-orbito-ethmoid complex, maxilla, palate, central mandible, tongue, and floor of the mouth. Zone 3 includes lateral orbit, ZMC, lateral maxilla, cheek soft tissue, facial nerve, great vessels, and lateral mandible region.



Zone 1 - Considerations

Frontal Sinus - Cranialization / Obliteration

Frontal Bone - Cranioplasty

Sinus Communication to Cranial Space - Skull base reconstruction / dead space obliteration / Pericranial flap

Skull Base - Structural reconstruction

CSF Leak - Dural repair / Pericranial flap

Fig. 3. Zone 1 describes a trajectory of the injury over the frontal region. The main considerations of this region include brain and dura protection and maintaining a separation between nasal cavity and anterior cranial fossa. When alloplastic cranioplasty is considered, the quality of soft tissue must be perfect to provide long-term soft tissue stability.

II defects involve the central, middle, and lower third of the face (including the central mandible), floor of the mouth, tongue, palate, nasal floor, nasal structure, and the naso-orbito-ethmoid complex (Fig. 4). Zone III involves the lateral face, including the zygomatico-maxillary complex (ZMC), lateral mandible, temporomandibular joint, lateral maxilla, temporal bone, facial nerve, and soft tissue of the cheek (Fig. 5). Injuries are often complex and involve multiple zones, but the approach can be simplified accordingly with this classification system.

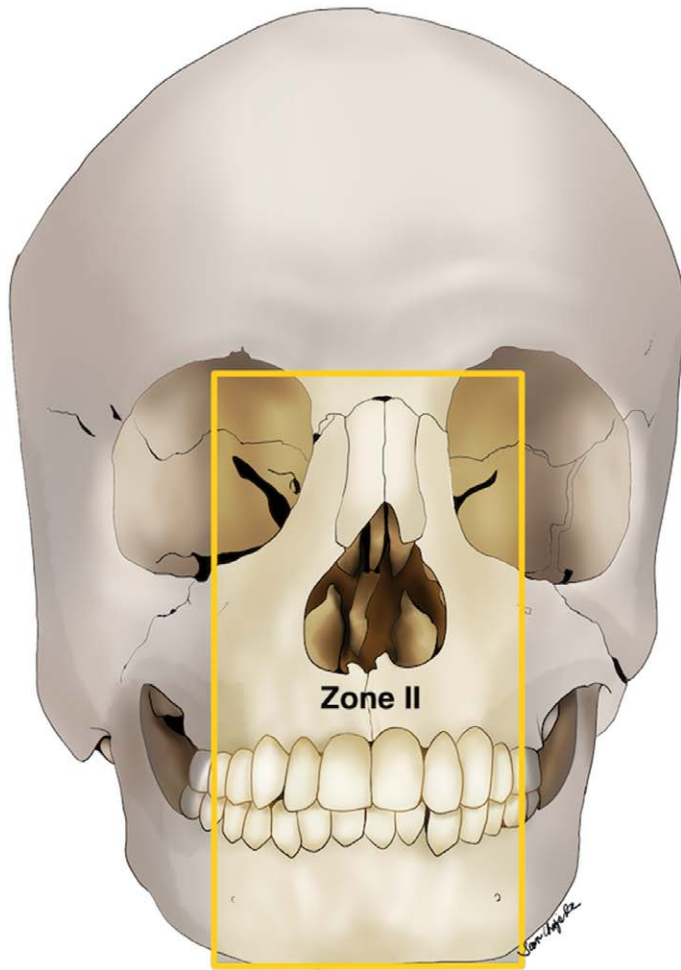
Surgical Management and Timing of Reconstruction

Surgical management of complex GSW injuries to the face can be divided into three phases: “initial stabilization,” “defect-oriented reconstruction,” and “aesthetic refinement.”

Initial Stabilization Phase

After ensuring adequate airway protection, care must be taken to control any ongoing hemorrhage and to allow for appropriate patient resuscitation and stabilization. Once all immediately life-threatening concerns

have abated, attention can then be focused on the initial stages of facial reconstruction. In zone I injury, the initial stabilization is focused heavily on a coordination between a neurosurgeon and a reconstructive surgeon to ensure appropriate neurosurgical interventions, dura repair, frontal sinus cranialization, and separation with galeal or pericranial flap. It is common practice to perform frontal bone craniectomy to prevent posttraumatic intracranial hypertension. In zone II and zone III injuries, the primary objective during the initial stabilization phase is to provide early conservative debridement of devascularized tissues, primary wound closure, and skeletal fixation following reduction with the goal of establishing and/or maintaining facial height and width and dental occlusion.^{4-6,10,14,15} Fractures of the orbit and maxilla should be reduced and stabilized with standard plates and screws. In some rare case where there is no solid bone stock available, the senior author uses K-wires to provide rigid fixation. For open comminuted mandible fractures, the senior author recommends using an external fixator for rigid fixation to minimize risk of further devascularization of bone fragments. In the senior author’s experience, early use of reconstruction



Zone II - Considerations

Nasal Bone, Septum, and NOE - Cranial Bone Graft, Medial Canthal Reconstruction

Nasal Soft Tissue - RFFF for lining and forehead flap for external skin

Hard Palate - Local Flap / Free Flap

Central Maxilla - Local Flap / Free Flap

Tongue - Primary Repair / Local Flap / Free Flap

Floor of the Mouth - Local Flap / Free Flap

Central Mandible - Free Flap

Fig. 4. Zone 2 describes a central face blast injury. The entrance wound and exit wound are always located in the submental region and nasal region, respectively. Due to the complexity of central face structures, the reconstruction always requires multiple local flaps and free flaps in a staged fashion.

plates performed at initial debridement (from outside institutions) without adequate, healthy soft tissue coverage often results in hardware extrusion, fistula formation, and infection. There are limited data regarding the incidence of reconstruction plate extrusion following a blast injury of the mandible. However, the incidence of plate extrusion after open reduction and internal fixation (ORIF) of the mandible in blunt trauma is reported between 4% and 17%.^{16,17} We surmise that the incidence of plate extrusion is much higher in blast injury of the mandible.

Defect-oriented Reconstruction

Following the initial stabilization phase, focus can then shift into the defect-oriented reconstructive phase. Within this phase, advanced craniofacial techniques and microsurgical free tissue transfer can be used to reconstruct bony and soft tissue deficits, restore facial buttresses, and prevent mid and lower face collapse. It is universally accepted that the initial stabilization phase should be performed acutely, ideally within 48 hours of injury, and the refinement phase can be performed entirely on an

elective basis. The timing of defect-oriented phase, however, remains controversial. The authors advocate for a delayed approach to definitive reconstruction. Delaying reconstruction allows for the resolution of inflammation, reducing the risk of infection and fistula formation. This delay also permits more time for the thoughtful and strategic planning that is often required in the management of complex composite craniofacial injuries. In addition, delaying reconstruction provides patients with an opportunity to establish a support system and exert their autonomy and preferences throughout their reconstructive journey.

Nearly all soft tissue injuries sustained following a blast injury require free flap reconstruction. CT angiogram of the neck is indicated in all cases to evaluate the potential recipient vessels. External carotid thrombosis was found in one patient with zone III injury. Knowing the availability of the recipient vessels, one could plan for the need for interposition vein graft before surgery.

For zone I injury, frontal bone cranioplasty and soft tissue reconstruction are indicated. The author believes that the quality of overlying soft tissue is more important

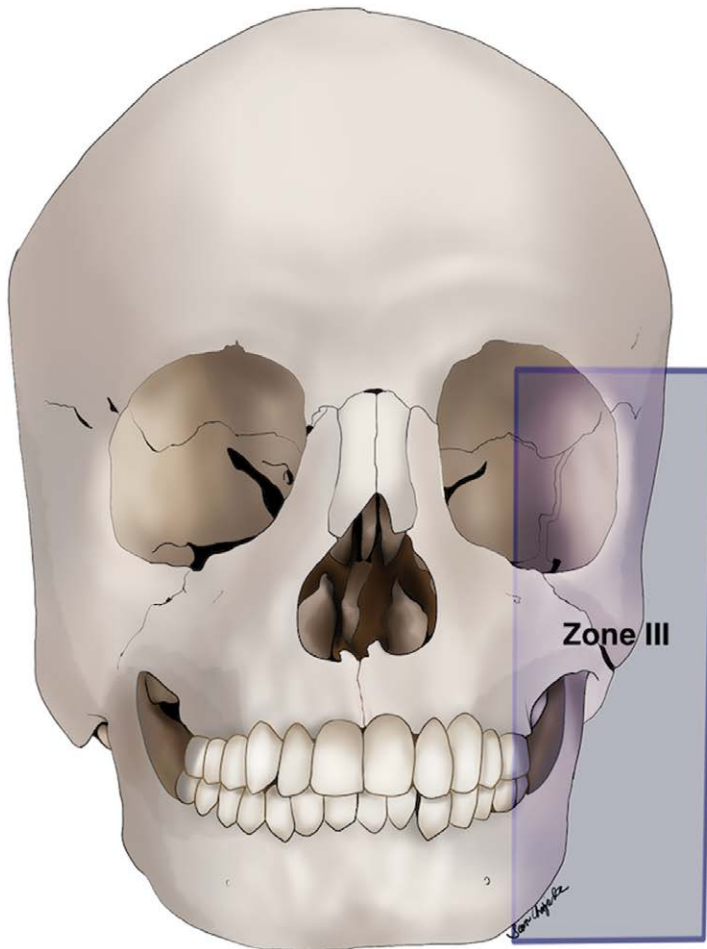


Fig. 5. Zone 3 describes a lateral face blast injury. In addition to lateral mandible and ZMC fracture, the facial nerve and neck vessels are at high risk of injury.

Zone III - Considerations

ZMC Complex/Maxilla - ORIF

Lateral Mandible - ORIF vs Ex Fix

Temporal Bone - Bone Graft / ORIF

Facial Nerve - Primary Repair / Cable Grafting / Delayed Reconstruction

Great Vessels - Angiographic vs Open Management

Soft Tissue - Local Flap / Free Flap

than the material used for cranioplasty. In this case series, we used the forearm free flap to reconstruct the soft-tissue defect at the time of alloplastic cranioplasty. For zone II injury, the author recommends staged reconstruction starting from the lower face toward the upper face. It is important to set the lower third of the face at the appropriate proportion. The occlusion should be reestablished using CAD/CAM, making sure that the condyles are seated at the normal location. Mandibular defects sustained from GSWs commonly involve severe soft tissue and skeletal deficiencies; therefore, a fibula osteoseptocutaneous free flap is our flap of choice. We have used a medial femoral epicondyle free flap in one patient who developed fibula bone flap atrophy. After the lower third of the face is reestablished, attention is paid to the middle third. For a small maxillary defect, soft tissue reconstruction using a radial forearm free flap with delayed, nonvascularized iliac bone graft may be adequate. For a large defect, a fibula osteocutaneous free flap is the flap of choice to achieve both soft tissue and skeletal reconstruction.

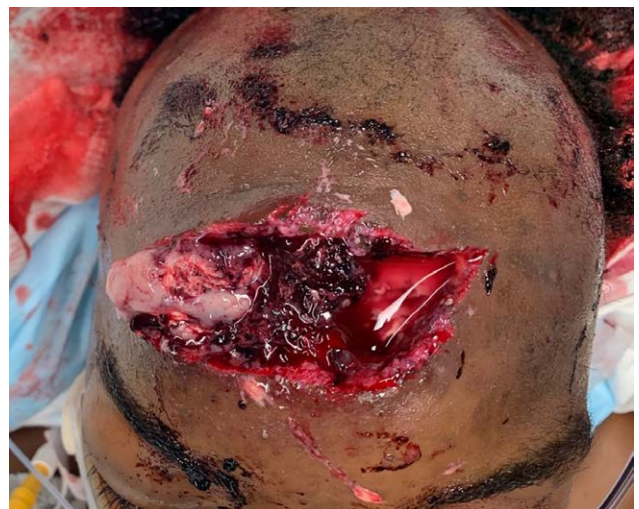

Fig. 6. Zone 1 injury. An 18-year-old man who sustained a GSW to the head. The initial management includes surgical debridement of the scalp, skull, and intracranial compartment and frontal bone craniectomy.

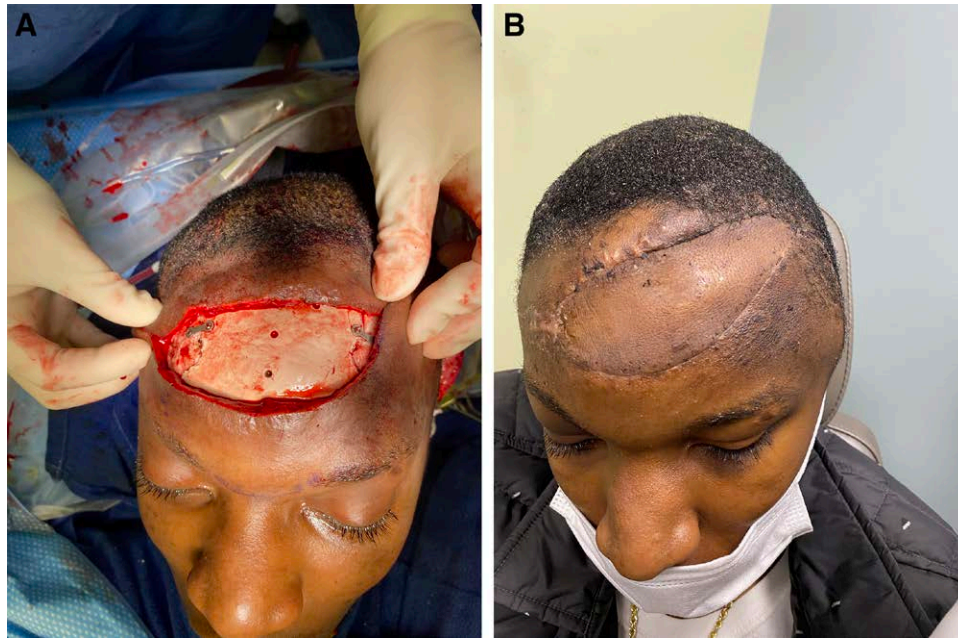

Fig. 7. After recovery from the initial injury, the patient underwent simultaneous PEEK implant cranioplasty (A) and ulnar forearm free flap soft tissue reconstruction (B). (Note the amount of soft tissue needed after PEEK implant cranioplasty.)

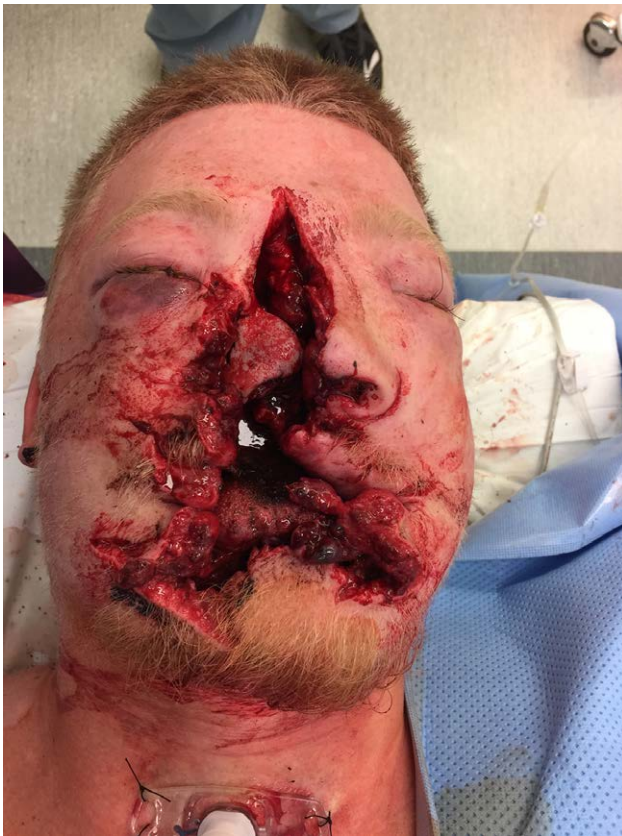

Fig. 8. Zone 2: case 1. A 16-year-old boy who sustained a self-inflicted GSW to the central face. He underwent tracheostomy, debridement of the soft tissue, ORIF of the midface and nasal bone, open reduction and external fixation of the mandible, and primary soft tissue repair.

After restoration of occlusion and maxillary/mandible alignment, attention is paid to reconstruct the nasal passage and nasal structures. For composite nasal defects, we routinely utilize the Menick approach for nasal reconstruction.^{18,19} This includes a radial forearm free flap for nasal lining followed by a three-stage forehead flap. An unstable nasal lining will result in the contraction of the nasal cavity. Additionally, a suboptimal nasal lining is not strong enough to support a bone or cartilage graft. The author uses the superficial temporal artery and vein as the preferred recipient vessels routinely for nasal lining reconstruction. As far as nasal structural support is concerned, if the nasal bone pyramid is destroyed due to the injury, the cranial bone strut graft is indicated. If the nasal bone pyramid is intact, a costochondral graft is adequate to provide stability.¹⁸ To address lateral facial blast injury (zone III), the fibula osteocutaneous free flap remains a flap of choice. For those who need more soft tissue than bone, the scapular free flap is also a great option. The soft tissue augmentation and facial reanimation could be performed simultaneously with a free functional gracilis musculocutaneous flap, using a contralateral facial nerve to motor the gracilis through a cross facial nerve graft. Blink restoration was performed using two cross facial nerve grafts and platysma muscle grafts as described by Biglioli et al.²⁰

Aesthetic Refinement

The final phase of surgical management involves reconstructive refinement of aesthetic appearance. The senior author usually waits at least 6 months before proceeding with any such revision procedures.

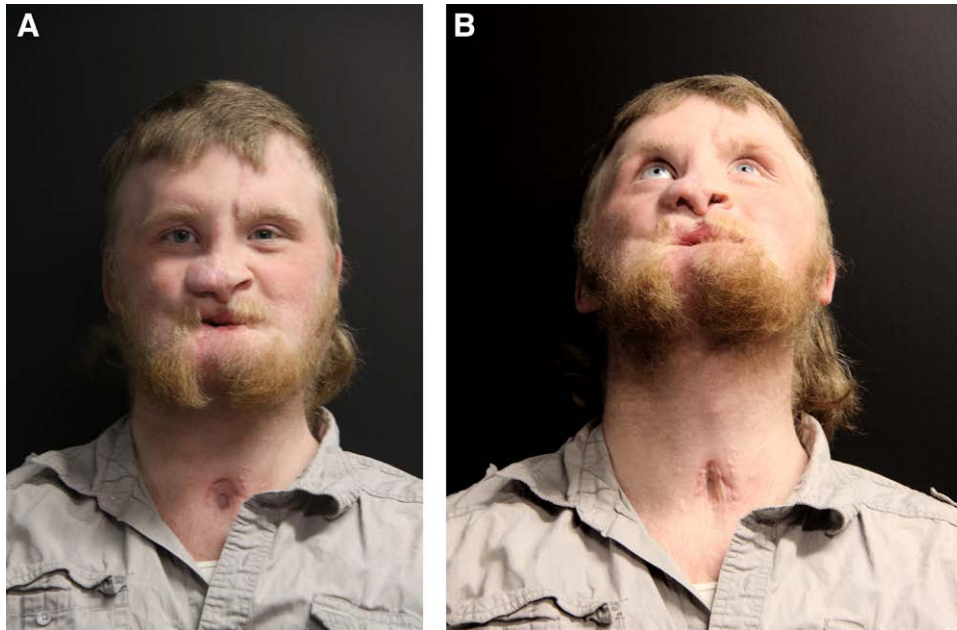


Fig. 9. Zone 2: case 1 (continued). The patient underwent mandibular reconstruction with fibula free flap 3 months later. The maxilla and midface were reconstructed with the second fibula free flap 3 months afterward. Three months later, he underwent nasal lining reconstruction with radial forearm free flap, and revision surgery of both maxilla and mandible. Two months later, he underwent three-stage nasal reconstruction with paramedial forehead flap and rib cartilage graft to the nose. The reconstruction has been stable for at least 6 years (A and B).

Complications and Prevention

Complications can be categorized into acute postinjury, acute postfree flap, subacute postreconstruction, and chronic. During the acute postinjury period, we were able to eliminate mandibular hardware extrusion and fistula formation by using external fixation. Infection was rare due to the robust blood supply of the face. It is important that during this time, the patients and family understand the process of facial reconstruction and anticipate complications and set their expectations appropriately. Family support is extremely important for successful reconstruction. After undergoing free flap reconstruction, postoperative care and complications were not different than any other head and neck microsurgical reconstruction. It is noted that these patients were physically healthy before the injuries. The hospital stay is usually less than 7 days.

CASE REPORTS

Zone 1: Case 1

This is an 18-year-old man who sustained a GSW to the head. Initial surgical management for the patient consisted of surgical debridement of the scalp, skull, and intracranial compartment (Fig. 6A). In addition, a frontal bone craniectomy was performed (Fig. 6B). After sufficient recovery from initial injury occurred, the patient underwent simultaneous polyetheretherketone (PEEK) implant cranioplasty along with ulnar forearm free flap soft tissue reconstruction (Fig. 7). It is critical to note that a significant amount of soft tissue was required after PEEK implant cranioplasty.

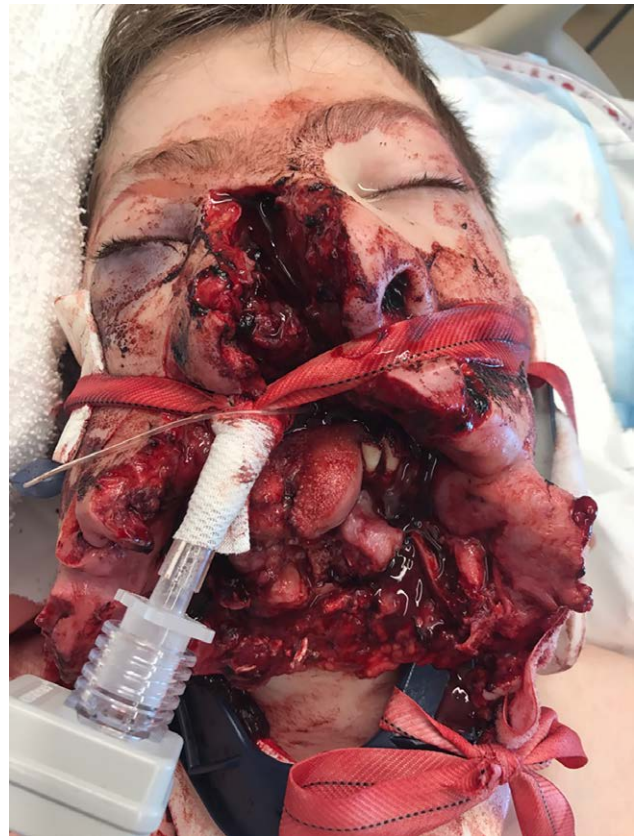

Fig. 10. Zone 2: case 2. A 16-year-old boy who sustained a GSW to the central face. He underwent debridement, tracheostomy, ORIF of the midface, and open reduction with external fixation of the mandible.



Fig. 11. Zone 2: case 2 (continued). Three months later, the mandible was reconstructed with a fibular free flap. At the same time, a commissuroplasty and right upper lip were reconstructed with a mucosa V-Y advancement flap. Three months later, the patient underwent midface, nasal floor, and upper lip reconstruction with soft tissue only-RFFF. He then underwent multistage nasal reconstruction with a paramedian forehead flap. He subsequently developed atrophy of the fibular bone graft after mandible reconstruction. He then underwent revision surgery with iliac bone graft wrapping along with a medial femoral condyle chimeric free flap. He has a stable result 3 years after the last operation (A and B). RFFF indicates radial forearm free flap.

Zone 2: Case 1

This is a 16-year-old boy who sustained a self-inflicted GSW to the central face (Fig. 8). The patient underwent tracheostomy, soft tissue debridement, open reduction and ORIF of the midface and nasal bone, open reduction and external fixation of the mandible, and primary soft tissue repair. Three months later, the patient then underwent mandibular reconstruction with a fibula free flap. The patient underwent nasal lining reconstruction utilizing a radial forearm free flap and revision surgery of the maxilla and mandible 3 months later. After 2 months, the patient underwent 3-stage nasal reconstruction with a paramedian forehead flap and rib cartilage to the nose. The patient followed up 6 years later, where it was found that the reconstruction has been stable and healed excellently (Fig. 9).

Zone 2: Case 2

This is a 16-year-old boy who sustained a GSW to the central face (Fig. 10). The patient underwent debridement, tracheostomy, ORIF of the midface, and open reduction with external fixation of the mandible (Fig. 10). Three months postoperatively, the mandible was reconstructed with a fibular free flap. Additionally, the patient underwent a commissuroplasty and right upper lip reconstruction with a mucosa V-Y advancement flap. Three months later, the patient underwent reconstruction of the midface, nasal floor, and upper lip with soft tissue. The patient then underwent staged nasal reconstruction with a paramedian forehead flap. Subsequently,

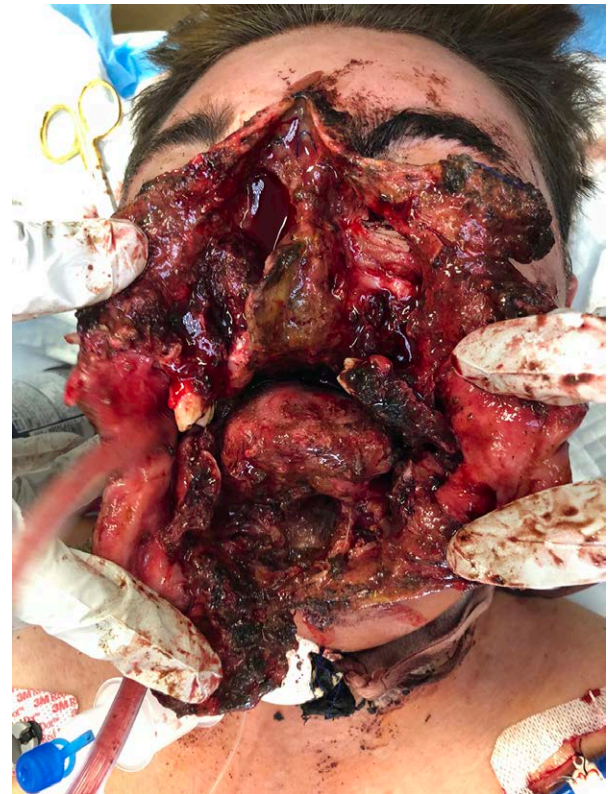

Fig. 12. Zone 2: case 3. A 15-year-old-boy who sustained a GSW to the central face. He underwent debridement, tracheostomy, ORIF of the midface, open reduction, and external fixation of the mandible and primary soft tissue closure.

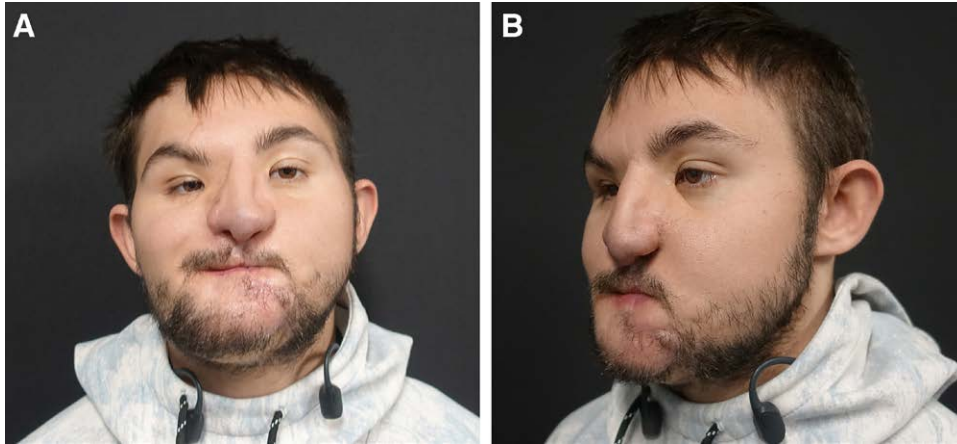

Fig. 13. Zone 2: case 3 (continued). Three months later, the patient underwent mandible reconstruction with a fibula free flap. He subsequently underwent midface reconstruction with a fibula free flap and local palatal flap for palatal fistula 3 months later. He then underwent nasal lining, nasal floor, and columella reconstruction with a radial forearm free flap. A forehead tissue expander was also placed during the radial forearm free flap. The nose was subsequently reconstructed with a paramedian forehead flap. A cranial bone graft was performed during forehead flap debulking. He has a stable result 3 years after the last operation (A and B).

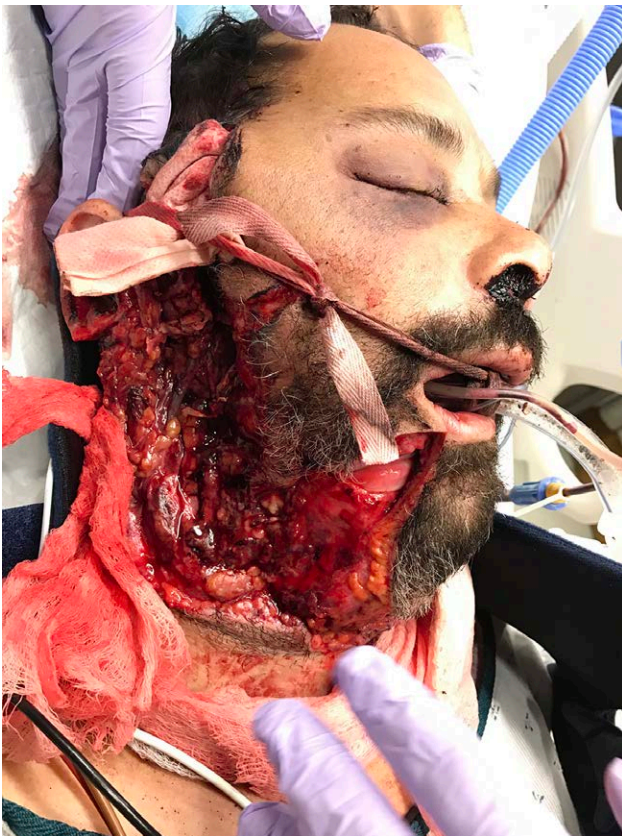

Fig. 14. Zone 3: case 1. A 42-year-old man who sustained a GSW to right side of the face. Computed tomography angiography demonstrated a complete occlusion of right external carotid artery. He underwent an initial soft tissue repair and ORIF of midface and right ZMC. In addition to missing the right hemimandible, he developed complete facial paralysis on the right side. A reconstruction started with a cross facial nerve graft using the antebrachial nerve as a donor. Two months later, he underwent right mandible reconstruction with a fibular osteocutaneous flap with interposition vein graft.

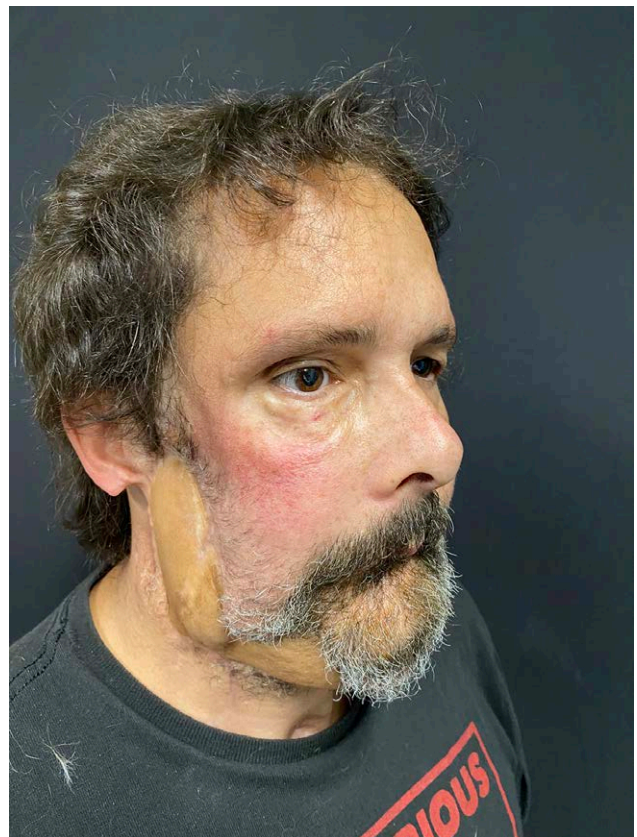


Fig. 15. Zone 3: case 1 (continued). After mandible reconstruction and a positive Tinel sign, he underwent a smile reconstruction with a gracilis free flap with interposition vein graft. Blink restoration was performed with a two-stage approach. An upper cross facial nerve graft was performed using the sural nerve as a donor nerve. Eight months later, he underwent a free platysma muscle graft to both upper and lower eyelids with direct neurotization. Postoperatively, he can blink and smile.

the patient developed atrophy of the fibular bone graft, which required revision surgery utilizing iliac bone graft wrapping along with a medial femoral condyle chimeric free flap. Three years postoperatively, the patient has stable results and is pleased with his reconstructive outcome (Fig. 11).

Zone 2: Case 3

This is a 15-year-old boy who sustained a GSW to the central face (Fig. 12A). He underwent immediate debridement, tracheostomy, ORIF of the midface, open reduction and external fixation of the mandible, and soft tissue closure (Fig. 12B). Three months postoperatively, the patient underwent mandible reconstruction with a fibula free flap. He then underwent midface reconstruction utilizing a fibula free flap and local palatal flap for palatal fistula 3 months later. The patient went on to receive nasal lining, nasal floor, and columellar reconstruction with a radial forearm free flap. In addition, the patient also received a forehead tissue expander during the same procedure with the radial forearm free flap. Finally, the nose was reconstructed with a paramedian forehead flap and a cranial bone graft was performed. Three years after the final operation, the patient was found to have clinically stable results (Fig. 13).

Zone 3: Case 1

This is a 42-year-old man who sustained a GSW to the right side of the face (Fig. 14). Computed tomography angiography demonstrated complete occlusion of the right external carotid artery. The patient underwent initial soft tissue repair, ORIF of the midface, and right-sided ZMC reconstruction. The patient went on to develop complete facial paralysis on the right side, which required reconstruction using cross facial nerve graft using antibrachial nerve as a donor. Two months later, the patient underwent right mandible reconstruction with a fibular osteocutaneous flap with interposition vein graft. After mandible reconstruction was completed, the patient underwent smile reconstruction with a gracilis free flap with interposition vein graft. Blink restoration was also performed with a two-stage approach. In addition, an upper cross facial nerve graft using the sural nerve as the donor site was performed. Eight months postoperatively, the patient underwent free platysma muscle graft to the upper and lower eyelids with direct neurotization. The procedure was successful, with the patient successfully blinking and smiling (Fig. 15).

CONCLUSIONS

Our institutional experience demonstrates successful reconstructive outcomes for ballistic injury to the face with planned serial surgeries, including acute establishment of facial buttresses, routine application of external fixation, and “delayed” free flap reconstruction. Using the zone of injury-related approach, the surgeon is able to plan reconstruction accordingly. These patients can return to their activities of daily living and have acceptable aesthetic outcomes.

ACKNOWLEDGMENTS

The authors acknowledge Sean Chaiyasate, who provided the medical illustrations for the figures in this article, and Meghan Chaiyasate, who provided an initial data collection.

PATIENT CONSENT

Patients provided written consent for the use of their images and for surgical treatment.

REFERENCES

1. Fowler KA, Dahlberg LL, Haileyesus T, et al. Firearm injuries in the United States. *Prev Med.* 2015;79:5–14.
2. Pereira C, Boyd JB, Dickenson B, et al. Gunshot wounds to the face: level I urban trauma center: a 10-year level I urban trauma center experience. *Ann Plast Surg.* 2012;68:378–381.
3. Taber AA. Reconstruction of gunshot wounds of the mandible. 128 cases treated by autogenous iliac crest bone grafts. *J Craniomaxillofac Surg.* 1990;18:310–314.
4. Vaca EE, Bellamy JL, Sinno S, et al. Management of high-energy avulsive ballistic facial injury: a review of the literature and algorithmic approach. *Plast Reconstr Surg Glob Open.* 2018;6:e1693.
5. Shuck LW, Orgel MG, Vogel AV. Self-inflicted gunshot wounds to the face: a review of 18 cases. *J Trauma.* 1980;20:370–377.
6. Sun GH, Patil YJ, Harmych BM, et al. Inpatients with gunshot wounds to the face. *J Craniofac Surg.* 2012;23:e62–e65.
7. Shackford SR, Kahl JE, Calvo RY, et al. Gunshot wounds and blast injuries to the face are associated with significant morbidity and mortality: results of an 11-year multi-institutional study of 720 patients. *J Trauma Acute Care Surg.* 2014;76:347–352.
8. Hollier L, Grantcharova EP, Kattash M. Facial gunshot wounds: a 4-year experience. *J Oral Maxillofac Surg.* 2001;59:277–282.
9. Alper M, Totan S, Cankayali R, et al. Gunshot wounds of the face in attempted suicide patients. *J Oral Maxillofac Surg.* 1998;56:930–933.
10. Clark N, Birely B, Manson PN, et al. High-energy ballistic and avulsive facial injuries: classification, patterns, and an algorithm for primary reconstruction. *Plast Reconstr Surg.* 1996;98:583–601.
11. Elder GA, Gama Sosa MA, De Gasperi R, et al. Vascular and inflammatory factors in the pathophysiology of blast-induced brain injury. *Front Neurol.* 2015;6:48.
12. Wang JM, Chen J. Damage of vascular endothelial barrier induced by explosive blast and its clinical significance. *Chin J Traumatol.* 2016;19:125–128.
13. Gussack GS, Jurkovich GJ. Penetrating facial trauma: a management plan. *South Med J.* 1988;81:297–302.
14. Burke JE, Lanzi GL. Early management of civilian gunshot wounds to the face. *J Trauma.* 1994;37:514.
15. Firat C, Geyik Y. Surgical modalities in gunshot wounds of the face. *J Craniofac Surg.* 2013;24:1322–1326.
16. Barry RG, Wolbert TT, Gress TW, et al. Outcomes after open reduction with internal fixation of mandible fractures. *J Craniofac Surg.* 2018;29:1237–1240.
17. Abdulrazaq SS, Riyadh S. The fate of the mandibular reconstruction plate. *J Craniofac Surg.* 2019;30:e97–e101.
18. Menick FJ. A 10-year experience in nasal reconstruction with the three-stage forehead flap. *Plast Reconstr Surg.* 2002;109:1839–1855.
19. Hauth D, Heppert W. “Aesthetic nasal reconstruction: principles and practice” by Frederick J. Menick. *Facial Plast Surg.* 2019;35:216.
20. Biglioli F, Zago M, Allevi F, et al. Reanimation of the paralyzed lids by cross-face nerve graft and platysma transfer. *J Craniomaxillofac Surg.* 2018;46:521–526.