

BRAIN COMMUNICATIONS

Left hemisphere abnormalities in developmental prosopagnosia when looking at faces but not words

 Christian Gerlach,^{1,2}  Solja K. Klargaard,¹ Dag Alnæs,³ Knut K. Kolskår,^{3,4} Jens Karstoft,^{2,5}  Lars T. Westlye^{3,4,†} and  Randi Starrfelt^{6,†}

[†]These authors shared last-authorship.

Developmental prosopagnosia is a disorder characterized by profound and lifelong difficulties with face recognition in the absence of sensory or intellectual deficits or known brain injury. While there has been a surge in research on developmental prosopagnosia over the last decade and a half, the cognitive mechanisms behind the disorder and its neural underpinnings remain elusive. Most recently it has been proposed that developmental prosopagnosia may be a manifestation of widespread disturbance in neural migration which affects both face responsive brain regions as well as other category-sensitive visual areas. We present a combined behavioural and functional MRI study of face, object and word processing in a group of developmental prosopagnosics ($N = 15$). We show that developmental prosopagnosia is associated with reduced activation of core ventral face areas during perception of faces. The reductions were bilateral but tended to be more pronounced in the left hemisphere. As the first study to address category selectivity for word processing in developmental prosopagnosia, we do not, however, find evidence for reduced activation of the visual word form area during perception of orthographic material. We also find no evidence for reduced activation of the lateral occipital complex during perception of objects. These imaging findings correspond well with the behavioural performance of the developmental prosopagnosics, who show severe impairment for faces but normal reading and recognition of line drawings. Our findings suggest that a general deficit in neural migration across ventral occipito-temporal cortex is not a viable explanation for developmental prosopagnosia. The finding of left hemisphere involvement in our group of developmental prosopagnosics was at first surprising. However, a closer look at existing studies shows similar, but hitherto undiscussed, findings. These left hemisphere abnormalities seen in developmental prosopagnosia contrasts with lesion and imaging studies suggesting primarily right hemisphere involvement in acquired prosopagnosia, and this may reflect that the left hemisphere is important for the development of a normal face recognition network.

1 Department of Psychology, University of Southern Denmark, DK-5230 Odense, Denmark

2 BRIDGE, University of Southern Denmark, DK-5230 Odense, Denmark

3 NORMENT, Division of Mental Health and Addiction, Oslo University Hospital, Oslo 0424, Norway

4 Department of Psychology, University of Oslo, Oslo 0317, Norway

5 Department of Radiology, Odense University Hospital, Odense DK-5230, Denmark

6 Department of Psychology, University of Copenhagen, Copenhagen DK-1353, Denmark

Correspondence to: Christian Gerlach, PhD

Department of Psychology,

University of Southern Denmark,

Campusvej 55, DK-5230 Odense M, Denmark

E-mail: cgerlach@health.sdu.dk

Received June 28, 2019. Revised September 11, 2019. Accepted October 17, 2019

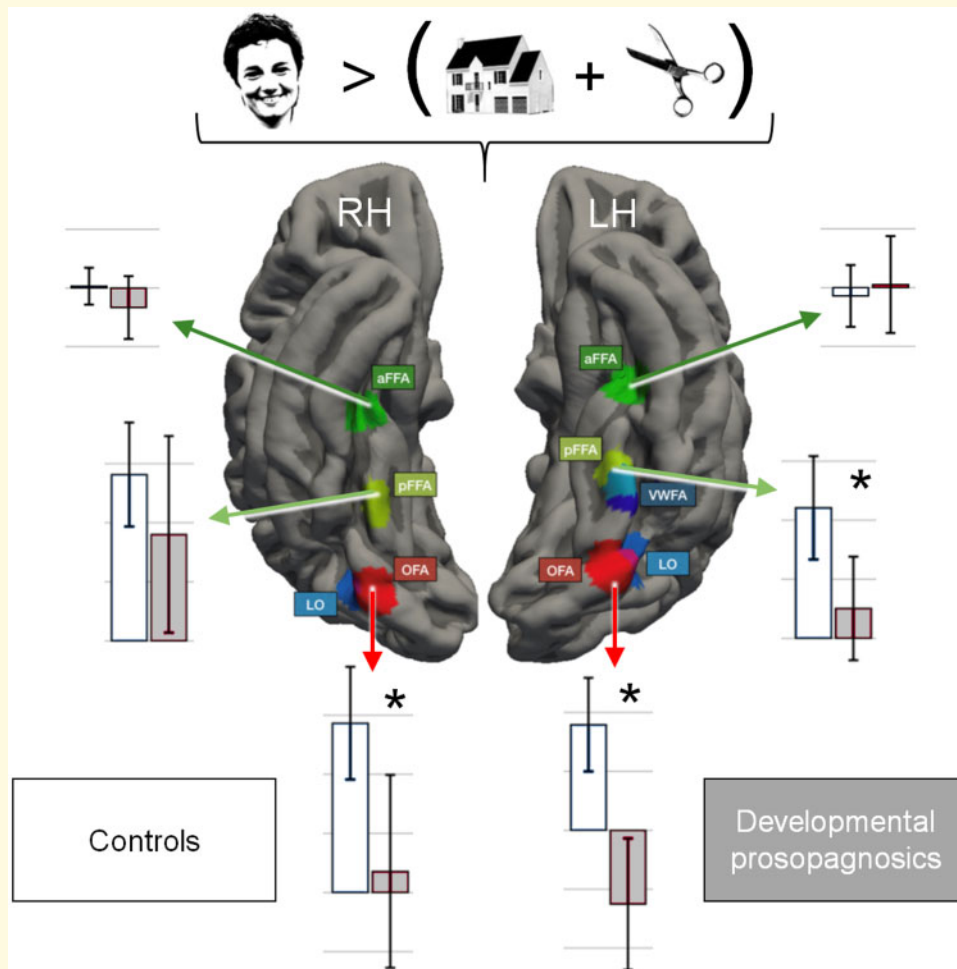
© The Author(s) (2019). Published by Oxford University Press on behalf of the Guarantors of Brain.

This is an Open Access article distributed under the terms of the Creative Commons Attribution Non-Commercial License (<http://creativecommons.org/licenses/by-nc/4.0/>), which permits non-commercial re-use, distribution, and reproduction in any medium, provided the original work is properly cited. For commercial re-use, please contact journals.permissions@oup.com

Keywords: developmental prosopagnosia; face recognition; object recognition; reading; the visual word form area

Abbreviations: aFFA = anterior fusiform face area; ATL = anterior temporal lobe; CI = confidence interval; CFMT = Cambridge Face Memory Test; CFPT = Cambridge Face Perception Test; COPE = COntasts Parameter Estimate; DP = developmental prosopagnosia; FEAT = FMRI expert analysis tool; FEQ = Faces and Emotion Questionnaire; FIR = face identity recognition; FFA = fusiform face area; fMRI = functional magnetic resonance imaging; ISI = inter stimulus interval; LO = lateral occipital area; MNI = Montreal Neurological Institute; OFA = occipital face area; pFFA = posterior fusiform face area; RT = reaction time; ROI = region of interest; SD = standard deviation; SPSS = Statistical Package for the Social Sciences; VWFA = visual word form area; WLE = word length effect

Graphical Abstract



Introduction

Developmental prosopagnosia (DP) is a disorder characterized by profound and lifelong difficulties with face recognition in the absence of any sensory or intellectual deficits or known brain injury (Duchaine, 2011). The first report of DP was made by McConachie (1976), and several hundred cases have been reported since (Geskin and Behrmann, 2018). Despite this, the disorder is not well understood, and it is even debated whether the impairment is confined to faces (Geskin and Behrmann, 2018; see also a range of commentaries in the same issue). Navigational problems, for example, perhaps due to

altered processing of topographical information, are often associated with DP (De Haan and Campbell, 1991; Duchaine et al., 2003; Grueter et al., 2007; Lee et al., 2010), as is impaired perception of bodies (Righart and de Gelder, 2007; Biotti et al., 2017; Rivolta et al., 2017). Even though the prevalence of topographical/navigational deficits and body perception impairments may be higher in DP than in the typical population, body perception deficits are not found in all DPs (Duchaine et al., 2006), and topographical processing also dissociates from face processing in DP (Corrow et al., 2016; Klargaard et al., 2016). Nevertheless, perceptual impairments with topography and bodies are of particular interest because these

categories, just like faces, are associated with circumscribed brain regions: The parahippocampal place area (Epstein and Kanwisher, 1998) and the occipital place area (Dilks *et al.*, 2013) for topographical processing, and the fusiform body area (Peelen and Downing, 2005) and the extrastriate body area (Downing *et al.*, 2001) for body perception. Furthermore, because of the anatomical proximity of these category-sensitive regions to areas in the face processing network (Haxby *et al.*, 2000), it has been speculated that such co-occurring deficits in DP may reflect individual differences in white matter integrity (Gray and Cook, 2018) or in widespread neural migration errors during cortical development (Susilo and Duchaine, 2013), similar to what has been suggested for comorbidity in dyslexia (ectopia and microgyria; Ramus, 2004).

The behavioural heterogeneity of DP (Schmalzl *et al.*, 2008; Susilo and Duchaine, 2013) is mirrored in findings regarding the neural underpinnings of DP. Many previous functional imaging studies have reported no significant differences in brain activation in response to facial stimuli between DPs and controls (Hasson *et al.*, 2003; Avidan *et al.*, 2005; Van den Stock *et al.*, 2008; Avidan and Behrmann, 2009; Furl *et al.*, 2011; Avidan *et al.*, 2014). The remaining studies have reported reduced activation in DPs compared with controls in different, and primarily ventral, areas of the face processing network (Hadjikhani and de Gelder, 2002; Bentin *et al.*, 2007; Williams *et al.*, 2007; Dobel *et al.*, 2008; Minnebusch *et al.*, 2009; Dinkelacker *et al.*, 2011; Rivolta *et al.*, 2014; Zhang *et al.*, 2015; Lohse *et al.*, 2016; Jiahui *et al.*, 2018). These areas include: the occipital face area (OFA; Haxby *et al.*, 1999; Gauthier *et al.*, 2000), the fusiform face area (FFA; Kanwisher *et al.*, 1997), and the anterior temporal lobe (ATL; Rajimehr *et al.*, 2009; Nestor *et al.*, 2011). Similar inconsistency is seen in terms of measures of structural and functional connectivity with some studies reporting altered long-range connections linking anterior (ATL) with posterior areas (Thomas *et al.*, 2009; Avidan *et al.*, 2014), whereas other studies report more local alterations in connectivity (Gomez *et al.*, 2015; Song *et al.*, 2015a, b; Lohse *et al.*, 2016; Zhao *et al.*, 2016), and two studies reporting alterations in both short- and long-range connectivity (Rosenthal *et al.*, 2017; Zhao *et al.*, 2018).

Provided that face recognition can be selectively affected in DP—a topic which is highly debated (Geskin and Behrmann, 2018)—some of the behavioural heterogeneity and comorbidity observed in DP may reflect true differences in aetiology. However, some of the variabilities are also likely to reflect differences in diagnostic criteria (Barton and Corrow, 2016), behavioural test paradigms (Campbell and Tanaka, 2018) and statistical procedures (Gerlach *et al.*, 2018). The same is certainly true of the diverse findings reported in the imaging literature. These inconsistencies make it very difficult to identify any common behavioural or neural pattern in DP and even more difficult to discern how behavioural and neural abnormalities are related. Furthermore, there are

relatively few imaging studies of DP and the ones that exist often involve the same (sub)set of individuals (Avidan *et al.*, 2005; Behrmann *et al.*, 2007; Avidan and Behrmann, 2009; Garrido *et al.*, 2009; Thomas *et al.*, 2009; Furl *et al.*, 2011; Avidan *et al.*, 2014; Lohse *et al.*, 2016; Zhao *et al.*, 2016; Rosenthal *et al.*, 2017; Zhao *et al.*, 2018) and/or are based on small samples ($N \leq 7$) (Hadjikhani and de Gelder, 2002; Hasson *et al.*, 2003; Avidan *et al.*, 2005; Behrmann *et al.*, 2007; Bentin *et al.*, 2007; Williams *et al.*, 2007; Dobel *et al.*, 2008; Van den Stock *et al.*, 2008; Avidan and Behrmann, 2009; Minnebusch *et al.*, 2009; Avidan *et al.*, 2014; Rivolta *et al.*, 2014; Gomez *et al.*, 2015; Zhang *et al.*, 2015).

Jiahui *et al.* (2018) recently addressed the neural selectivity of the face processing deficit in a relatively large sample of DPs ($N=22$). They examined activation not only in the ventral face network (OFA and FFA) but also in ‘body areas’ (extrastriate body area/fusiform body area) and ‘place areas’ (occipital place area/parahippocampal place area) during a one-back task. Compared with controls, the DP group showed generally reduced activation in the OFA and FFA during face processing although only the FFA activations (bilaterally) were significantly reduced. However, the DPs also exhibited significantly reduced activation of the parahippocampal place area bilaterally, and the right occipital place area and medial place area during scene processing. Reduced, although not significantly reduced, activations during processing of bodies in the extrastriate body area and fusiform body area were also reported. In comparison, there were no general reductions for objects in ‘object areas’ LO (lateral occipital area) and posterior fusiform gyrus (Grill-Spector *et al.*, 2001; Grill-Spector, 2003). Interestingly, the reductions in activation seen for the DPs in the face regions of interest (ROIs) were not larger than the reductions observed during scene processing in the right medial place area and parahippocampal place area.

One limitation of the study by Jiahui *et al.* (2018) is that it does not report whether the DPs also exhibited behavioural problems with processing of scenes and bodies (in addition to faces). This makes it difficult to assess the functional relevance of the observed reductions in category-sensitive areas. According to the authors, the widespread nature of the observed reductions might reflect neural migration errors; an explanation that as mentioned has also been advanced to account for comorbidity in dyslexia. Such an account is not incompatible with reduced activations in category-sensitive areas as white matter structure may be important for, and perhaps even a prerequisite for, functional specialization (Fields, 2008; Song *et al.*, 2015b). If this is the case, we might expect that individuals with DPs should evince reduced activation in other visual category-sensitive areas too, such as the visual word form area (VWFA); a patch in the left lateral occipito-temporal sulcus (Cohen *et al.*, 2000) claimed to be specialized for processing of orthographic

input (Dehaene and Cohen, 2011). To our knowledge this has not yet been tested.

The aim of the present investigation was thus 2-fold: (i) to gain further evidence for alterations in the ventral face processing network (OFA and posterior and anterior FFA) in a comparatively large group of DPs ($N=15$), and more specifically (ii) to examine whether DPs exhibit reduced category sensitive activation in the VWFA during processing of orthographic input relative to neurotypical individuals ($N=34$).

Materials and methods

Participants and behavioural measures

We report data from 15 DPs [three males, mean age: 36.9 years ($SD = 13$)] and two control groups of 34 neurotypical participants each. Control Group 1 [12 males, mean age: 37.6 years ($SD = 8$)] served as controls in the functional magnetic resonance imaging (fMRI) experiment. Control Group 2 [10 males, mean age: 36.5 years ($SD = 12$)] served as controls in the behavioural assessment of object recognition and reading. Control Group 2 has served in previous publications (Gerlach *et al.*, 2016; Hendel *et al.*, 2019) and is included here because they completed the same extended behavioural test battery as the DPs. Control Group 1 was recruited for the scanning study but also performed the face processing tests.

The DP participants and controls provided written informed consent according to the Helsinki declaration. The Regional Committee for Health Research Ethics of Southern Denmark has approved the project (Project-ID: S-20150134).

All participants with DP have independently contacted our research group with subjective concerns about their ability to recognize faces and have completed structured interviews regarding everyday difficulty with facial identity recognition and possible family history of DP. They all report lifelong difficulties recognizing friends, colleagues and sometimes even close family members and themselves by their faces. The inclusion criteria for DP in the present study were (i) a deficit in learning to recognize novel upright faces on the Cambridge Face Memory Test (CFMT; Duchaine and Nakayama, 2006) determined as a score that deviates significantly ($P < 0.05$ one-tailed Bayesian estimate) from the mean of a Danish reference sample ($N=65$) and (ii) a score on the first part of the Faces and Emotion Questionnaire [FEQ; Face Identity Recognition (FIR) scale: 29-items; Freeman *et al.*, 2015] that deviates significantly ($P < 0.05$ one-tailed Bayesian estimate) from the mean of a Danish reference sample ($N=64$). These comparisons were made by means of the methods developed for comparing the performance of an individual with that of a small control sample (Bayesian test for a deficit; implemented in the program SingleBayes_ES; Crawford

et al., 2010). It should be noted that each DP also differed significantly from Control Group 1 on both the CFMT and the FIR-scale using the same assessment procedure (see Supplementary Table 1). As a final index of face processing, which was not used as an inclusion criterion, the DPs performed the Cambridge Face Perception Test (CFPT; Duchaine *et al.*, 2007).

In addition to the face processing tasks, the DPs have been assessed with a battery of other tests. Here, we report the results from two of these which directly relate to the stimulus types used in the scanning paradigm: an object recognition task (object decision) and a reading task. In the object recognition task, the participants were presented with 160 full line drawings and had to decide whether they represented real objects or non-objects (Gerlach *et al.*, 2016). Performance in this task is measured in terms of the trimmed ($2.5 SDs > <$ the mean of each individual) reaction time (RT) to correct trials for real objects, and A which is bias-free measure of discrimination sensitivity (Zhang and Mueller, 2005) that varies between 0.5 and 1.0 with higher scores indicating better discrimination between objects and non-objects. In the reading task, the participants were presented with 150 words, one at a time, of 5–7 letters (50 of each length matched for word frequency and orthographic neighbourhood size). Reading RTs are measured by a voice key (a microphone connected to a response box). The mean-trimmed RT was calculated for each participant as was the word length effect (WLE; Starrfelt *et al.*, 2018). The WLE was calculated using linear regression, where the slope represents the additional time needed per additional letter in a word.

The dependent variable in the CFMT and the CFPT is accuracy rather than RT as neither task is based on speeded responses. In comparison, all other experimental tasks involve speeded responses in that the participants are encouraged to respond as fast and as accurately as possible. Hence, for these tasks RT to correct trials is often the most sensitive dependent variable. This is in particular true of the reading task where (non-dyslexic) participants often make very few errors (Starrfelt *et al.*, 2018).

The DPs received gift certificates of 400 DKK (~60 USD) for participating in the scanning part of the present study but did not receive remuneration for participating in the behavioural tests.

All participants in Control Group 1 performed within 2 SDs on the CFMT evaluated by the age and sex adjusted norms provided by Bowles *et al.* (2009), and also within the normal range of the Danish reference sample on both the CFMT and the FIR scale. For participation in the scanning part of the study, the controls received gift certificates of 400 DKK (~60 USD).

fMRI task paradigm

To ensure that the DPs were able to perform the task at the same level as the control group (Price and Friston,



Figure 1 Examples of the stimuli shown during image acquisition.

1999), we used a simple target detection task adapted from Dehaene *et al.* (2010) and Monzalvo *et al.* (2012) who kindly provided the stimuli. We chose this paradigm because it has already proven sensitive to the kind of category-sensitive activations we wanted to examine. While in the scanner participants were presented with stimuli from four main categories (faces, houses, tools and words) as well as a baseline stimulus (revolving checkerboards; see Fig. 1) and were instructed to press a button when a red asterisk appeared above or below the stimulus (i.e. in the periphery). The stimuli were displayed on a screen in front of the scanner and viewed through a tilted mirror on the head coil. All stimuli were black on white background. The face and object stimuli (houses, tools) were high contrast grey-scale photographs that had been matched for size and luminance. The face images were of unknown people (12 females and 12 males) with neutral or happy expression, shown in frontal or slightly lateral view and with hair and occasionally accessories included (e.g. eyeglasses). The tools were 24 common handheld household tools (e.g. hammer and scissors). The houses included 24 frontal exterior views of unknown houses and buildings. The words were 24 common six-letter words in Danish (e.g. smykke and kontor), with every second word presented in uppercase. The control stimuli consisted of two circular images of a checkerboard that were presented in iteration to create the impression of a moving checkerboard.

Stimuli were presented in blocks of eight images from a category, displayed for 500 ms each with a variable ISI of around 500 ms (average ISI = 500 ms). Blocks started with a fixation cross (4 s) and an ISI of variable length (average ISI = 500 ms) with a total length of 12.5 s. Each image category (i.e. faces, houses, tools and words) contained 24 different images, which were divided into three sets (A, B, C) of eight images each. Set A was repeated three times and set B and C were each repeated six times. The first and last blocks were always checkerboards. The order of categories within sets as well as the order of images was randomized. The asterisk, to which participants were asked to press a button, was randomly displayed either below or above the presented stimuli in two trials out of eight trials in each block (i.e. 25% of all trials). The total time of the task (not including the introduction) was 14.2 min.

MRI acquisition

Scanning was conducted at Odense University Hospital, Denmark, on a Philips Achieva 3.0 Tesla MRI scanner. Whole-brain functional images were acquired using a gradient-echo planar imaging sequence [45 axial slices with 3 mm thickness and 2.625*2.625 mm in-plane resolution, repetition time (TR) = 2.5 s, echo time (TE) = 35 ms, flip angle: 90°]. For registration and localization purposes in this study, a high-resolution T1 weighted MPRAGE scan was acquired (TR = 8.2 ms, TE = 3.8 ms, flip angle = 8°, 190 sagittal slices with 1 mm thickness, in-plane resolution: 0.87*0.87 mm).

fMRI data pre-processing and analysis

Data pre-processing was performed using FMRI Expert Analysis Tool (FEAT) Version 6.00, from FMRIB's Software Library (Smith, 2004; Jenkinson *et al.*, 2012). Head motion was corrected using MCFLIRT (Jenkinson *et al.*, 2002), before linear trends and low-frequency drifts were removed (high-pass filter of 0.011 Hz).

Brain extraction tool (Smith, 2002) was used to remove non-brain tissue from the fMRI data. Spatial smoothing was performed using a Gaussian kernel filter with a full width at half maximum of 6 mm (SUSAN; Smith and Brady, 1997). FMRIB's Nonlinear Image Registration tool was used to register the participant's fMRI volumes to Montreal Neurological Institute (MNI) 152 standard space using the T1-weighted scan in an intermediate step to improve alignment. The T1-weighted volume had the skull and other non-brain tissue removed using Freesurfer 5.3 (<http://surfer.nmr.mgh.harvard.edu> (27 January 2019, date last accessed); Dale *et al.*, 1999; Fischl *et al.*, 1999).

Statistical analysis

Behavioural data

To examine whether the DP group performed differently than Control Group 1 on the face measures (CFMT, FEQ-FIR and CFPT), their scores were subjected to independent *t*-tests. The same procedure was applied to examine whether the DP group differed from Control

Group 2 on the object recognition (RT and A) and reading measures (RT and WLE). The 95% CIs and the independent *t*-tests were based on bias-corrected and accelerated bootstrapping (1000 samples). Bootstrapping is based on taking *n* random samples with replacement from the sample data and estimating properties of the sampling distribution from these samples. As an example, the 95% CI of the mean can be estimated by looking at the variance of the mean found across *n* (bootstrap) samples of equal size to the sample data. Compared with traditional parametric estimates, bootstrap estimates are less affected by bias (e.g. outliers and violations of homoscedasticity and normality).

Functional MRI

Individual level whole-brain analysis

Individual level whole-brain fixed-effects analysis was conducted using a general linear model with six regressors of interest: faces, houses, tools, words, checkerboards and response along with their temporal dispersion derivatives, in addition to six standard motion parameters from MCFLIRT and 18 motion derivatives (24 motion parameters in total) (no participants were excluded due to head motion). All predictors were convolved with a double-gamma canonical haemodynamic response function, and for main effects relative to baseline (e.g. faces vs. fixation, houses vs. fixation, etc.) *t*-contrasts were modelled for all regressors. To examine stimulus specific processing, the following three *t*-contrasts were conducted (i) Faces > Objects (houses + tools), (ii) Objects (houses + tools) > Words and (iii) Words > Objects (houses + tools). The corresponding fMRI contrasts parameter estimates (COPEs) were further explored within pre-defined ROIs. The choice to base contrasts on high-level conditions only, e.g. faces vs. objects, rather on a mixture of high- and low-level conditions, say faces vs. fixation, is that only high-level contrasts reflect category-sensitive activations whereas differences associated with mixed-level contrasts could reflect, for example, reduced processing of visual complex stimuli in general. This of course raises the possibility that group differences in, for example, face sensitivity could reflect both reduced activation for faces or increased activation for objects in the DP group compared with the control group. Such a possibility will always exist in fMRI studies given that the signal measured is relative to some other condition. Hence, it will also apply to contrasts based on fixation. Having said this, we have no reason to suspect that DP should be associated with a visual processing deficit causing activations to be higher for objects but lower for faces.

Group-level effects of task condition in healthy controls

In order to assess the validity of the experimental paradigm, we estimated group-level effects of task conditions

in the healthy control group using general linear models, and obtained non-parametric *P*-values corrected for multiple comparisons across space using randomize (Winkler *et al.*, 2014) with threshold-free cluster enhancement (Smith and Nichols, 2009) and 5000 permutations for each contrast.

Group ROI comparisons

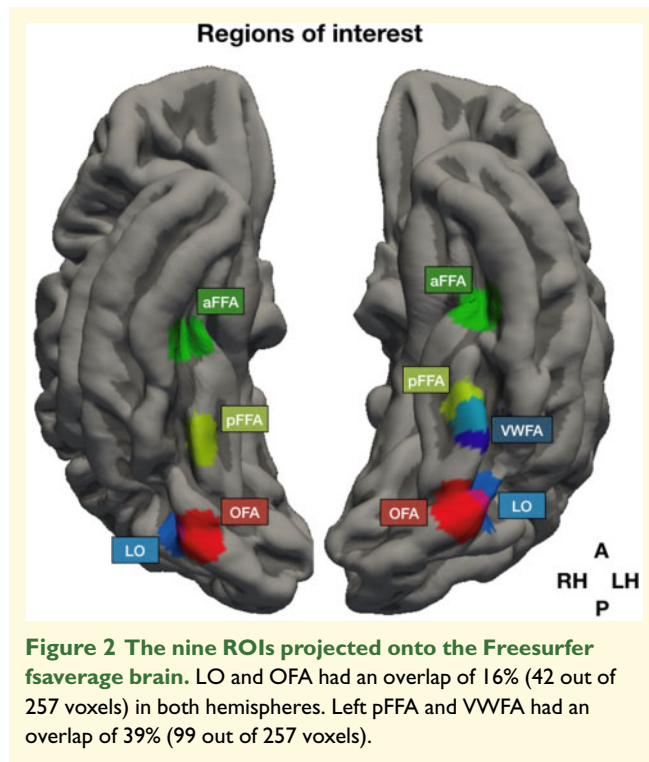
We examined group differences in six ROIs corresponding to the following ventral areas bilaterally in the face network: OFA, posterior FFA (pFFA) and anterior FFA [aFFA; by some also termed ATL (Jiahui *et al.*, 2018)]. The MNI co-ordinates for these ROIs were based on the mean co-ordinates for these areas as given in Zhen *et al.* (2015). In addition, we examined group differences in object sensitive areas LO bilaterally based on the mean co-ordinates (averaged over the right and left hemispheres) given in a meta-analysis by Emberson *et al.* (2017), and in the left VWFA based on the mean co-ordinate in the meta-analysis by Jobard *et al.* (2003). For the mean co-ordinates associated with each ROI, see Table 1.

The ROIs were defined by creating a binary single voxel mask centred on their respective co-ordinates. These voxels were further smoothed with a Gaussian kernel ($\sigma = 4$), and then thresholded at intensity 0.001, creating a spherical mask surrounding their respective centres. For illustration purposes, the ROIs were projected onto the Freesurfer fsaverage brain (see Fig. 2). Relevant COPEs were extracted using fslmeans in FMRIB's Software Library, creating, for each individual, an average COPE for each contrast for each ROI.

Statistical analyses were performed in SPSS (version 25). For each ROI, we conducted an analysis of covariance with COPE as the dependent variable, group (DP vs. control) as a fixed factor, and age and sex as covariates. For the six 'face' ROIs (left and right OFA, pFFA and aFFA), the relevant COPE was the contrast between activation to faces relative to objects; for the two 'object' ROIs (left and right LO), the relevant COPE was the contrast between activation to objects relative to words; and for the 'word' ROI (VWFA), the relevant COPE was the contrast between activation to words relative to objects. We computed effect sizes in terms of Cohen's *d*

Table 1 MNI co-ordinates for the nine ROIs used for assessing activation differences between developmental prosopagnosics and controls

	x	y	z
Left OFA	-41	-80	-12
Right OFA	43	-78	-13
Left pFFA	-40	-54	-20
Right pFFA	42	-52	-20
Left aFFA	-42	-26	-23
Right aFFA	43	-24	-25
Left LO	-42	-74	-4
Right LO	42	-74	-4
Left VWFA	-44	-58	-15



based on the raw COPE values. We corrected for multiple tests by controlling the false discovery rate at $q < 0.05$ (Benjamini and Hochberg, 1995). To further assess the robustness of the differences found, we conducted independent t -tests on the COPEs in the relevant ROIs using bias-corrected and accelerated bootstrapping (1000 samples).

Data availability

The authors confirm that the behavioural data supporting the findings of this study are available within the article and its [Supplementary material](#). The imaging data are available from the corresponding author, upon reasonable request.

Results

Behavioural tasks

As can be seen from [Table 2](#), the DP group was clearly impaired on all face measures but did not differ significantly from the controls with respect to object recognition and reading performance (for the individual scores, see [Supplementary Table 1](#)).

Functional MRI

Group-level effects of task condition in healthy controls

[Figure 3](#) shows the results from the voxel-wise (whole brain) analyses testing for main effects of task conditions

in the healthy control participants. In brief, the contrast Words > Objects was associated with increased activation in the left inferior frontal gyrus as well as in bilateral middle temporal gyrus, and decreased activation in the visual cortex, including the occipital parts of the fusiform gyri, the lingual gyri and the lateral occipital cortex. Faces > Objects was associated with increased activation in the right inferior division of the lateral occipital cortex and lateral parts of the right temporo-occipital fusiform cortex, and decreased activation bilaterally in medial parts of the temporo-occipital fusiform cortex (for a complete list of activated regions, see [Supplementary Table 2](#)). All findings are corrected for multiple comparisons using permutation testing and threshold-free cluster enhancement ($P < 0.05$).

Group ROI comparisons

[Table 3](#) and [Fig. 4](#) summarize the results from the ROI-based group comparisons (for information regarding the contrast parameter estimates in each ROI for each participant, see [Supplementary Table 3](#)). For the Faces > Objects contrast, the analysis of covariance revealed significantly higher activation in the control group in the left and right OFA and left FFA. In comparison, there were no significant group differences in the left and right LO for the Objects > Words contrast or in the (left) VWFA for the Words > Objects contrast.

As can be seen from [Table 3](#), the effects of group were numerically larger in the left than in the right OFA and FFA. However, *post hoc* mixed factorial analyses failed to find significant interactions between group and hemisphere in these regions [OFA: $F(1,47) = 0.59$, $P = 0.44$; FFA: $F(1,47) = 0.84$, $P = 0.37$].

Discussion

Two aspects of the present results are noteworthy: First, developmental prosopagnosics (DPs) show reduced brain activation in response to facial stimuli in posterior parts of the face network. Interestingly, this reduction was seen bilaterally and tended to be greater in the left than in the right hemisphere. Secondly, our analyses reveal no evidence of group differences in activation to orthographic material in the VWFA in the left hemisphere or to objects in LO bilaterally. These imaging results correspond with the behavioural pattern observed in the included DPs, who show preserved reading and recognition of line drawings, but severely impaired face recognition. A recent study suggested that DP is characterized by widespread selectivity reductions across category selective visual cortex (Jiahui *et al.*, 2018). Our results show that this does not apply for word selectivity in the VWFA, thus constraining hypotheses of a general deficit affecting category selective visual processing in DP.

The finding of reduced activation in posterior/mid (OFA/pFFA) rather than in anterior parts (aFFA) of the face network in individuals with DP is similar to what

Table 2 Behavioural differences between the DP group and the control groups on measures of face processing (FEQ-FIR, CFMT, CFPT), object recognition (ODT RT, A) and reading (RT, WLE)

	Developmental prosopagnosics <i>M</i> (SD)	Control participants <i>M</i> (SD)	<i>M</i> _{Dif}	95% CI ^a	<i>p</i> -level ^a	<i>d</i>
Faces and Emotion Questionnaire (FIR scale)	57.3 (7.8)	18.8 (11.3) ^b	38.5	32.9 to 43.9	0.001	3.81
Cambridge Face Memory Test (CFMT)	38.7 (3.6)	58.0 (7.4) ^b	-19.3	-22.5 to -16.1	0.001	3.03
Cambridge Face Perception Test (CFPT)	61.3 (15)	38.8 (14.0) ^b	22.5	13.9 to 30.9	0.001	1.61
Object Decision RT	955 (416)	828 (210) ^c	127	-76 to 349	0.276	0.45
Object Decision A	.952 (.035)	.958 (.023) ^c	-.006	-.013 to .025	0.559	0.22
Reading RT	557 (55)	545 (73) ^c	11.9	-25 to 47	0.524	0.18
Word length effect (WLE)	9 (11)	12 (12) ^c	-2.2	-4.4 to 9.0	0.536	0.19

^aBased on bias-corrected and accelerated bootstrap analysis (1000 samples).

^bControl Group 1.

^cControl Group 2.

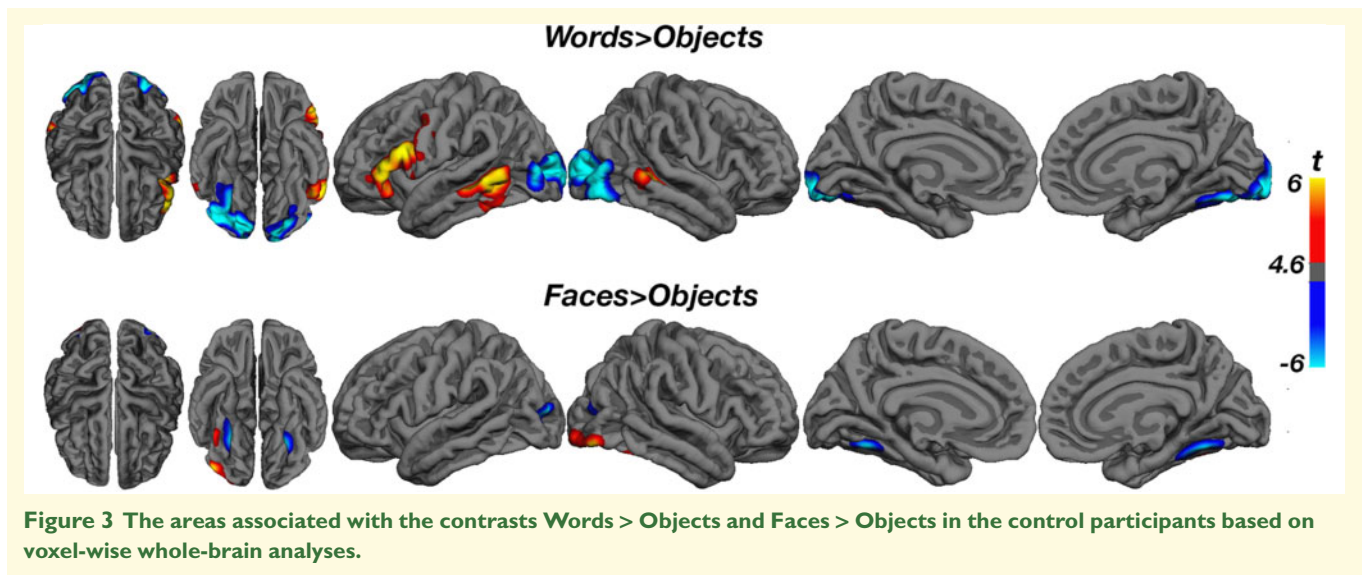


Figure 3 The areas associated with the contrasts Words > Objects and Faces > Objects in the control participants based on voxel-wise whole-brain analyses.

has been reported in previous studies (Dinkelacker et al., 2011; Furl et al., 2011; Jiahui et al., 2018). This may not be surprising considering that the aFFA/ATL is associated with processing of semantic and biographical information (Duchaine and Yovel, 2015; Rossion, 2015); information not accessed in the present paradigm. What is surprising is that the activation differences in face processing included left hemisphere regions and, although not statistically different, actually tended to be more pronounced in the left (both OFA and FFA) than in the right hemisphere (OFA only). Typically, the right hemisphere is considered dominant in terms of face processing, being associated with more and larger face-sensitive clusters than the left hemisphere (Kanwisher and Yovel, 2006; Zhen et al., 2015). Likewise, unilateral lesions to the right hemisphere also seems sufficient to cause acquired prosopagnosia (i.e. prosopagnosia following brain damage; Bouvier and Engel, 2006), although the disorder is more severe following more extensive right hemisphere damage or bilateral lesions (Barton, 2008). Indeed, some have argued that the left hemisphere might

contribute to but is not necessary for face perception (Rossion, 2014).

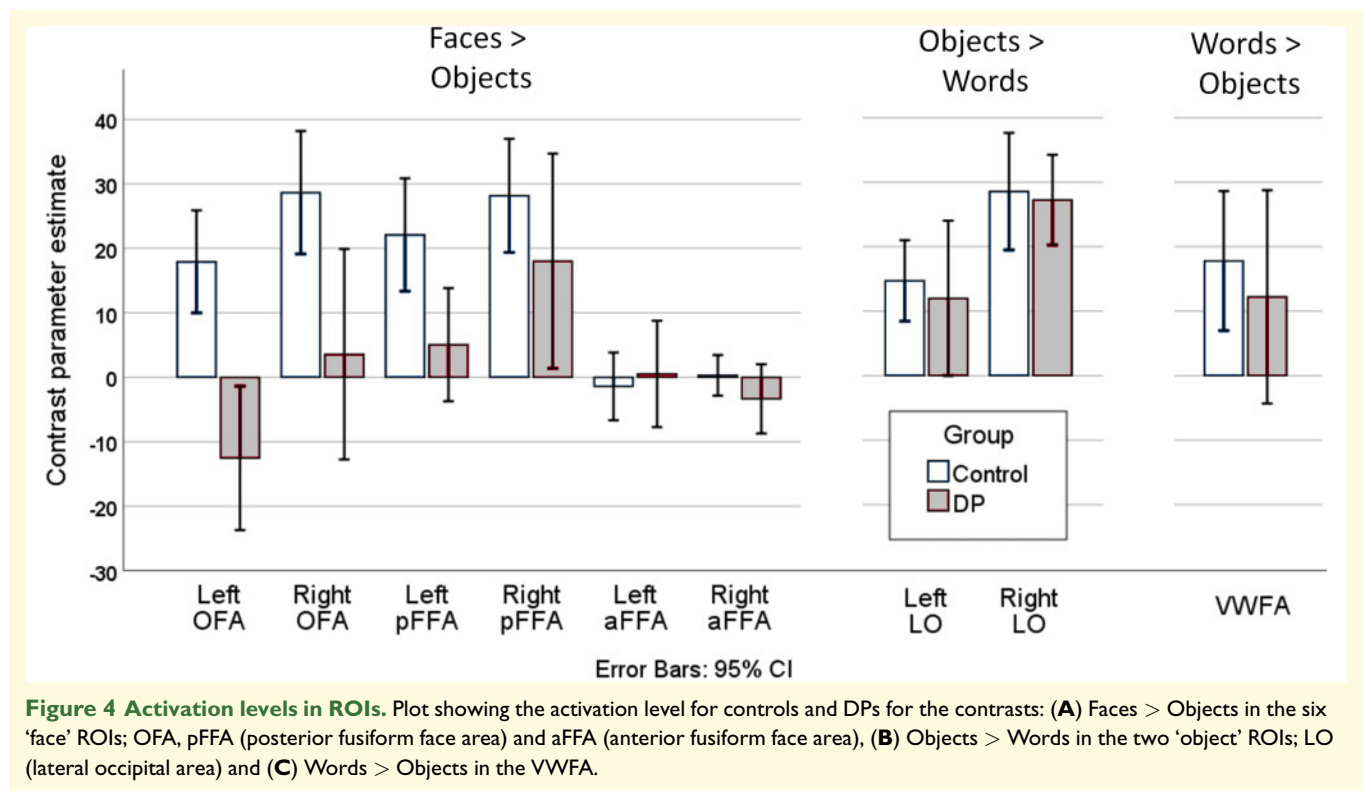
A closer look at the literature nevertheless suggest that abnormal activation of left hemisphere regions is just as common and pronounced in DP as involvement of right hemisphere regions, but while reported, these findings have largely been ignored. Dobel et al. (2008), for example, found that reduced activity in occipito-temporal areas in DP was especially prominent in the left hemisphere, and one of the largest fMRI studies conducted on DPs found decreased activity to faces compared with scrambled faces in left FFA, with no evidence of abnormal activation in either right FFA or right and left OFA (Dinkelacker et al., 2011). A number of other studies with DPs also indicate that the core ventral face regions in the left hemisphere may be important for efficient face processing, with DPs showing reduced activity in left hemispheric occipito-temporal areas, e.g. in left FFA (Avidan et al., 2005; Avidan and Behrmann, 2009; Minnebusch et al., 2009; Furl et al., 2011; Lohse et al., 2016) and left OFA (Minnebusch et al., 2009). Indeed,

Table 3 Activation differences between the DP group and Control group I in the 7 ROIs

	F^a	P -level ^a	False discovery rate significant	M_{Dir}	95% CI ^b	P -level ^b	d
Faces > Objects L. OFA	19.35	0.00007	Yes	30.5	16.2 to 43.7	0.001	1.41
Faces > Objects R. OFA	9.44	0.004	Yes	25.1	6.6 to 43.2	0.008	0.92
Faces > Objects L. pFFA	6.28	0.016	Yes	17.0	6.4 to 28.0	0.009	0.77
Faces > Objects R. pFFA	1.98	0.166	No	10.1	-8.0 to 29.2	0.243	0.39
Faces > Objects L. aFFA	0.07	0.788	No	-1.9	-11.9 to 6.9	0.683	0.13
Faces > Objects R. aFFA	1.46	0.233	No	3.7	-2.1 to 9.7	0.210	0.40
Objects > Words L. LO	0.31	0.578	No	2.7	-11.7 to 14.4	0.682	0.15
Objects > Words R. LO	0.00	0.979	No	1.3	-8.9 to 11.9	0.803	0.08
Words > Objects L. VWFA	0.21	0.646	No	5.6	-12.5 to 23.8	0.572	0.19

^aBased on analysis of covariance with sex and age as covariates.

^bBased on bias-corrected and accelerated bootstrap analysis (1000 samples).



the only study reporting abnormal fMRI activity exclusively in the right hemisphere did not test for group differences in the left hemisphere at all (Zhang *et al.*, 2015). The results reported by Jiahui *et al.* (2018) also indicate (greater) left hemisphere involvement with similar group differences in the left ($d = 0.88$) and right FFA ($d = 0.87$), and slightly stronger effect sizes in the left OFA ($P = 0.06$, $d = 0.57$) compared with the right ($P = 0.28$, $d = 0.32$).

It seems, then, that the left hemisphere abnormality is consistent enough across the literature to warrant an explanation, and we suggest that this has at least two implications. First, it challenges the proposition that the left hemisphere is not necessary for face perception (Rossion, 2014). While we cannot dismiss this possibility

entirely, because functional imaging alone is not suited for identifying which areas are critical for any cognitive process, the left > right asymmetry in DP, or at least the bilateral involvement, does suggest that the left hemisphere could be important for gaining normal efficiency in face recognition. This is consistent with other evidence suggesting that left FFA shows protracted development compared with the right FFA, increasing in face specialization from childhood to adulthood together with the left and right OFA (Joseph *et al.*, 2011; Joseph *et al.*, 2015). Interestingly, abnormal activation of OFA bilaterally and left FFA but not right FFA, the pattern we observe here in DP, has also been observed in adults who underwent removal of an eye (monocular enucleation) as children before their fourth year (Kelly *et al.*, 2019). On

a speculative note, this might imply that specialization of the right FFA in face processing is perhaps less dependent on (continued) experience than the left FFA and the right and left OFA. This brings us to the second implication. If the left hemisphere is important for *developing* a normal face recognition network, but is not *critical* for face recognition when this network has been established, this may explain why face recognition difficulties are typically less severe in DP than they are in acquired prosopagnosia (Rossion, 2018): The right-sided part of the face network may be less affected in DP than the left-sided part whereas the reverse is clearly true in acquired prosopagnosia following unilateral right hemisphere lesions. Nevertheless, while acquired prosopagnosia is most typically seen following right hemisphere lesions, it is as mentioned more severe with bilateral lesions (Barton, 2008), indicating that there are processes contributing significantly to face recognition in the left as well as the right hemisphere. Supporting this, studies of patients with acquired reading problems and lesions confined to *left* ventral temporo-occipital cortex have shown that these patients also have deficits in face processing (Behrmann and Plaut, 2014; Roberts et al., 2015), although less severe than those seen in acquired prosopagnosia.

The second aim of our study was to directly address potential differences in activation in the VWFA between DPs and controls. Activation patterns for words, and analyses looking directly at the VWFA, have not previously been reported in DP. This comparison becomes even more interesting as the key abnormalities we find in DP also involve the left hemisphere. During presentation of orthographic stimuli, however, we found no evidence of abnormal activation in the VWFA in DPs compared with controls. This pattern corresponds well with behavioural reports of preserved word processing in DP (Rubino et al., 2016; Burns et al., 2017; Starrfelt et al., 2018), and also with the present behavioural findings showing normal word reading RTs and WLEs in the DPs. This suggests that DP is not associated with reduced activation in category-sensitive areas in general; not even in areas like the VWFA which is located quite near/partially overlaps with the left pFFA where there was a clear difference in activation between groups. Like Jiahui et al. (2018), we also found no significant reductions in activation for the DPs in left or right LO during object processing.

The present finding of within normal range neural and behavioural responses to orthographic material in DP is not necessarily incompatible with the notion that other *and* associated deficits observed in DP may reflect individual differences in abnormal neural migration patterns (Susilo and Duchaine, 2013) or white matter integrity (Gray and Cook, 2018). It does, however, highlight a limitation of such broad-spectrum explanations of developmental disorders (Gray and Cook, 2018). They offer no principled account of which disorders should co-occur more frequently than others and why. It seems clear that developmental deficits in face recognition may occur

without preventing the acquisition of normal reading skills and development of a cerebral area supporting word recognition (the VWFA), and this suggests that a general deficit in neural migration across ventral occipito-temporal cortex is not a viable explanation for DP.

The division of labour between the hemispheres in visual processing has become a central point of dispute in recent years, in particular with regards to development of potential category-sensitive areas and cerebral competition/neuronal recycling of areas involved in face and word processing (Dehaene et al., 2010; Behrmann and Plaut, 2013; Ventura et al., 2013). While theories diverge on the assumed degree of category sensitivity in such areas, and the learning mechanisms involved, a core hypothesis is that learning to read may capitalize on cerebral areas involved in face recognition. In that light, it is interesting that we find clear differences between DPs and controls in left lateralized areas involved in face processing, but no difference in activation for words or in behavioural reading responses. This stands in contrast to patterns revealed in developmental dyslexia (a disorder affecting reading acquisition), where recent studies have revealed behavioural impairments in recognition of faces as well as words (Sigurdardottir et al., 2015; Gabay et al., 2017; Sigurdardottir et al., 2018; but see Robotham and Starrfelt, 2017). Correspondingly, using the same stimuli and paradigm as the current study, Monzalvo et al. (2012) found lower activation in the VWFA and right FFA, respectively, in dyslexic children. In comparison, then, DP appears as a more selective developmental deficit than dyslexia both in behavioural and anatomical terms. Whether the left hemisphere abnormalities in DP observed here are related to the suggested cerebral competition or neuronal recycling that may occur when learning to read will be a central question in future research. Further characterization of the unique contributions of left hemisphere areas in normal face recognition will also be helpful in understanding better how abnormalities in this part of the network may contribute to the behavioural deficits in face recognition seen in DP.

Supplementary material

Supplementary material is available at *Brain Communications* online.

Acknowledgements

We wish to thank Marlene Hjørre and Anca Friismose for their outstanding support during scanning, the Friends of Fakutsi Association and the subjects who participated. We thank Stanislas Dehaene for sharing the fMRI stimuli.

Funding

This project was supported by a grant from the Danish Research Council for Independent Research | Humanities

(grant no. DFF – 4001-00115), to C.G. and R.S. L.T.W. was supported by the European Research Council (ERC) under the European Union's Horizon 2020 research and innovation programme (ERC Starting Grant, Grant agreement No. 802998) and the Research Council of Norway (249795). D.A. was supported by the South-Eastern Norway Regional Health Authority (2019107).

Competing interests

The authors report no competing interests.

References

- Avidan G, Behrmann M. Functional MRI reveals compromised neural integrity of the face processing network in congenital prosopagnosia. *Curr Biol* 2009; 19: 1146–50.
- Avidan G, Hasson U, Malach R, Behrmann M. Detailed exploration of face-related processing in congenital prosopagnosia: 2. Functional neuroimaging findings. *J Cogn Neurosci* 2005; 17: 1150–67.
- Avidan G, Tanzer M, Hadj-Bouziane F, Liu N, Ungerleider LG, Behrmann M. Selective dissociation between core and extended regions of the face processing network in congenital prosopagnosia. *Cereb Cortex* 2014; 24: 1565–78.
- Barton JJ. Structure and function in acquired prosopagnosia: lessons from a series of 10 patients with brain damage. *J Neuropsychol* 2008; 2 (Pt 1): 197–225.
- Barton JJ, Corrow SL. The problem of being bad at faces. *Neuropsychologia* 2016; 89: 119–24.
- Behrmann M, Avidan G, Gao F, Black S. Structural imaging reveals anatomical alterations in inferotemporal cortex in congenital prosopagnosia. *Cereb Cortex* 2007; 17: 2354–63.
- Behrmann M, Plaut DC. Distributed circuits, not circumscribed centers, mediate visual recognition. *Trends Cogn Sci* 2013; 17: 210–9.
- Behrmann M, Plaut DC. Bilateral hemispheric processing of words and faces: evidence from word impairments in prosopagnosia and face impairments in pure alexia. *Cereb Cortex* 2014; 24: 1102–18.
- Benjamini Y, Hochberg Y. Controlling the false discovery rate: a practical and powerful approach to multiple testing. *J R Stat Soc Ser B* 1995; 57: 289–300.
- Bentin S, Degutis JM, D'Esposito M, Robertson LC. Too many trees to see the forest: performance, event-related potential, and functional magnetic resonance imaging manifestations of integrative congenital prosopagnosia. *J Cogn Neurosci* 2007; 19: 132–46.
- Biotti F, Gray KLH, Cook R. Impaired body perception in developmental prosopagnosia. *Cortex* 2017; 93: 41–9.
- Bouvier SE, Engel SA. Behavioral deficits and cortical damage loci in cerebral achromatopsia. *Cereb Cortex* 2006; 16: 183–91.
- Bowles DC, McKone E, Dawel A, Duchaine B, Palermo R, Schmalzl L, et al. Diagnosing prosopagnosia: effects of ageing, sex, and participant-stimulus ethnic match on the Cambridge Face Memory Test and Cambridge Face Perception Test. *Cogn Neuropsychol* 2009; 26: 423–55.
- Burns EJ, Bennetts RJ, Bate S, Wright VC, Weidemann CT, Tree JJ. Intact word processing in developmental prosopagnosia. *Sci Rep* 2017; 7: 1683.
- Campbell A, Tanaka JW. Decoupling category level and perceptual similarity in congenital prosopagnosia. *Cogn Neuropsychol* 2018; 35: 63–5.
- Cohen L, Dehaene S, Naccache L, Lehéricy S, Dehaene-Lambertz G, Henaff MA, et al. The visual word form area: spatial and temporal characterization of an initial stage of reading in normal subjects and posterior split-brain patients. *Brain* 2000; 123 (Pt 2): 291–307.
- Corrow JC, Corrow SL, Lee E, Pancaroglu R, Burles F, Duchaine B, et al. Getting lost: topographic skills in acquired and developmental prosopagnosia. *Cortex* 2016; 76: 89–103.
- Crawford JR, Garthwaite PH, Porter S. Point and interval estimates of effect sizes for the case-controls design in neuropsychology: rationale, methods, implementations, and proposed reporting standards. *Cogn Neuropsychol* 2010; 27: 245–60.
- Dale AM, Fischl B, Sereno MI. Cortical surface-based analysis. I. Segmentation and surface reconstruction. *NeuroImage* 1999; 9: 179–94.
- De Haan EH, Campbell R. A fifteen year follow-up of a case of developmental prosopagnosia. *Cortex* 1991; 27: 489–509.
- Dehaene S, Cohen L. The unique role of the visual word form area in reading. *Trends Cogn Sci* 2011; 15: 254–62.
- Dehaene S, Pegado F, Braga LW, Ventura P, Filho GN, Jobert A, et al. How learning to read changes the cortical networks for vision and language. *Science* 2010; 330: 1359–64.
- Dilks DD, Julian JB, Paunov AM, Kanwisher N. The occipital place area is causally and selectively involved in scene perception. *J Neurosci* 2013; 33: 1331–6a.
- Dinkelacker V, Gruter M, Klaver P, Gruter T, Specht K, Weis S, et al. Congenital prosopagnosia: multistage anatomical and functional deficits in face processing circuitry. *J Neurol* 2011; 258: 770–82.
- Dobel C, Putsche C, Zwitserlood P, Junghofer M. Early left-hemispheric dysfunction of face processing in congenital prosopagnosia: an MEG study. *PLoS One* 2008; 3: e2326.
- Downing PE, Jiang Y, Shuman M, Kanwisher N. A cortical area selective for visual processing of the human body. *Science* 2001; 293: 2470–3.
- Duchaine B. Developmental prosopagnosia. In: Calder AJ, Rhodes G, Haxby MK, J Johnson, editors. *The Oxford handbook of face perception*. Oxford: Oxford University Press; 2011. p. 821–38.
- Duchaine B, Germine L, Nakayama K. Family resemblance: ten family members with prosopagnosia and within-class object agnosia. *Cogn Neuropsychol* 2007; 24: 419–30.
- Duchaine B, Nakayama K. The Cambridge Face Memory Test: results for neurologically intact individuals and an investigation of its validity using inverted face stimuli and prosopagnosic participants. *Neuropsychologia* 2006; 44: 576–85.
- Duchaine B, Parker H, Nakayama K. Normal recognition of emotion in a prosopagnosic. *Perception* 2003; 32: 827–38.
- Duchaine B, Yovel G. A revised neural framework for face processing. *Annu Rev Vis Sci* 2015; 1: 393–416.
- Duchaine B, Yovel G, Butterworth EJ, Nakayama K. Prosopagnosia as an impairment to face-specific mechanisms: elimination of the alternative hypotheses in a developmental case. *Cogn Neuropsychol* 2006; 23: 714–47.
- Emberson LL, Crosswhite SL, Richards JE, Aslin RN. The lateral occipital cortex is selective for object shape, not texture/color, at six months. *J Neurosci* 2017; 37: 3698–703.
- Epstein R, Kanwisher N. A cortical representation of the local visual environment. *Nature* 1998; 392: 598–601.
- Fields RD. White matter in learning, cognition and psychiatric disorders. *Trends Neurosci* 2008; 31: 361–70.
- Fischl B, Sereno MI, Dale AM. Cortical surface-based analysis. II: Inflation, flattening, and a surface-based coordinate system. *NeuroImage* 1999; 9: 195–207.
- Freeman P, Palermo R, Brock J. Faces and Emotion Questionnaire; 2015. <https://doi.org/10.6084/m9.figshare.1501441>.
- Furl N, Garrido L, Dolan RJ, Driver J, Duchaine B. Fusiform gyrus face selectivity relates to individual differences in facial recognition ability. *J Cogn Neurosci* 2011; 23: 1723–40.
- Gabay Y, Dundas E, Plaut D, Behrmann M. Atypical perceptual processing of faces in developmental dyslexia. *Brain Lang* 2017; 173: 41–51.
- Garrido L, Furl N, Draganski B, Weiskopf N, Stevens J, Tan GC, et al. Voxel-based morphometry reveals reduced grey matter volume in the temporal cortex of developmental prosopagnosics. *Brain* 2009; 132 (Pt 12): 3443–55.

- Gauthier I, Tarr MJ, Moylan J, Skudlarski P, Gore JC, Anderson AW. The fusiform “face area” is part of a network that processes faces at the individual level. *J Cogn Neurosci* 2000; 12: 495–504.
- Gerlach C, Klargaard SK, Starrfelt R. On the relation between face and object recognition in developmental prosopagnosia: no dissociation but a systematic association. *PLoS One* 2016; 11: e0165561.
- Gerlach C, Lissau CH, Hildebrandt NK. On defining and interpreting dissociations. *Cogn Neuropsychol* 2018; 35: 66–9.
- Geskin J, Behrmann M. Congenital prosopagnosia without object agnosia? A literature review. *Cogn Neuropsychol* 2018; 35: 4–54.
- Gomez J, Pestilli F, Witthoft N, Golarai G, Liberman A, Poltoratski S, et al. Functionally defined white matter reveals segregated pathways in human ventral temporal cortex associated with category-specific processing. *Neuron* 2015; 85: 216–27.
- Gray KLH, Cook R. Should developmental prosopagnosia, developmental body agnosia, and developmental object agnosia be considered independent neurodevelopmental conditions? *Cogn Neuropsychol* 2018; 35: 59–62.
- Grill-Spector K. The neural basis of object perception. *Curr Opin Neurobiol* 2003; 13: 159–66.
- Grill-Spector K, Kourtzi Z, Kanwisher N. The lateral occipital complex and its role in object recognition. *Vision Res* 2001; 41: 1409–22.
- Grueter M, Grueter T, Bell V, Horst J, Laskowski W, Sperling K, et al. Hereditary prosopagnosia: the first case series. *Cortex* 2007; 43: 734–49.
- Hadjikhani N, de Gelder B. Neural basis of prosopagnosia: an fMRI study. *Hum Brain Mapp* 2002; 16: 176–82.
- Hasson U, Avidan G, Deouell LY, Bentin S, Malach R. Face-selective activation in a congenital prosopagnosic subject. *J Cogn Neurosci* 2003; 15: 419–31.
- Haxby JV, Hoffman EA, Gobbini MI. The distributed human neural system for face perception. *Trends Cogn Sci* 2000; 4: 223–33.
- Haxby JV, Ungerleider LG, Clark VP, Schouten JL, Hoffman EA, Martin A. The effect of face inversion on activity in human neural systems for face and object perception. *Neuron* 1999; 22: 189–99.
- Hendel RK, Starrfelt R, Gerlach C. The good, the bad, and the average: characterizing the relationship between face and object processing across the face recognition spectrum. *Neuropsychologia* 2019; 124: 274–84.
- Jenkinson M, Bannister P, Brady M, Smith S. Improved optimization for the robust and accurate linear registration and motion correction of brain images. *NeuroImage* 2002; 17: 825–41.
- Jenkinson M, Beckmann CF, Behrens TE, Woolrich MW, Smith SM. FSL. *NeuroImage* 2012; 62: 782–90.
- Jiahui G, Yang H, Duchaine B. Developmental prosopagnosics have widespread selectivity reductions across category-selective visual cortex. *Proc Natl Acad Sci U S A* 2018; 115: E6418–27.
- Jobard G, Crivello F, Tzourio-Mazoyer N. Evaluation of the dual route theory of reading: a metanalysis of 35 neuroimaging studies. *NeuroImage* 2003; 20: 693–712.
- Joseph JE, Gathers AD, Bhatt RS. Progressive and regressive developmental changes in neural substrates for face processing: testing specific predictions of the Interactive Specialization account. *Dev Sci* 2011; 14: 227–41.
- Joseph JE, Zhu X, Gundran A, Davies F, Clark JD, Ruble L, et al. Typical and atypical neurodevelopment for face specialization: an fMRI study. *J Autism Dev Disord* 2015; 45: 1725–41.
- Kanwisher N, McDermott J, Chun MM. The fusiform face area: a module in human extrastriate cortex specialized for face perception. *J Neurosci* 1997; 17: 4302–11.
- Kanwisher N, Yovel G. The fusiform face area: a cortical region specialized for the perception of faces. *Phil Trans R Soc B* 2006; 361: 2109–28.
- Kelly KR, Gallie BL, Steeves J. Early monocular enucleation selectively disrupts neural development of face perception in the occipital face area. *Exp Eye Res* 2019; 183: 57–61.
- Klargaard SK, Starrfelt R, Petersen A, Gerlach C. Topographic processing in developmental prosopagnosia: preserved perception but impaired memory of scenes. *Cogn Neuropsychol* 2016; 33: 405–13.
- Lee Y, Duchaine B, Wilson HR, Nakayama K. Three cases of developmental prosopagnosia from one family: detailed neuropsychological and psychophysical investigation of face processing. *Cortex* 2010; 46: 949–64.
- Lohse M, Garrido L, Driver J, Dolan RJ, Duchaine BC, Furl N. Effective connectivity from early visual cortex to posterior occipito-temporal face areas supports face selectivity and predicts developmental prosopagnosia. *J Neurosci* 2016; 36: 3821–8.
- McConachie HR. Developmental prosopagnosia. A single case report. *Cortex* 1976; 12: 76–82.
- Minnebusch DA, Suchan B, Koster O, Daum I. A bilateral occipito-temporal network mediates face perception. *Behav Brain Res* 2009; 198: 179–85.
- Monzalvo K, Fluss J, Billard C, Dehaene S, Dehaene-Lambertz G. Cortical networks for vision and language in dyslexic and normal children of variable socio-economic status. *NeuroImage* 2012; 61: 258–74.
- Nestor A, Plaut DC, Behrmann M. Unraveling the distributed neural code of facial identity through spatiotemporal pattern analysis. *Proc Natl Acad Sci U S A* 2011; 108: 9998–10003.
- Peelen MV, Downing PE. Selectivity for the human body in the fusiform gyrus. *J Neurophysiol* 2005; 93: 603–8.
- Price CJ, Friston KJ. Scanning patients with tasks they can perform. *Hum Brain Mapp* 1999; 8: 102–8.
- Rajimehr R, Young JC, Tootell RB. An anterior temporal face patch in human cortex, predicted by macaque maps. *Proc Natl Acad Sci U S A* 2009; 106: 1995–2000.
- Ramus F. Neurobiology of dyslexia: a reinterpretation of the data. *Trends Neurosci* 2004; 27: 720–6.
- Righart R, de Gelder B. Impaired face and body perception in developmental prosopagnosia. *Proc Natl Acad Sci U S A* 2007; 104: 17234–8.
- Rivolta D, Lawson RP, Palermo R. More than just a problem with faces: altered body perception in a group of congenital prosopagnosics. *Q J Exp Psychol (Hove)* 2017; 70: 276–86.
- Rivolta D, Woolgar A, Palermo R, Butko M, Schmalzl L, Williams MA. Multi-voxel pattern analysis (MVPA) reveals abnormal fMRI activity in both the “core” and “extended” face network in congenital prosopagnosia. *Front Hum Neurosci* 2014; 8: 925.
- Roberts DJ, Lambon Ralph MA, Kim E, Tainturier MJ, Beeson PM, Rapcsak SZ, et al. Processing deficits for familiar and novel faces in patients with left posterior fusiform lesions. *Cortex* 2015; 72: 79–96.
- Robotham RJ, Starrfelt R. Face and word recognition can be selectively affected by brain injury or developmental disorders. *Front Psychol* 2017; 8: 1547.
- Rosenthal G, Tanzer M, Simony E, Hasson U, Behrmann M, Avidan G. Altered topology of neural circuits in congenital prosopagnosia. *Elife* 2017; 6: e25069.
- Rossion B. Understanding face perception by means of prosopagnosia and neuroimaging. *Front Biosci* 2014; 6: 258–307.
- Rossion B. Face perception. In: Toga AW, editor. *Brain mapping: an encyclopedic reference*. Amsterdam: Academic Press, Elsevier. Vol. 2. 2015. p. 515–22.
- Rossion B. Prosopagnosia? What could it tell us about the neural organization of face and object recognition? *Cogn Neuropsychol* 2018; 35: 98–101.
- Rubino C, Corrow SL, Corrow JC, Duchaine B, Barton JJ. Word and text processing in developmental prosopagnosia. *Cogn Neuropsychol* 2016; 33: 315–28.
- Schmalzl L, Palermo R, Coltheart M. Cognitive heterogeneity in genetically based prosopagnosia: a family study. *J Neuropsychol* 2008; 2 (Pt 1): 99–117.
- Sigurdardottir HM, Fridriksdottir LE, Gudjonsdottir S, Kristjansson A. Specific problems in visual cognition of dyslexic readers: face discrimination deficits predict dyslexia over and above discrimination of scrambled faces and novel objects. *Cognition* 2018; 175: 157–68.

- Sigurdardottir HM, Ivarsson E, Kristinsdottir K, Kristjansson A. Impaired recognition of faces and objects in dyslexia: evidence for ventral stream dysfunction? *Neuropsychology* 2015; 29: 739–50.
- Smith SM. Fast robust automated brain extraction. *Hum Brain Mapp* 2002; 17: 143–55.
- Smith SM. Overview of fMRI analysis. *Br J Radiol* 2004; 77 (Spec No 2): S167–75.
- Smith SM, Brady JM. SUSAN—a new approach to low level image processing. *Int J Comput Vision* 1997; 23: 45–78.
- Smith SM, Nichols TE. Threshold-free cluster enhancement: addressing problems of smoothing, threshold dependence and localisation in cluster inference. *NeuroImage* 2009; 44: 83–98.
- Song S, Garrido L, Nagy Z, Mohammadi S, Steel A, Driver J, et al. Local but not long-range microstructural differences of the ventral temporal cortex in developmental prosopagnosia. *Neuropsychologia* 2015a; 78: 195–206.
- Song Y, Zhu Q, Li J, Wang X, Liu J. Typical and atypical development of functional connectivity in the face network. *J Neurosci* 2015b; 35: 14624–35.
- Starrfelt R, Klargaard SK, Petersen A, Gerlach C. Reading in developmental prosopagnosia: evidence for a dissociation between word and face recognition. *Neuropsychology* 2018; 32: 138–47.
- Susilo T, Duchaine B. Advances in developmental prosopagnosia research. *Curr Opin Neurobiol* 2013; 23: 423–9.
- Thomas C, Avidan G, Humphreys K, Jung KJ, Gao F, Behrmann M. Reduced structural connectivity in ventral visual cortex in congenital prosopagnosia. *Nat Neurosci* 2009; 12: 29–31.
- Van den Stock J, van de Riet WA, Righart R, de Gelder B. Neural correlates of perceiving emotional faces and bodies in developmental prosopagnosia: an event-related fMRI-study. *PLoS One* 2008; 3: e3195.
- Ventura P, Fernandes T, Cohen L, Morais J, Kolinsky R, Dehaene S. Literacy acquisition reduces the influence of automatic holistic processing of faces and houses. *Neurosci Lett* 2013; 554: 105–9.
- Williams MA, Berberovic N, Mattingley JB. Abnormal fMRI adaptation to unfamiliar faces in a case of developmental prosopagnosia. *Curr Biol* 2007; 17: 1259–64.
- Winkler AM, Ridgway GR, Webster MA, Smith SM, Nichols TE. Permutation inference for the general linear model. *NeuroImage* 2014; 92: 381–97.
- Zhang J, Liu J, Xu Y. Neural decoding reveals impaired face configural processing in the right fusiform face area of individuals with developmental prosopagnosia. *J Neurosci* 2015; 35: 1539–48.
- Zhang J, Mueller ST. A note on ROC analysis and non-parametric estimate of sensitivity. *Psychometrika* 2005; 70: 203–12.
- Zhao Y, Li J, Liu X, Song Y, Wang R, Yang Z, et al. Altered spontaneous neural activity in the occipital face area reflects behavioral deficits in developmental prosopagnosia. *Neuropsychologia* 2016; 89: 344–55.
- Zhao Y, Zhen Z, Liu X, Song Y, Liu J. The neural network for face recognition: insights from an fMRI study on developmental prosopagnosia. *NeuroImage* 2018; 169: 151–61.
- Zhen Z, Yang Z, Huang L, Kong XZ, Wang X, Dang X, et al. Quantifying interindividual variability and asymmetry of face-selective regions: a probabilistic functional atlas. *NeuroImage* 2015; 113: 13–25.