

# Intra-articular Anterior Cruciate Ligament Reconstruction With Extra-articular Lateral Tenodesis of the Iliotibial Band

João Luiz Ellera Gomes, M.D., Ph.D., Murilo Anderson Leie, M.D., Marcos Marczwski, M.D., George Sánchez, B.S., and Márcio Balbinotti Ferrari, M.D.

**Abstract:** An increasing concern has been given to the rotation stability of the knee in the setting of an anterior cruciate ligament (ACL) reconstruction. This growing interest stems from a better understanding of the rotational stability of the knee afforded by the identification of the anterolateral ligament. Previously, a residual abnormal pivot-shift test had been found after an anatomic single-band reconstruction of the ACL because of a lack of rotational stability, which may lead to the development of osteoarthritis. Residual instability affects function, especially in high-demand athletes who perform many flexion-rotation movements during sporting activity. The purpose of this Technical Note is to describe our preferred method of intra-articular ACL reconstruction using a hamstring tendon autograft in combination with an extra-articular iliotibial band tenodesis for reinforcement of rotational stability.

Full restoration to preinjury function and quality of life after an anterior cruciate ligament (ACL) reconstruction (ACLR) has been shown to be jeopardized because of a lack of rotational stability confirmed through a residual positive pivot shift test at postoperative physical examination.<sup>1,2</sup> Although operative treatment, regardless of technique, provides acceptable anterior knee stability in the majority of the cases after ACLR, residual rotational instability in some cases demonstrates the lack of an isolated ACLR to definitively reproduce preinjury knee stability.<sup>3</sup> Moreover, rotational instability in the setting of an ACLR may result in an inability to return to play at an athlete's preinjury level.<sup>2</sup>

As a result, intra-articular ACLR has been previously done in conjunction with an extra-articular lateral tenodesis of the iliotibial band (ITB) for reinforcement of rotational stability.<sup>3</sup> However, the prevalence of this coupled technique has declined in the recent past given the steep learning curve, length of the incision/scar, and challenging postoperative rehabilitation associated with the technique. Currently, studies suggest that rotational instability after an ACLR may be due to the injury of a newly discovered structure known as the anterolateral ligament (ALL).<sup>4</sup> However, many remain skeptical concerning the exact definition of the structure and do not

From the Hospital de Clínicas de Porto Alegre (J.L.E.G., M.A.L., M.M., M.B.F.), Porto Alegre, Rio Grande do Sul, Brazil; and Steadman Philippon Research Institute (G.S.), Vail, Colorado, U.S.A.

The investigation was performed at the Hospital de Clínicas de Porto Alegre, Brazil.

The authors report that they have no conflicts of interest in the authorship and publication of this article. Full ICMJE author disclosure forms are available for this article online, as [supplementary material](#).

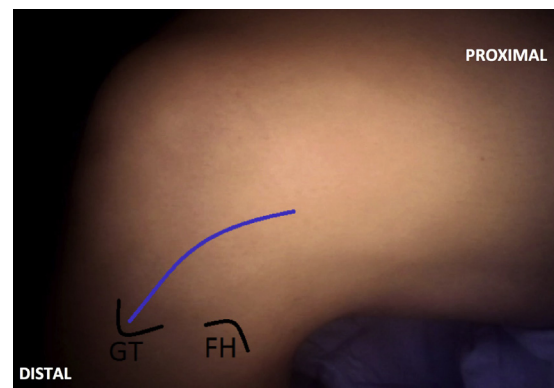
Received February 14, 2017; accepted May 2, 2017.

Address correspondence to João Luiz Ellera Gomes, M.D., Ph.D., Rua Ramiro Barcelos, 2350—Santa Cecília 90035-903, Porto Alegre, Rio Grande do Sul, Brazil. E-mail: [joelgo.voy@terra.com.br](mailto:joelgo.voy@terra.com.br)

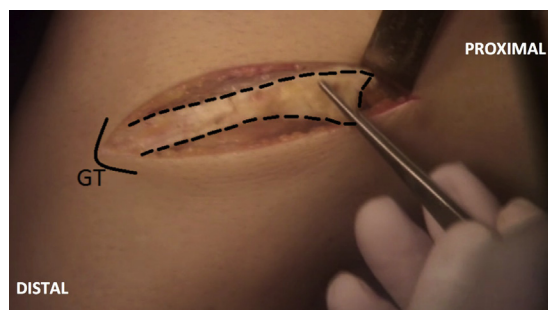
© 2017 by the Arthroscopy Association of North America. Published by Elsevier. This is an open access article under the CC BY-NC-ND license (<http://creativecommons.org/licenses/by-nc-nd/4.0/>).

2212-6287/17193

<http://dx.doi.org/10.1016/j.eats.2017.05.032>



**Fig 1.** The Gerdy tubercle (GT) is palpated and a curved skin incision (blue line) is performed starting 2 cm proximal to the GT and extending 10 cm proximally and slightly posterior to the femoral axis in the left knee. (FH, fibular head.)



**Fig 2.** After the initial skin incision performed in the left knee, the subcutaneous tissue is bluntly dissected. The iliotibial band (ITB) is exposed and a 10-cm-long and 1-cm-wide strip of ITB (dotted black line) is released using a coagulator. Care must be taken to avoid damage to the capsule and preserve the distal attachment of the ITB onto the Gerdy tubercle (GT).

support the claim that it is a ligament.<sup>5</sup> The ALL is located on the prominence of the lateral femoral epicondyle, slightly anterior to the origin of the lateral collateral ligament (LCL), and assumes an oblique course into the proximal anterolateral aspect of the tibia.<sup>6</sup> This position corresponds to the exact placement of the graft during a lateral tenodesis procedure.<sup>7-13</sup> Ultimately, lateral tenodesis of the ITB can provide a better leverage arm in very rotationally unstable knees, thereby severely limiting anterolateral mobility unlike an isolated intra-articular ACLR.<sup>3,14</sup> The purpose of this Technical Note is to describe our preferred method of intra-articular ACLR using a hamstring tendon autograft in combination with an extra-articular ITB tenodesis for reinforcement of rotational stability.

## Surgical Technique

### Patient Positioning

The patient is placed supine on the surgical table (Video 1). After induction of general anesthesia, a thigh tourniquet is placed on the proximal aspect of the operative limb. The knee is then prepared and draped in a sterile fashion. After this, the surgical limb is exsanguinated, and then the tourniquet is inflated to 250 to 350 mmHg.

### Harvesting and Preparing the Hamstring Tendon

An oblique 5-cm incision is performed at the anteromedial portion of the proximal tibia, directly over the pes anserinus. The subcutaneous tissue is then bluntly dissected using Metzenbaum scissors, thereby exposing the tendon insertion. The semitendinosus and gracilis tendons are then carefully isolated and all adhesions are removed. A tendon stripper (Smith & Nephew, Andover, MA) is used to harvest the 2 tendons individually. After this, the 2 harvested portions of the tendon are transferred to the back table and prepared through use of a

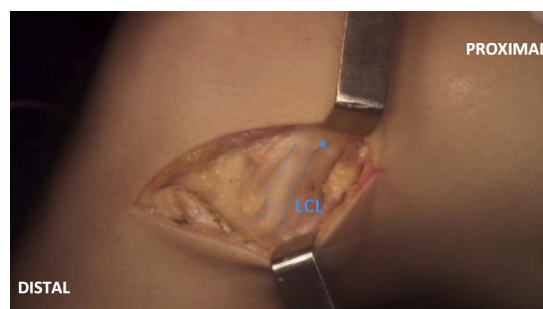
tendon workstation (Arthrex, Naples, FL). A quadruple-band, 12-cm-long and 8- to 10-mm-thick autograft is prepared through use of absorbable Vicryl suture (Ethicon, Somerville, NJ) at the proximal portion and no. 2.0 nonabsorbable Ethibond suture (Ethicon) at the distal portion of the graft. After this, the autograft is pre-tensioned for approximately 5 minutes and then kept in physiological saline solution until its eventual use.

### Harvest and Preparation of the ITB Strip

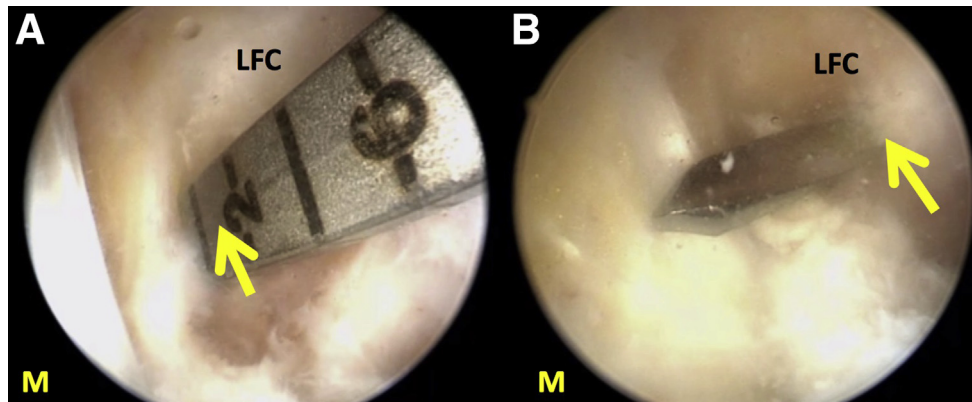
After the harvest of the hamstring autograft, attention is turned to the exposure of the ITB to complete the lateral tenodesis. A curved incision is performed, starting from 2 cm proximal to the Gerdy tubercle (GT) and extending 10 cm proximally and slightly posterior to the femoral axis (Fig 1). The subcutaneous tissue is then bluntly dissected and the ITB is thoroughly exposed. Using a coagulator, a strip of ITB to be removed, measuring 10 cm long and 1 cm wide, is outlined (Fig 2), with its corresponding incision done from posterior to anterior. The proximal tip is then carefully detached from the rest of the ITB whereas the distal insertion on GT remains intact. After this, no. 5.0 nonabsorbable Ethibond suture (Ethicon) is whip-stitched through the final 30 mm of the proximal portion of the strip. The strip of ITB is then kept in the subcutaneous tissue layer to minimize contact with the skin layer and risk of graft dehydration. The lateral epicondyle and LCL are then carefully dissected with Metzenbaum scissors to identify the location where the strip of ITB shall be positioned. We suggest that the strip of ITB be placed at the prominence of the lateral epicondyle, slightly posterior and proximal to the origin of the LCL (Fig 3). Care must be taken to avoid potential damage of the knee capsule given that a disturbance in the capsule will result in fluid leakage during ACLR completed through arthroscopy.

### Femoral Tunnel Preparation

Once the strip of ITB has been secured to the prominence of the lateral epicondyle, ACLR may be



**Fig 3.** To ensure the correct position of the lateral tenodesis fixation in the left knee, the lateral collateral ligament (dotted blue line) is identified. Then, a proximal and slightly posterior point is marked (\*) as the location where the formation of the outside-in femoral tunnel will take place.



**Fig 4.** Visualization of the lateral femoral condyle of the left knee is achieved using a 30° arthroscope through the anterolateral portal. An outside-in femoral guide (Arthrex) is placed on the anterior cruciate ligament (ACL) footprint on the medial wall of the lateral femoral condyle (yellow arrow, A). A no. 2.0 guide pin is introduced at this point while the intra-articular position of the ACL is arthroscopically confirmed (B). (L, lateral; LFC, lateral femoral condyle; M, medial.)

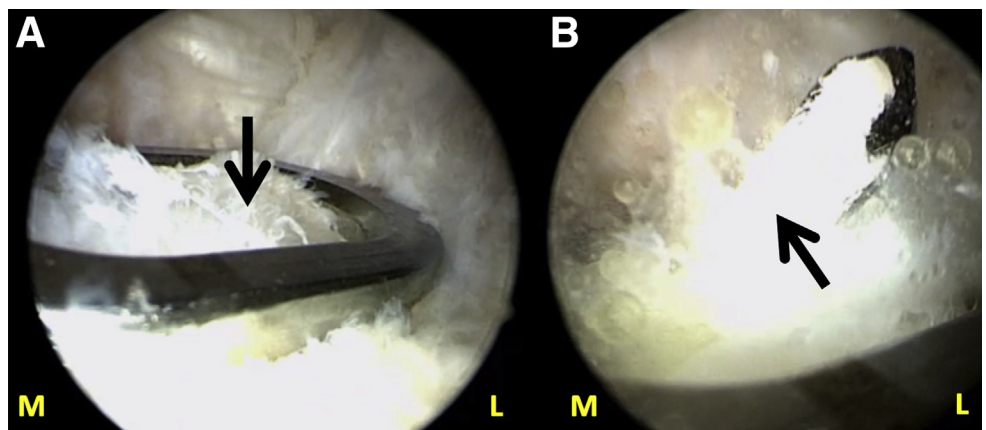
completed. First, an anterolateral portal is created in standard fashion. A 30° arthroscope (Smith & Nephew) is then inserted. After this, an anteromedial portal is created under direct visualization. A diagnostic arthroscopy is initially performed throughout all compartments. If any previously unidentified injury is recognized, it is addressed at this point. Afterward, the femoral footprint is exposed and identified. An outside-in femoral guide (Arthrex) is then introduced through the anterolateral portal with its tip placed exactly on the anatomic insertion of the ACL at the medial wall of the lateral femoral condyle. The insertion is located 5 mm anterior to the posterior femoral cortex and 5 mm inferior to the intercondylar roof at the 1- to 2-o'clock position on the left knee. The external portion of the guide is then positioned slightly posterior and proximal to the LCL proximal attachment. After this, the guide is placed in an oblique position approximately 15° to 20° anterior in the axial plane and 90° in the coronal plane to avoid damage to the posterior cortex of the femur.

Once the knee is flexed more than 120°, a 2.0-mm guidewire is drilled in an outside-in direction through use of the guide. The intra-articular position of the guidewire is then further shaped through arthroscopy (Fig 4). A cannulated femoral drill with the same diameter as the hamstring autograft to be inserted (Arthrex) is then used to prepare the femoral tunnel. Any remaining bony debris around and inside the femoral tunnel is then removed through use of a soft tissue shaver (Dyonics; Smith & Nephew). Once the femoral tunnel is finalized, the lateral posterior femoral condyle wall is inspected to ensure that it is intact.

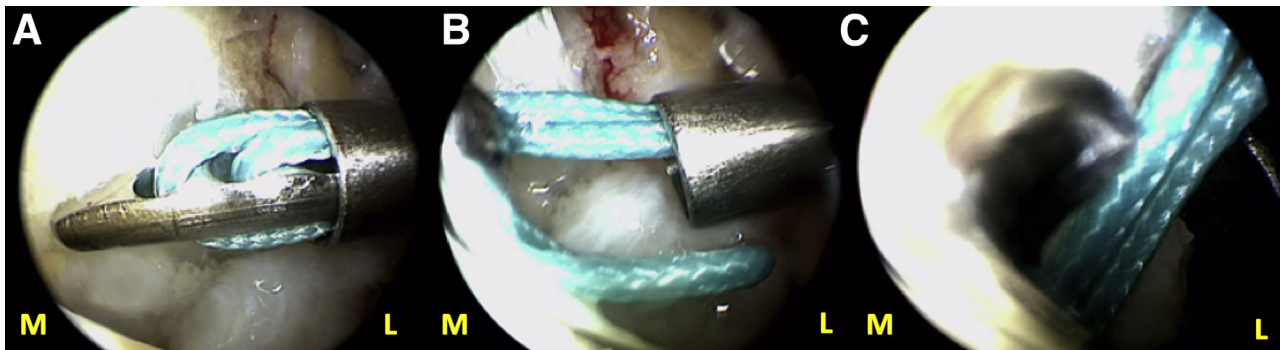
#### Tibial Tunnel Preparation

A C-shaped tibial guide (Arthrex) set at 50° to 55° is introduced through the anteromedial portal and placed on the ACL footprint of the tibia. Any ACL remnant around the tibial insertion is preserved to stimulate graft consolidation. The external portion of the guide is then positioned over the previous incision on the

**Fig 5.** Arthroscopic knee visualization of the left knee is achieved using a 30° arthroscope through the anterolateral portal. After identification of the tibial footprint of the anterior cruciate ligament (ACL, black arrow), a tibial C-shaped guide (Arthrex) set at 50°-55° is introduced through the anteromedial portal with its tip placed over the footprint (A). A guide pin is then introduced (B) into the footprint. (L, lateral; M, medial.)







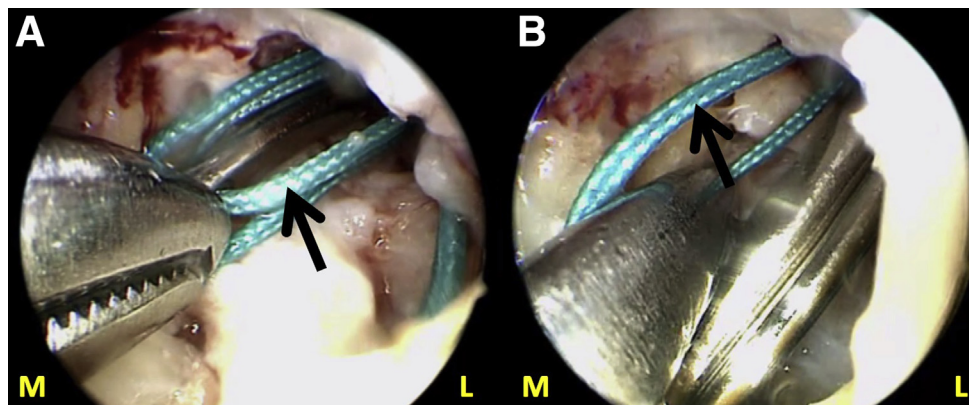
**Fig 6.** A passing suture is introduced in an outside-in direction into the left knee through the previously formed femoral tunnel (A). Then, it is retrieved (B, C) through the anteromedial arthroscopic portal while viewing through the anterolateral portal using a 30° arthroscope through use of a Kocher clamp or arthroscopic grasper. After this, the suture will be used to pull the hamstring autograft through the tibial and femoral tunnels prior to fixation. (L, lateral; M, medial.)

anteromedial aspect of the tibia for harvest of the autograft. The guide is positioned 45° in relation to the tibial axis in the coronal plane and parallel to the femoral axis. The knee is maintained at 90° of flexion while the guide pin is drilled. Once the optimal position is confirmed, based on the surgeon's judgment, the tibial drill (Arthrex) is used to prepare the tunnel (Fig 5).

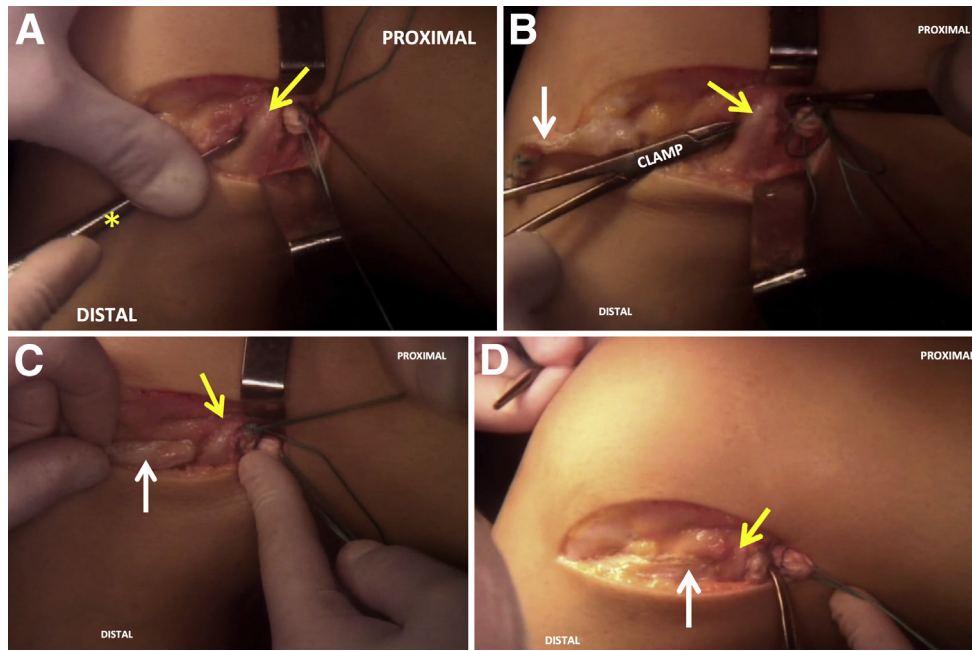
#### Passage of the Hamstring Autograft and Strip of ITB

A passing suture is first passed in an outside-in direction through the femoral tunnel and retrieved through the anteromedial portal using an arthroscopic grasper. Once retrieved, the passing suture is passed through the tibial tunnel using a grasper (Fig 6). Then, a second passing suture is introduced in an outside-in direction through the femoral tunnel and then retrieved through the anteromedial portal using the arthroscopic grasper (Fig 7).

First, the hamstring autograft is passed through use of the first passing suture. Under arthroscopic visualization, the graft is placed inside the femoral tunnel. After this, the location of the proximal 30 mm of the graft within the tunnel is verified. At this point, the arthroscopic portion of the procedure is briefly interrupted to create a soft tunnel underneath the LCL using a Penfield dissector and/or osteotomes. The second passing suture is then passed through this newly created tunnel to allow for the passage of the strip of ITB. Once this is complete, the strip of ITB is passed directly underneath the LCL and introduced inside the femoral tunnel (Fig 8). As the hamstring autograft is held in place to ensure its optimal position, the assistant retrieves the second passing suture through the anteromedial portal to deliver the strip of ITB through the femoral tunnel. Prior to definitive fixation, the positioning of the grafts is verified.



**Fig 7.** After the passage of the first passing suture in the left knee, a second passing suture (black arrow) is also passed through the femoral tunnel and retrieved through the anteromedial portal using a Kocher clamp or arthroscopic grasper. While the first passing suture is used to deliver the hamstring autograft through the tibial and femoral tunnels, the second passing suture is used to pull the strip of iliotibial band through the femoral tunnel. This portion of the procedure is performed under arthroscopic visualization with a 30° arthroscope in the anterolateral portal. (L, lateral; M, medial.)

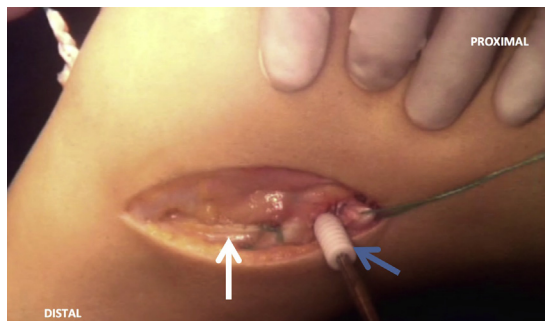


**Fig 8.** To perform the lateral tenodesis portion of the procedure in the left knee, a soft-tissue tunnel is first created underneath the lateral collateral ligament (LCL, yellow arrow) using an osteotome (\*) or Penfield dissector (A). This newly formed tunnel will allow for the passage of the strip of iliotibial band (ITB) (white arrow) into the femoral tunnel. The passing suture is pulled distally through the soft tunnel using a Kocher or Kelly clamp (B). The ITB strip is then pulled into the created soft-tissue tunnel directly underneath the LCL (C). Once the optimal positioning of the ITB strip is confirmed, the surgical assistant pulls the strip through the anteromedial portal using the passing suture (D).

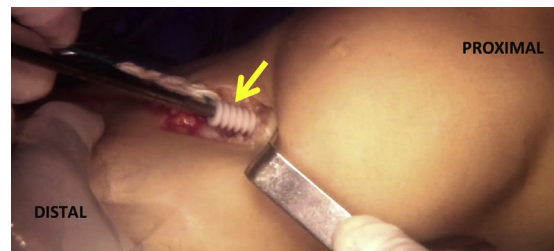### Fixation of the Hamstring Autograft and Strip of ITB

Once positioning is verified, the knee is placed in 50° to 60° of flexion and slight external rotation. The strip of ITB is first secured to the LCL using a no. 5.0 nonabsorbable Ethibond suture (Ethicon) to verify optimal anterolateral tensioning prior to screw fixation. A guide pin is then introduced in the femoral tunnel while the surgical assistant maintains the autograft and strip of ITB under tension. As the knee is kept in this position, an 8 × 25-mm

bioabsorbable interference screw (Arthrex) corresponding to the 8-mm previously formed femoral tunnel is introduced with a matching screwdriver (Fig 9). Inside the femoral tunnel, the screw simultaneously secures the strip of ITB as well as the femoral portion of the hamstring autograft. After this, the knee is placed in 10° to 30° of flexion and the tibia is reduced. While maintaining the knee in this position, the hamstring autograft is fixed into the tibial tunnel using a 9 × 25-mm bioabsorbable interference screw (Arthrex) (Fig 10). Once fixation at the femoral and tibial tunnels is complete, the knee is taken through a full range of motion, while the Lachmann and Pivot-Shift tests are performed to verify proper reconstruction.



**Fig 9.** While the left knee is maintained at 50°-60° of flexion and slight external rotation, the iliotibial band (ITB) strip (white arrow) and hamstring autograft are appropriately tensioned, and then an 8 × 25-mm bioabsorbable interference screw (Arthrex) (blue arrow) is introduced into the femoral tunnel to complete the simultaneous fixation of the ITB strip and hamstring autograft in the femoral tunnel.



**Fig 10.** After femoral fixation, the left knee is moved to 10° of flexion. While distal traction is applied to the hamstring autograft, a 9 × 25-mm bioabsorbable interference screw is used for fixation inside the tibial tunnel. The graft is kept under tension until the screw fixation is complete.

**Table 1.** Advantages and Limitations

Advantages	Limitations
Additional anterolateral stability of the knee in comparison to an isolated ACL reconstruction	Large incision resulting in a notable postoperative scar
Direct visualization of bone and soft-tissue landmarks	Risk of hematoma in the lateral thigh compartment
Lateral tenodesis is completed simultaneously with intra-articular ACL reconstruction	Risk of a hernia of the vastus lateralis due to harvesting site of the ITB
Minimal extraoperative time necessary	Risk of overconstraining the knee, which may result in cartilage damage
Minimal morbidity of harvesting site of ITB with added rotational knee stability	

ACL, anterior cruciate ligament; ITB, iliotibial band.

### Wound Closure

After copious irrigation with saline solution, ropivacaine 7.5 mg/mL (20 mL) and epinephrine (2 mL) are injected in the subcutaneous layer over the lateral incision to maximize hemostasis. Afterward, the tourniquet is released. Absorbable no. 1.0 Vicryl suture (Ethicon) is then used to close the proximal portion of the ITB while the distal portion over the lateral epicondyle remains as is. Finally, the subcutaneous layer is closed using no. 2.0 Vicryl suture (Ethicon) and the skin layer is closed through use of no. 4.0 Mononylon suture (Ethicon).

### Postoperative Rehabilitation

After the procedure, early knee range of motion is encouraged as soon as the first postoperative day. The patient is allowed to bear weight as tolerated. However, we recommend the use of crutches during the first 2 weeks postoperatively. Physiotherapy should begin as soon as possible, varying in length according to the patient's discretion. The patient's reported knee pain and noted swelling of the knee is used to guide the progression of rehabilitation exercises. During the initial 2 postoperative months, rehabilitation should focus on re-establishing proper knee range of motion in combination with exercises for quadriceps activation as well as restoration of patella and patellar tendon mobility. After these initial 3 months, cycling exercise should begin with a gradual progression of resistance according to the patient's individual progress. In combination with cycling

exercise, walking exercise on a treadmill is initiated with gradual progression to 7° of inclination from the horizontal plane. A full return to sports and exercise without limitations is individualized according to the progress of the patient, but usually is not reached until 6 months after surgery. [Tables 1](#) and [2](#) list the advantages and disadvantages as well as the pearls and pitfalls associated with the described technique. Our indications for this technique are listed in [Table 3](#).

### Discussion

The interest in the rotational component of knee stability after ACLR has increased given the recent increase in the awareness of lack of rotational stability seen after ACLR.<sup>15</sup> Kocher et al.<sup>15</sup> reported that the pivot shift examination after ACLR may be a better, more clinically relevant measure than the Lachman test to evaluate knee stability given that the pivot-shift test shows a better association with subjective variables, including patient satisfaction, return to sport, and difficulty in cutting and twisting exercises. The search for a solution that sufficiently addresses and corrects residual rotational instability seen in up to 20% of all isolated ACLRs has stimulated the return of the lateral tenodesis technique done in combination with ACLR to reinforce rotational stability.<sup>16,17</sup> Moreover, the newly discovered structure, ALL, found on the anterolateral aspect of the knee has gained considerable attention in recent years, although there remains a lack of consensus regarding

**Table 2.** Pearls and Pitfalls

Pearls	Pitfalls
Knee capsule must be preserved during harvest and preparation of strip of ITB.	Inaccurate identification of extra-articular landmark points will result in suboptimal postoperative outcome.
Femoral fixation of the strip of ITB and hamstring autograft must be done simultaneously.	Inappropriate position of the knee during tibial and femoral screw fixation will result in improper tensioning of the strip of ITB and hamstring autograft.
Femoral fixation of the strip of ITB and hamstring autograft should be done at 50°-60° of flexion and slight external rotation.	Muscular hernia and hematoma may result from improper closure of the fascia lata or lack of thorough hemostasis.
Tibial fixation of the hamstring autograft is done in 10°-30° of flexion; then the tibia is reduced.	

ITB, iliotibial band.



**Table 3.** Indications

Limited ipsilateral hip range of motion
Grade 3 pivot-shift test
ACL revision with rotational instability
ACL, anterior cruciate ligament.

the ALL's exact anatomic properties.<sup>18</sup> Nevertheless, reconstruction of the ALL has been described as a possible procedure done to correct anterolateral instability, similarly to the lateral tenodesis technique.<sup>19-21</sup>

A lateral tenodesis of the ITB is an effective surgical method that not only restores but also reinforces anterolateral stability and allows for sufficient rotational stability in the setting of an ACLR. Ultimately, a hamstring autograft in an isolated ACLR may be more predisposed to deformation and elongation than an ACLR done in combination with an extra-articular procedure due to supplementary stability afforded by the extra-articular graft.<sup>22</sup> In fact, a tenodesis of the ITB reduces the tension placed on the graft in an ACLR by approximately 43%.<sup>23</sup> Another important consideration regarding a tenodesis of the ITB that should be highlighted is that a site more posterior and proximal to the LCL for the attachment point of the strip of ITB results in the basic reproduction of ALL anatomy.

Aside from the lack of rotational stability that may be seen in some cases of ACLR, a better understanding concerning the relation between hip bony abnormalities as well as irregularity in hip range of motion and risk of ACL injuries has also been reported in the literature.<sup>24-27</sup> In addition to cases of knee rotatory instability confirmed clinically as a high-grade pivot shift, we also perform and recommend our technique of lateral tenodesis in patients with restricted hip range of motion because tension placed on the graft will be severely limited as a result.<sup>23</sup>

Furthermore, we would like to highlight that the strip of ITB must be fixed in flexion to arrive at optimal tensioning and restrict internal rotation of the knee to 35° of flexion at most. However, in contrast, the hamstring autograft must be fixed in almost full extension for proper restoration of anterior stability while ensuring extension of the knee is not limited.<sup>28</sup> Although excess operative time may be a perceived disadvantage of the described technique, the overall time for the procedure does not greatly exceed an arthroscopic isolated single-bundle ACLR even with the additional steps associated with the extra-articular tenodesis. Moreover, despite the added risk for hematoma and muscular hernia with the described technique, we have not recognized any incidence of hematoma or muscular hernia in our case series. Therefore, these risks should not be considered, especially if thorough hemostasis and closure of the fascia lata is carefully performed.

In conclusion, we acknowledge that our technique is not indicated in all cases of an ACL tear. Instead, the

described technique may only be considered after a thorough physical examination that allows for comprehensive patient selection. Ultimately, the described technique should be particularly considered in the case of a high-grade pivot-shift (grades 2-3), a challenging ACL primary case with bony abnormality of the hip or restricted hip range of motion, and selected revision cases of ACLR with noted rotational instability of the affected knee.

## References

1. Ferretti A, Monaco E, Vadalà A. Rotatory instability of the knee after ACL tear and reconstruction. *J Orthop Traumatol* 2014;15:75-79.
2. Rahnemai-Azar AA, Naendrup J-H, Soni A, Olsen A, Zlotnicki J, Musahl V. Knee instability scores for ACL reconstruction. *Curr Rev Musculoskelet Med* 2016;9:170-177.
3. Inderhaug E, Stephen JM, Williams A, Amis AA. Biomechanical comparison of anterolateral procedures combined with anterior cruciate ligament reconstruction. *Am J Sports Med* 2017;45:347-354.
4. Roessler PP, Schuttler KF, Heyse TJ, Wirtz DC, Efe T. The anterolateral ligament (ALL) and its role in rotational extra-articular stability of the knee joint: A review of anatomy and surgical concepts. *Arch Orthop Trauma Surg* 2016;136:305-313.
5. Musahl V, Rahnemai-Azar AA, van Eck CF, Guenther D, Fu FH. Anterolateral ligament of the knee, fact or fiction? *Knee Surg Sports Traumatol Arthrosc* 2016;24:2-3.
6. Claes S, Vereecke E, Maes M, Victor J, Verdonk P, Bellemans J. Anatomy of the anterolateral ligament of the knee. *J Anat* 2013;223:321-328.
7. MacIntosh DL, Darby TA. Lateral substitution reconstruction. *J Bone Joint Surg Br* 1976;58:142.
8. Fox JM, Blazina ME, Del Pizzo W, Ivey FM, Broukhim B. Extra-articular stabilization of the knee joint for anterior instability. *Clin Orthop Relat Res* 1980;147:56-61.
9. Ferretti A, Monaco E, Ponzio A, et al. Combined intra-articular and extra-articular reconstruction in anterior cruciate ligament-deficient knee: 25 years later. *Arthroscopy* 2016;32:2039-2047.
10. Guzzini M, Mazza D, Fabbri M, et al. Extra-articular tenodesis combined with an anterior cruciate ligament reconstruction in acute anterior cruciate ligament tear in elite female football players. *Int Orthop* 2016;40:2091-2096.
11. Ellera Gomes JL, Marczyk LR. Anterior cruciate ligament reconstruction with a loop or double thickness of semitendinosus tendon. *Am J Sports Med* 1984;12:199-203.
12. Zarins B, Rowe CR. Combined anterior cruciate-ligament reconstruction using semitendinosus tendon and iliotibial tract. *J Bone Joint Surg Am* 1986;68:160-177.
13. Lipscomb AB, Johnston RK, Snyder RB. The technique of cruciate ligament reconstruction. *Am J Sports Med* 1981;9:77-81.
14. Lording TD, Lustig S, Servien E, Neyret P. Lateral reinforcement in anterior cruciate ligament reconstruction. *AP-SMART* 2014;1:3-10.

15. Kocher MS, Steadman JR, Briggs KK, Sterett WI, Hawkins RJ. Relationships between objective assessment of ligament stability and subjective assessment of symptoms and function after anterior cruciate ligament reconstruction. *Am J Sports Med* 2004;32:629-634.
16. Luzo MV, Franciozi CE, Rezende FC, Gracitelli GC, Debieux P, Cohen M. Anterior cruciate ligament—Updating article. *Rev Bras Ortop* 2016;51:385-395.
17. Crawford SN, Waterman BR, Lubowitz JH. Long-term failure of anterior cruciate ligament reconstruction. *Arthroscopy* 2013;29:1566-1571.
18. Bonasia DE, D'Amelio A, Pellegrino P, Rosso F, Rossi R. Anterolateral ligament of the knee: Back to the future in anterior cruciate ligament reconstruction. *Orthop Rev* 2015;7:5773.
19. Zhang H, Qiu M, Zhou A, Zhang J, Jiang D. Anatomic anterolateral ligament reconstruction improves post-operative clinical outcomes combined with anatomic anterior cruciate ligament reconstruction. *J Sports Sci Med* 2016;15:688-696.
20. Smith JO, Yasen SK, Lord B, Wilson AJ. Combined anterolateral ligament and anatomic anterior cruciate ligament reconstruction of the knee. *Knee Surg Sports Traumatol Arthrosc* 2015;23:3151-3156.
21. Sonnery-Cottet B, Daggett M, Helito CP, Fayard JM, Thaunat M. Combined anterior cruciate ligament and anterolateral ligament reconstruction. *Arthrosc Tech* 2016;5:e1253-e1259.
22. Pernin J, Verdonk P, Si Selmi TA, Massin P, Neyret P. Long-term follow-up of 24.5 years after intra-articular anterior cruciate ligament reconstruction with lateral extra-articular augmentation. *Am J Sports Med* 2010;38:1094-1102.
23. Engebretsen L, Lew WD, Lewis JL, Hunter RE. The effect of an iliotibial tenodesis on intraarticular graft forces and knee joint motion. *Am J Sports Med* 1990;18:169-176.
24. Ellera Gomes JL, Palma HM, Ruthner R. Influence of hip restriction on noncontact ACL rerupture. *Knee Surg Sports Traumatol Arthrosc* 2014;22:188-191.
25. Ellera Gomes JL, Palma HM, Becker R. Radiographic findings in restrained hip joints associated with ACL rupture. *Knee Surg Sports Traumatol Arthrosc* 2010;18:1562-1567.
26. Lopes OV Jr, Gomes JL, de Freitas Spinelli L. Range of motion and radiographic analysis of the hip in patients with contact and non-contact anterior cruciate ligament injury. *Knee Surg Sports Traumatol Arthrosc* 2016;24:2868-2873.
27. Gomes JL, de Castro JV, Becker R. Decreased hip range of motion and noncontact injuries of the anterior cruciate ligament. *Arthroscopy* 2008;24:1034-1037.
28. Austin JC, Phornphutkul C, Wojtys EM. Loss of knee extension after anterior cruciate ligament reconstruction: Effects of knee position and graft tensioning. *J Bone Joint Surg Am* 2007;89:1565-1574.