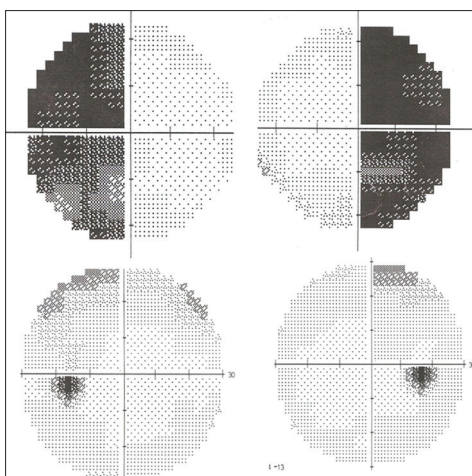


## Subclinical pituitary apoplexy with preserved pituitary functions

Sir,

The word “apoplexy” means accumulation of blood or fluid within any organ in Greek. Pituitary apoplexy was firstly described by Brougham *et al.*, in 1950.<sup>[1]</sup> Pituitary apoplexy is a medical emergency and clinically manifest as a sudden onset of severe headache, visual deterioration, ophthalmoplegia, and partial or complete pituitary failure, with or without altered consciousness. However, the presentation varies from asymptomatic presentation to life-threatening subarachnoid hemorrhage.<sup>[2]</sup> Asymptomatic pituitary hemorrhage is often termed subacute or subclinical pituitary apoplexy, which occurs in about 14-22% of cases with pituitary macroadenoma.<sup>[2,3]</sup>

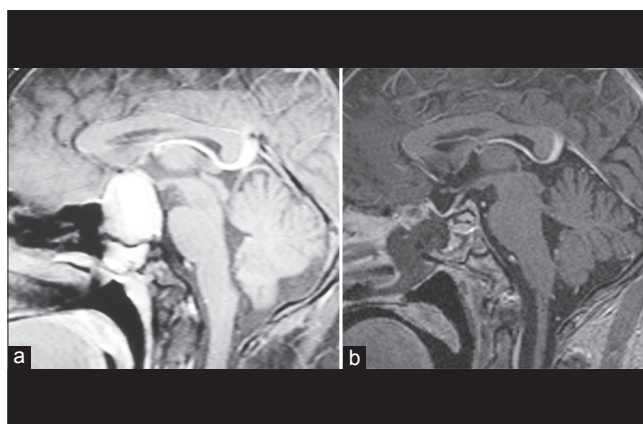
A 22-year-old male presented with progressive diminution of vision in both eye for 1 month to an eye department. There was no history of headache, vomiting, seizure, motor, sensory, altered sensorium, and bowel or bladder symptoms. He had no symptoms suggestive of endocrine dysfunction. He was of average built and his general examination was unremarkable including vital parameters. He had no clinical evidence of endocrine hyper or hypofunction. His visual field examination showed bitemporal hemianopia [Figure 1]. There was no evidence of any neurological deficit, including cranial nerves. He had normal hematological and biochemical parameters (hemoglobin 13.0 g/dl, P. glucose fasting 76 mg/dl, PP 76 mg/dl, B urea 26 mg/dl, S creatinine 0.7 mg/dl, S sodium 138 meq/L, potassium 4.8 meq/L, S bilirubin 0.6 mg/dl, ALT 11 IU/L, AST 17 IU/L, urine specific gravity 1020, spot sodium 11.5 meq/dl). His magnetic resonance imaging (MRI) showed hemorrhagic pituitary macroadenoma (2.9 × 4.3 × 4.6 cm) with suprasellar extension with solid and cystic component within tumor. It also extended into cavernous sinus, displacing both the cavernous internal carotid arteries laterally [Figure 2].



**Figure 1:** Preoperative bitemporal hemianopia, which completely recovered following surgery

Preoperative hormonal evaluation showed normal target gland functions (total T3 1.56 ng/ml, T4 9.23 µg/dl, TSH 1.67 mIU/L, S cortisol 10.21 µg/dl, post ACTH cortisol 36.01 µg/dl, LH 6.3 mIU/L, FSH 5.9 mIU/L, testosterone 6.5 ng/ml, prolactin 34 ng/ml). He underwent endoscopic trans-sphenoidal surgery. Postoperatively, his visual functions improved [Figure 1]. He had no abnormalities of hormonal evaluation postoperatively (total T3 1.26 ng/ml, T4 8.74 µg/dl, TSH 2.77 mIU/L, basal cortisol 14.25 µg/dl, post ACTH cortisol 27.1 µg/dl, LH 5.6 mIU/L, FSH 6.7 mIU/L, testosterone 5.4 ng/ml, prolactin 14 ng/ml). Postoperative imaging showed enhancing tissue in the cavernous sinus and bilaterally the cavernous segments of internal carotid arteries. The adenohypophysis was visualized as a thin (<1 mm) rim of enhancing tissue along the sella with empty sella [Figure 2]. Histopathological examination showed pituitary adenoma with large areas of hemorrhage.

Subclinical pituitary apoplexy is most common in third decade,<sup>[4]</sup> and our case was in his third decade. Our case presented with gradual deterioration of vision with bitemporal hemianopia due to compression of optic chiasma from the enlarged pituitary adenoma associated with hemorrhage. Similar slowly progressive visual loss has been reported in 8 cases of subclinical pituitary apoplexy.<sup>[5]</sup> Visual dysfunctions associated with pituitary apoplexy have been described as mono-ocular or bi-ocular blindness.<sup>[2]</sup> There were no symptoms related to classical pituitary apoplexy. Although various precipitating factors have been described such as trauma, hypertension, diabetes mellitus, drugs, radiotherapy, dynamic pituitary function tests, and anticoagulant therapy, our case had none of them.<sup>[2]</sup> It occurs spontaneously in most of the cases as occurred in our case. Another feature was the absence



**Figure 2:** (a) Pre-operative sagittal MRI showing pituitary adenoma with large hemorrhage compressing optic chiasma, (b) post-operative MRI showing empty sella with thin rim of enhancing tissue in floor, indicating preserved adenohypophysis

of hypopituitarism pre- and postoperatively, whereas most of the cases of pituitary apoplexy have partial or complete pituitary failure. The most common abnormalities described with subclinical pituitary apoplexy are thyroid and adrenal failure.<sup>[3]</sup>

**M. K. Garg, H. C. Pathak<sup>1</sup>, Giriraj Singh<sup>2</sup>**

Departments of Endocrinology, <sup>1</sup>Neurosurgery and <sup>2</sup>Radiology, Command Hospital (Southern Command), Pune, Maharashtra, India

Corresponding Author: Dr. Col. M. K. Garg, Department of Endocrinology, Command Hospital (Southern Command), Pune, Maharashtra, India. E-mail: mkgargs@gmail.com

## REFERENCES

1. Brougham M, Heusner AP, Adams RD. Acute degenerative changes in adenomas of the pituitary body – with special reference to pituitary apoplexy. *J Neurosurg* 1950;7:421-39.
2. Turgut M, Ozsunar Y, Başak S, Güneş E, Kir E, Meteoglu I. Pituitary apoplexy: An overview of 186 cases published during the last century. *Acta Neurochir (Wien)* 2010;152:749-61.
3. Zhang F, Chen J, Lu Y, Ding X. Manifestation, management and outcome of subclinical pituitary adenoma apoplexy. *J Clin Neurosci* 2009;16:1273-5.
4. Wakai S, Fukushima T, Teramoto A, Sano K. Pituitary apoplexy: Its incidence and clinical significance. *J Neurosurg* 1981;55:187-93.
5. Pinheiro MM, Cukiert A, Salgado LR, Nery M, Goldman J, Pimentel F, et al. Subclinical apoplexy in pituitary tumors. *Arq Neuropsiquiatr* 1999;57:74-7.

### Access this article online

#### Quick Response Code:



Website:  
www.ijem.in

DOI:  
10.4103/2230-8210.126597