

# Endotoxin-induced changes in expression of cyclooxygenase isoforms in the lamellar tissue of extracorporeally haemoperfused equine limbs

Bianca Patan-Zugaj<sup>1</sup>  | Monika Egerbacher<sup>2</sup> | Theresia F. Licka<sup>3,4</sup>

<sup>1</sup>Institute of Topographic Anatomy, University of Veterinary Medicine Vienna, Vienna, Austria

<sup>2</sup>Institute of Pathology, University of Veterinary Medicine Vienna, Vienna, Austria

<sup>3</sup>Equine University Clinic, University of Veterinary Medicine Vienna, Vienna, Austria

<sup>4</sup>Royal (Dick) School of Veterinary Studies, University of Edinburgh, Roslin, UK

## Correspondence

Bianca Patan-Zugaj, Institute of Topographic Anatomy, University of Veterinary Medicine Vienna, Vienna, Austria.

Email: Bianca.Patan-Zugaj@vetmeduni.ac.at

## Funding information

University of Veterinary Medicine Vienna; International Federation against Animal Experiments (Internationaler Bund der Tierversuchgegner)

## Abstract

Angiogenesis and sepsis-related equine laminitis have several features in common. Both events can be induced by endotoxin (lipopolysaccharide— LPS) and both are associated with increased expression of the enzyme cyclooxygenase (COX), of which two isoforms (COX-1 and COX-2) exist. To examine the causal relationship between LPS exposure and COX expression and to investigate the tissue distribution of COX in the LPS-exposed tissue, the technique of extracorporeal haemoperfusion of isolated equine forelimbs was utilized. Perfusion was performed for 10 hr under physiological conditions (control-perfused limbs,  $n = 5$ ) and with addition of 80 ng/L of endotoxin (LPS-perfused limbs;  $n = 5$ ). After perfusion, samples of lamellar tissue were collected from the dorsal aspect of the hoof wall. Additional control samples were collected from three non-perfused limbs. Immunohistochemical analysis was performed using antibodies against COX-1 and COX-2, and intensity of immunohistochemical staining was scored for each isoform. In the lamellar tissue of control- and LPS-perfused limbs, there was no significant difference in COX-1 staining intensity and distribution, whereas COX-2 expression was significantly increased in LPS-perfused limbs (especially in endothelial cells, fibroblasts and intravascular leucocytes as well as in epidermal basal cells at the base of the primary epidermal lamellae). These results suggest that COX-2 and its metabolites are involved in the initiation of pathological changes seen in sepsis-associated events such as sepsis-related laminitis. In such cases, COX-2 could therefore be an important therapeutic target; however, early therapy may be required as increase in COX-2 expression occurs within 10 hr after LPS exposure.

## KEYWORDS

angiogenesis, cyclooxygenase, equine laminitis, extracorporeal perfusion, immunohistochemistry, lipopolysaccharide

This is an open access article under the terms of the Creative Commons Attribution-NonCommercial-NoDerivs License, which permits use and distribution in any medium, provided the original work is properly cited, the use is non-commercial and no modifications or adaptations are made.

© 2019 The Authors. Anatomia, Histologia, Embryologia published by Wiley-VCH GmbH

## 1 | INTRODUCTION

Angiogenesis, the process of the development of new vessels from the initial vasculature, plays an important role in wound healing, inflammation and tumour growth (Alkim, Alkim, Koksall, Boga, & Sen, 2015; Mattsby-Baltzer, Jakobsson, Sörbo, & Norrby, 1994; Yao et al., 2011). First steps in the angiogenesis process include stimulation and activation of endothelial cells, secretion of various pro-angiogenic and pro-inflammatory molecules by activated endothelial cells, extravasation of leucocytes and degradation of basal membrane and extracellular matrix by matrix metalloproteinases (MMPs) and other proteases (Alkim et al., 2015). Similar steps occur in sepsis-related laminitis (De la Rebière de Pouyade et al., 2010; French & Pollitt, 2004; Loftus, Black, Pettigrew, Abrahamsen, & Belknap, 2007; Riggs et al., 2007), a very painful and often life-threatening disease of the suspensory apparatus of the distal phalanx of horses. Systemic sepsis (endotoxemia) develops secondary to diseases in which endotoxin from gram-negative bacteria (lipopolysaccharide, LPS) enters the bloodstream such as enterocolitis, pleuropneumonia and endometritis (Leise, 2018). Sepsis-related laminitis is the consequence of a systemic inflammatory response syndrome (SIRS); it is characterized by an inflammatory reaction in the lamellar tissue, which results in damage and separation of the lamellar dermo-epidermal interface between the distal phalanx and the inner surface of the hoof capsule (Leise, 2018; Menzies-Gow, 2018; Nourian, Baldwin, van Eps, & Pollitt, 2007).

The systemic inflammatory events that occur in sepsis-/SIRS-related laminitis coincide with marked increase in lamellar expression of a variety of inflammatory mediators including the cyclooxygenase (COX) enzyme (Blikslager et al., 2006; Waguespack, Cochran, & Belknap, 2004), which catalyses the biosynthesis of prostanoids (prostaglandins, prostacyclin and thromboxane) from arachidonic acid (Rouzer & Marnett, 2009; Smith, 1992). There are at least two isoforms of the COX enzyme, COX-1 and COX-2. The former enzyme is constitutively expressed in most cell types and its metabolites are thought to mediate physiological responses (Rouzer & Marnett, 2009; Smith, 1992; Tsatsanis, Androulidaki, Venihaki, & Margioris, 2006); however, COX-1 might also contribute to the inflammatory reaction (McAdam et al., 2000) as well as to the regulation of the angiogenesis process (Tsuji et al., 1998). The other isoform, COX-2, has low basal expression in most tissues, but it is rapidly and transiently induced in several cell types including fibroblasts, endothelial cells and leucocytes during inflammation (Rouzer & Marnett, 2009; Tsatsanis et al., 2006; Wadleigh, Reddy, Kopp, Ghosh, & Herschman, 2000). Metabolites of COX-2 are important in some physiological and also in numerous pathological mechanisms including the pathophysiologic events that are involved in SIRS-induced laminitis such as vasomotoric changes, platelet aggregation and perception of inflammatory pain (Tsatsanis et al., 2006; van Eps, Leise, Watts, Pollitt, & Belknap, 2012). Another important role of COX-2 is as mediator in the angiogenesis process (Iniguez, Rodriguez, Volpert, Fresno, & Redondo, 2003; Tsuji et al., 1998; Yao et al., 2011).

While there is evidence that LPS can initiate both SIRS-induced laminitis (Parsons, Orsini, Krafty, Capewell, & Boston, 2007) and angiogenesis (Mattsby-Baltzer et al., 1994; Pollet et al., 2003; Wang et al., 2018), little is known about the direct effect of LPS on the expression of COX and the distribution of this pro-inflammatory and pro-angiogenic enzyme in the LPS-stimulated tissue.

The aim of the present study was therefore to use extracorporeal haemoperfusion of isolated equine limbs with LPS-supplemented perfusate to investigate the effect of LPS on the expression and distribution of both isoforms of COX enzyme in the lamellar tissue. Our hypothesis was that perfusion of the isolated equine limbs with a clinically relevant concentration of LPS results in an increase in lamellar presence of the COX enzyme.

## 2 | MATERIALS AND METHODS

### 2.1 | Samples

In the present study, archived paraffin-embedded lamellar tissue samples from previous studies (Patan, Budras, & Licka, 2009; Patan-Zugaj, Gauff, & Licka, 2012) were used. The samples were collected after extracorporeal perfusion of isolated right forelimbs from 10 horses of various breeds (mean  $\pm$  SD age: 14.0  $\pm$  6.1 years, mean body weight: 516  $\pm$  70 kg). The limbs (mean  $\pm$  SD limb-weight: 6.74  $\pm$  1.69 kg) were obtained by disarticulation at the middle carpal joint directly after the horse's death following routine slaughter processing at a local licensed abattoir. The left forelimbs of three of those horses were also collected for use as non-perfused control limbs.

Prior to slaughter, each horse was examined at walk and trot and assessed for lameness. Additionally, a short clinical examination was performed to detect obvious signs of systemic disease. Horses were excluded if any sign of systemic or hoof disease was detected. Horses were killed at a commercial abattoir using a penetrating captive bolt followed by exsanguination during the routine slaughter process. The blood of each horse was collected during exsanguination, heparinized and used for autologous extracorporeal perfusion. As limbs and blood were collected as by-products during the routine slaughter process, no approval from an institutional care and use committee was required.

### 2.2 | Limb processing

Immediately after limb collection, the median artery of each isolated right forelimb was cannulated and flushed with ice-cold oxygenated and heparinized flushing solution, while the radial artery and the palmar branch of the median artery were ligated. The left forelimbs intended for use as non-perfused controls were prepared in the same way. For transportation to the laboratory (with a transportation time of 60–120 min), limbs and blood were placed on ice.

### 2.3 | Extracorporeal perfusion of the isolated limbs

For perfusion, the isolated right forelimbs were randomly assigned to two groups: perfusion under physiological conditions (control-perfused limbs;  $n = 5$ ), or under the same conditions with addition of 80 ng/L of endotoxin (LPS from *Escherichia coli* type O55:B5; Sigma-Aldrich Handels GmbH) to the blood perfusate (LPS-perfused limbs;  $n = 5$ ). This LPS-concentration was chosen because it is within the range of the plasma endotoxin concentration of horses affected with gastrointestinal or infectious (septicemic) diseases (Fessler et al., 1989; Senior, Proudman, Leuwer, & Carter, 2011; Steverink et al., 1994) and of horses with experimental SIRS-induced laminitis (Sprouse, Garner, & Green, 1987).

The extracorporeal perfusion of the isolated limbs was performed as described previously (Patan et al., 2009; Patan-Zugaj et al., 2012). Briefly, immediately after arrival at the laboratory, the median artery of each isolated right forelimb was connected to the recirculating perfusion system. Perfusion was performed with heparinized autologous blood, which was oxygenated and warmed to 35°C. Total duration of perfusion was 10 hr, including an initial equilibration period of 30 min in which the blood flow was slowly increased to 12 ml kg<sup>-1</sup> min<sup>-1</sup>. For monitoring of the viability of the perfused tissues, glucose utilization as well as lactate and lactate dehydrogenase production were determined and blood gas analysis was performed at 1-hr intervals. Supplementation of the perfusate with glucose was necessary in 1-hr intervals to compensate for glucose utilization.

### 2.4 | Sample preparation

Immediately after perfusion, blocks of lamellar tissue (approx. 10 × 10 × 10 mm) were obtained from the proximal and distal part of the dorsal aspect of the hoof. Specimens were fixed in 4% formaldehyde, embedded in paraffin and kept in a dark room temperature (approx. 20°C) storage unit until further processing. Samples from the non-perfused left forelimbs were collected immediately after transport and prepared in the same way.

### 2.5 | Immunohistochemistry

Immunohistochemical staining of the lamellar tissue was performed using polyclonal goat anti-human COX-1 antibody (C20; Santa Cruz Biotechnology Inc; dilution, 1:100) and monoclonal rabbit anti-human COX-2 antibody (clone SP21; Thermo Fisher Scientific Inc; dilution, 1:500). Both antibodies are not tested for cross-reactivity with equine COX enzymes by the antibody manufacturers, but the COX-1 antibody was already used in equine lamellar tissue in a different study (Blikslager et al., 2006). Prior to staining, dilution series were performed to determine a suitable staining dilution with little background staining. For both antibodies, all slides were stained in a single batch.

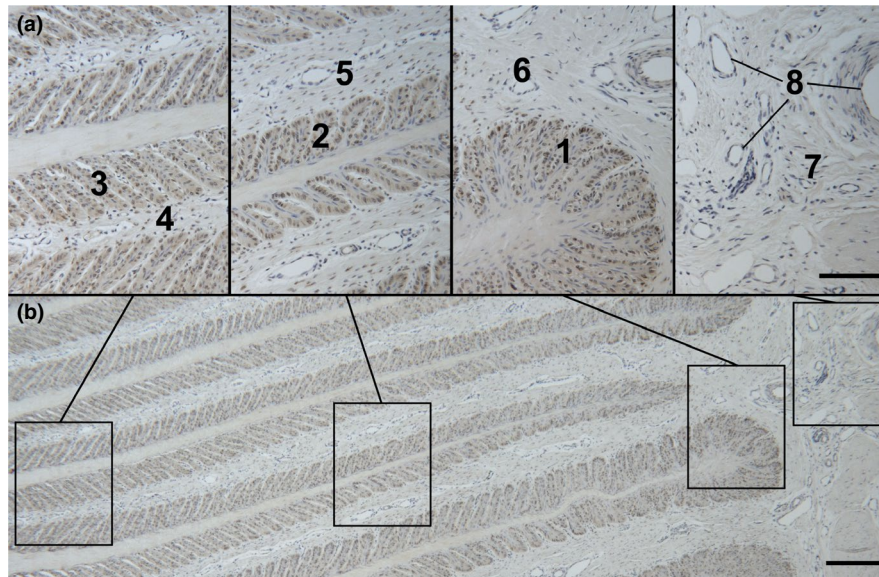
For immunohistochemical staining, archived paraffin-embedded blocks of lamellar tissue were sectioned at 4 μm thickness.

Afterwards, sections were mounted on silane-coated glass slides, deparaffinised, rehydrated and incubated in 0.6% hydrogen peroxide for 15 min. For antigen retrieval, sections were heat treated (65°C) for 2 hr with a citrate buffer (pH 6.0, for COX-2 detection) or with a Tris/EDTA buffer (pH 9.0, for COX-1 detection). To block non-specific bindings, the sections were then incubated in 1.5% goat serum in PBS solution (COX-2) or in 1.5% bovine serum albumin in PBS solution (COX-1) for 30 min. Afterwards, slides were incubated with the primary antibody diluted in PBS solution overnight at 4°C. Additional sections were incubated with PBS solution alone to serve as negative control. Slides intended to use for detection of COX-2 were then incubated with a biotin-free secondary antibody that was polymerized directly with horseradish peroxidase (BrightVision Poly-HRP-anti-rabbit antibody; ImmunoLogic) for 30 min at room temperature. For detection of COX-1, a different biotin-free secondary antibody (ImmPress anti-goat Ig Peroxidase Polymer Detection Kit; Vector Laboratories Inc) was used. Finally, sections were incubated for 10 min in 3,3'-diaminobenzidine tetrahydrochloride to visually identify the antigen as a brown precipitate. All sections were counterstained with hemalum for 3 min. For both antibodies, human placenta samples and lamellar tissue samples from forehooves of a horse that had naturally acquired acute, clinical laminitis were treated similarly and served as positive controls.

All slides were randomly coded with a unique alphanumeric identification and then evaluated via light microscopy at 25× magnification by one of the authors (BPZ), who was blinded to the identity of samples. The intensity of staining was subjectively scored using a semi-quantitative scoring system ranging from 0 to 3 (Fedchenko & Reifenrath, 2014). Score 0 was assigned if no stained cells were visible, and scores 1, 2 and 3 were assigned if the degree of staining was assessed as mild, moderate or intense, respectively. To examine the distribution of the COX enzymes in the lamellar tissue, eight locations were evaluated in each section (Figure 1): basal and suprabasal epidermal cells (stratum basale and spinosum) at the tip, in the middle and at the base of the primary epidermal lamellae (PEL), dermal tissue at the tip, in the middle and at the base of the primary dermal lamellae (PDL) as well as in the supralamellar region (above the tip of the primary epidermal lamellae) and endothelial cells of the vessels in the supralamellar region. For this evaluation, one slide per archived tissue block and antibody was evaluated. As one proximal and one distal lamellar tissue samples were obtained from each hoof, a total of two slides were evaluated per limb. The total score per slide (sum of all scores from the eight locations; minimum 0, maximum 24) was used for statistical evaluation.

### 2.6 | Statistical analysis

Data analyses were performed by use of a commercial software program (IBM SPSS Statistics, version 24; IBM Corp). Because of the small samples size, all data analyses were performed using non-parametric tests. Data were considered to differ significantly



**FIGURE 1** Photomicrograph of equine lamellar tissue sections showing the locations of eight regions evaluated for the presence of COX-1 and COX-2. Images in panel (a) are enlargements of the boxed regions in panel (b). Numbered areas represent basal and suprabasal epidermal cells (stratum basale and spinosum) at the tip (1), in the middle (2) and at the base (3) of the primary epidermal lamellae, dermal tissue at the tip (4), in the middle (5) and at the base (6) of the primary dermal lamellae as well as perivascular dermal tissue (7) and endothelial cells (8) in the supralamellar region (above the tip of the primary epidermal lamellae). Immunohistochemical stain for COX-1; bars = 100  $\mu$ m in panel (a) and 200  $\mu$ m in panel (b)

at values of  $p < .05$ . For comparison of the immunohistochemical scores of lamellar tissue sections from the proximal versus distal portion of the dorsal aspect of the hoof, the Wilcoxon test was used. As scores for the proximal and distal samples did not differ significantly, the mean of the scores for the two sections was calculated for each limb. These mean scores were used for further statistical analyses.

To control for differences caused by perfusion, comparisons between perfused (right) and non-perfused (left) forelimbs were performed using the Wilcoxon test including only data obtained from the three donor horses where both limbs were available. Comparison between the LPS-perfused ( $n = 5$ ) and control-perfused right forelimbs ( $n = 5$ ) was performed using the Mann-Whitney  $U$  test. Descriptive statistics such as median and IQR were used to summarize results.

### 3 | RESULTS

#### 3.1 | Immunohistochemical analyses

Both antibodies showed an obvious reaction in the positive control samples, whereas no reaction was visible in the negative control samples.

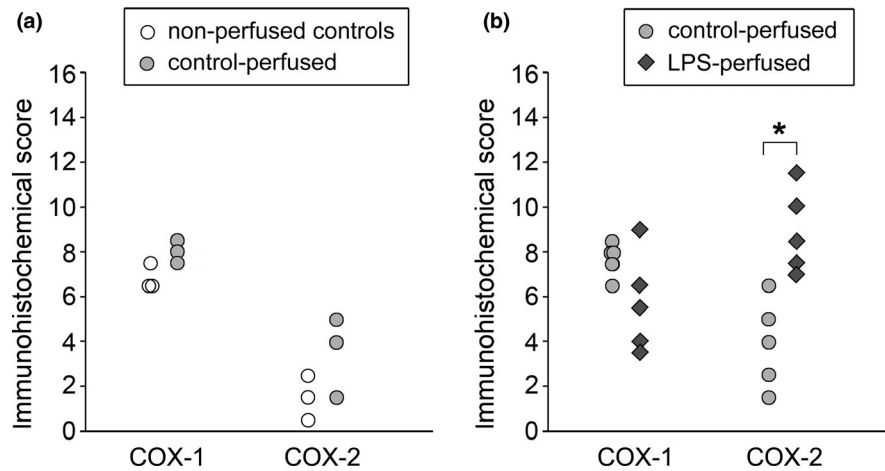
The median immunohistochemical scores of lamellar tissue sections from non-perfused control limbs and control-perfused limbs ( $n = 3$  in both groups) did not differ significantly neither for COX-1 (6.5; IQR 6.6 to 7 vs. 8; IQR 7.75–8.25;  $p = .109$ ) nor for COX-2 (1.5; IQR, 1 to 2 vs. 4; IQR 2.75–4.5;  $p = .276$ ; Figure 2a).

For COX-1, comparison of the median scores of lamellar tissue sections from LPS-perfused limbs (5.5; IQR, 4–6.5) versus control-perfused limbs (8; IQR, 7.5–8) revealed no significant differences ( $p = .141$ ). However, for COX-2, the median score for LPS-perfused limbs was significantly ( $p = .009$ ) higher (8.5; IQR, 7.5–10) than that for control-perfused limbs (4; IQR, 2.5–5; Figure 2b).

#### 3.2 | Distribution of the isoforms of the COX enzyme in the lamellar tissue

For COX-1, in all groups, a moderate staining of the basal epidermal cells and fibroblasts as well as a mild staining of the suprabasal epidermal cells, the dermal extracellular matrix and the endothelial and vascular smooth muscle cells was detectable in the entire laminar region (Figure 3a–c).

For COX-2, little staining was visible in the entire lamellar region in tissue sections from non-perfused control and control-perfused limbs; in both groups, only single basal epidermal cells, fibroblasts and endothelial cells showed a mild staining (Figure 4a,b). In the sections from LPS-perfused limbs, moderate-to-intense staining of endothelial cells, intravascular leucocytes and fibroblasts (especially at the base of the PDL and at the supralamellar region) was detectable, whereas vascular smooth muscle cells and extracellular matrix showed no reaction with the COX-2 antibody. The staining pattern of the keratinocytes at the tip of the PEL was similar to that of the control group with only mild staining of some isolated basal epidermal cells, but the staining intensity and incidence increased from the tip to the base of the PEL (Figure 4c–f).



**FIGURE 2** Immunohistochemical scores for detection of COX-1 and COX-2 in equine lamellar tissue sections. (a) Comparison between isolated equine forelimbs that underwent extracorporeal perfusion with autologous blood for 10 hr (control-perfused limbs) and non-perfused contralateral forelimbs ( $n = 3/\text{group}$ ). (b) Comparison between control-perfused limbs and isolated equine forelimbs that underwent extracorporeal perfusion as described for panel (a) with addition of 80 ng of LPS/L of perfusate ( $n = 5/\text{group}$ ). The amount of visible staining was scored on a scale from 0 to 3 for each of the eight locations described in Figure 1 (maximum score/stain, 24). \*The median value for the bracketed data points differ significantly ( $p < .01$ ) between LPS-perfused and control-perfused limbs

## 4 | DISCUSSION

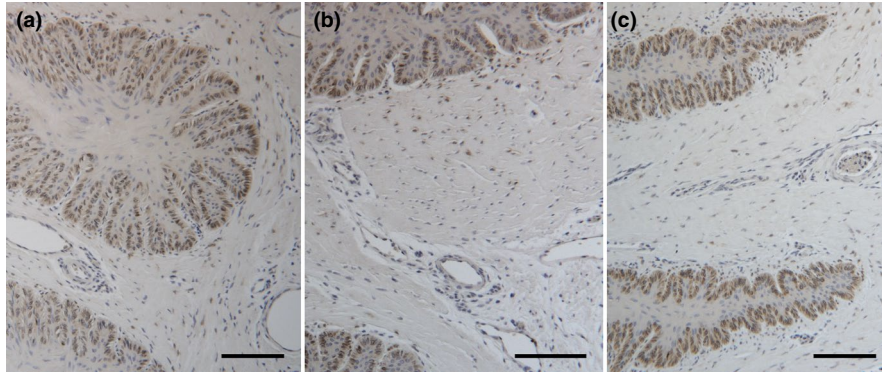
In the present study, we used extracorporeal haemoperfusion of isolated equine limbs with LPS-supplemented perfusate to investigate the effect of LPS on the COX expression in the lamellar tissue. This technique has the advantage that the effect of continuing LPS exposure on the tissue can be investigated under controlled conditions and without systemic influences. Additionally, it offers the possibility of examining complex relationships and interactions in the exposed tissue, which are neglected in simplified *in vitro* studies, without the ethical dilemma of animal experiments of *in vivo* studies. In previous studies using this technique, it was shown that direct exposure of the lamellar tissue to LPS leads to changes in haemodynamics with vasodilation of laminar vessels and formation of microthrombi (Patan-Zugaj et al., 2012; Patan-Zugaj, Gauff, Plendl, & Licka, 2014). Additionally, LPS exposure induced inflammatory reaction in the lamellar tissue with intra- and extravascular accumulation of leucocytes, increased expression and activation of MMP-9 and damage of the dermo-epidermal basement membrane (Patan-Zugaj, Gauff, Egerbacher, & Licka, 2018; Patan-Zugaj et al., 2014). These events are similar to the pathological changes seen in lamellar tissue of horses with naturally acquired or experimentally induced SIRS-related laminitis (French & Pollitt, 2004; Loftus, Johnson, Belknap, Pettigrew, & Black, 2009; Nourian et al., 2007); they also occur as first steps in the angiogenesis process (Alkim et al., 2015).

An important limitation of the set-up used in the present study may arise from the fact that the results were gained post-mortem using extracorporeally perfused isolated limbs. The resultant lack of systemic influences can be regarded as advantage for examination of a specific aspect, but otherwise, it may implicate a disadvantage for transferring the results to living horses and therapeutic approaches. Another potential limitation was the time required for

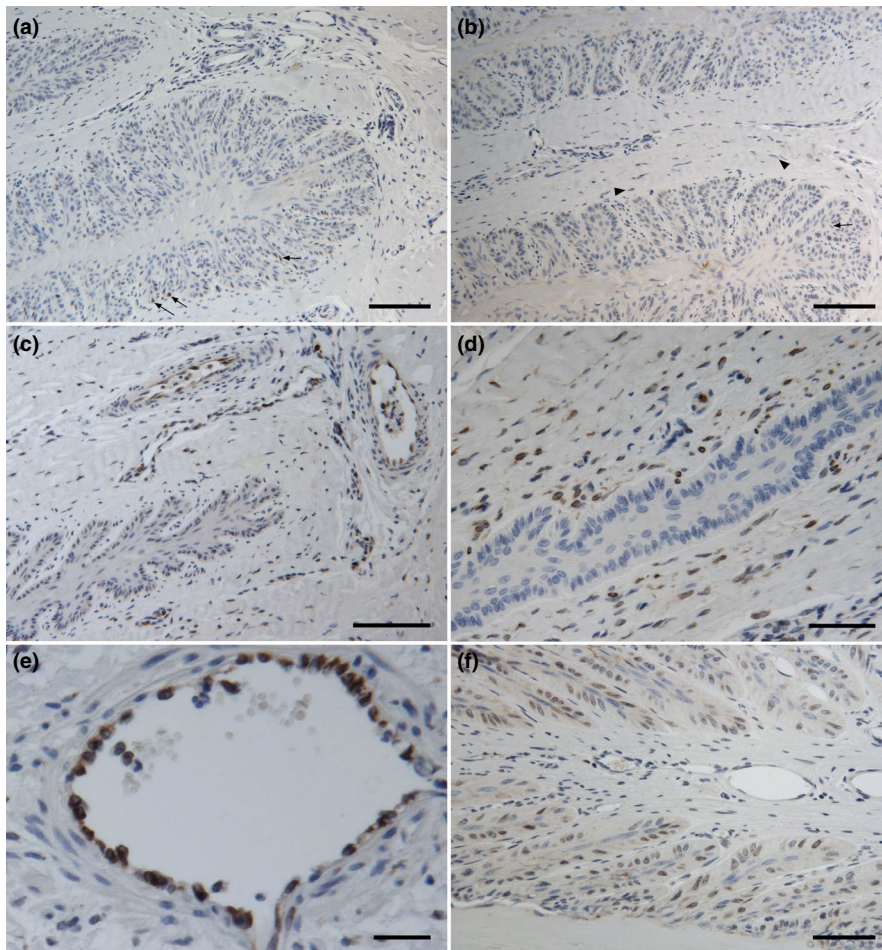
transportation of the limbs to the laboratory leading to cold ischaemia for 60–120 min followed by reperfusion. The effect of cold ischaemia and reperfusion on the lamellar tissue of extracorporeally haemoperfused equine limbs was examined in a previous study (Patan et al., 2009). In this study, indicators for cell metabolism such as oxygen and glucose consumption as well as lactate generation, indicators for cellular damage such as potassium concentration and lactate dehydrogenase (LDH) activity in the perfusate, and also the histologic and ultrastructural appearance of the lamellar tissue were examined. All these parameters showed no signs of post-ischaemic cellular damage of the perfused lamellar tissue after 10 hr of haemoperfusion (Patan et al., 2009). To assess possible ischaemia- and reperfusion-induced changes as well as effects induced by the extracorporeal perfusion system on the COX expression in the present study, samples of control-perfused limbs were compared with samples of non-perfused control limbs, which revealed no significant differences in the immunohistochemical scores for both isoforms of the COX enzyme.

Investigation of the COX isoforms is of key interest in laminitis (Blikslager et al., 2006), not only because of its role as key mediator in inflammation (van Eps et al., 2012), but also because of its inhibition by non-steroidal anti-inflammatory drugs (NSAIDs) which are the mainstay of therapy of equine laminitis. The COX enzyme is also important in tumour research, because of its role as mediator in the angiogenesis process (Iniguez et al., 2003; Tsujii et al., 1998; Yao et al., 2011). The inhibition of COX activity by NSAIDs (especially selective COX-2 inhibitors) also inhibits angiogenesis and leads to a dramatic antineoplastic effect in a number of tumour model systems (Iniguez et al., 2003; Kim, Sharma, Ren, Han, & Kim, 2018; Tsujii et al., 1998).

The two isoforms of the COX enzyme distinctly differ in their distribution in the lamellar tissue and in their reaction to LPS



**FIGURE 3** Representative photomicrographs of immunohistochemical staining for COX-1 in equine lamellar tissue sections from a non-perfused control limb (a), a control-perfused limb (b) and a LPS-perfused limb (c). The COX-1 staining (represented by brown precipitates) has a similar pattern in all three groups with a moderate (score = 2) reaction of the basal epidermal cells and fibroblasts and a mild (score = 1) reaction of the suprabasal epidermal cells, the dermal extracellular matrix and the endothelial and vascular smooth muscle cells. Bars = 100  $\mu$ m



**FIGURE 4** Representative photomicrographs of immunohistochemical staining for COX-2 in equine lamellar tissue sections from a non-perfused control limb (a), a control-perfused limb (b) and a LPS-perfused limb (c-f). The COX-2 staining (represented by the brown colour) reveals a mild (score = 1) reaction of single basal epidermal cells (arrows) and fibroblasts (arrowheads) in the non-perfused control (a) and the control-perfused (b) section. The LPS-perfused section shows a moderate (score = 2) staining of endothelial cells and fibroblasts at the base of the primary dermal lamellae (c and d) as well as an intense (score = 3) reaction of endothelial cells and intravasal leucocytes in the supralamellar region (e). At the base of the primary epidermal lamellae, the basal epidermal cells also show a moderate COX-2 reaction in the LPS-perfused section (f). Bars = 100  $\mu$ m in panels (a-c), 50  $\mu$ m in panels (d) and (f), and 25  $\mu$ m in panel (e)

exposure. The presence of COX-1 in various cell types of the lamellar tissue (especially in the basal epidermal cells and in fibroblasts) even in samples of non-perfused control limbs suggests that COX-1 and its metabolites play a physiologic role in hoof wall growth. After 10 hr, COX-1 expression and distribution were not significantly different in the LPS-exposed lamellar tissue than in

controls. These findings are similar to those in the developmental phase of experimental, SIRS-induced laminitis (Blikslager et al., 2006; Leise et al., 2011; Waguespack et al., 2004). If samples had been taken after a shorter time of LPS exposure, an increase in COX-1 is conceivable, because from as early as 30 min after LPS exposure it is increased in monocytes, and at this time, it may

contribute to the early stage of prostanoid production (McAdam et al., 2000). However, COX-1 is rapidly degraded in response to the elevation of the intracellular calcium level (with a half-life of <30 min; Yazaki, Kashiwagi, Aritake, Urade, & Fujimori, 2012). This calcium level is increased by various factors including hypoxia (Arnould, Michiels, Alexandre, & Remacle, 1992) and oxidative stress (Stone et al., 2000), and both hypoxia and oxidative stress are thought to play a role in the developmental phase of SIRS-induced laminitis (Medina-Torres, Mason, Floyd, Harris, & Mobasheri, 2011; Yin, Pettigrew, Loftus, Black, & Belknap, 2009). These factors are probably also present in the lamellar tissue of LPS-perfused limbs, where microthrombi may lead to local hypoxia and accumulation of leucocytes with activation of myeloperoxidase may lead to oxidative stress (Patan-Zugaj et al., 2014). Therefore, it is likely that COX-1 or rather its metabolites contribute to LPS-induced inflammatory reaction in the lamellar tissue during the early phase even though COX-1 is no longer detectable at the end of the 10-hr LPS-perfusion. In clinical cases of laminitis possible contribution of COX-1 to the early inflammatory reaction may be of minor relevance, as therapy with NSAIDs is only initiated as and when first clinical signs of laminitis become apparent; in experimentally induced laminitis, this was not before 9–12 hr after induction of laminitis (Riggs et al., 2009).

In contrast to COX-1, a significant LPS-induced increase in COX-2 expression in lamellar tissue was detected, while COX-2 was only marginally present in perfused and non-perfused controls. This is consistent with findings in experimental, SIRS-induced laminitis, where COX-2 mRNA and protein expression are also increased (Bliklager et al., 2006; Leise et al., 2011; Waguespack et al., 2004). In vitro studies show that exposure of several cell types (including fibroblasts, endothelial cells and leucocytes) to bacterial endotoxin or other stimuli induces COX-2 expression within 2–6 hr (McAdam et al., 2000; Tsatsanis et al., 2006; Wadleigh et al., 2000). This is confirmed in the more complex set-up of the present study, where COX-2 expression in the LPS-exposed lamellar tissue is mainly localized in endothelial cells, intravascular leucocytes, fibroblasts (especially at the base of the PDL and at the supralamellar region) and also in the epidermal basal cells at the base of the PEL.

The prostanoids produced by the COX enzymes can cause a variety of changes in the lamellar tissue potentially involved in the haemodynamic changes of the lamellar microvasculature and the pathological changes in the dermo-epidermal interface in SIRS-induced laminitis.

One of the main COX-2 products is prostaglandin  $I_2$  (prostacyclin), a potent vasodilator (Brooks et al., 2009), which may contribute to the vasodilation of the dermal lamellar vessels observed in the developmental phase of experimental, SIRS-induced, laminitis (Pollitt & Davies, 1998) and also in isolated haemoperfused equine limbs after LPS exposure (Patan-Zugaj et al., 2012).

Another COX-2 product, thromboxane  $A_2$ , is synthesized by platelets and neutrophils (Smith, 1992) and induces platelet aggregation (Tohgi, Konno, Tamura, Kimura, & Kawani, 1992).

Thromboxane  $A_2$  may thus contribute to the formation of microthrombi in the lamellar tissue, which are found in the developmental phase of experimentally SIRS-induced laminitis (Eades et al., 2007; Weiss, Geor, Johnston, & Trent, 1994) as well as after LPS exposure in isolated haemoperfused equine limbs (Patan-Zugaj et al., 2014).

The LPS-induced increase in COX-2 which was observed in the present study may also be responsible for the increased expression of MMP-9 in the LPS-exposed lamellar tissue (Patan-Zugaj et al., 2018), because prostaglandin  $E_2$ , a metabolite of COX-2, promotes the production of various MMPs including MMP-9 (Shankavaram, DeWitt, Funk, Sage, & Wahl, 1997). Specifically, MMP-9 is thought to play an important role in the degradation and structural failure of the dermo-epidermal basement membrane during SIRS-induced laminitis (Medina-Torres et al., 2011; Loftus et al., 2009; Pollitt, Pass, & Pollitt, 1998; Riggs et al., 2009). Additionally, MMP-9 is known as important pro-angiogenic enzyme, which plays a decisive role in degradation of basement membrane and extracellular matrix during angiogenesis (Alkim et al., 2015).

COX-2-induced prostaglandins are also important in the perception of inflammatory pain because they sensitize peripheral sensory nerve endings at the site of inflammation increasing transmission of pain signals to the spinal cord (Tsatsanis et al., 2006). Therefore, increased lamellar COX-2 expression may contribute to the extreme pain seen in laminitic horses.

In conclusion, a clinically relevant concentration of LPS was able to increase the COX-2 expression in the lamellar tissue of extracorporeal haemoperfused isolated equine limbs, whereas COX-1 of LPS- and control-perfused limbs showed the same amount and distribution after 10 hr of perfusion as non-perfused controls. These results suggest that predominately COX-2 and its metabolites may be involved in the pathological changes seen in sepsis-related events such as SIRS-induced laminitis or LPS-induced angiogenesis. Considering the fact that the activity of native LPS is 5–50 times stronger compared to the purified LPS that was used here (Mattsby-Baltzer et al., 1994), it is conceivable that the LPS-induced effect on COX-2 expression could be initiated by even lower doses of the native LPS in sepsis-related diseases. In SIRS-induced laminitis as well as in LPS-induced angiogenesis, COX-2 could be an important therapeutic target, but early therapy may be required as COX-2 expression is markedly increased within 10 hr of LPS exposure.

#### ACKNOWLEDGEMENTS

Supported by a research grant from the University of Veterinary Medicine Vienna and an award for the development of alternatives to animal experiments from the International Federation against Animal Experiments (Internationaler Bund der Tierversuchsgegner). The authors thank Dr. Felicia Gauff for help with LPS-perfusion, Magdalena Helmreich and Claudia Höchsmann for execution of sample preparation and immunohistochemical staining and Dr. Alexander Tichy for help with the statistical analyses.

## CONFLICT OF INTEREST

None of the authors has any financial or personal relationships that could inappropriately influence or bias the content of the paper.

## ORCID

Bianca Patan-Zugaj  <https://orcid.org/0000-0001-9466-354X>

## REFERENCES

- Alkim, C., Alkim, A., Koksak, A. R., Boga, S., & Sen, I. (2015). Angiogenesis in inflammatory Bowel disease. *International Journal of Inflammation*, 2015, 1–10. <https://doi.org/10.1155/2015/970890>
- Arnould, T., Michiels, C., Alexandre, I., & Remacle, J. (1992). Effect of hypoxia upon intracellular calcium concentration of human endothelial cells. *Journal of Cellular Physiology*, 152, 215–221. <https://doi.org/10.1002/jcp.1041520127>
- Blikslager, A. T., Yin, C., Cochran, A. M., Wooten, J. G., Pettigrew, A., & Belknap, J. K. (2006). Cyclooxygenase expression in the early stages of equine laminitis: A cytologic study. *Journal of Veterinary Internal Medicine*, 20, 1191–1196. <https://doi.org/10.1111/j.1939-1676.2006.tb00721.x>
- Brooks, A. C., Menzies-Gow, N. J., Wheeler-Jones, C., Bailey, S. R., Cunningham, F. M., & Elliott, J. (2009). Endotoxin-induced activation of equine digital vein endothelial cells: Role of p38 MAPK. *Veterinary Immunology and Immunopathology*, 129, 174–180. <https://doi.org/10.1016/j.vetimm.2008.11.008>
- De la Rebière de Pouyade, D. E., Riggs, L. M., Moore, J. N., Franck, T., Deby-Dupont, G., Hurley, D. J., & Serateyn, D. (2010). Equine neutrophil elastase in plasma, lamellar tissue, and skin of horses administered black walnut heartwood extract. *Veterinary Immunology and Immunopathology*, 135, 181–187. <https://doi.org/10.1016/j.vetimm.2009.10.024>
- Eades, S. C., Stokes, A. M., Johnson, P. J., LeBlanc, C. J., Ganjam, V. K., Buff, P. R., & Moore, R. M. (2007). Serial alterations in digital hemodynamics and endothelin-1 immunoreactivity, platelet-neutrophil aggregation, and concentration of nitric oxide, insulin, and glucose in blood obtained from horses following carbohydrate overload. *American Journal of Veterinary Research*, 68, 87–94. <https://doi.org/10.2460/ajvr.68.1.87>
- Fedchenko, N., & Reifnath, J. (2014). Different approaches for interpretation and reporting of immunohistochemistry analysis results in the bone tissue – A review. *Diagnostic Pathology*, 9, 221. <https://doi.org/10.1186/s13000-014-0221-9>
- Fessler, J. F., Bottoms, G. D., Coppoc, G. L., Gimarc, S., Latshaw, H. S., & Noble, J. K. (1989). Plasma endotoxin concentrations in experimental and clinical equine subjects. *Equine Veterinary Journal. Supplement*, 7, 24–28. <https://doi.org/10.1111/j.2042-3306.1989.tb05650.x>
- French, K. R., & Pollitt, C. C. (2004). Equine laminitis: Loss of hemidesmosomes in hoof secondary epidermal lamellae correlates to dose in an oligofructose induction model: An ultrastructural study. *Equine Veterinary Journal*, 36, 230–235. <https://doi.org/10.2746/0425164044877125>
- Iniguez, M. A., Rodriguez, A., Volpert, O. V., Fresno, M., & Redondo, J. M. (2003). Cyclooxygenase-2: A therapeutic target in angiogenesis. *Trends in Molecular Medicine*, 9, 73–78. [https://doi.org/10.1016/S1471-4914\(02\)00011-4](https://doi.org/10.1016/S1471-4914(02)00011-4)
- Kim, H. S., Sharma, A., Ren, W. X., Han, J., & Kim, J. S. (2018). COX-2 inhibition mediated anti-angiogenic activatable prodrug potentiates cancer therapy in preclinical models. *Biomaterials*, 185, 63–72. <https://doi.org/10.1016/j.biomaterials.2018.09.006>
- Leise, B. (2018). The role of neutrophils in equine laminitis. *Cell and Tissue Research*, 371, 541–550. <https://doi.org/10.1007/s00441-018-2788-z>
- Leise, B. S., Faleiros, R. R., Watts, M., Johnson, P. J., Black, S. J., & Belknap, J. K. (2011). Lamellar inflammatory gene expression in the carbohydrate overload model of equine laminitis. *Equine Veterinary Journal*, 43, 54–61. <https://doi.org/10.1111/j.2042-3306.2010.00122.x>
- Loftus, J. P., Black, S. J., Pettigrew, A., Abrahamsen, E. J., & Belknap, J. K. (2007). Early lamellar events involving endothelial activation in horses with black walnut-induced laminitis. *American Journal of Veterinary Research*, 68, 1205–1211. <https://doi.org/10.2460/ajvr.68.11.1205>
- Loftus, J. P., Johnson, P. J., Belknap, J. K., Pettigrew, A., & Black, S. J. (2009). Leukocyte-derived and endogenous matrix metalloproteinases in the lamellae of horses with naturally acquired and experimentally induced laminitis. *Veterinary Immunology and Immunopathology*, 129, 221–230. <https://doi.org/10.1016/j.vetimm.2008.11.003>
- Mattsby-Baltzer, I., Jakobsson, A., Sörbo, J., & Norrby, K. (1994). Endotoxin is angiogenic. *International Journal of Experimental Pathology*, 75, 191–196.
- McAdam, B. F., Mardini, I. A., Habib, A., Burke, A., Lawson, J. A., Kapoor, S., & FitzGerald, G. A. (2000). Effect of regulated expression of human cyclooxygenase isoforms on eicosanoid and isoicosanoid production in inflammation. *Journal of Clinical Investigation*, 105, 1473–1482. <https://doi.org/10.1172/JCI9523>
- Medina-Torres, C. E., Mason, S. L., Floyd, R. V., Harris, P. A., & Mobasher, A. (2011). Hypoxia and a hypoxia mimetic up-regulate matrix metalloproteinase 2 and 9 in equine lamellar keratinocytes. *The Veterinary Journal*, 190, e54–e59. <https://doi.org/10.1016/j.tvjl.2011.02.026>
- Menzies-Gow, N. (2018). Laminitis in horses. *In Practice*, 40, 411–419. <https://doi.org/10.1136/inp.k4485>
- Nourian, A. R., Baldwin, G. I., van Eps, A. W., & Pollitt, C. C. (2007). Equine laminitis: Ultrastructural lesions detected 24–30 hours after induction with oligofructose. *Equine Veterinary Journal*, 39, 360–364. <https://doi.org/10.2746/042516407X177448>
- Parsons, C. S., Orsini, J. A., Krafty, R., Capewell, L., & Boston, R. (2007). Risk factors for development of acute laminitis in horses during hospitalization: 73 cases (1997–2004). *Journal of the American Veterinary Medical Association*, 230, 885–889. <https://doi.org/10.2460/javma.239.6.885>
- Patan, B., Budras, K. D., & Licka, T. F. (2009). Effects of long-term extracorporeal blood perfusion of the distal portion of isolated equine forelimbs on metabolic variables and morphology of lamellar tissue. *American Journal of Veterinary Research*, 70, 669–677. <https://doi.org/10.2460/ajvr.70.5.669>
- Patan-Zugaj, B., Gauff, F. C., Egerbacher, M., & Licka, T. F. (2018). Endotoxin-induced changes of type VII collagen-cleaving matrix metalloproteinases in lamellar tissue of extracorporeally perfused equine limbs. *American Journal of Veterinary Research*, 79, 986–994. <https://doi.org/10.2460/ajvr.79.9.986>
- Patan-Zugaj, B., Gauff, F. C., & Licka, T. F. (2012). Effects of the addition of endotoxin during perfusion of isolated forelimbs of equine cadavers. *American Journal of Veterinary Research*, 73, 1462–1468. <https://doi.org/10.2460/ajvr.73.9.1462>
- Patan-Zugaj, B., Gauff, F. C., Plendl, J., & Licka, T. F. (2014). Effects of endotoxin on leucocyte activation and migration into lamellar tissue of isolated perfused equine limbs. *American Journal of Veterinary Research*, 75, 842–850. <https://doi.org/10.2460/ajvr.75.9.842>
- Pollet, I., Opina, C. J., Zimmerman, C., Leong, K. G., Wong, F., & Karsan, A. (2003). Bacterial lipopolysaccharide directly induces angiogenesis through TRAF6-mediated activation of NF- $\kappa$ B and c-Jun N-terminal kinase. *Blood*, 102, 1740–1742. <https://doi.org/10.1182/blood-2003-01-0288>
- Pollitt, C. C., & Davies, C. T. (1998). Equine laminitis: Its development coincides with increased sublamellar blood flow. *Equine Veterinary Journal. Supplement*, 26, 125–132. <https://doi.org/10.1111/j.2042-3306.1998.tb05131.x>
- Pollitt, C. C., Pass, M. A., & Pollitt, S. (1998). Batimastat (BB-94) inhibits matrix metalloproteinases of equine laminitis. *Equine Veterinary Journal*.



- Supplement, 26, 119–124. <https://doi.org/10.1111/j.2042-3306.1998.tb05130.x>
- Riggs, L. M., Franck, T., Moore, J. M., Krunkosky, T. M., Hurley, D. J., Peroni, J. F., ... Serteyn, D. A. (2007). Neutrophil myeloperoxidase measurements in plasma, lamellar tissue, and skin of horses given black walnut extract. *American Journal of Veterinary Research*, 68, 81–86. <https://doi.org/10.2460/ajvr.68.1.81>
- Riggs, L. M., Krunkosky, T. M., Noschka, E., Boozer, L. A., Moore, J. N., & Robertson, T. P. (2009). Comparison of characteristics and enzymatic products of leukocytes in the skin and lamellar tissues of horses administered black walnut heartwood extract or lipopolysaccharide. *American Journal of Veterinary Research*, 70, 1383–1390. <https://doi.org/10.2460/ajvr.70.11.1383>
- Rouzer, C. A., & Marnett, L. J. (2009). Cyclooxygenases: Structural and functional insights. *Journal of Lipid Research*, S29–S34. <https://doi.org/10.1194/jlr.R800042-JLR200>
- Senior, J. M., Proudman, C. J., Leuwer, M., & Carter, S. D. (2011). Plasma endotoxin in horses presented to an equine referral hospital: Correlation to selected clinical parameters and outcomes. *Equine Veterinary Journal*, 43, 585–591. <https://doi.org/10.1111/j.2042-3306.2010.00328.x>
- Shankavaram, U. T., DeWitt, D. L., Funk, S. E., Sage, E. H., & Wahl, L. M. (1997). Regulation of human monocyte matrix metalloproteinases by SPARC. *Journal of Cellular Physiology*, 173, 327–334. [https://doi.org/10.1002/\(SICI\)1097-4652\(199712\)173:3<327:AID-JCP4>3.0.CO;2-P](https://doi.org/10.1002/(SICI)1097-4652(199712)173:3<327:AID-JCP4>3.0.CO;2-P)
- Smith, W. L. (1992). Prostanoid biosynthesis and mechanisms of action. *American Journal of Physiology-Renal Physiology*, 263, F181–F191. <https://doi.org/10.1152/ajprenal.1992.263.2.F181>
- Sprouse, R. F., Garner, H. E., & Green, E. M. (1987). Plasma endotoxin levels in horses subjected to carbohydrate induced laminitis. *Equine Veterinary Journal*, 19, 25–28. <https://doi.org/10.1111/j.2042-3306.1987.tb02571.x>
- Steverink, P. J. G. M., Salden, H. J. M., Sturk, A., Klein, W. R., van der Velden, M. A., & Németh, F. (1994). Laboratory and clinical evaluation of a chromogenic endotoxin assay for horses with acute intestinal disorders. *Veterinary Quarterly*, 16(sup2), 117–121. <https://doi.org/10.1080/01652176.1994.9694517>
- Stone, V., Tuinman, M., Vamvakopoulos, J. E., Shaw, J., Brown, D., Petterson, S., ... Donaldson, K. (2000). Increased calcium influx in a monocytic cell line on exposure to ultrafine carbon black. *European Respiratory Journal*, 15, 297–303. <https://doi.org/10.1034/j.1399-3003.2000.15b13.x>
- Tohgi, H., Konno, S., Tamura, K., Kimura, B., & Kawani, K. (1992). Effects of low-to high doses of aspirin on platelet aggregability and metabolites of thromboxane A<sub>2</sub> and Prostacyclin. *Stroke*, 23, 1400–1403. <https://doi.org/10.1161/01.STR.23.10.1400>
- Tsatsanis, C., Androulidaki, A., Venihaki, M., & Margioris, A. N. (2006). Signalling networks regulating cyclooxygenase-2. *The International Journal of Biochemistry and Cell Biology*, 38, 1654–1661. <https://doi.org/10.1016/j.biocel.2006.03.021>
- Tsuji, M., Kawano, S., Tsuji, S., Sawaoka, H., Hori, M., & DuBois, R. N. (1998). Cyclooxygenase regulates angiogenesis induced by colon cancer cells. *Cell*, 93, 705–716. [https://doi.org/10.1016/S0092-8674\(00\)81433-6](https://doi.org/10.1016/S0092-8674(00)81433-6)
- Van Eps, A. W., Leise, B. S., Watts, M., Pollitt, C. C., & Belknap, J. K. (2012). Digital hypothermia inhibits early lamellar inflammatory signalling in the oligofructose laminitis model. *Equine Veterinary Journal*, 44, 230–237. <https://doi.org/10.1111/j.2042-3306.2011.00416.x>
- Wadleigh, D. J., Reddy, S. T., Kopp, E., Ghosh, S., & Herschman, H. R. (2000). Transcriptional activation of the cyclooxygenase-2 gene in endotoxin-treated RAW 264.7 macrophages. *The Journal of Biological Chemistry*, 275, 6259–6266. <https://doi.org/10.1074/jbc.275.9.6259>
- Waguespack, R. W., Cochran, A., & Belknap, J. K. (2004). Expression of the cyclooxygenase isoforms in the prodromal stage of black walnut-induced laminitis in horses. *American Journal of Veterinary Research*, 65, 1724–1729. <https://doi.org/10.2460/ajvr.2004.65.1724>
- Wang, G., Li, P., Zhang, S., Zhong, S., Chu, C., Zeng, S., ... Yang, X. (2018). Lipopolysaccharides (LPS) induced angiogenesis during chicken embryogenesis is abolished by combined ETA/ETB receptor blockade. *Cellular Physiology and Biochemistry*, 48, 2084–2090. <https://doi.org/10.1159/000492547>
- Weiss, D. J., Geor, R. J., Johnston, G., & Trent, A. M. (1994). Microvascular thrombosis associated with onset of acute laminitis in ponies. *American Journal of Veterinary Research*, 55, 606–612.
- Yao, L., Liu, F., Hong, L., Sun, L., Liang, S., Wu, K., & Fan, D. (2011). The function and mechanism of COX-2 in angiogenesis of gastric cancer cells. *Journal of Experimental & Clinical Cancer Research*, 30, 13. <https://doi.org/10.1186/1756-9966-30-13>
- Yazaki, M., Kashiwagi, K., Aritake, K., Urade, Y., & Fujimori, K. (2012). Rapid degradation of cyclooxygenase-1 and hematopoietic prostaglandin D synthase through ubiquitin-proteasome system in response to intracellular calcium level. *Molecular Biology of the Cell*, 23, 12–21. <https://doi.org/10.1091/mbc.E11-07-0623>
- Yin, C., Pettigrew, A., Loftus, J. P., Black, S. J., & Belknap, J. K. (2009). Tissue concentration of 4-HNE in the black walnut extract model of laminitis: Indication of oxidant stress in affected laminae. *Veterinary Immunology and Immunopathology*, 129, 211–215. <https://doi.org/10.1016/j.vetimm.2008.11.016>

**How to cite this article:** Patan-Zugaj B, Egerbacher M, Licka TF. Endotoxin-induced changes in expression of cyclooxygenase isoforms in the lamellar tissue of extracorporeally haemoperfused equine limbs. *Anat Histol Embryol*. 2020;49:597–605. <https://doi.org/10.1111/ahc.12520>