




ORIGINAL RESEARCH

Three-dimensional imaging of upper esophageal sphincter resting pressure

Shun-ichi Chitose MD, PhD  | Yasuro Shin MD | Kiminori Sato MD, PhD  |
Sachiyo Hamakawa BA | Mioko Fukahori MD, PhD | Takeharu Ono MD, PhD  |
Hirohito Umeno MD, PhD

Department of Otolaryngology—Head and Neck Surgery, Kurume University School of Medicine, Kurume, Japan

Correspondence

Shun-ichi Chitose, Department of Otolaryngology—Head and Neck Surgery, Kurume University School of Medicine, 67 Asahi-Machi, Kurume 830-0011, Japan. Email: yonekawa@med.kurume-u.ac.jp

Funding information

JSPS KAKENHI, Grant/Award Number: 16K11250

Abstract

Objective: High-resolution manometry (HRM) is used to analyze upper esophageal sphincter (UES) physiology. Conventional HRM can yield imprecise measurements of UES resting pressure given its unidirectional sensors and averaging of circumferential pressure. In contrast, three-dimensional (3D) measurements can yield precise UES resting pressure data over the entire length of the UES. This study conducted a detailed analysis of UES resting pressure as evaluated by 3D-HRM.

Methods: Seventeen young, healthy adult participants (7 females and 10 males) were recruited. The 3D-HRM system used includes a pressure sensor catheter (outer diameter, 4 mm) and eight-channel transducers arranged circumferentially to acquire pressure data at 45° intervals. The catheter was inserted transnasally into the esophagus and automatically retracted at a speed of 1 mm/s. Participants performed the following tasks: maintain resting breathing, perform breath holding, and perform the Valsalva maneuver. Data were obtained and compared per millimeter over the longitudinal UES length.

Results: Clear 3D waveforms were identified, with greater mean UES pressures in anterior-posterior directions than in lateral directions ($P < .05$). The anterior distribution was located superior to the posterior portion. Significant differences were observed in mean UES pressures and UES resting integrals between resting breathing and the Valsalva maneuver ($P < 0.05$). No differences in functional UES length were observed.

Conclusions: The normal UES resting pressure was not directionally uniform in the luminal structure. 3D-HRM imaging of UES resting pressure can help deepen our understanding of UES physiology.

Level of Evidence: 4

This article was presented at the American Academy of Otolaryngology—Head and Neck Surgery Foundation (AAO-HNSF) 2017 Annual Meeting and OTO Experience, in Chicago, Illinois, on October 7–10, 2017.

Shun-ichi Chitose and Yasuro Shin contributed equally to this study.

This is an open access article under the terms of the Creative Commons Attribution-NonCommercial-NoDerivs License, which permits use and distribution in any medium, provided the original work is properly cited, the use is non-commercial and no modifications or adaptations are made.

© 2019 The Authors. *Laryngoscope Investigative Otolaryngology* published by Wiley Periodicals, Inc. on behalf of The Triological Society.

KEYWORDS

high-resolution manometry, pharynx, resting pressure, swallowing pressure, upper esophageal sphincter

1 | INTRODUCTION

The upper esophageal sphincter (UES) is a high-pressure zone (HPZ) located between the hypopharynx and the cervical esophagus. The anterior wall of this musculocartilaginous structure is formed by the posterior lamina of the cricoid cartilage and posterior cricoarytenoid muscles, and its upper border is formed by the arytenoid and interarytenoid muscles.¹ The posterior and lateral components of the UES include the cricopharyngeal (CP) muscle, with some contribution from the oblique thyropharyngeal fibers of the inferior pharyngeal constrictor and upper esophageal circular muscle fibers. The CP fibers are slow-twitch tonically contracting fibers that cease tonic contraction only when deglutition is initiated. Thus, the UES has a characteristic mechanism in which relaxation occurs in precise intervals and opening is caused by distracting forces, such as a swallowed bolus or hyoid and laryngeal excursion.² Esophageal manometry provides pressure data and can be used to obtain information on pharyngeal phase dynamics, especially when combined with high-resolution manometry (HRM) systems with multiple sensors.

HRM has been described to be the primary method of esophageal motor function analysis. To visualize the data more clearly, a process of intersensor interpolation or averaging has been incorporated. This allows the information to be displayed in the form of seamless isobaric color regions on esophageal pressure topography plots.^{3,4} One of the most important advantages of HRM is the easier and faster performance of diagnostic esophageal manometry. HRM, equipped with

36 circumferential pressure channels at the same longitudinal setting, has the ability to measure pressure across 35 cm of esophageal length and to output pressure changes as high-resolution pressure topography in real time. Recently, HRM has been used to quantify the dynamics of the pharyngeal phase of swallowing, including UES physiology.^{5,6} It is extremely difficult to detect the precise position of the UES during swallowing, even with HRM, because the position changes up and down with the movement of the larynx without application of UES pressure. It is also possible for HRM to provide imprecise information about UES resting pressure due to its unidirectional sensors and averaging of circumferential pressure. Based on the instability of UES pressure changes, this technique may not be realistic for the evaluation of swallowing rehabilitation or CP myotomy,⁷ especially in patients with dysphagia and UES dysfunction. The current study focused on the significance of detailed UES resting pressure analysis (ie, analysis of the closing function of the UES, in which CP muscles maintain a constant resting tone).

To obtain precise UES resting pressure data, circumferential measurements are needed over the longitudinal UES length. Newly developed three-dimensional (3D)-HRM technology includes circumferentially arranged transducers, which permit real-time recording of anal and esophagogastric junction pressure morphologies.⁸⁻¹⁰ We hypothesized that 3D imaging of normal UES resting pressure would be clinically relevant for evaluating the effects of swallowing rehabilitation and CP myotomy. Against this backdrop, the current study aimed to conduct a detailed analysis of UES resting pressure using 3D-HRM.




FIGURE 1 A three-dimensional (3D) high-resolution manometry system. A pressure sensor catheter was prepared measuring 4 mm in outer diameter, with eight-channel transducers (arrow) arranged circumferentially to acquire pressure data at 45° intervals (A,B). A recording and analysis software (Eight Star, Star Medical Inc.) on a personal computer and an automatic drawing device were used with the 3D-high-resolution manometry system (C)

2 | MATERIALS AND METHODS

2.1 | Subjects

Seventeen young, healthy adult participants (7 females and 10 males; mean age, 27.9 ± 4.3 years) were recruited through an advertisement

posted on a bulletin board in Kurume University. None of the participants had any history of structural damage to the head or neck, neurological damage, gastrointestinal disorders, or dysphagia. Mean participant height was 166.5 ± 7.4 cm (range: 159.0-182.0 cm), mean weight was 61.2 ± 10.5 kg (range: 44.0-80.0 kg), and mean body mass index (BMI) was 22.0 ± 2.9 kg/m² (range: 18.0-29.0 kg/m²). This

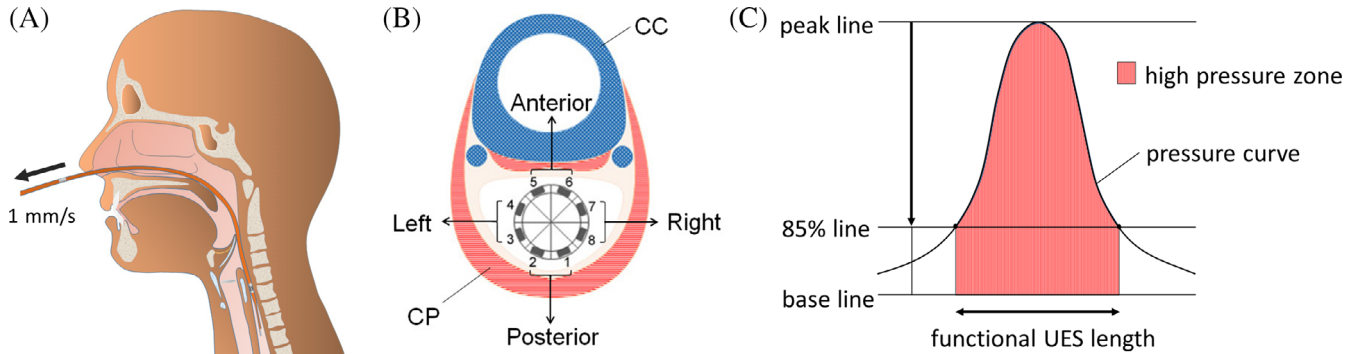


FIGURE 2 Schematic views of measurement and definition of the high-pressure zone. The catheter was retracted using an automatic drawing device (A). An eight-channel transducer acquired circumferential pressure data. Sensors were grouped by averaging pairs of channels into four directions (B), as follows: posterior (channels 1-2), left (channels 3-4), anterior (channels 5-6), and right (channels 7-8). The high-pressure zone was defined as the range within the pressure curve between the intersections of the pressure curve and the 85% line from the peak to the base line (C). CC, cricoid cartilage; CP, cricopharyngeal muscle

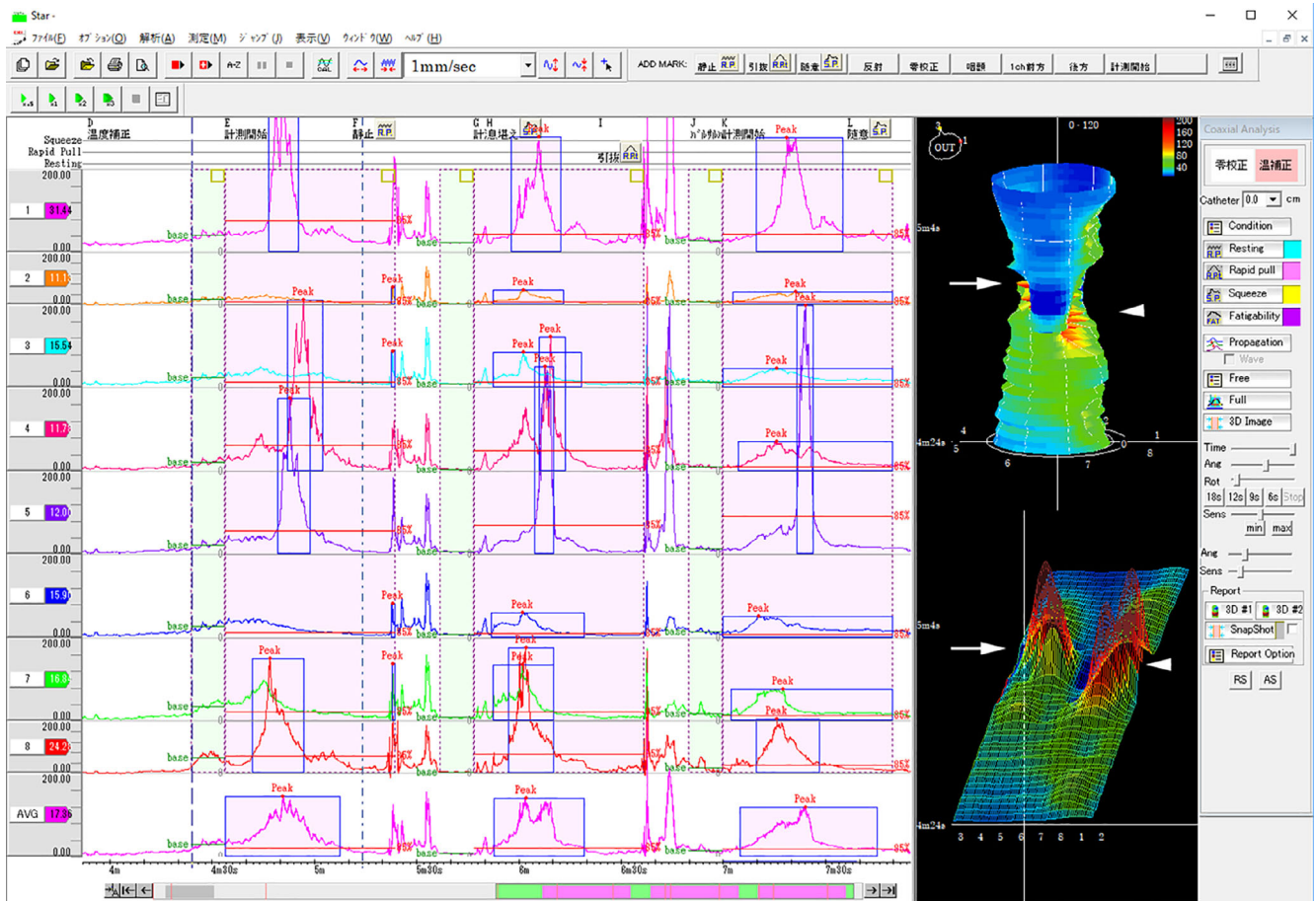


FIGURE 3 Monitor view during measurement. Forty pressure data points per second for each of the eight channels were acquired. The pressure waveforms were converted into three-dimensional (3D) images and displayed. 3D waveforms of the upper esophageal sphincter showed a bimodal distribution of the high-pressure zone in the anterior (arrow) and posterior (arrow head) portions (right upper: 3D cylindrical waveform; right lower: 3D development waveform)

study was approved by the Ethical Committee of Kurume University, and written informed consent was obtained from all participants.

2.2 | Measurements

A 3D-HRM system (Star Medical Inc., Tokyo, Japan) was prepared with a pressure sensor catheter measuring 2 mm in length and 4 mm in outer diameter, and eight-channel transducers arranged circumferentially to acquire pressure data at 45° intervals (Unisensor AG, Bahnstrasse, Switzerland) (Figure 1A,B). A recording/analysis software (Eight Star, Star Medical Inc.) on a personal computer and an automatic drawing device (Star Medical Inc.) were used with the 3D-HRM system (Figure 1C).

The catheter-tip pressure transducer was zeroed at atmospheric pressure before placing the catheter inside the body. Topical 2% viscous lidocaine hydrochloride was applied to the nasal passages and

manometric catheter as a lubricant and topical anesthetic. The catheter was inserted through the unilateral nasal cavity to the esophagus. Placement of the catheter through the UES was confirmed by a laryngeal endoscope inserted through the contralateral nasal cavity. After confirming the high-pressure band of the UES on the 3D-HRM system monitor, catheter insertion was advanced until the sensor was approximately 50 mm inferior to the midline of the bilateral arytenoids. Thermal compensation was also adjusted at this time, as the pressure detected by sensors can be affected by thermal drift.¹¹ Once the catheter was positioned in the UES region, participants were allowed to rest for several minutes before testing began.

The catheter was retracted at a speed of 1 mm/s (Figure 2A) using the automatic drawing device. The 3D-HRM system acquired 40 pressure data points per second per channel. Each measurement took approximately 50 seconds until the sensor passed through the midline of the bilateral arytenoids, which was confirmed by laryngeal endoscopy. All tests were performed at 5-minute intervals on the same day.

Participants were asked to maintain a sitting position and perform the following three tasks for a total of three times each: maintain resting breathing, perform breath holding, and perform the Valsalva maneuver. Data were acquired for each of eight channels over the longitudinal UES length. If spontaneous swallowing occurred during data collection, those trials were excluded. To simplify the results, we adopted the method described by Meyer et al.¹² Specifically, sensors were grouped by averaging pairs of channels into four directions (Figure 2B), as follows: posterior (channels 1-2), left (channels 3-4), anterior (channels 5-6), and right (channels 7-8).

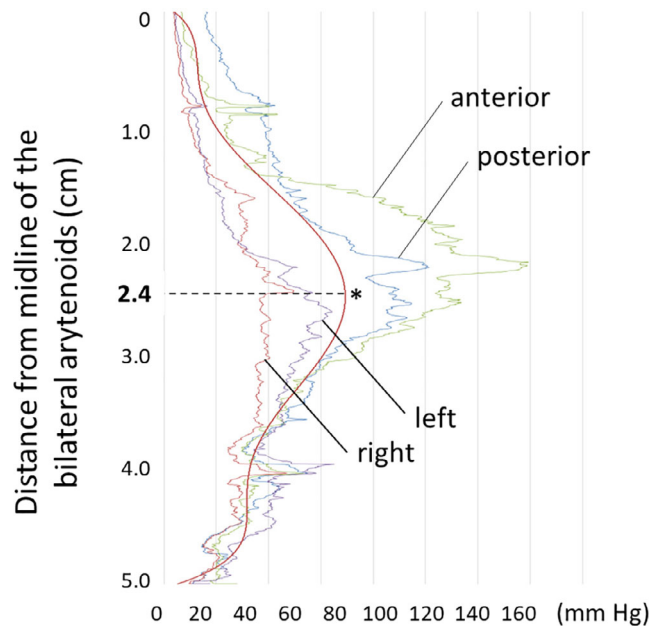


FIGURE 4 Pressure curves from raw data and average trend line in four directions. The mean distance from the midline of the bilateral arytenoids to the highest trend line point (asterisk) was 2.4 cm. The anterior distribution was located superior to the posterior and bilateral distributions

2.3 | Data analysis

The average pressure during the initial 10 seconds of catheter retraction in the cervical esophagus was regarded as the baseline for each channel. The subsequent 40 seconds were used for analysis of the HPZ. The HPZ was defined as the range within the pressure curve between the intersections of the pressure curve and the 85% line from the peak to the base line (Figure 2C). Pressure curves from raw data in four directions were graphed, and each direction was compared. 3D-UES resting pressure data were automatically calculated and assessed by the following measurements: (a) functional UES

TABLE 1 Correlations between manometric values at rest and height, weight, and BMI

		Functional UES length (mm)			Mean UES pressure (mm Hg)			UES resting integral (mm Hg s)		
		Male	Female	Total	Male	Female	Total	Male	Female	Total
Manometric value	Mean ± SD	22.6 ± 3.7	24.9 ± 4.2	23.5 ± 3.8	32.5 ± 9.1	42.1 ± 19.2	36.5 ± 11.5	1134.8 ± 309.1	1712.6 ± 774.7	1372.7 ± 413.2
r Value	Height	.26	-.05	.05	-.21	.27	-.15	.02	.17	-.15
	Weight	-.21	.38	-.09	-.67	.33	-.36	-.60	.31	-.34
	BMI	-.32	.76	-.14	-.54	.32	-.35	-.57	.41	-.33

Note: r Value represents Pearson's product-moment correlation coefficient. Abbreviations: BMI, body mass index; UES, upper esophageal sphincter.

length (mm) in the HPZ; (b) mean UES pressure (mmHg) in the HPZ; and (c) UES resting integral (mm Hg s) of the average integral values in the HPZ. Manometric results of resting breathing were documented according to participant gender. All manometric results were compared in four directions (posterior, left, anterior, and right) for each task.

2.4 | Statistical analysis

Correlations between manometric values at rest and height, weight, and BMI were assessed using Pearson's correlation analysis. Strength

correlations were determined using the guide suggested by Evans for the absolute *r* value.¹³ Paired *t* tests were used for paired samples according to tasks or directions. All statistical analyses were performed using JMP 10 for Windows (ATMS, Tokyo, Japan). *P* < .05 was considered statistically significant.

3 | RESULTS

Measurements during resting breathing were successfully completed by all participants. Measurements during breath holding and the Valsalva maneuver could not be achieved for one participant each,

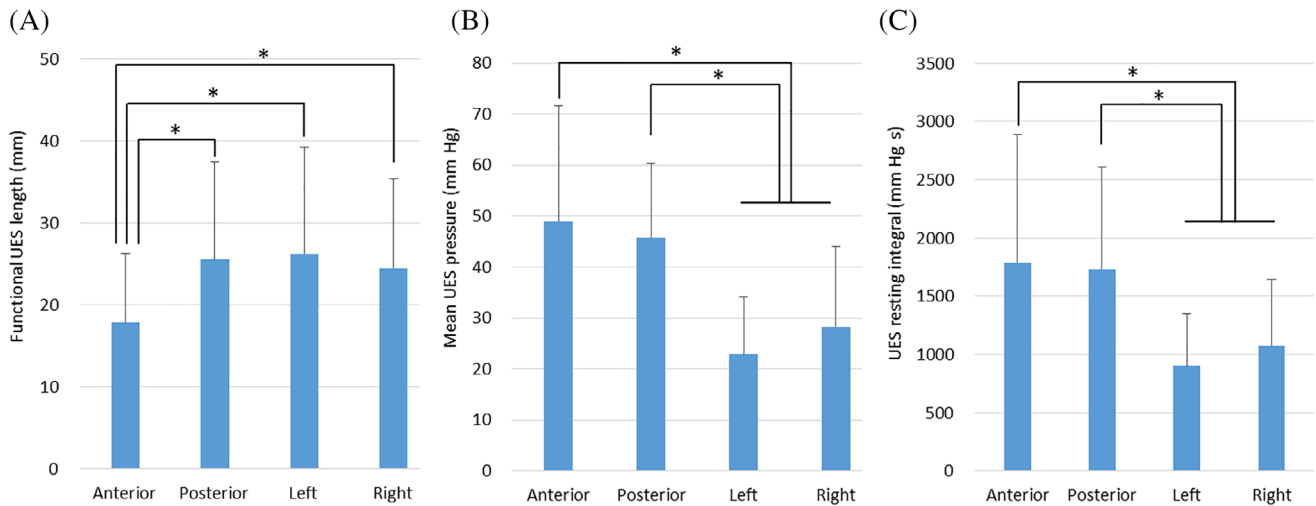


FIGURE 5 Comparison of data in four directions (anterior, posterior, left, and right). The functional UES length was significantly shorter in the anterior direction than in other directions (A). Mean UES pressures were significantly higher in the anterior and posterior directions than in bilateral directions (B). UES resting integrals were significantly higher in the anterior and posterior directions than in bilateral directions (C).

**P* < .05. UES, upper esophageal sphincter

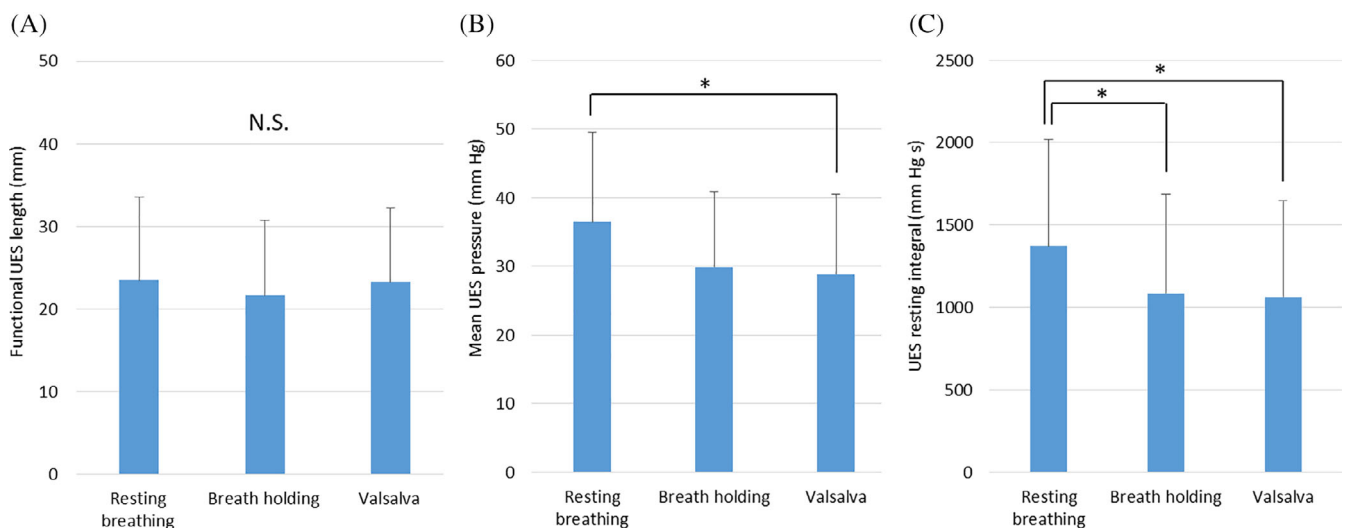


FIGURE 6 Comparisons of data during three tasks (resting breathing, breath holding, and Valsalva maneuver). No significant differences in functional UES lengths were noted between the three tasks (A). Mean UES pressure was significantly higher during resting breathing than during the Valsalva maneuver (B). The UES resting integral was significantly higher during resting breathing than during breath holding or the Valsalva maneuver (C). **P* < .05. NS, not significant; UES, upper esophageal sphincter

due to noncontinuous breath holding and strong discomfort, respectively. 3D waveforms of the UES showed a bimodal distribution of the HPZ in the anterior and posterior directions (Figure 3). 3D waveforms were clearly visualized in various directions in all participants using 3D-HRM.

Pressure curves from raw data and an average trend line for the four measured directions are shown in Figure 4. Distances from the midline of the bilateral arytenoids to the highest trend line point in anterior, posterior, right, and left directions were 2.3, 2.4, 2.7, and 2.8 cm, respectively (mean, 2.4 cm). The anterior distribution was located superior to the posterior and bilateral distributions.

Manometric results for resting breathing and correlations between the manometric values and height, weight, and BMI are shown in Table 1. The functional UES length was 23.5 ± 3.8 mm. A strong positive correlation was observed between the functional UES

length and BMI scores in females ($r = .76$). The mean UES pressure was 36.5 ± 11.5 mm Hg. A strong negative correlation was observed between the mean UES pressure and weight in males ($r = -.67$). The UES resting integral was 1372.7 ± 413.2 mm Hg s. A strong negative correlation was observed between the UES resting integral and weight in males ($r = -.60$). The other measurements showed less than moderate correlations ($-.60 < r < .60$).

Functional UES length was significantly shorter in the anterior direction than in other directions (Figure 5A). Mean UES pressures were significantly higher in the anterior and posterior directions than in bilateral directions (Figure 5B). UES resting integrals were also significantly higher in anterior and posterior directions than in bilateral directions (Figure 5C).

No significant differences in functional UES length were noted between the three tasks (Figure 6A). Mean UES pressure was

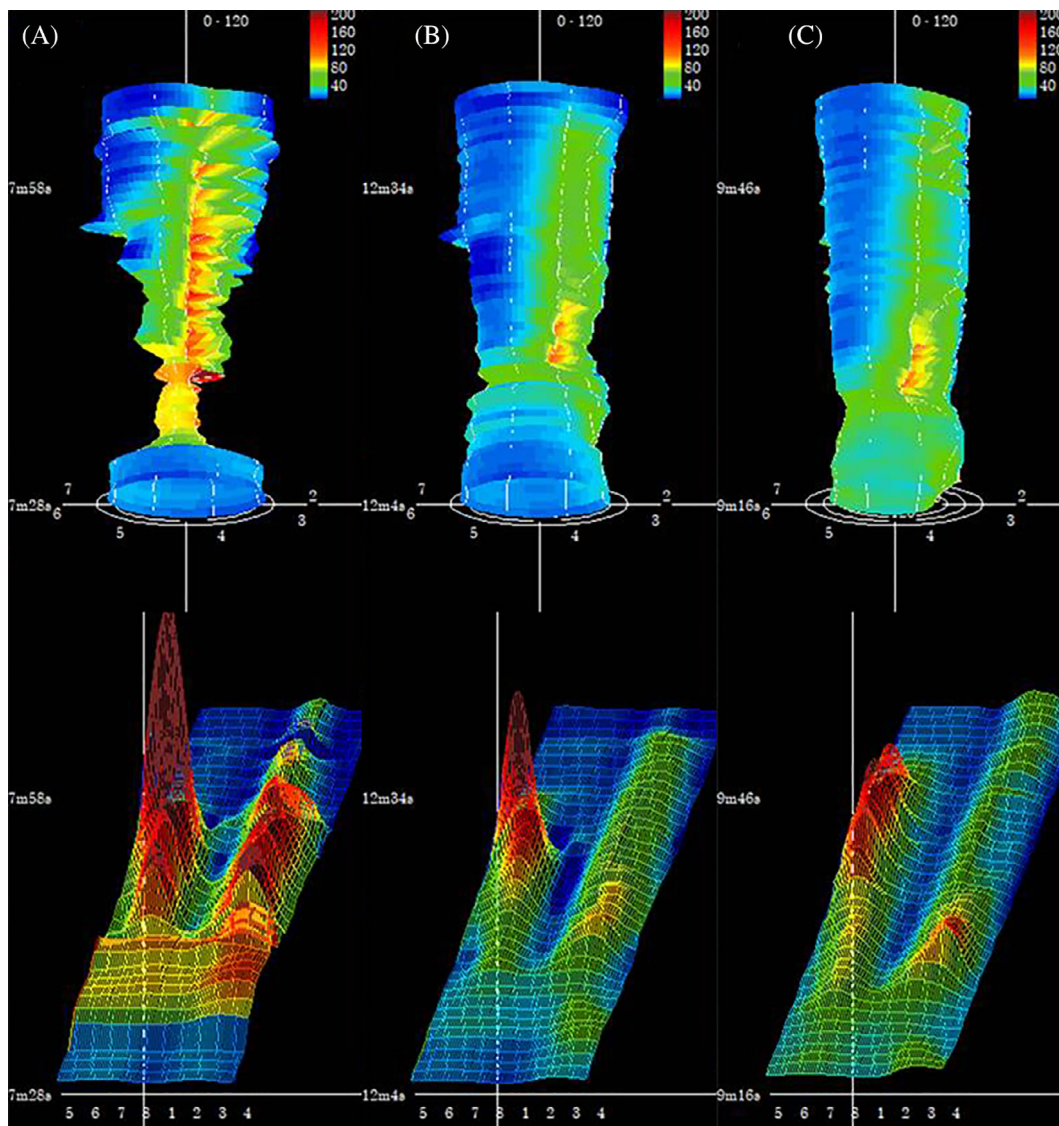


FIGURE 7 UES three-dimensional (3D) waveform case example. A bimodal distribution of the HPZ in the anterior and posterior portions was clearly visualized during resting breathing (A). The HPZ during breath holding (B) and the Valsalva maneuver (C) was smaller than that during resting breathing (upper: 3D cylindrical waveform; lower: 3D development waveform). HPZ, high-pressure zone; UES, upper esophageal sphincter

significantly higher during resting breathing than during the Valsalva maneuver (Figure 6B). The UES resting integral was significantly higher during resting breathing than during breath holding or the Valsalva maneuver (Figure 6C). An example of UES 3D waveforms is shown in Figure 7. A bimodal distribution of the HPZ in the anterior and posterior directions can be clearly visualized during resting breathing (Figure 7A). HPZs in 3D cylindrical and development waveforms had a lower peak during breath holding (Figure 7B) and the Valsalva maneuver (Figure 7C) than that during resting breathing.

4 | DISCUSSION

Analysis of UES closing function was performed using 3D-HRM. We found that normal UES resting pressure was not uniform in the luminal structure, but that there was a bimodal distribution in the anterior and posterior portions. The HPZ in the anterior direction (postcricoid structures) was located more superiorly than the posterior portion (dorsal median of the CP muscle). These findings suggest that a detailed analysis of UES resting pressure using 3D-HRM could help deepen our understanding of UES physiology.

The pressure component is based on the passive elasticity of the tissues, and the UES pressure is not entirely the result of myogenic activity. The CP muscle, which is tonically active, has a high degree of elasticity.¹ Conventional manometry cannot easily represent the internal pressures of uneven cylindrical structures (such as the UES) with 3D imaging. Welch et al first provided a 3D representation of UES pressure characterized by anteroposterior enhancement of peak pressures and also by consistent axial asymmetry with an oral shift of anterior pressures.¹⁴ Meyer et al analyzed UES resting pressure and swallowing pressure in different axial directions using a catheter with circumferentially arranged transducers.¹² They suggested that resting anteroposterior UES pressure was due to passive pressure from the spine and cricoid cartilage against the manometric sensors. However, the sensors they used had wide intervals (5 mm long with 3 mm spacing) compared to the UES length, potentially making it difficult to clearly visualize UES resting pressure. Winans et al reported that UES resting pressure was 100 mm Hg in the anterior to posterior direction and 33 mm Hg in the lateral direction.¹⁵ These results are clear from the anatomical features that the CP muscle does not extend around the entire circumference of the UES, but that it adheres to the cricoid cartilage in the anterior portion. Belafsky et al also described the cross-sectional area of the UES to be kidney shaped due to this anatomic configuration, with compression between the cricoid lamina and vertebral bodies resulting in a flattened anterior-posterior portion.^{16,17}

Mean UES resting pressures have previously been reported to be 70 ± 30 mm Hg in males and 62 ± 27 mm Hg in females using a catheter of 4 mm diameter by Takasaki et al.⁵ Using a catheter of 2.64 mm diameter, Matsubara et al¹⁸ reported mean UES resting pressures of 4 ± 13 mm Hg in total, 47 ± 16 mm Hg in males, and 42 ± 9 mm Hg in females. In the current study, the mean overall UES resting pressure of 36.5 ± 11.5 mm Hg using a catheter of 4 mm diameter

was lower than that observed in previous reports. One possible reason for this difference is that the current study calibrated measurement values based on the HPZ definition, to define UES length.

The CP muscle constitutes only the lowest one-third of the entire HPZ.¹ Esaki reported that mean longitudinal dorsal median lengths of the CP muscle were 26.8 mm in males and 22.1 mm in females, based on 40 adult autopsies.¹⁸ Matsubara et al measured the UES of 30 healthy participants using conventional HRM, and found the mean length to be 34 mm.¹⁹ Functional UES lengths in the current 3D-HRM study were 24.9 ± 4.2 mm in males and 22.6 ± 3.7 mm in females. The functional UES length also anatomically approximated the dorsal median length of the CP muscle. The measured length was shorter than HPZ length measurements obtained via conventional HRM with transducers arranged in 10 mm intervals longitudinally.

Performing certain voluntary maneuvers can alter pressure distribution. The current study found no differences in functional UES length during the three tasks, but both mean UES pressure and UES resting integral decreased with breath holding and the Valsalva maneuver. These breath-holding postures may pull the cricoid away from the spine to engage the CP muscle, thereby reducing the effect of anteroposterior forces.¹² Therefore, breath holding and the Valsalva maneuver may be useful for relaxing the CP muscle during swallowing rehabilitation. The supraglottic swallow rehabilitation technique²⁰ may be meaningful not only to protect the upper airway well in advance of the bolus arriving, but also to propel the bolus into the esophagus.

This study has a few limitations worth noting. First, 3D data were measured using a pull-through method of manometry with a single-point sensor. Nicodème et al reported that sphincter length assessed by the pull-through method greatly exaggerated the estimate of lower esophageal sphincter length, because circumferential diaphragm contractile pressure and asymmetric extrinsic pressure signals attributable to other structures are indistinguishable.⁹ Second, our study does not consider the possibility that the motion of the posterior cricoarytenoid muscle during breathing affected measurement results during resting breathing. Third, it is logistically difficult to compare findings with other reports due to differences in measurement conditions, such as catheter diameter, type of transducer, and sensor spacing. Lydon et al reported that smaller catheter diameters in the body were associated with lower pressure measurements.²¹ Therefore, a different manometric system would be useful for assessing individual differences in treatment effects before and after swallowing rehabilitation or surgery.

5 | CONCLUSIONS

The current study analyzed UES closing functions using 3D-HRM and found that normal UES resting pressure was not directionally uniform in the luminal structure, but rather that it exhibited a bimodal distribution in the anterior and posterior directions. The anterior portion of the HPZ was located superiorly to the posterior portion. These findings suggest that a detailed analysis of UES resting pressure using 3D-HRM can help deepen our understanding of UES physiology.

ACKNOWLEDGMENTS

This work was supported by a JSPS KAKENHI, Grant No. 16K11250 from Grant-in-Aid for Scientific Research (C), Tokyo (<http://www.jsp.go.jp/english/e-grants/>).

CONFLICT OF INTEREST

The authors declare no potential conflicts of interest with respect to this study, authorship, and/or publication of this article.

ORCID

Shun-ichi Chitose  <https://orcid.org/0000-0002-9307-2331>

Kiminori Sato  <https://orcid.org/0000-0001-5415-0176>

Takeharu Ono  <https://orcid.org/0000-0003-2414-7034>

REFERENCES

- Sivarao DV, Goyal RK. Functional anatomy and physiology of the upper esophageal sphincter. *Am J Med*. 2000;108(Suppl 4a):275-375.
- Palmer JB, Tanaka E, Ensrud E, et al. Motion of the posterior pharyngeal wall in human swallowing: a quantitative videofluorographic study. *Arch Phys Med Rehabil*. 2000;81:1520-1526.
- Clouse RE, Staiano A. Topography of the esophageal peristaltic pressure wave. *Am J Physiol*. 1991;261(4 Pt 1):G677-G684.
- Pandolfino JE, Roman S. High-resolution manometry: an atlas of esophageal motility disorders and findings of GERD using esophageal pressure topography. *Thorac Surg Clin*. 2011;21:465-475.
- Takasaki K, Umeki H, Enatsu K, et al. Investigation of pharyngeal swallowing function using high-resolution manometry. *Laryngoscope*. 2008;118:1729-1732.
- McCulloch TM, Hoffman MR, Ciucci MR. High-resolution manometry of pharyngeal swallow pressure events associated with head turn and chin tuck. *Ann Otol Rhinol Laryngol*. 2010;119:369-376.
- Chitose S, Sato K, Hamakawa S, Umeno H, Nakashima T. A new paradigm of endoscopic cricopharyngeal myotomy with CO₂ laser. *Laryngoscope*. 2011;121:567-570.
- Kwiatk MA, Pandolfino JE, Kahrilas PJ. 3D-high resolution manometry of the esophagogastric junction. *Neurogastroenterol Motil*. 2011;23:e461-e469.
- Nicodème F, Lin Z, Pandolfino JE, Kahrilas PJ. Esophagogastric junction pressure morphology: comparison between a station pull-through and real-time 3D-HRM representation. *Neurogastroenterol Motil*. 2013;25:e591-e598.
- Banasiuk M, Banaszkiwicz A, Piotrowski D, Albrecht P, Kamiński A, Radzikowski A. 3D high-definition manometry in evaluation of children after surgery for Hirschsprung's disease: a pilot study. *Adv Med Sci*. 2016;61:18-22.
- Robertson EV, Lee YY, Derakhshan MH, et al. High-resolution esophageal manometry: addressing thermal drift of the manoscan system. *Neurogastroenterol Motil*. 2012;24:61-64.
- Meyer JP, Jones CA, Walczak CC, McCulloch TM. Three-dimensional manometry of the upper esophageal sphincter in swallowing and non-swallowing tasks. *Laryngoscope*. 2016;126:2539-2545.
- Evans JD. *Straightforward Statistics for the Behavioral Sciences*. Brooks/Cole: Pacific Grove; 1996.
- Welch RW, Luckmann K, Ricks PM, Drake ST, Gates GA. Manometry of the normal upper esophageal sphincter and its alterations in laryngectomy. *J Clin Invest*. 1979;63:1036-1041.
- Winans CS. The pharyngoesophageal closure mechanism: a manometric study. *Gastroenterology*. 1972;63:768-777.
- Belafsky PC, Plowman EK, Mehdizadeh O, Cates D, Domer A, Yen K. The upper esophageal sphincter is not round: a pilot study evaluating a novel, physiology-based approach to upper esophageal sphincter dilation. *Ann Otol Rhinol Laryngol*. 2013;122:217-221.
- Cates D, Plowman EK, Mehdizadeh O, et al. Geometric morphometric shape analysis in an ovine model confirms that the upper esophageal sphincter is not round. *Laryngoscope*. 2013;123:721-726.
- Esaki S. A clinicoanatomical investigation of the cricopharyngeus muscle. *Otologia Fukuoka*. 1983;29:162-176.
- Matsubara K, Kumai Y, Samejima Y, Yumoto E. Swallowing pressure and pressure profiles in young healthy adults. *Laryngoscope*. 2014;124:711-717.
- Logemann JA. *Evaluation and Treatment of Swallowing Disorders*. San Diego, CA: College Hill Press; 1983.
- Lydon SB, Dodds WJ, Hogan WJ, Arndorfer RC. The effect of manometric assembly diameter on intraluminal esophageal pressure recording. *Am J Dig Dis*. 1975;20:968-970.

How to cite this article: Chitose S-i, Shin Y, Sato K, et al. Three-dimensional imaging of upper esophageal sphincter resting pressure. *Laryngoscope Investigative Otolaryngology*. 2019;4:645-652. <https://doi.org/10.1002/lio2.324>