

# Successful catheter ablation of idiopathic ventricular tachycardia originating from the top of the left ventricular posterior papillary muscle near the chordae tendineae: Usefulness of intracardiac three-dimensional echocardiography



Hiroshi Kawakami, MD,<sup>\*</sup> Takashi Noda, MD, PhD,<sup>\*</sup> Koji Miyamoto, MD,<sup>\*</sup> Kazuhiro Satomi, MD, PhD,<sup>†</sup> Wataru Shimizu, MD, PhD,<sup>‡</sup> Kengo F Kusano, MD, PhD<sup>\*</sup>

From the <sup>\*</sup>Division of Arrhythmia and Electrophysiology, Department of Cardiovascular Medicine, National Cerebral and Cardiovascular Center, Suita, Japan, <sup>†</sup>Department of Cardiology, Tokyo Medical University Hachioji Medical Center, Tokyo, Japan, and <sup>‡</sup>Department of Cardiovascular Medicine, Nippon Medical School, Tokyo, Japan.

## Introduction

Idiopathic ventricular tachycardias (VTs) may originate from several sites in the left ventricle (LV).<sup>1,2</sup> It was shown recently that the LV papillary muscles (PMs) can give rise to ventricular arrhythmias (VAs) in patients without structural heart disease, and radiofrequency (RF) catheter ablation can cure these VAs.<sup>3–5</sup> However, the PMs are complex structures, and VAs originating from them can be difficult to ablate. Previous studies reported that various cardiac imaging modalities, such as intracardiac echocardiography<sup>6</sup> and cardiac magnetic resonance (CMR) imaging, were useful for detecting the origin of idiopathic VTs.<sup>7</sup> We report the case of a patient with VT originating from the top of the LV posterior papillary muscle (PPM) near the chordae tendineae, which was successfully eliminated by catheter ablation guided by 3-dimensional intracardiac echocardiography and confirmed by CMR imaging after ablation.

## Case report

A 48-year-old man was admitted to our hospital because of ventricular tachycardia (VT). His chief complaint was palpitations during the VT; however, his hemodynamic status was stable. He had no structural heart disease or family history of sudden cardiac death. Twelve-lead ECG

during the VT showed QRS complexes with right bundle branch block-type morphology and left-axis deviation, suggesting an LV posterior origin of the VT (Figure 1A). VT cycle length was 310 ms. Verapamil infusion was not effective in terminating the VT. After spontaneous termination of the VT, transthoracic echocardiography demonstrated a reduced left ventricular ejection fraction (LVEF) of 40%.

Electrophysiologic study and catheter ablation were performed the day after admission. Programmed ventricular stimulation with intravenous isoproterenol infusion easily induced the clinical VT. However, burst pacing from the right atrium and both ventricles during VT could not entrain the tachycardia. Therefore, the VT mechanism was thought to be abnormal automaticity or triggered activity rather than reentry. The LV activation map was constructed during VT using an electroanatomic mapping system (CARTO 3, Biosense Webster, Diamond Bar, CA) and a 3-dimensional intracardiac echocardiography image integration system (CARTOSOUND, Biosense Webster). The activation map showed that the earliest activation site during VT was located near the PPM (Figures 1B and 1C). The local bipolar electrogram at that site preceded QRS onset by 40 ms. An excellent pace-map was obtained at this site. After detailed mapping, RF energy was delivered to that site using a 3.5-mm-tip open-irrigated ablation catheter (Navi-Star ThermoCool, Biosense Webster) and irrigated RF power, which was titrated up to 45 W. Care was taken to limit the temperature to <43°. However, VT with a slight change in QRS morphology was sustained after the first ablation. The site of earliest activation moved to another site near the first ablation lesion, where the local bipolar electrogram preceded QRS onset by 34 ms (Figure 1D). A good pace-map was obtained at this site. The tip of the ablation catheter was touching the top of the LV PPM near the chordae tendineae (Figures 2A and 2B). While monitoring with CARTOSOUND to ensure stable contact of the catheter tip

**KEYWORDS** Ventricular tachycardia; Papillary muscle; Chordae tendineae; Intracardiac echocardiography; Cardiac magnetic resonance imaging; Catheter ablation

**ABBREVIATIONS** CMR = cardiac magnetic resonance; LV = left ventricle; LVEF = left ventricular ejection fraction; PM = papillary muscle; PPM = posterior papillary muscle; RF = radiofrequency; VA = ventricular arrhythmia; VT = ventricular tachycardia  
(Heart Rhythm Case Reports 2015;1:110–113)

**Address reprint requests and correspondence:** Dr. Takashi Noda, 5-7-1 Fujishiro-dai, Suita, Osaka 565-8565, Japan. E-mail address: tnoda@ncvc.go.jp.

## KEY TEACHING POINTS

- The origin of VT is uncommonly located on the surface of the PMs, especially near the junction of the LV PPM and the chordae tendineae, although a deep intramural focus is the likely origin of VAs/VTs from PMs in general.
- Use of 3-dimensional intracardiac echocardiography is important to monitor the stability of the catheter contact during ablation of VTs/VAs originating from endocavitary structures including PMs.
- The bipolar electrogram may have more of a far-field appearance at the successful ablation site.

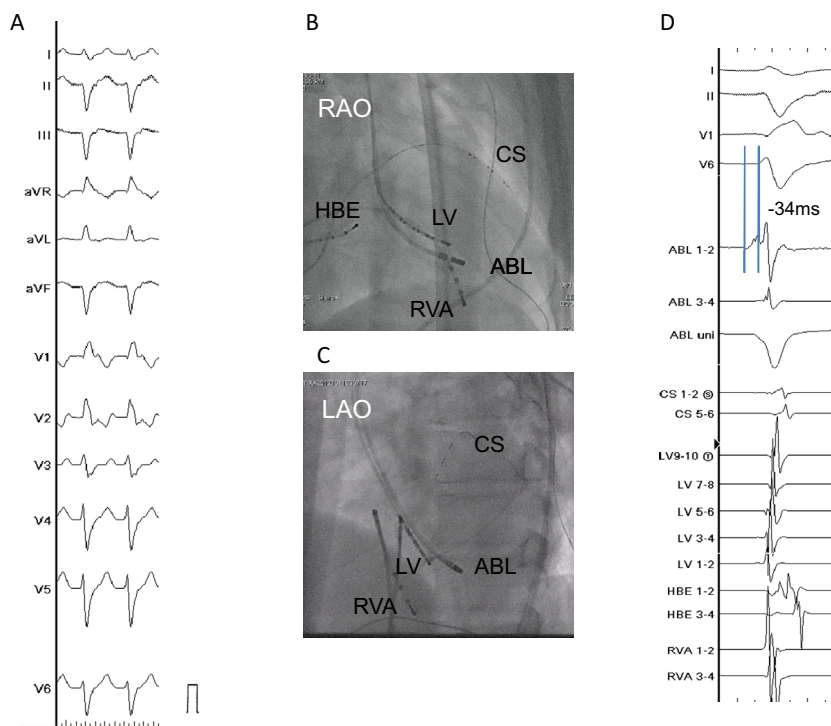
with the top of the LV PPM near the chordae tendineae, this VT was eliminated immediately after delivery of RF energy at that site. A bonus ablation was added at an adjacent site (Figure 3). The total RF time was 645 seconds. Subsequently no VAs could be induced by programmed electrical stimulation during isoproterenol infusion.

CMR imaging performed on the fifth day after ablation (1.5 T, 10-mm slices) identified the ablation site by delayed enhancement that was confined to the top of the LV PPM (Figure 2C). The patient has now remained free of VTs/VAs,

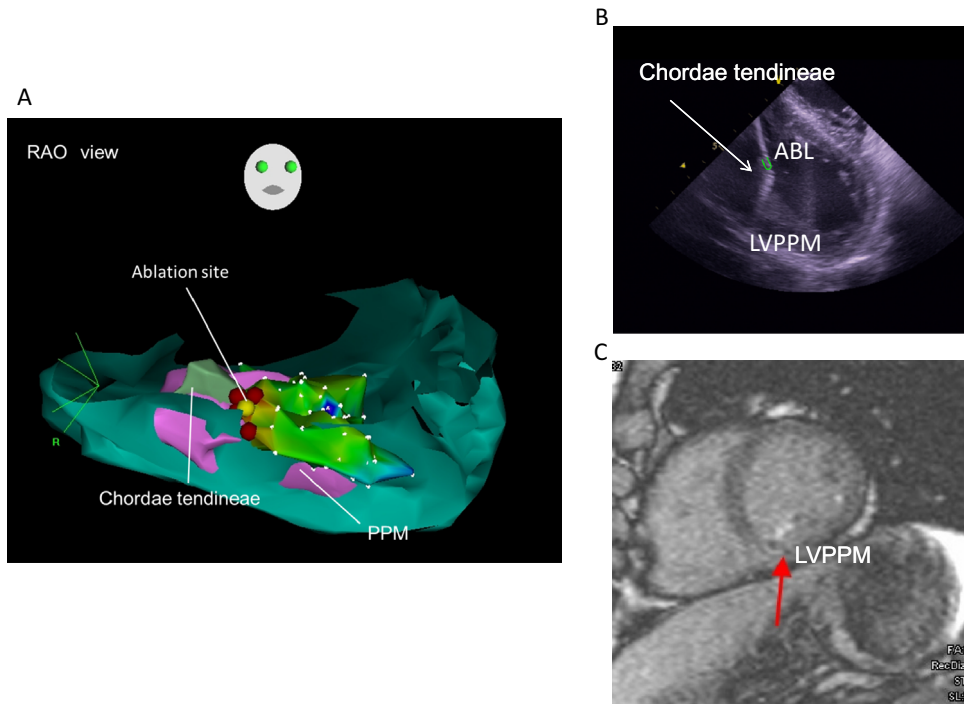
and his LVEF had improved to 60% at 6-month follow-up without any significant mitral regurgitation.

## Discussion

Previous reports revealed that endocavitary structures including PMs in the LV have arrhythmogenicity and harbor the substrate for VTs in patients with or without structural heart disease.<sup>5</sup> Yokokawa et al<sup>8</sup> reported that RF ablation was acutely effective in eliminating VTs/VAs originating from the PMs in 78% of study patients. Yamada et al<sup>9</sup> reported the ECG and electrophysiologic characteristics of idiopathic VAs originating from PMs in the LV. In their study, most idiopathic VAs originating from PMs were eliminated by catheter ablation. However, 2 procedures failed, and VAs recurred in 58% of the study subjects during long-term follow-up. Possible reasons for the results include lack of identification of the precise origin of the VAs and difficulty in maintaining stable catheter contact during ablation. Generally, a deep intramural focus is the likely origin of VAs originating from PMs, and achieving stable contact of the ablation catheter on the PMs during VT is difficult. The electrophysiologic and ablation characteristics of the VT in our patient (focal mechanism without entrainment) and the need for several RF applications were identical to those reported by Yamada et al.<sup>9</sup> However, using CARTOSOUND we confirmed that the tip of the ablation



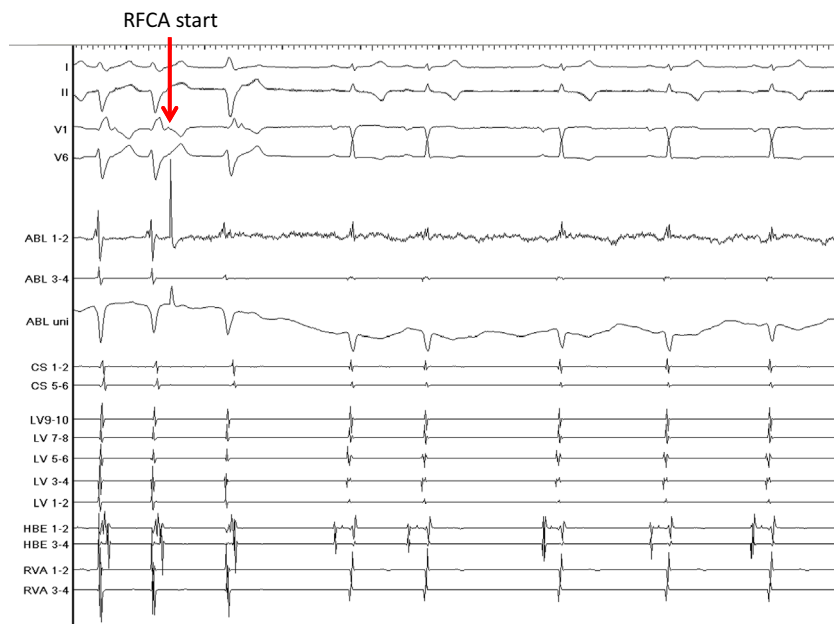
**Figure 1** **A:** Twelve-lead ECG recorded during the clinical ventricular tachycardia (VT) exhibits a QRS complex with right bundle branch block type morphology and left-axis deviation. **B:** Right anterior oblique fluoroscopic views (RAO) of the ablation catheter at the site of successful ablation. **C:** Left anterior oblique fluoroscopic views (LAO) of the ablation catheter at the site of successful ablation. The ablation catheter is located on the left ventricular posterior papillary muscle (LV PPM). **D:** Intracardiac electrogram recordings during the clinical VT. The local bipolar electrogram recorded from the ablation (ABL) catheter (ABL1-2) precedes QRS onset by 34 ms. There was a QS pattern in the ABL unipolar recording. I, II, V<sub>1</sub>, V<sub>6</sub> = surface ECGs; ABL = ablation catheter; CS 1 to 6 = first to sixth electrode pairs of the coronary sinus catheter; LV 1 to 10 = first to tenth electrode pairs of the left ventricular catheter; HBE 1 to 4 = first to fourth electrode pairs of the His-bundle catheter; RVA 1 to 4 = first to fourth electrode pairs of the right ventricular catheter.



**Figure 2** A: Three-dimensional left ventricular anatomic mapping using a CARTO-based 3-dimensional intracardiac echocardiography image integration system (CARTOSOUND). *Yellow dot* indicates site of successful ablation, which was located at the top of the left ventricular posterior papillary muscle (LV PPM) near the chordae tendineae. B: Intracardiac echocardiographic image showing the site of successful ablation. The tip of the ablation catheter, highlighted by a *green marker*, is touching the top of the LV PPM near the chordae tendineae. C: Two-dimensional short-axis cardiac magnetic resonance image at the level of the LV PPM. The ablation lesions are identified clearly by confined delayed enhancement at the top of the LV PPM near the chordae tendineae (*red arrow*). ABL = ablation catheter; PPM = posterior papillary muscle; RAO = right anterior oblique.

catheter was touching the top of the LV PPM near the chordae tendineae, which indicated that the origin of the VT was adjacent to the top of the LV PPM near the chordae tendineae. Previous studies showed that VTs originating

from the LV PMs arose from the body or base of the PM. However, to the best of our knowledge there are no reports of the origin being at the top of the LV PPM near the chordae tendineae. The bipolar electrogram had more of a far-field



**Figure 3** Ventricular tachycardia (VT) was eliminated immediately after delivery of radiofrequency energy at the top of the left ventricular posterior papillary muscle (LV PPM) near the chordae tendineae. RFCA = radiofrequency catheter ablation; I, II, V<sub>1</sub>, V<sub>6</sub> = surface ECGs; ABL = ablation catheter; CS 1 to 6 = first to sixth electrode pairs of the coronary sinus catheter; LV 1 to 10 = first to tenth electrode pairs of the left ventricular catheter; HBE 1 to 4 = first to fourth electrode pairs of the His-bundle catheter; RVA 1 to 4 = first to fourth electrode pairs of the right ventricular catheter.

appearance, which indicated the VT originated from a deep intramural focus. However, we believe that the origin of VT was located near the junction of the LV PPM and the chordae tendineae because the target VT was terminated just after delivery of RF energy.

Three-dimensional intracardiac echocardiography has been used to assist with catheter ablation. Seiler et al<sup>10</sup> reported that better catheter contact on the lateral aspect of the LV PPM could be established using intracardiac echocardiography, and thus a high rate of ablation success could be achieved. Our successful catheter ablation was due in part to use of CARTOSOUND during RF energy delivery to monitor the stability of the contact between the catheter tip and the top of the LV PPM near the chordae tendineae. Moreover, PMs are situated within the LV cavity and are surrounded by other endocavitary structures with electrical properties, including false tendons, aberrant chords, and Lancisi fibers, which could play a role in VTs/VAs. By careful echocardiographic examination using CARTOSOUND, we could not find any endocavitary structures other than the PM in our patient. Our results indicate that a 3-dimensional intracardiac echocardiography image integration system (CARTOSOUND) is useful for identifying detailed structures in the LV cavity and for monitoring the stability of catheter contact during ablation of VTs/VAs originating from endocavitary structures, including PMs. CMR imaging has been used recently to identify cauterized ablation lesions and their size after RF catheter ablation of VT.<sup>7</sup> In addition to intracardiac echocardiography, which confirmed that the successful ablation site was located at the top of the LV PPM near the chordae tendineae, CMR imaging with delayed enhancement after ablation in our case showed that the cauterized lesion was relatively superficial and included the top of the LV PPM. However, we could not perform CMR before ablation, so a study limitation is that we could not compare CMR imaging before and after ablation.

This case report describes VT originating from the top of the LV PPM near the chordae tendineae. The origin of the VT was confirmed by 3-dimensional intracardiac

echocardiography and cardiac magnetic resonance imaging. Three-dimensional intracardiac echocardiography facilitates catheter ablation of VAs originating from endocavitary structures such as PMs by identifying detailed structures in the LV cavity and ensuring stable contact of the ablation catheter during energy delivery.

## References

1. Ohe T, Shimomura K, Aihara N, Kamakura S, Matsuhisa M, Sato I, Nakagawa H, Shimizu A. Idiopathic sustained left ventricular tachycardia: clinical and electrophysiologic characteristics. *Circulation* 1988;77:560–568.
2. Abouezzeddine O, Suleiman M, Buescher T, Kapa S, Friedman PA, Jahangir A, Mears JA, Ladewig DJ, Munger TM, Hammill SC, Packer DL, Asirvatham SJ. Relevance of endocavitary structures in ablation procedures for ventricular tachycardia. *J Cardiovasc Electrophysiol* 2010;21:245–254.
3. Liu XK, Barrett R, Packer DL, Asirvatham SJ. Successful management of recurrent ventricular tachycardia by electrical isolation of anterolateral papillary muscle. *Heart Rhythm* 2008;5:479–482.
4. Doppalapudi H, Yamada T, McElderry HT, Plumb VJ, Epstein AE, Kay GN. Ventricular tachycardia originating from the posterior papillary muscle in the left ventricle: a novel clinical syndrome. *Circ Arrhythmia Electrophysiol* 2008;1: 23–29.
5. Yamada T, Doppalapudi H, McElderry HT, Okada T, Murakami Y, Inden Y, Yoshida Y, Kaneko S, Yoshida N, Murohara T, Epstein AE, Plumb VJ, Kay GN. Idiopathic ventricular arrhythmias originating from the papillary muscles in the left ventricle: prevalence, electrocardiographic and electrophysiological characteristics, and results of the radiofrequency catheter ablation. *J Cardiovasc Electrophysiol* 2010;21:62–69.
6. Yamada T, McElderry HT, Doppalapudi H, Kay GN. Real-time Integration of intracardiac echocardiography and electroanatomic mapping in PVCs arising from the LV anterior papillary muscle. *Pacing Clin Electrophysiol* 2009;32: 1240–1243.
7. Ilg K, Baman TS, Gupta SK, Swanson S, Good E, Chugh A, Jongnarangsin K, Pelosi F Jr, Crawford T, Oral H, Morady F, Bogun F. Assessment of radiofrequency ablation lesions by CMI imaging after ablation of idiopathic ventricular arrhythmias. *JACC Cardiovasc Imaging* 2010;3:278–285.
8. Yokokawa M, Good E, Desjardins B, Crawford T, Jongnarangsin K, Chugh A, Pelosi F Jr, Oral H, Morady F, Bogun F. Predictors of successful catheter ablation of ventricular arrhythmias arising from the papillary muscles. *Heart Rhythm* 2010;7:1654–1659.
9. Yamada T, Doppalapudi H, McElderry HT, Okada T, Murakami Y, Inden Y, Yoshida Y, Yoshida N, Murohara T, Epstein AE, Plumb VJ, Litovsky SH, Kay GN. Electrocardiographic and electrophysiological characteristics in idiopathic ventricular arrhythmias originating from the papillary muscles in the left ventricle: relevance for catheter ablation. *Circ Arrhythmia Electrophysiol* 2010;3: 324–331.
10. Seiler J, Lee JC, Roberts-Thomson KC, Stevenson WG. Intracardiac echocardiography guided catheter ablation of incessant ventricular tachycardia from the posterior papillary muscle causing tachycardia-mediated cardiomyopathy. *Heart Rhythm* 2009;6:389–392.