

A Treatment Case of Delayed Aortic Injury: The Patient with Posterior Rib Fracture

Hyun-Seok Park, M.D.¹, Se-Min Ryu, M.D.¹, Seong-Joon Cho, M.D.¹,
Sung-Min Park, M.D.¹, Sun-Hye Lim, M.D.²

A 66-year-old male patient arrived at the emergency room with a crush injury to his chest. Multiple rib fractures, hemothorax on both sides, left scapular fracture, liver laceration, and retroperitoneal hematoma were found upon the radiologic examination. After closed thoracostomy, the patient had been initially admitted to the intensive care unit, but he was transferred to the general ward on the next day. On the 4th post-trauma day, the patient complained of severe pain and there was bloody drainage through the chest tube. This case is an exploration with the consideration of the possibility of major bleeding and the subsequent repair of the descending thoracic aorta. This case is regarded as a case in which the aorta wall was damaged as the sharp margin of the fractured ribs caused continuous irritation.

Key words: 1. Rib fractures
2. Thoracic injuries
3. Aortic rupture

CASE REPORT

A 66-year-old male patient arrived at the emergency room of Kangwon National University Hospital. He was rescued after being jammed between an excavator basket and a wall with some stacked material for 5 minutes. When the patient arrived, the vital signs were stable except the respiratory rate: blood pressure 121/71 mmHg, heart rate 90 beats per minute (bpm), respiratory rate 30 breaths per minute, body temperature 36.9°C, and O₂ saturation 94%. The patient complained of severe pain on the whole left side of his body down to the waist and on the right chest wall. According to the plain radiography and the computed tomography performed in the emergency room, the patient had multiple rib fractures (right,

7th and 8th; left, 3rd to 12th), hemothorax on both sides (left dominant), left scapular fracture, liver laceration, retroperitoneal hematoma, and transverse process fracture of the thoracic and lumbar spine. He was initially admitted to the intensive care unit after closed thoracostomy (Fig. 1). There was no special complication during the chest tube insertion, and the initial drainage was approximately 200 mL. There was bloody drainage during the chest tube insertion; however, it became serous and the patient was transferred to the general ward on the next day. On the 4th post-trauma day, the patient complained of acute pain radiating in the left rear direction. About 400 mL of bloody drainage was found at the collecting bottle at the same time. When the patient complained of pain, he became drowsy as the blood pressure de-

Departments of ¹Thoracic and Cardiovascular Surgery and ²Family Medicine, Kangwon National University School of Medicine

Received: November 25, 2013, Revised: November 30, 2013, Accepted: December 1, 2013, Published online: August 5, 2014

Corresponding author: Hyun-Seok Park, Department of Thoracic and Cardiovascular Surgery, Kangwon National University Hospital, Kangwon National University School of Medicine, 156 Baengnyeong-ro, Chuncheon 200-722, Korea
(Tel) 82-33-241-5740 (Fax) 82-33-241-5740 (E-mail) bluecorr@naver.com

© The Korean Society for Thoracic and Cardiovascular Surgery. 2014. All right reserved.

© This is an open access article distributed under the terms of the Creative Commons Attribution Non-Commercial License (<http://creativecommons.org/licenses/by-nc/3.0>) which permits unrestricted non-commercial use, distribution, and reproduction in any medium, provided the original work is properly cited.

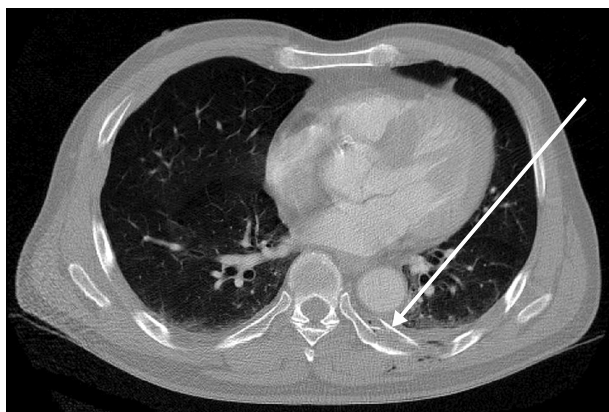


Fig. 1. Initial chest computed tomography (arrow: fractured fragment of 7th rib).

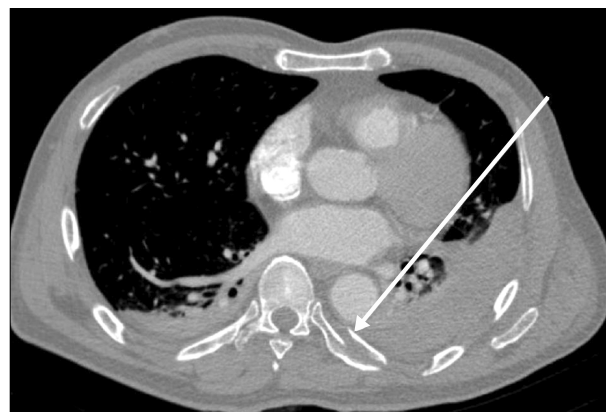

Fig. 2. Follow-up chest computed tomography, 4-post trauma day. Increased hemothorax (arrow: fractured fragment of 7th rib, nearly same plane to Fig. 1).

creased to 70/50 mmHg; however, the blood pressure became 100/70 mmHg after the infusion of 300 mL of isotonic saline. Although the vital signs became stable with a heart rate of 71 beats per minute, respiratory rate of 24 breaths per minute, body temperature of 36.6°C, and O₂ saturation of 99%, bloody drainage of 100 mL or more hourly continued. A fluid resuscitation was done through the intravenous infusion of vitamin K1 and tranexamic acid. Then, plain radiography and computed tomography were performed. From the results of plain radiography and chest computed tomography, we observed that the left hemothorax had increased. At the abdominal computed tomography, a portion of laceration at the liver improved; however, it was decided to perform further exploration on the basis of the judgment that there was a possibility of major bleeding because the retroperitoneal hematoma increased (Fig. 2). At 0:00 (midnight) on the 5th post-trauma day, the patient was transferred to an operating room. After the insertion of the right radial arterial line and the right internal jugular venous central line under general anesthesia, a drape was performed while the patient was in the right lateral decubitus position. When a thoracoscope was inserted after removing the existing chest tube, a huge amount of pleural hematoma was found. The 2nd port was made at the intersection of the 4th intercostal space and the anterior axillary line, and the 3rd port was made at the intersection of the 8th intercostal space and the posterior axillary line. The 3rd port was elongated by 8 cm for bleeding control and hematoma evacuation during one-lung ventilation.

When the hematoma was removed through the 3rd port under the assistance of a thoracoscope, it was possible to find that a fractured fragment of the 7th rib remained in the intrathoracic cavity after penetrating the parietal pleura with its sharp edge. The descending thoracic aorta was just next to it. It was believed that the bleeding originated from the damage of the aorta adventitia inflicted by the fractured rib segment. The sharpness of the rib was dulled by a bone file, and the aorta was repaired by a 2-point interrupted suture using 4-0 prolene (Fig. 3B). Other than this, there was no conspicuous damage at the pleura, diaphragm, lung, or parenchyma. After irrigation by 5 L of warm isotonic saline, two 28-Fr. chest tubes were inserted at the 1st and the 2nd ports, and the operation was completed with routine closure. The patient was checked for stable vital signs and chest tube drain status in the recovery room. Around 4:30 a.m., the patient was transferred to the general ward after extubation.

DISCUSSION

Multiple rib fracture is quite common in blunt chest trauma patients, and it is a major indicator suggesting solid-organ damage in the thoracic cavity or the peritoneal cavity [1,2]. The aorta injury caused by the fractured rib fragment is a major sign of a blunt chest trauma patient; however, the actual occurrence of such an injury is very rare [2]. This case is judged as a case in which the aorta wall was damaged and

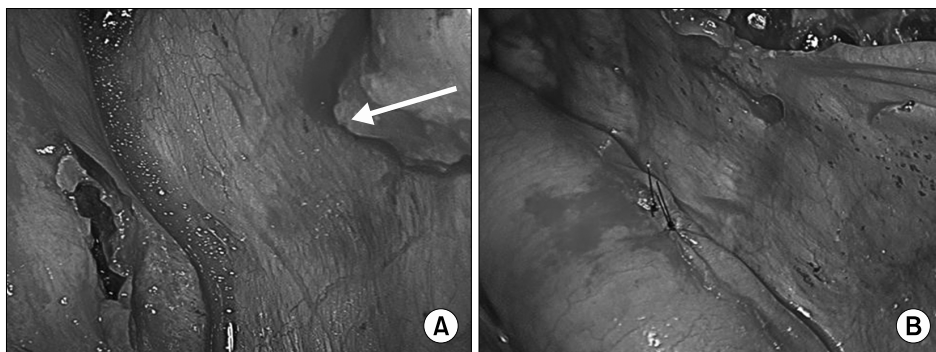


Fig. 3. Intraoperative findings. (A) See fractured fragment and injured adventitia (arrow: fractured fragment of rib. sharp edge was observed). (B) Repair of aortic wall.

the sharp margin of the fractured rib caused continuous irritation. According to O'Connor et al. [3], only 15% of patients with aorta damage at the time of injury can survive until they arrive at a hospital. On the other hand, some delayed injuries caused by the fractured rib fragment are found after few days depending on the case. Carter et al. [4] repaired the impinging of the descending thoracic aorta wall by the fractured 5th rib during a motor vehicle collision on the 3rd post-trauma day. Kano et al. [5] performed the replacement of an ascending thoracic aorta on the 11th post-trauma day (although it was a psychological problem of the patient). There was also a case in which the patient returned home from the emergency room on the injury date because there were no symptoms other than rib fracture; however, a delayed injury was found on the 4th post-trauma day when the patient visited the clinic due to pain [6]. The mechanism of such delay is not clear; however, it was suggested that the penetration of vessels had happened at the time of injury but was immediately clotted; then, the clot was dissolved after a few days. Alternatively, it was suggested that there could have been a new laceration caused by the physical movement of the patient [6,7]. Funaki et al. [8] suggested a video-assisted resection of the fractured fragment to prevent the descending thoracic aorta injury. The patient in the case of this paper also had been generally stable and an acceptable quantity of chest tube drainage. He had been transferred to the general ward, but a bleeding complication occurred 2 days after his transfer to the general ward.

Therefore, even in the case of multiple fractures of the ribs without any external injury, a secondary delayed injury is possible depending on the part of fracture or the shape of the fractured plane. It should be remembered that the delayed in-

jury can have fatal results depending on the damaged part.

CONFLICT OF INTEREST

No potential conflict of interest relevant to this article was reported.

REFERENCES

1. Boyles AD, Taylor BC, Ferrel JR. *Posterior rib fractures as a cause of delayed aortic injury: a case series and literature review.* Inj Extra 2013;44:43-5.
2. Morimoto Y, Sugimoto T, Sakahira H, Matsuoka H, Yoshioka Y, Arase H. *Successful management of threatened aortic rupture late after rib fracture caused by blunt chest trauma.* Ann Vasc Surg 2014;28:1035.e11-3.
3. O'Connor CE. *Diagnosing traumatic rupture of the thoracic aorta in the emergency department.* Emerg Med J 2004; 21:414-9.
4. Carter RR, Orr NT, Minion DJ, Xenos ES. *Aortic injury from posterior rib fracture.* Eur J Cardiothorac Surg 2011; 39:138.
5. Kano M, Chikugo F, Fujimoto E. *Delayed aortic injury caused by sharp rib fracture.* Asian Cardiovasc Thorac Ann 2014;22:500.
6. Bruno VD, Batchelor TJ. *Late aortic injury: a rare complication of a posterior rib fracture.* Ann Thorac Surg 2009; 87:301-3.
7. Kigawa I, Fukuda I, Fujii Y, Yamabuki K. *A sharp edge of the fractured ribs caused the aortic injury at body-position change: a case report.* Nihon Kyobu Geka Gakkai Zasshi 1992;40:1116-20.
8. Funaki S, Inoue M, Minami M, Okumura M. *Video-assisted thoracoscopic resection of fractured ribs to prevent descending aorta injury in patient with chest trauma.* Ann Thorac Cardiovasc Surg 2014;20:173-4.