

Left anterior descending artery percutaneous coronary intervention via the left internal mammary artery in a 54-year-old type 1 diabetic woman: a case report

Przezskórna angioplastyka gałęzi przedniej zstępującej z dostępu przez tętnicę piersiową wewnętrzną lewą u 54-letniej kobiety z cukrzycą typu 1 – opis przypadku

Radostaw Kręcki, Jarostaw Kasprzak

Chair and Department of Cardiology, Medical University of Lodz, Poland

Postep Kardiol Inter 2013; 9, 1 (31): 101–104

DOI: 10.5114/pwki.2013.34035

Abstract

Data on the treatment of left anterior descending artery (LAD) stenosis involving or localized distally to left internal mammary artery anastomosis are scarce and not homogeneous. Both surgery (CABG) and percutaneous interventions (PCI) have been attempted, but the most effective treatment has not yet been established. We report a case of a 54-year-old woman suffering from chronic, stable angina and diabetes type 1 successfully treated with percutaneous angioplasty of LAD via the left internal mammary artery with drug-eluting stent implantation with excellent short-term results.

Key words: percutaneous interventions, left internal mammary artery, diabetes type 1.

Streszczenie

Dostępna wiedza na temat terapii zwężeń w gałęzi przedniej zstępującej (GPZ), zlokalizowanych dystalnie w stosunku do zespolenia z tętnicą piersiową wewnętrzną lewą (*left internal mammary artery* – LIMA) oraz obejmujących to zespolenie, jest skąpa i niejednoznaczna. Podejmowano próby leczenia zarówno przezskórnego (*percutaneous intervention* – PCI), jak i kardiologicznego (*coronary artery bypass grafting* – CABG), ale żadna z tych strategii nie uzyskała jednoznacznej przewagi. W pracy przedstawiono przypadek 54-letniej pacjentki z przewlekłą, stabilną chorobą wieńcową, z nasileniem dolegliwości do III klasy według CCS oraz z cukrzycą typu 1, leczonej metodą angioplastyki GPZ z dostępu przez LIMA, z objęciem zespolenia, zakończonej implantacją stentu uwalniającego lek.

Słowa kluczowe: angioplastyka wieńcowa, tętnica piersiowa wewnętrzną lewa, cukrzyca typu 1.

Introduction

There are insufficient data regarding the treatment of left anterior descending artery (LAD) stenosis located distally to its anastomosis with the left internal mammary artery (LIMA) or at the site of anastomosis. Percutaneous (PCI) and surgical (CABG) treatment attempts have been made, but none of these strategies showed a clear advantage.

Aim

We present a case of a 54-year-old woman with chronic, stable coronary artery disease (CCS class III) and diabetes type 1 treated with PCI of the LAD through the LIMA with

anastomosis coverage and finished with drug-eluting stent (DES) implantation.

Case report

A 54-year-old woman with a history of coronary artery disease, diabetes type 1 (probably latent autoimmune diabetes in adults (LADA)); the diagnosis was made at the age of 32 years) was electively admitted to the Department of Cardiology, because of worsening symptoms of angina (CCS class III). Medical history also included hypercholesterolemia. Coronary artery disease first manifested with ST-elevation myocardial infarction (STEMI) of the anterior wall

Corresponding author/Adres do korespondencji:

Radostaw Kręcki MD, PhD, Chair and Department of Cardiology, Medical University, Bieganski Hospital, 1/5 Kniaziewiczza St, 91-347 Lodz, Poland, e-mail: rkrecki@gazeta.pl

Received: 16.09.2012, accepted: 8.11.2012.

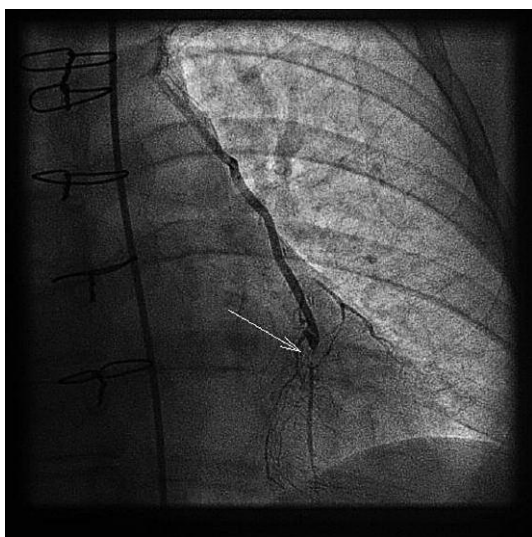


Fig. 1. 99% stenosis of the left anterior descending (LAD) artery just below the site of its anastomosis with the internal mammary artery (arrow) – CRA 30

Ryc. 1. Zwężenie 99% w gałęzi przedniej zstępującej (GPZ) tuż za miejscem wszycia tętnicy piersiowej wewnętrznej lewej (strzałka) – CRA 30

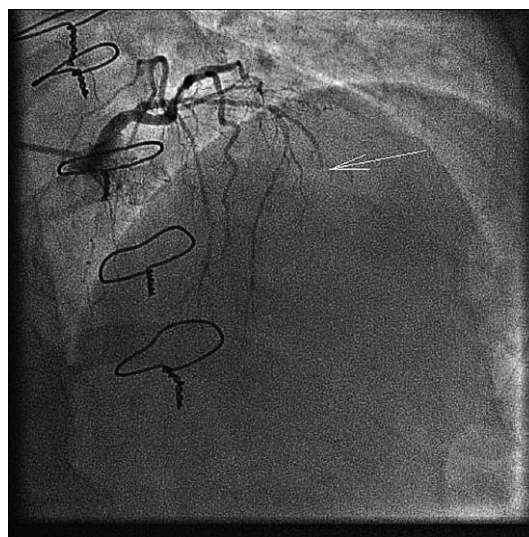


Fig. 2. Angiogram of the native left anterior descending artery after contrast injection to the left main stem – the vessel is amputated in the medial segment above the site of anastomosis with LIMA (arrow) – CRA 30, RAO 30

Ryc. 2. Angiogram natywnej gałęzi przedniej zstępującej z podaniem kontrastu przez pień lewej tętnicy wieńcowej – amputacja naczynia w segmencie środkowym przed miejscem wszycia LIMA (strzałka) – CRA 30, RAO 30

in 2005 (age of the patient at the time of the event was 47 years) and was treated with primary angioplasty of the LAD artery with bare metal stent implantation. Two years later, in 2007, the patient underwent coronary angiography due to worsening of angina symptoms to CCS class III. The examination documented marked progression of coronary artery disease with the presence of 99% restenosis at the site of bare metal stent implantation to the proximal LAD segment and significant stenosis of the right coronary artery (RCA) and circumflex artery (Cx). Because of this clinical picture the patient was qualified for coronary artery bypass grafting. In 2007 the patient underwent an operation consisting of LIMA implantation to the LAD and implantation of saphenous vein grafts to the RCA and to the marginal branch. Because of the unsatisfactory control of glycemia (HbA_{1c}: 9.85%), intensification of therapy with insulin and regular monitoring by a diabetologist were recommended. At the beginning of August 2012 the patient was admitted to the Department of Cardiology again because of the worsening of angina symptoms to CCS class III, which was confirmed by the treadmill test leading to the onset of typical, severe angina pain at 4.6 METs load lasting until the second minute of recovery. Echocardiographic examination demonstrated regional systolic wall motion abnormalities with predominance of hypokinesia of the periapical 1/3 of the left ventricle, which corresponded to the location of the previous myocardial infarction. Left ventricular ejection fraction was 54%. Biochemical tests revealed a high level of glycosylated hemoglobin (HbA_{1c}: 8.83%), LDL cholesterol of 74 mg/dl (on 20 mg of simvastatin) and creatinine level of 0.66 mg/dl (GFR: 105 ml/min). Physical examination showed resting

heart rate of 85/min (on 2.5 mg of bisoprolol). The patient was qualified for coronary angiography from transradial access, which showed both venous grafts amputated at the origin, distally occluded RCA and marginal branch with narrow distal segment supplied by the collateral circulation. The LAD was amputated in the medial segment and there was 99% stenosis of the LAD located just below the site of its anastomosis with LIMA with impaired flow of contrast medium to the peripheries of the vessel (TIMI II) – Figures 1 and 2. Echocardiographic assessment using modern quantitative techniques clearly demonstrated the viability of myocardial segments supplied by the distal LAD [1]. According to guidelines the clinical decision was made by the “heart team” consisting of a cardiac surgeon, an interventional cardiologist and a treating physician (non-interventional cardiologist). Based on this decision the patient was qualified for percutaneous treatment of the LAD stenosis located below the site of anastomosis through the arterial graft and in case this would fail for re-CABG (EuroSCORE risk was estimated at 3.08%). After obtaining informed consent and administration of clopidogrel (300 mg on the day before the procedure) the patient underwent angioplasty of the LAD with femoral access using an IM 6 F guiding catheter and the Pilot 50 angioplasty guidewire (Hi-Torque Guide Wire Pilot 50, Abbott) culminating in the implantation of a sirolimus-eluting stent (2.5 mm × 18 mm, 16 atm). There was a very good angiographic result with improvement of

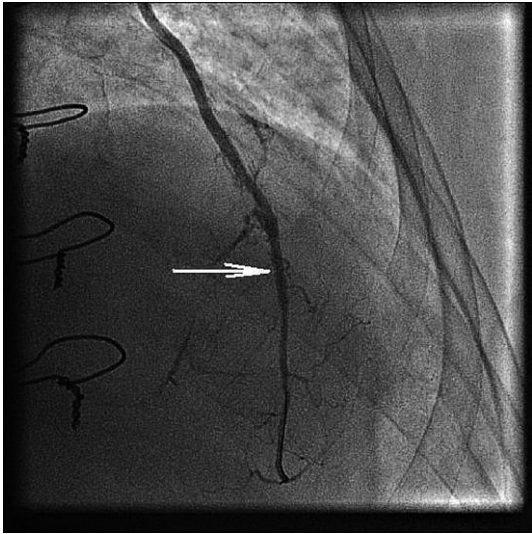


Fig. 3. Left anterior descending artery after angioplasty with DES implantation (arrow) filled with contrast medium injected through the left internal mammary artery – CRA 30

Ryc. 3. Gałąź przednia zstępująca po zabiegu angioplastyki z implantacją DES (strzałka) z podaniem kontrastu przez tętnicę piersiową wewnętrzną lewą – CRA 30

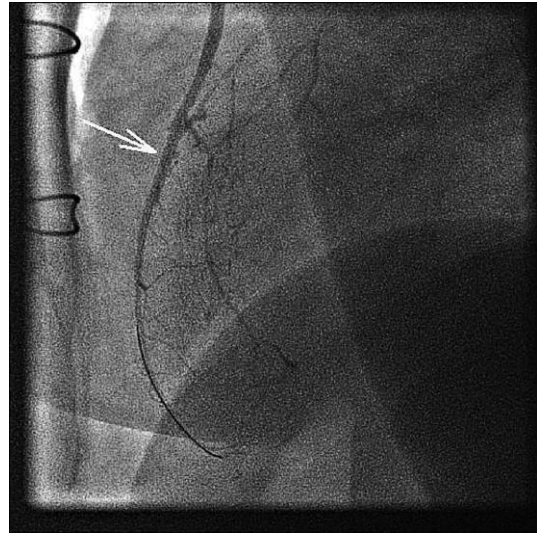


Fig. 4. Left anterior descending artery after angioplasty with DES implantation filled with contrast medium injected through the left internal mammary artery – LAO 90

Ryc. 4. Gałąź przednia zstępująca po zabiegu angioplastyki z implantacją DES (strzałka) z podaniem kontrastu przez tętnicę piersiową wewnętrzną lewą – LAO 90

the blood flow to the LAD and through the network of collateral circulation to the diagonal branch and the right coronary artery (Figures 3 and 4). Wonderful effects of treatment were confirmed clinically by the results of a treadmill test performed at discharge, which was stopped at a load of 8.2 METS without the onset of chest pain or significant ischemic changes in the ECG. The patient was transferred to the Department of Diabetology for the modification of anti-diabetic treatment on the following medications: 10 mg of bisoprolol, 10 mg of perindopril, 40 mg of atorvastatin, 150 mg of aspirin, 75 mg of clopidogrel (for 12 months minimum) and 50 mg of isosorbide mononitrate.

Discussion

At first sight the case presented by us represents a problem of a worsening chronic coronary artery disease routinely diagnosed on cardiologic wards. However, the patient's medical history, angiographic presentation of atherosclerosis and the strategy of treatment developed by the "heart team" create a unique clinical situation. Remarkably accelerated atherosclerosis, early ACS and the whole history of coronary artery disease, which developed in a woman at a very young age (47 years old), are undoubtedly the result of long-term, poorly controlled type 1 diabetes (taking into account the age of diagnosis we are probably dealing with LADA type of diabetes mellitus). This is confirmed by very high values of HbA_{1c}. Despite the efforts made in 2007 after cardiac surgery diabetes control improved only slightly, but remained far from ideal (HbA_{1c}: 8.83%), which is confirmed

by the coronary angiographic image. The dramatic progress of atherosclerosis leading to the occlusion of vein grafts and native coronary arteries with coexisting critical LAD stenosis located just below the site of its anastomosis with the internal mammary artery placed the patient in a high-risk group of cardiovascular events and reflected the severity of angina in the patient's daily life. Improvement of chronotropism and administration of other anti-anginal drugs would have certainly helped to control the symptoms, but total elimination of symptoms as expected by the patient was practically unobtainable. Despite the relatively low risk of reoperation (EuroSCORE 3.08%) the consulting team of experts decided to treat the patient percutaneously with a possible conversion to CABG in case of PCI failure. The decision was based on the very unfavorable conditions for full anatomical surgical revascularization (very narrow peripheral segments of the right coronary artery and the marginal branch). Anatomical conditions such as good LIMA engagement from the subclavian artery with femoral access and direct course of the artery favored this decision. However, the location of stenosis just below the anastomosis (with the necessity of its coverage during stent implantation) increased the periprocedural risk above the average. Knowledge available in the literature on the treatment of LAD stenosis located distally to its anastomosis with the LIMA or including the site of anastomosis is scarce and ambiguous. Attempts are being made to treat these lesions percutaneously or surgically, but none of these strategies has shown a clear advantage, and anatomical diver-

sity implies the need to make individual decisions [2-4]. In the present case, the PCI procedure was fully successful as demonstrated angiographically and clinically. Adequate treatment of diabetes is currently a key factor which can protect the patient from future recurrent cardiologic events.

References

1. Lipiec P, Szymczyk E, Michalski, et al. Echocardiographic assessment of myocardial viability at rest by speckle tracking technique – comparison with stress echocardiography. *Pol Przegl Kardiol* 2010; 12: 281-286.
2. Brilakis ES, Rao SV, Banerjee S, et al. Percutaneous coronary intervention in native arteries versus bypass grafts in prior coronary artery bypass grafting patients: a report from the National Cardiovascular Data Registry. *JACC Cardiovasc Interv* 2011; 4: 844-850.
3. Andrade PJ, Medeiros MM, Andrade AT, Lima AA. Coronary angioplasty versus CABG: review of randomized trials. *Arq Bras Cardiol* 2011; 97: e60-e69.
4. Zavalloni D, Rossi ML, Scatturin M, et al. Drug-eluting stents for the percutaneous treatment of the anastomosis of the left internal mammary graft to left anterior descending artery. *Coron Artery Dis* 2007; 18: 495-500.