



ORIGINAL ARTICLE

# Evaluating the effectiveness of infliximab on perianal fistulizing Crohn's disease by magnetic resonance imaging

Xiaohan Yan<sup>1,†</sup>, Mingming Zhu<sup>1,†</sup>, Qi Feng<sup>2,†</sup>, Yunqi Yan<sup>2</sup>, Jiangchen Peng<sup>1</sup>, Xitao Xu<sup>1</sup>, Antao Xu<sup>1</sup> and Zhihua Ran<sup>1,\*</sup>

<sup>1</sup>Division of Gastroenterology and Hepatology, Key Laboratory of Gastroenterology and Hepatology, Ministry of Health; Shanghai Inflammatory Bowel Disease Research Center; Renji Hospital, School of Medicine, Shanghai Jiao Tong University, Shanghai, China and <sup>2</sup>Department of Radiology, Renji Hospital, School of Medicine, Shanghai Jiao Tong University, Shanghai, China

\*Corresponding author. Division of Gastroenterology and Hepatology, Key Laboratory of Gastroenterology and Hepatology, Ministry of Health; Shanghai Inflammatory Bowel Disease Research Center; Renji Hospital, School of Medicine, Shanghai Jiao Tong University; 145 Middle Shandong Road, Shanghai 200001, China. Tel: +86-13801868827; Email: zhihuan@vip.163.com

†These authors contributed equally to this work.

## Abstract

**Background and aim:** Data on the radiologic evaluation of perianal fistulizing Crohn's disease (PFCD) naïve to anti-tumor necrosis factor therapy are scarce, especially in Asian populations. We assessed the effectiveness of infliximab (IFX) on PFCD and explored predictors of 'deep remission' based on clinical and radiologic assessments.

**Methods:** Patients with Crohn's disease and active anal fistulas attending our care center for IFX therapy were prospectively enrolled. Each patient underwent clinical examination according to the Fistula Drainage Assessment Index, endoscopy for assessment of Crohn's Disease Activity Index (CDAI) and Perianal Crohn's Disease Activity Index (PCDAI), magnetic resonance imaging (MRI) to determine Van Assche score and Ng score, and laboratory tests up to 2 weeks prior to the start of and up to 2 weeks after the sixth IFX therapy (Week 32).

**Results:** Among 38 patients treated with IFX, 52.6% achieved clinical remission based on the Fistula Drainage Assessment Index and 42.1% achieved deep remission based on Ng score. Van Assche score (from  $14.5 \pm 4.26$  to  $7.36 \pm 7.53$ ), CDAI (from  $170 \pm 92$  to  $71 \pm 69$ ) and PCDAI (from  $7.45 \pm 2.65$  to  $2.44 \pm 3.20$ ) decreased significantly after six IFX treatments. The only predictor of deep remission was simple fistula ( $P = 0.004$ , odds ratio = 3.802, 95% confidence interval: 1.541–9.383).

**Conclusions:** IFX has been shown to have appreciable effectiveness in Chinese patients with PFCD. MRI is the gold standard for evaluating PFCD, but Van Assche score has some limitations.

**Key words:** Crohn's disease; perianal fistula; magnetic resonance imaging; infliximab

Submitted: 4 April 2018; Revised: 11 June 2018; Accepted: 5 July 2018

© The Author(s) 2018. Published by Oxford University Press and Sixth Affiliated Hospital of Sun Yat-Sen University

This is an Open Access article distributed under the terms of the Creative Commons Attribution Non-Commercial License (<http://creativecommons.org/licenses/by-nc/4.0/>), which permits non-commercial re-use, distribution, and reproduction in any medium, provided the original work is properly cited.

For commercial re-use, please contact [journals.permissions@oup.com](mailto:journals.permissions@oup.com)

## Introduction

Perianal fistulizing Crohn's disease (PFCD) has a serious impact on quality of life and mental health [1]. It is always indicative of a more aggressive and refractory disease phenotype [2]. A population-based study found that the incidence of perianal fistula in patients with Crohn's disease (CD) is 21–23% and that the cumulative incidences of the condition at 1, 5, 10 and 20 years are 12, 15, 21 and 26%, respectively [3–5]. Large prospective and retrospective studies have shown that two-thirds of patients with PFCD experience relapses; thus, the treatment of PFCD is challenging [6, 7].

Medical treatments for PFCD include antibiotics, immunosuppressants (ISs) and anti-tumor necrosis factor (TNF) agents, and surgical treatments include seton, fistulotomy, fistulectomy, advancement flap, fecal diversion and proctectomy [8–11]. Nearly 40% of PFCD patients underwent proctectomy before the clinical application of biologic agents [12]. Biologic agents such as infliximab (IFX) have brought new hope to PFCD patients: after continuous treatment for 1 year, one-third of patients maintain clinical remission [13]. Personalized treatments are required based on magnetic resonance imaging (MRI) findings [14]. Pelvic enhancement MRI is the first choice for evaluating PFCD and monitoring the effects of treatment [10]. When used in combination with examination under anesthesia, its specificity and sensitivity are increased [11].

Exploring predictors of the need for different therapies is an important guide for treatment selection for PFCD. Fistula healing based on MRI evaluation is always later than that based on clinical evaluation. Therefore, in the *Second European Evidence-Based Consensus on the Diagnosis and Management of Crohn's Disease* [15], it was proposed that a clinical examination should be combined with MRI as the basis of an effective clinical evaluation. Most previous studies have evaluated treatment efficacy based on clinical evaluation rather than endoscopic or radiologic findings. However, the assessment of treatment efficacy should be based on 'deep remission' (the absence of anal canal ulcers and presence of healing on MRI in association with clinical remission) or the combination of clinical assessment and objective radiologic and endoscopic evaluations. T2-weighted imaging (T2WI) and fat-suppression sequences are the gold standard for the MRI evaluation of fistulas [16]. Imaging-based scoring, although not yet widely used in clinical practice, can reflect disease activity.

In this study, we describe the clinical and radiologic courses of PFCD treated by IFX, evaluate the efficacy of IFX for the condition and explore the predictors of deep remission.

## Patients and methods

### Patients and protocol

Between September 2015 and May 2017, all consecutive patients diagnosed with CD and at least one draining fistula who attended our center for IFX therapy were prospectively enrolled. CD diagnosis was based on a combination of clinical, serologic, endoscopic and pathologic examinations. The diagnosis of anal fistula was based on examination under anesthesia and MRI. IFX therapy consisted of induction therapy (5 mg/kg at Weeks 0, 2 and 6) followed by maintenance therapy (5 mg/kg every 8 weeks). The exclusion criteria included age less than 18 years, pregnancy and unwillingness to undergo IFX therapy or follow-up at our center for more than 6 months.

The data retrieved from medical records included: age; sex; date of diagnosis; smoking history; family history of

inflammatory bowel disease (IBD); disease distribution according to the Montreal classification; treatments (antibiotics, setons, immunomodulators) before IFX therapy; type of fistula; concomitant treatment; adverse events; need for surgical treatment; and early IFX withdrawal because of adverse events or lack of efficacy.

Up to 2 weeks prior to the start of IFX therapy and up to 2 weeks after the sixth IFX therapy (Week 32), each patient underwent clinical assessment of their fistulas according to the Fistula Drainage Assessment Index, MRI to determine Van Assche score, Ng score, main fistula length, endoscopy, assessment of Crohn's Disease Activity Index (CDAI) and Perianal Crohn's Disease Activity Index (PCDAI) and laboratory tests for the following parameters: white blood-cell count; neutrophil count; hemoglobin concentration (HB); hematocrit; platelet count (PLT); C-reactive protein concentration (CRP); erythrocyte sedimentation rate (ESR); and Albumin concentration (ALB). Concurrent therapies for CD, including antibiotics and ISs, were permitted. Seton placement was allowed before IFX therapy. All participants of this study provided written informed consent. The study protocol was approved by the Research Ethics Committee of Renji Hospital (School of Medicine, Shanghai Jiao Tong University, Shanghai, China).

### Evaluation of effectiveness

CDAI was applied to evaluate the disease activity of CD in terms of general well-being, abdominal pain, abdominal mass, diarrhea, the need for diphenoxylate/atropine or opiates for diarrhea, hematocrit, weight and complications [17]. PCDAI was assessed on the basis of five clinical symptoms: discharge; restriction of activities; restriction of sexual activity; type of perianal disease; and degree of induration [18]. Each section was rated from 0–5 according to severity.

Clinical evaluation was performed according to the Fistula Drainage Assessment Index. The definition of 'clinical remission' was the absence of any draining fistulas and any drainage episodes self-reported by the patient in two successive evaluations under gentle finger compression. 'Clinical response' meant reducing the number of draining fistulas by half or more from baseline under gentle finger compression at the clinical evaluation. In all other circumstances, patients were considered 'non-responders' [19]. All clinical examinations were performed by the same senior physician specialized in IBD dedicated to each patient. We no longer assess the Van Assche score of the MRIs of healed fistulas according to Ng score: the Van Assche scores of these MRIs were regarded as zero.

A senior radiologist specialized in gastrointestinal radiology with more than 10 years of experience evaluated the MRIs by calculating the main fistula length and diameter, abscess volume, proctitis, Van Assche score and Ng score. The radiologist used the same standardized report for the initial and follow-up MRIs and was blinded to each patient's medical history and clinical outcome. The Van Assche score included six items, with higher scores indicating severe disease (ranging from 0–22): complexity of the fistula tracts; location relative to the sphincters; extension; hyperintensity on T2WI; presence of abscesses; and rectal wall involvement [20]. We used the predetermined MRI definitions proposed by Ng et al. [21, 22] to classify the radiologic findings (Table 1).

The need for surgery, severe secondary effects requiring discontinuation of medical therapy and voluntary discontinuation of the treatment were considered treatment failures.

**Table 1.** Ng Score for perianal Crohn's disease severity

Terms	Definition
Healed	Absence of high-signal tracks on fat-saturated T2-weighted sequences
Partial response	Reduction in the number of fistula tracts and/or draining cavities and/or a reduction in the volume of inflammation of 10% or more
Unchanged	Similar number of tracts and volume of inflammation
Deterioration	Development of new tracts or collections, or an increase in the size or number of any previous cavities or fistula tracts

### MRI parameters

MRI examinations were performed using a Philips Achieva 3.0-T scanner with a cardiac phased-array coil (Philips Medical Systems, Amsterdam, The Netherlands) and a Philips Ingenia 3-T scanner with a torso phased-array coil (Philips Medical Systems). Patients did not receive any bowel preparation. All patients underwent examination in the supine position. The MRI sequence protocol is presented in [Supplementary Table 1](#). The intravenous injection was a mean dose of 15–20 ml gadolinium-diethylenetriamine penta-acetic acid (Magnevist<sup>®</sup>; Schering AG, Berlin, Germany) and the scan delay was 60 s. The oblique coronal plane was placed parallel to and the oblique transverse plane was placed perpendicular to the long axis of the anal canal. Patients with contraindications to MRI, such as severe claustrophobia, pacemakers or metallic implants, were excluded.

### Statistical analysis

Continuous variables are presented as means and standard deviation, and categorical variables as percentages and 95% confidence intervals (CIs). Comparison of patients was conducted using the  $\chi^2$  test for categorical variables and the Student's *t*-test for continuous variables. The  $\kappa$ -statistic was used to assess the correlation between clinical response and radiologic indices. Predictors of deep remission were assessed using multiple logistic regression analysis. Models of logistic regression were performed. The results were considered statistically significant at a *P*-value of <0.05. We used SPSS 18.0 (SPSS Inc., Chicago, IL, USA) for all statistical analyses.

## Results

### Patient characteristics

A total of 38 patients (26.3% women) with a mean age of  $28.5 \pm 8.2$  years scheduled for IFX therapy were prospectively enrolled. Of them, 68.4% had complex fistulas and 5.3% had anorecto-vaginal fistulas. Among them, 8 patients were receiving a combination of IFX and azathioprine (AZA), whereas 30 patients were receiving IFX alone. The baseline characteristics of this study population are presented in [Table 2](#).

### Clinical and radiologic responses

Four patients discontinued because of adverse effects or subjective reluctance, whereas 20 (52.6%) were in clinical remission, 9 (23.7%) exhibited a clinical response and 5 (13.2%) were non-responders after six IFX therapies. CDAI and PDAI decreased

**Table 2.** Baseline characteristics of 38 patients with perianal fistulizing Crohn's disease

Variables	IFX patients (n = 38)
Sex	
Male	28 (73.7%)
Female	10 (26.3%)
Age, years	$28.5 \pm 8.2$
Smokers	2 (5.3%)
IBD family history	0 (0%)
CD disease location	13 (34.2%)
L1 (Ileal)	3 (7.9%)
L2 (Colonic)	22 (57.9%)
L3 (Ileocolonic)	
Duration, years	$1.95 \pm 3.01$
Fistula location	
Superficial	1 (2.6%)
Intersphincteric	19 (50%)
Transsphincteric	14 (36.8%)
Suprasphincteric	2 (5.3%)
Extrasphincteric	2 (5.3%)
Fistula type	
Simple fistula	12 (31.6%)
Complex fistula	26 (68.4%)
Anorecto-vaginal fistula	2 (5.3%)
Proctitis	20 (52.6%)
Abscess	20 (52.6%)
Previous surgery	
Drainage techniques	10 (26.3%)
Seton or fistulotomy	9 (23.7%)
Fistulectomy	5 (13.2%)
Segmental bowel resection	2 (5.3%)
Treatment	
Infliximab	30 (78.9%)
Infliximab + azathioprine	8 (21.1%)
Time between initial and follow-up MRI	6 infliximab therapy

IFX, infliximab; IBD, inflammatory bowel disease; CD, Crohn's disease; MRI, magnetic resonance imaging.

significantly from  $170 \pm 92$  and  $7.45 \pm 2.65$  at baseline to  $71 \pm 69$  and  $2.44 \pm 3.2$  after six IFX therapies, respectively (both  $P < 0.05$ ). According to Ng score, 16 (42.1%) of the patients achieved deep remission, 11 (28.9%) exhibited a partial response, 4 (10.5%) remained unchanged and 3 (7.9%) deteriorated ([Table 3](#)). The healing rates of patients receiving IFX therapy alone and those receiving AZA + IFX were 40% (12/30) and 50% (4/8), respectively. Van Assche score decreased significantly from  $14.50 \pm 4.26$  at baseline to  $7.36 \pm 7.53$  after six IFX therapies ([Figure 1](#)). The changes in patient ratios for the six components of the Van Assche score are shown in detail in [Figure 2](#).

The changes in serologic findings are shown in [Supplementary Table 2](#). ESR (from  $18.6 \pm 19.4$  to  $11 \pm 12.3$  mm/h,  $P < 0.05$ ), CRP (from  $9.59 \pm 11.3$  to  $4.24 \pm 8.09$  mg/L,  $P < 0.05$ ) and PLT (from  $[286 \pm 88] \times 10^9$  to  $[260 \pm 91] \times 10^9$ ,  $P < 0.05$ ) decreased significantly between baseline and after six IFX therapies, whereas ALB (from  $39.8 \pm 6.2$  to  $43.7 \pm 5.16$  g/L,  $P < 0.05$ ) and HB (from  $125 \pm 21.8$  to  $134 \pm 23$  g/L,  $P < 0.05$ ) increased significantly.

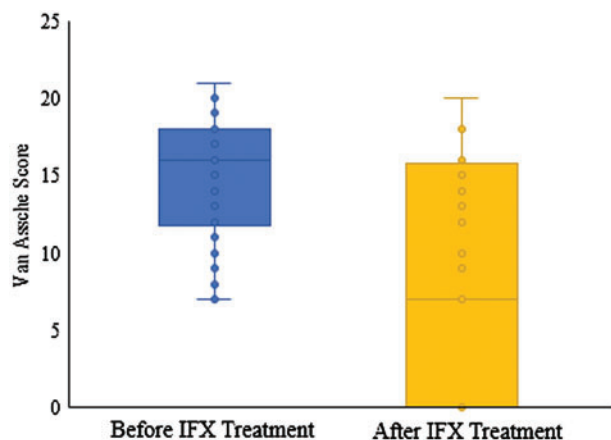
### Correlation between clinical and radiologic responses

Clinical examination according to the Fistula Drainage Assessment Index and MRIs were performed in each patient. Sixteen of the 20 patients (80%) who were in clinical remission exhibited healed fistula tracts on MRI and six of the nine

**Table 3.** Clinical and radiologic evaluation of infliximab (IFX) efficacy

Outcomes	IFX patients (n = 38)
Discontinued	4 (10.5%)
Clinical evaluation	
Fistula Drainage Assessment Index	
Clinical remission	20 (52.6%)
Clinical response	9 (23.7%)
Non-response	5 (13.2%)
Crohn's Disease Activity Index	
Baseline	170 ± 92
Follow-up	71 ± 69*
Perianal Crohn's Disease Activity Index	
Baseline	7.45 ± 2.65
Follow-up	2.44 ± 3.20*
Radiologic evaluation	
Ng score	
Healed	16 (42.1%)
Partial response	11 (28.9%)
Unchanged	4 (10.5%)
Deterioration	3 (7.9%)
Healing rate of complex fistulas	8/26 (30.8%)
Van Assche score	
Baseline	14.5 ± 4.26
Follow-up	7.36 ± 7.53*
Maximum fistula length, mm	
Baseline	41.4 ± 20.7
Follow-up	17.2 ± 23.1*
Maximum fistula diameter, mm	
Baseline	3.39 ± 1.81
Follow-up	1.18 ± 1.58*

\*P &lt; 0.05.

**Figure 1.** Van Assche scores were significantly reduced after six infliximab (IFX) treatments, from  $14.5 \pm 4.26$  to  $7.36 \pm 7.53$ 

patients (66.7%) who exhibited a clinical response demonstrated a partial response on MRI ( $\kappa$ -statistic = 0.613,  $P < 0.001$ ).

### Predictors of deep remission

In a univariate analysis, deep remission was significantly associated with low initial Van Assche score ( $12.6 \pm 4.3$  vs  $15.9 \pm 3.7$ ,  $P = 0.015$ ), absence of proctitis ( $P = 0.047$ ) and simple fistula ( $P = 0.002$ ), but showed no relationship with sex, age, duration of disease, smoking history, surgery history, absence of abscesses, combinatorial treatment with AZA, CD disease location, main

fistula length on initial MRI, main fistula diameter on initial MRI, the five components of Van Assche score except fistula type, initial CDAI, initial PCDAI or initial laboratory findings (all  $P > 0.05$ ). In a multivariate analysis, deep remission was only significantly associated with simple fistula (odds ratio 3.802, 95% CI: 1.541–9.383,  $P = 0.004$ ).

### Safety of IFX therapy

Four patients were considered to have experienced treatment failure. One patient discontinued because of pre-excitation syndrome after the first IFX therapy, one because of hepatapostema at the fourth IFX therapy, one because of pulmonary infection at the fifth IFX therapy and one postponed the sixth IFX therapy because of upper respiratory tract infection then discontinued for being reluctant to follow IFX therapy. In addition, two patients presented minor adverse effects (dermatitis) that did not require cessation of the therapy.

### Discussion

Anti-TNF therapies have revolutionized the management of PFCD. Several randomized controlled trials have proven their efficacy at achieving and maintaining remission of PFCD [23, 24]. However, few studies have focused on deep remission as the therapeutic outcome of interest and, to the best of our knowledge, there are no studies involving Asian populations. In this study, we prospectively examined the clinical and radiologic evaluation of IFX therapy for PFCD: 52.6% of our patients receiving IFX therapy achieved clinical remission, whereas 42.1% exhibited deep remission.

Regarding the basic characteristics of the 38 participants of this study, the male:female ratio was 28:10, which is consistent with the epidemiology of PFCD in China, but different from that in Europe and the USA [25]. The proportion of smokers was only 5.3%, which is much lower than that in Western countries. The family history of IBD was 0%, which may be due to the low incidence and low detection rate of the condition in China 10 years ago. Other basic patient information was similar to that in research in China and abroad.

Published studies on the efficacy of IFX therapy for PFCD as evaluated by MRI are summarized in Table 4 [13, 25–28]. The clinical and deep remission rates observed in this study were higher than those presented in Table 4. The reasons are as follows.

First, not all patients in earlier studies were naïve to anti-TNF agents. Several patients had refractory PFCD that had already failed to respond to other anti-TNF agents. Despite the similar efficacy of each anti-TNF agent, the use of a second anti-TNF agent is often not as effective as that of the initial anti-TNF agent, but it is still effective in some patients [26]. Currently, of the anti-TNF drugs available for the treatment of CD, only IFX is approved in China. All patients in this study were naïve to IFX. A retrospective study of patients naïve to adalimumab therapy showed that 39% of patients achieved radiologic remission after 6 months [22]—a higher proportion than those of the five studies listed in Table 4 in which patients were not naïve to IFX.

Second, the patients studied in the papers listed in Table 4 were Europeans and Americans, whereas the patients enrolled in this study were Han Chinese. It has been shown that the expression of five genes (*S100A8*, *S100A9*, *GOS2*, *TNFAIP6* and *IL11*) has an etiologic role in the IFX response pathway and predicts the response to IFX of patients with CD [29]. However, the



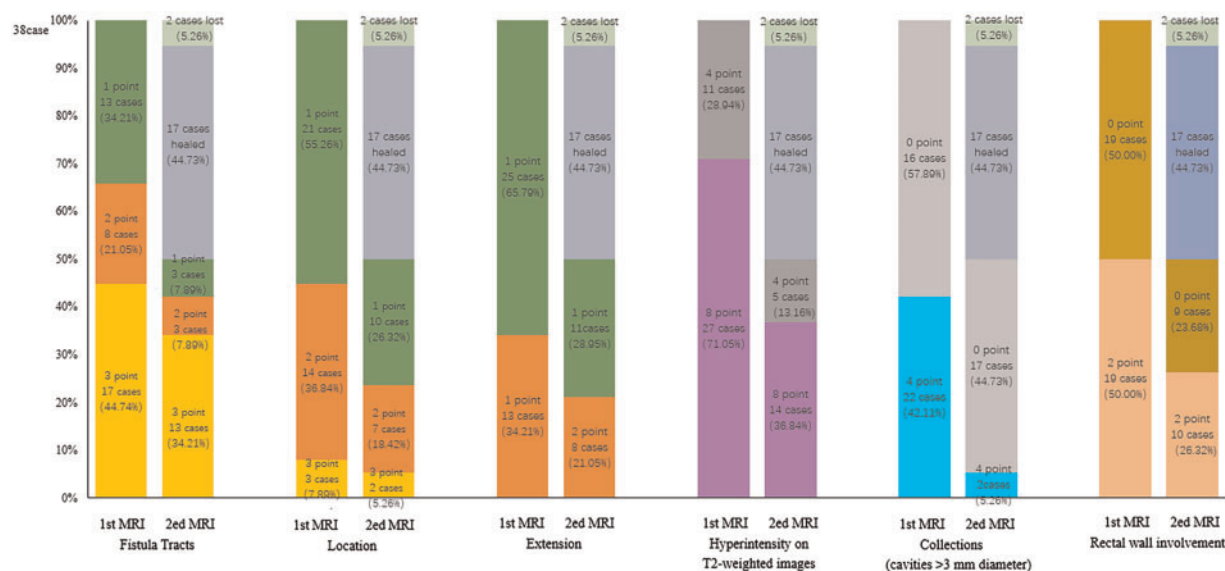


Figure 2. Patient ratios of the six components (complexity of fistula tracks, location relative to the sphincters, extension, hyperintensity on T2-weighted imaging, presence of abscesses and rectal wall involvement) of the Van Assche score on initial and follow-up magnetic resonance imaging

Table 4. Previous studies on the radiologic evaluation of infliximab efficacy

Reference	Publication year and type	Treatment	No. of patients	Complex fistulas	Duration, year	Follow-up, months	Outcome	Risk factors
Thomassin [27]	2017, retrospective	IFX/ADA and IS	49	–	6	40	Deep remission: 33%	Rectal involvement
Tozer [13]	2012, retrospective	IFX and TP	32	83%	10	6	Radiologic healing: 25%	Number of fistulas
Ng [28]	2009, prospective	IFX/ADA or with AZA	26	–	12	6	Deep remission: 20%	Proctitis
Tougeron [29]	2008, retrospective	IFX or with IS	26	69%*	13	59	Clinical remission: 42%	Proctitis
Karmiris [30]	2011, retrospective	IFX or with IS	29	85%	9	9	Reduction of fistula number: 14%	None

\*Anorecto-vaginal fistula: 30%. IFX, infliximab; ADA, adalimumab; TP, thiopurine; IS, immunosuppressants; AZA, azathioprine.

susceptibility genes of CD differ between Chinese and Western patients. It can be inferred from the results of this study that the efficacy of IFX for PFCD is better in Chinese patients than in Western patients.

Third, studies have shown that the shorter the disease duration, the higher the response rate to biologic agents [30, 31]. A retrospective study with a small sample size showed that patients with PFCD with disease durations (before the beginning of anti-TNF treatment) of less than 3, 3–6 and >6 years achieved radiographic healing rates of 50, 38 and 14%, respectively [26]. The average disease duration in this study was  $1.95 \pm 3.01$  years—well below those of the five studies presented in Table 4.

Fourth, in this study, 68.4% of the patients had complex fistulas and 5.3% had anorecto-vaginal fistulas—well below the proportions of patients with these conditions in the studies listed in Table 4. In combination with the fact that several patients had already failed to respond to other anti-TNF agents, the PFCD described in those papers presented in Table 4 was more refractory than that described in this study. Furthermore, the number of fistulas was a risk factor for no response to IFX therapy in patients with PFCD [13].

IFX is safe and efficient for the treatment of PFCD. However, treatment options for PFCD are limited and biologics are expensive. Consequently, it is important to explore the predictors of

treatment response. In the first study listed in Table 4, 33% of patients achieved deep remission 2 years after receiving anti-TNF agents and the absence of rectal involvement on MRI was the only predictor of deep remission [25]. Other studies in Table 4 showed that a large number of fistulas [13] and proctitis [26, 27] are risk factors for no response to IFX. Another study showed that proctitis is a predictor of poor response and even proctectomy [32]. In addition, a single-center study showed that a history of perianal abscesses and antibiotic treatment in the course of anti-TNF therapy were predictors of poor response in PFCD [33]. Moreover, individuals with a younger age at onset, male sex, rectal lesions and non-white or Jewish ethnicities were at high risk of developing perianal lesions [8, 34]. However, our study indicated that the only predictor of deep remission was simple anal fistula.

One study showed that an aggregate length of  $\geq 2.5$  cm predicted disease progression, whereas a maximum single fistula length of  $< 2.5$  cm on MRI predicted treatment response; thus, the authors recommended that the measurement of fistula length should be incorporated into routine clinical practice [35]. We measured both the length and diameter of the main fistula using MRI. Unfortunately, neither the length nor the diameter of the main fistula was a risk factor in univariate or multivariate analyses.

In the current study, only 21.1% of the patients were treated with a combination of IFX and AZA in this study (lower than the

proportions in the studies listed in Table 4): the rest were treated with IFX alone. A study demonstrated that AZA maximizes the long-term effects of antibiotics [36]. Similarly, studies on IFX in combination with thiopurines have shown that thiopurines increase the extent and duration of the response to IFX [37, 38]. The *European Evidence-Based Consensus on the Diagnosis and Management of Crohn's Disease 2016* stated that combination of anti-TNF treatment with thiopurines may enhance the effects of anti-TNF agents on complex fistulizing disease [39]. However, some studies asserted that IFX alone achieves better outcomes than in combination with AZA. It was inferred from the subgroups of the ACCENT I and II trials that the use of IFX in combination with ISs does not increase its efficacy or pharmacokinetics [40]. In addition, a randomized controlled study showed that the mucosal healing of the combination of IFX and ISs was not statistically superior to IFX alone after continuous treatment for 6 months [41]. Another retrospective study showed that the improvement rates in MRI findings of IFX alone and IFX in combination with ISs at 12 months were 53 and 67%, respectively [26]. Therefore, whether the combination of IFX and AZA is superior to IFX alone is inconclusive. However, in current clinical practice in China, monotherapy is preferable. First, Chinese patients have better response to biologic agents. Second, Chinese patients have more side effects when receiving combination of IFX and AZA.

Currently, Van Assche score is widely used in clinical research [20]. However, our findings suggest that this score has some limitations related to its inability to reflect new fistulas and abscesses in some circumstances [42]. For example, when a third fistula emerges when two initial fistulas are unchanged, Van Assche score remains unchanged because of the invariability of the complexity of the fistula tracks. In this case, Van Assche score no longer reflects the deterioration of the disease, and vice versa when one of the three initial fistulas heals. Also, when the original abscess lesion turns into granulation tissue, Van Assche score does not show any improvement. In order to better reflect the changes evident on imaging, a more standard, effective and uniform grading standard needs to be developed. Hence, in this study, we used Ng score to compare the changes between the initial and follow-up MRIs in each patient, which is more objective and suitable for monitoring the therapeutic effect.

In this study, the consistency of the clinical and radiologic evaluations was high. Fistula closure is often later on MRI than on clinical evaluation. When the fistula has not yet fully undergone fibrosis and closure of the external orifice, there is a risk of recurrence. Therefore, pelvic enhancement MRI is essential for the assessment of PFCF.

Our study has several limitations. We did not measure anti-IFX antibody concentration or serum trough level. The IFX dose was 5 mg/kg all the time in all patients. Patients with a poor response should receive an increased dose of IFX or switch to another biologic agent according to anti-IFX antibody concentration and serum trough level, which is not yet renewed in the guideline of China. Furthermore, higher IFX serum trough level (>9–10 µg/mL) is favorable for fistula healing [43, 44]. Nonetheless, IFX is the only anti-TNF drug approved for the treatment of CD in China. However, the association between IFX levels and outcomes is beyond the studying scope of this study.

In conclusion, IFX is safe and effective for PFCF with a high deep remission rate. The only predictor of deep remission is simple fistula. MRI is the gold standard for evaluating PFCF, but Van Assche score has some limitations.

## Funding

This work was supported by the National Natural Science Foundation of China (No. 81302092, 81302095 and 81600435), the Fundamental Research Funds for the Central Universities (No. YG2015QN38) and the Foundation for Fostering Clinical Research of Renji Hospital (No. PYMDT-005).

## Acknowledgements

All procedures performed in studies involving human participants were in accordance with the ethical standards of the Research Ethics Committee of Renji Hospital (School of Medicine, Shanghai Jiao Tong University, Shanghai, China) and with the 1964 Helsinki declaration and its later amendments or comparable ethical standards. Informed consent was obtained from all individual participants included in the study.

## Supplementary Data

Supplementary data is available at *Gastroenterology Report* online.

Conflict of interest statement: none declared.

## References

1. Maconi G, Gridavilla D, Viganò C. Perianal disease is associated with psychiatric co-morbidity in Crohn's disease in remission. *Int J Colorectal Dis* 2014;29:1285–90.
2. Beaugerie L, Seksik P, Nion-Larmurier I et al. Predictors of Crohn's disease. *Gastroenterology* 2006;130:650–6.
3. Hellers G, Bergstrand O, Ewerth S et al. Occurrence and outcome after primary treatment of anal fistulae in Crohn's disease. *Gut* 1980;21:525–7.
4. Schwartz DA, Loftus EV, Tremaine WJ et al. Response to infliximab in Crohn's disease: genetic analysis supporting expression profile the natural history of fistulizing Crohn's disease in Olmsted County, Minnesota. *Gastroenterology* 2002; 122:875–80.
5. Tang LY, Rawsthorne P, Bernstein CN. Are perineal and luminal fistulas associated in Crohn's disease? A population-based study. *Clin Gastroenterol Hepatol* 2006;4:1130–4.
6. Makowiec F, Jehle EC, Starlinger M. Clinical course of perianal fistulas in Crohn's disease. *Gut* 1995;37:696–701.
7. Molendijk I, Nuij VJ, van der Meulen-de Jong AE et al. Disappointing durable remission rates in complex Crohn's disease fistula. *Inflamm Bowel Dis* 2014;20:2022–8.
8. Marzo M, Felice C, Pugliese D et al. Management of perianal fistulas in Crohn's disease: an up-to-date review. *World J Gastroenterol* 2015;21:1394–403.
9. Juncadella AC, Alame AM, Sands LR et al. Perianal Crohn's disease: a review. *Postgrad Med* 2015;127:266–72.
10. Ran Z. *Diagnosis and Treatment Strategy of Inflammatory Bowel Disease*. Shanghai: Chinese Science Press, 2015.
11. Lightner AL, Shen B. Perioperative use of immunosuppressive medication in patients with Crohn's disease in the new 'biological era'. *Gastroenterol Rep (Oxf)* 2017;5:165–77.
12. Ingle SB, Loftus EV Jr. The natural history of perianal Crohn's disease. *Dig Liver Dis* 2007;39:963–9.
13. Tozer P, Ng SC, Siddiqui MR et al. Long-term MRI-guided combined anti-TNF-alpha and thiopurine therapy for Crohn's perianal fistulas. *Inflamm Bowel Dis* 2012;18:1825–34.

14. Gecse KB, Bemelman W, Kamm MA et al. A global consensus on the classification, diagnosis and multidisciplinary treatment of perianal fistulising Crohn's disease. *Gut* 2014;**63**:1381–92.
15. Van Assche G, Dignass A, Reinisch W et al. The second European evidence-based Consensus on the diagnosis and management of Crohn's disease: definitions and diagnosis. *J Crohns Colitis* 2010;**4**:63–101.
16. Gecse KB, Sebastian S, Hertogh G et al. Results of the fifth scientific workshop of the ECCO [II]: clinical aspects of perianal fistulising Crohn's disease-the unmet needs. *J Crohns Colitis* 2016;**10**:758–65.
17. Best WR, Beckett JM, Singleton JW et al. Development of a Crohn's disease activity index. National Cooperative Crohn's Disease Study. *Gastroenterology* 1976;**70**:439–44.
18. Irvine EJ. Usual therapy improves perianal Crohn's disease as measured by a new disease activity index: McMaster IBD Study Group. *J Clin Gastroenterol* 1995;**20**:27–32.
19. Present DH, Rutgeerts P, Targan S et al. Infliximab for the treatment of fistulas in patients with Crohn's disease. *N Engl J Med* 1999;**340**:1398–405.
20. Van Assche G, Vanbeckevoort D, Bielen D et al. Magnetic resonance imaging of the effects of infliximab on perianal fistulizing Crohn's disease. *Am J Gastroenterol* 2003;**98**:332–9.
21. Ng SC, Plamondon S, Gupta A et al. Prospective assessment of the effect on quality of life of anti-tumour necrosis factor therapy for perineal Crohn's fistulas. *Aliment Pharmacol Ther* 2009;**30**:757–66.
22. Castaño-Milla C, Chaparro M, Saro C et al. Effectiveness of adalimumab in perianal fistulas in crohn's disease patients naive to anti-TNF therapy. *J Clin Gastroenterol* 2015;**49**:34–40.
23. Hanauer SB, Feagan BG, Lichtenstein GR, ACCENT I Study Group et al. Maintenance infliximab for Crohn's disease: the ACCENT I randomised trial. *Lancet* 2002;**359**:1541–9.
24. Sands BE, Anderson FH, Bernstein CN et al. Infliximab maintenance therapy for fistulizing Crohn's disease. *N Engl J Med* 2004;**350**:876–85.
25. Thomassin L, Armengol-Debeir L, Charpentier C et al. Magnetic resonance imaging may predict deep remission in patients with perianal fistulizing Crohn's disease. *World J Gastroenterol* 2017;**23**:4285–92.
26. Ng SC, Plamondon S, Gupta A et al. Prospective evaluation of anti-tumor necrosis factor therapy guided by magnetic resonance imaging for Crohn's perineal fistulas. *Am J Gastroenterol* 2009;**104**:2973–86.
27. Tougeron D, Savoye G, Savoye-Collet C et al. Predicting factors of fistula healing and clinical remission after infliximab-based combined therapy for perianal fistulizing Crohn's disease. *Dig Dis Sci* 2009;**54**:1746–52.
28. Karmiris K, Bielen D, Vanbeckevoort D et al. Long-term monitoring of infliximab therapy for perianal fistulizing Crohn's disease by using magnetic resonance imaging. *Clin Gastroenterol Hepatol* 2011;**9**:130–6.
29. Medrano LM, Taxonera C, González-Artacho C et al. Response to Infliximab in Crohn's disease: genetic analysis supporting expression profile. *Mediators Inflamm* 2015;**2015**:318207.
30. Kugathasan S, Werlin SL, Martinez A et al. Prolonged duration of response to infliximab in early but not late pediatric Crohn's disease. *Am J Gastroenterol* 2000;**95**:3189–94.
31. Lionetti P, Bronzini F, Salvestrini C et al. Response to infliximab is related to disease duration in paediatric Crohn's disease. *Aliment Pharmacol Ther* 2003;**18**:425–31.
32. Panes J, Jairath V, Levesque BG. Advances in use of endoscopy, radiology, and biomarkers to monitor inflammatory bowel diseases. *Gastroenterology* 2017;**152**:362–73e363.
33. Rayen J, Currie T, Geary RB et al. The long-term outcome of anti-TNF alpha therapy in perianal Crohn's disease. *Tech Coloproctol* 2017;**21**:119–24.
34. Tozer PJ, Burling D, Gupta A et al. Review article: medical, surgical and radiological management of perianal Crohn's fistulas. *Aliment Pharmacol Ther* 2011;**33**:5–22.
35. Shenoy-Bhangle A, Nimkin K, Goldner D et al. MRI predictors of treatment response for perianal fistulizing Crohn disease in children and young adults. *Pediatr Radiol* 2014;**44**:23–9.
36. Dejaco C, Harrer M, Waldhoer T et al. Antibiotics and azathioprine for the treatment of perianal fistulas in Crohn's disease. *Aliment Pharmacol Ther* 2003;**18**:1113–20.
37. Viscido A, Habib FI, Kohn A et al. Infliximab in refractory pouchitis complicated by fistulae following ileo-anal pouch for ulcerative colitis. *Aliment Pharmacol Ther* 2003;**17**:1263–71.
38. Topstad DR, Panaccione R, Heine JA et al. Combined seton placement, infliximab infusion, and maintenance immunosuppressives improve healing rate in fistulizing anorectal Crohn's disease: a single center experience. *Dis Colon Rectum* 2003;**46**:577–83.
39. Gionchetti P, Dignass A, Danese S et al. 3rd European evidence-based consensus on the diagnosis and management of Crohn's disease 2016: Part 2: Surgical management and special situations. *J Crohns Colitis* 2017;**11**:135–49.
40. Lichtenstein GR, Diamond RH, Wagner CL et al. Clinical trial: benefits and risks of immunomodulators and maintenance infliximab for IBD-subgroup analyses across four randomized trials. *Aliment Pharmacol Ther* 2009;**30**:210–26.
41. Van Assche G, Magdelaine-Beuzelin C, D'Haens G et al. Withdrawal of immunosuppression in Crohn's disease treated with scheduled infliximab maintenance: a randomized trial. *Gastroenterology* 2008;**134**:1861–8.
42. Korelitz BI, Adler DJ, Mendelsohn RA et al. Long-term experience with 6-mercaptopurine in the treatment of Crohn's disease. *Am J Gastroenterol* 1993;**88**:1198–205.
43. Davidov Y, Ungar B, Bar-Yoseph H et al. Association of induction infliximab levels with clinical response in perianal Crohn's disease. *J Crohns Colitis* 2017;**11**:549–55.
44. Yarur AJ, Kanagala V, Stein DJ et al. Higher infliximab trough levels are associated with perianal fistula healing in patients with Crohn's disease. *Aliment Pharmacol Ther* 2017;**45**:933–40.