



Since January 2020 Elsevier has created a COVID-19 resource centre with free information in English and Mandarin on the novel coronavirus COVID-19. The COVID-19 resource centre is hosted on Elsevier Connect, the company's public news and information website.

Elsevier hereby grants permission to make all its COVID-19-related research that is available on the COVID-19 resource centre - including this research content - immediately available in PubMed Central and other publicly funded repositories, such as the WHO COVID database with rights for unrestricted research re-use and analyses in any form or by any means with acknowledgement of the original source. These permissions are granted for free by Elsevier for as long as the COVID-19 resource centre remains active.

ORIGINAL PAPERS

VIRAL INTESTINAL INFECTIONS OF ANIMALS AND MAN

A. K. EUGSTER and L. SNEED

Texas Veterinary Medical Diagnostic Laboratory, P.O. Drawer 3040,
College Station, TX 77840, U.S.A.

Abstract—The extensive use of negative staining techniques and electron microscopy in diagnostic centers has resulted in a dramatic increase in the number of reported viral enteric infections in man and animals in the last 10 yr. Enteric infection due to adenoviruses, astroviruses, coronaviruses, paramyxoviruses, parvoviruses, picornaviruses (caliciviruses), rotaviruses as well as some unidentified viral particles are described. The brief literature review on each of these virus families is supplemented with clinical cases submitted to the Texas Veterinary Medical Diagnostic Laboratory. Comparative aspects of viral infections between different animal species as well as man are discussed wherever possible.

Key words: Enteric viruses, adenovirus, coronavirus, paramyxovirus, parvovirus, picornavirus, astrovirus, rotavirus

INFECTIONS VIRALES DE L'INTESTIN CHEZ LES ANIMAUX ET CHEZ L'HOMME

Résumé—L'utilisation considérable des techniques de coloration négative et de microscopie électronique dans les centres de diagnostic a abouti à une dramatique augmentation du nombre des infections virales de l'intestin décelées chez l'homme et chez les animaux au cours de ces 10 dernières années. Nous avons décrit les infections des intestins provoquées par les adénovirus, astrovirus, coronavirus, paramyxovirus, parvovirus, picornavirus (calicivirus), rotavirus ainsi que quelques particules virales non identifiées. La brève littérature écrite sur chacune de ces familles de virus est complétée par des cas cliniques soumis au Laboratoire des Diagnostics Vétérinaires du Texas. Les aspects des infections virales qui pouvaient être comparés dans les différentes espèces animales ainsi que chez l'homme ont été discutés lorsque cela était possible.

Mots-clés: Virus de l'intestin, adénovirus, coronavirus, paramyxovirus, parvovirus, picornavirus, astrovirus, rotavirus.

INTRODUCTION

Diarrheal diseases are a leading cause of morbidity and mortality, especially in the young of many species including man. Bacterial pathogens such as enteropathogenic *E. coli* and *Salmonella* sp. play an important role as a cause of primary and secondary enteric infections. However, in the last decade since Mebus discovered rotaviruses as a cause of diarrhea in neonatal calves, numerous previously unrecognized viruses have been found in diarrheic feces of a variety of animals and man. Part of the reason for this upsurge was the fact that virologists started using the electron microscope as a diagnostic tool, looking for viruses directly in negatively stained fecal preparations as an adjunct to the routine procedure of inoculating tissue cultures. Many of the viruses such as corona-, rota-, parvo- and adenoviruses are difficult to isolate from clinical specimens and propagate in cell cultures with present techniques. The presence of mixed enteric viral infections, which are not as uncommon as the literature might suggest, would remain undetected in most cases without the employment of the electron microscope.

It is the intent of this treatise to impress upon the reader the host of different viruses present in the intestinal tract and the similarity of different viral infections in various animals and man. Members of some of these viral families are recognized pathogens, while others are still more or less in search of a disease.

Members of all virus families described herein have been observed in clinical specimens submitted to the Texas Veterinary Medical Diagnostic Laboratory (TVMDL) by practicing veterinarians in Texas. The literature is briefly reviewed in the case of recognized intestinal viral infections while clinical cases wherein viruses were found which have not yet been reported in the literature are described in more detail.

MATERIALS AND METHODS

Feces or tissue homogenates were prepared as 20–30% suspensions in distilled water. After a clarifying centrifugation at $800 \times g$ for 30 min the resultant supernatant was centrifuged at $55,000 \times g$ for 1 hr in a swinging bucket. The pellet was resuspended in distilled water to 1/10 of the original volume. Fifty to 100 μ l of this suspension was then placed in a spot plate and 1 ml of distilled water, 200 μ l of a 4% phosphotungstic acid and 50 μ l of a 1% bovine albumin solution added. After thorough mixing with the aid of a Pasteur pipette this suspension was then placed in an all-glass nebulizer and sprayed onto collodium-carbon-coated 400-mesh copper grids under a hood. All specimens were immediately examined in a Philips 301 transmission electron microscope.

RESULTS AND DISCUSSION

Adenoviruses

The organ system primarily affected by adenovirus infections in various species is the respiratory tract. However, the intestinal tract is also a frequent site of clinical or subclinical adenovirus infection.

Several adenovirus types have been shown to cause respiratory infections and conjunctivitis, while other types cause latent infections in adenoids and tonsils in man [1–3]. Human adenoviruses also have been isolated from feces, intestinal tracts and urine of man [4]. While the intestinal tract plays a role in the pathogenesis and epidemiology of adenovirus infection, it is the respiratory tract that is clinically-affected in man. In nonhuman primates adenoviruses cause both respiratory and enteric infections [5].

Adenovirus infections in pigs are usually clinically inapparent. Occasionally adenoviruses have been isolated from pigs with signs of anorexia, enteritis, pneumonia and convulsions. These signs also have been reproduced in experimentally-inoculated specific pathogen-free pigs [6]. *In utero* inoculation of swine with adenoviruses resulted in abortion [7].

The usefulness of the electron microscope in detecting viruses that would be missed by routine tissue culture methods is evident from a submission to TVMDL involving 4 piglets. In a large farrowing house, piglets were born normally and were healthy for the first week of life. At 1–2 weeks of age the piglets stopped nursing and rapidly became unthrifty with some vomiting. Morbidity was high (approx. 80%) while the mortality was low (approx. 10%). Older pigs and sows did not show any clinical signs except for excessive

nasal discharge. The 4 piglets submitted were leukopenic (2000–6000 white blood cells/ml) and rectal temperatures averaged 41°C. Encapsulated *E. coli* and the following viruses were found in the intestines of the 4 piglets: adenovirus, parvovirus (possibly adeno-associated virus), picornavirus and rotavirus. The microscopic lesions pointed to an involvement of any or all of these viruses in the pathogenesis of this syndrome. Lymphocytic cuffs were noted around small veins in the hippocampus of one piglet and in the muscularis of the stomach of all 4 piglets. Also, some ganglia in the gastric wall of all 4 animals were infiltrated with lymphocytes. All of these viruses would have been missed had routine tissue culture isolation procedures been used because some of the viruses (picornavirus, adenovirus and parvovirus) were found to be coated with antibodies and rotaviruses simply do not replicate well in tissue cultures.

The main adenovirus type described in dogs is canine hepatitis virus that causes fever and gastrointestinal disturbances in puppies and adults and subclinical infections in adult dogs [8]. Concurrent infections of adenoviruses and other viral agents have been observed at TVMDL. A case in point was a 3-month-old puppy that harbored paramyxoviruses (identified as canine distemper virus by FA test) and adenoviruses in the lungs and intestines. The intestines also contained parvoviruses (possibly adeno-associated viruses).

Adenoviruses have recently also been isolated from foals with pneumonia [9].

The first bovine adenoviruses were isolated from feces of normal calves [10]. Subsequently, adenoviruses were isolated from calves with diarrhea [11]. Experimental inoculation of calves can induce mild respiratory as well as intestinal signs [11, 12].

Enteric adenovirus infections of unusual severity have been reported. Fatal gastroenteritis in a 16-month-old boy was associated with an adenovirus infection [13]. The acuteness of the illness in the boy and the symptoms described had some similarities to a bovine case submitted to TVMDL. One 9-month-old calf in a feedlot pen of 35 died after a 12-hr illness consisting of a severe bloody diarrhea. Hemorrhagic enteritis with some necrosis of the epithelium was noted in the large and small intestine. The Peyer's patches were depleted of lymphocytes. Numerous adenovirus particles were present in all parts of the intestinal tract (Fig. 1). Hemolytic *E. coli* was also isolated. All tests for other infectious or toxic agents including *Clostridium perfringens*, coccidia, salmonella, anthrax and arsenic were negative. Reed and co-workers described similar signs in a 6-day-old calf from which an adenovirus, identified as type 7, was isolated [14].

There are few reports on adenovirus infections in sheep. McFerran and co-workers first isolated adenoviruses from normal as well as diarrheic sheep feces [15]. Subsequently, adenoviruses also were isolated from lambs with respiratory illness [16]. Respiratory as well as enteric signs were induced in experimentally inoculated colostrum-deprived lambs [16, 17]. The first adenoviruses in lambs in the U.S.A. were encountered in the following field case submitted to TVMDL: one thousand and fifty 6–8-month-old lambs were purchased through a sale and vaccinated against *Clostridium perfringens* type D at that time. One week later a few lambs were anorectic and had a watery diarrhea. They were found dead 2–5 days later. Ultimately 90 lambs became ill and all affected lambs died despite specific antibiotic treatments against *Salmonella* sp. which was isolated from the intestine. Adenoviruses as well as parvoviruses (possibly adeno-associated viruses) were demonstrated in the intestinal contents (Fig. 2). It is interesting that all affected lambs apparently originated from the same farm. Since latency in adenovirus infections is not

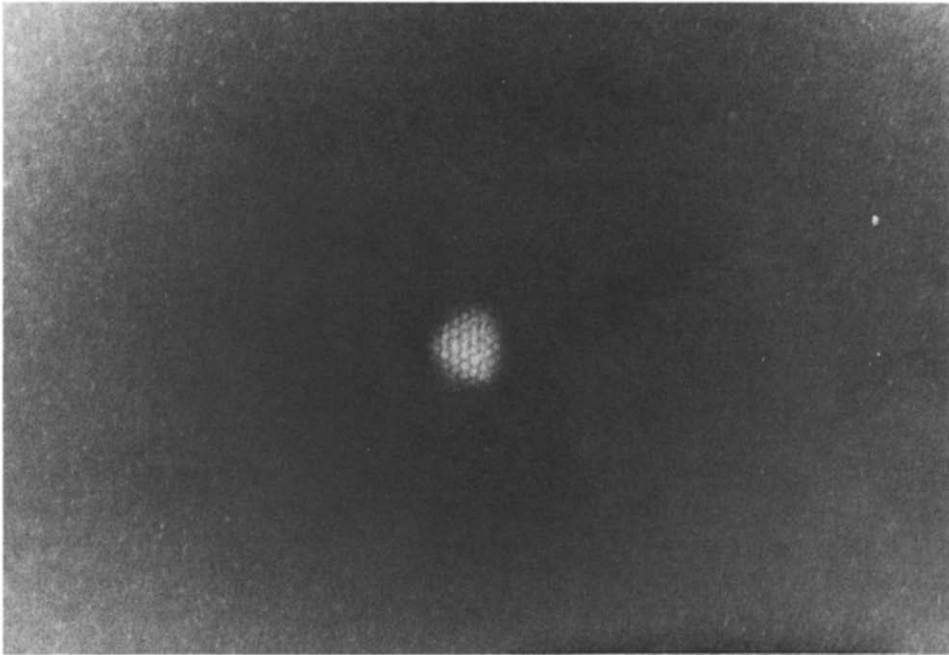


Fig. 1. Bovine adenoviruses, 80 nm in diameter. Subunits in 'star of David' arrangement.

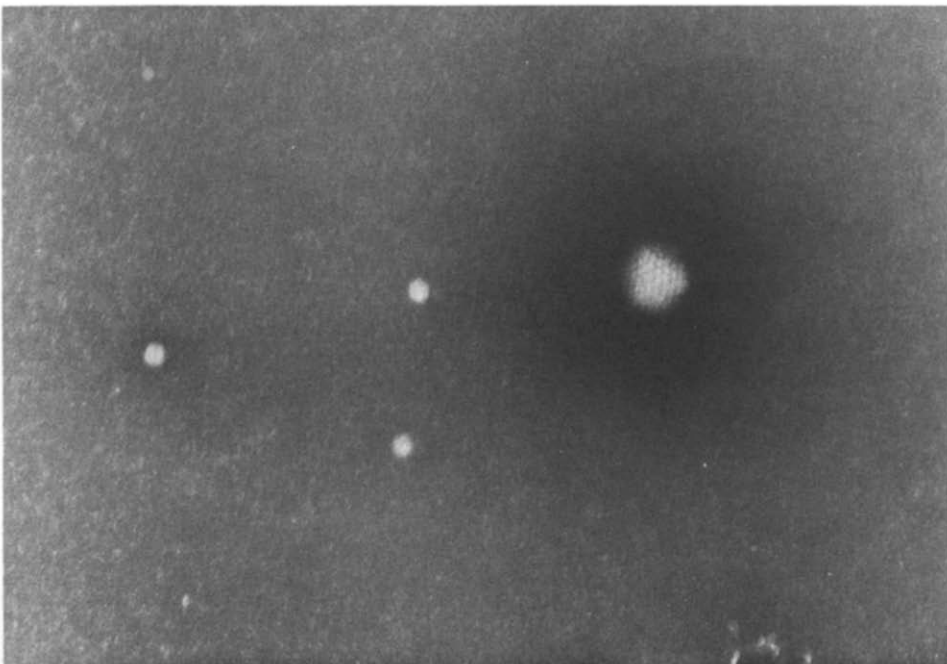


Fig. 2. Ovine adenovirus and 3 intact parvovirus (adeno-associated viruses).

uncommon, it is conceivable that these 90 lambs already harbored adenoviruses when they entered the sale at which time they may also have become infected with *Salmonella* sp. The dual infection was lethal to the lambs while the salmonella infections alone might have been controlled with antibiotics as determined by antibiotic sensitivity tests. Of course, the reverse is also possible, i.e. lambs were latently infected with salmonella upon entry into the sale where they became exposed to adenoviruses.

Coronaviruses

The first recognized enteric coronavirus infection was transmissible gastroenteritis in pigs [18]. Coronaviruses have since been implicated in enteric infections in man [19], calves [20], dogs [21], cats [22], turkeys [23] and rodents [24].

Clinical signs of watery to mucoid diarrhea, depression and anorexia attributed to coronavirus infections are most often observed in 1–3-week-old calves. Rotaviruses, on the other hand, cause the most severe illnesses during the first week of life of the calf. These clinical pictures, however, are frequently not clear-cut since dual infections of rota- and coronavirus are not uncommon in calves. Coronaviruses are also occasionally found in diarrheic as well as normal feces of adult cows.

Transmissible gastroenteritis (TGE) virus causes up to 100% mortalities in piglets during the first week of life. TGE virus infects pigs of all ages but mortality rates in pigs over two weeks of age are minimal. Adult sows may be anorectic and vomit for 24 hr during a TGE outbreak.

Another coronavirus of pigs, hemagglutinating encephalomyelitis virus, can also locate in the intestinal tract but does not induce diarrhea; in fact, it frequently causes constipation [25].

Coronaviruses have recently been isolated from dogs with signs of vomiting and diarrhea [21]. Experimentally-inoculated puppies developed neutralizing antibodies not only to the infecting canine coronavirus but also to TGE virus. However, pigs were resistant to infection with the canine coronavirus [21]. A similar, one-way cross-reaction has also been reported between TGE and a feline coronavirus—feline infectious peritonitis (FIP) virus [26].

Coronavirus-like particles were observed in 24 of 58 canine fecal samples examined from three different geographical areas in Australia [27]. While many of the fecal samples examined in this study were of a loose consistency, the association between coronavirus and diarrhea was not as clear-cut as reported by Binn and co-workers [21].

Coronaviruses were found in the intestines or feces of 25 dogs submitted to our laboratory with signs of gastroenteritis. No consistent pattern of clinical signs was associated with these cases. The clinical courses ranged from acute to chronic or periodic reoccurrence of signs. Affected dogs usually had a watery mucoid type diarrhea with occasional vomiting and blood streaks in the fecal material. In a few cases mixed viral infections were noted consisting of coronaviruses, parvoviruses, picornaviruses and/or paramyxoviruses.

It is now recognized that a coronavirus plays a significant part in the etiology of feline infectious peritonitis (FIP) [22]. While enteritis is not a major clinical manifestation in FIP, we were able to demonstrate coronavirus in the intestinal ingesta of cats succumbing to FIP

infections. Attempts to find FIP virus in the peritoneal and pleural exudate were unsuccessful [28].

Coronavirus infections in humans appear to be associated with upper respiratory as well as enteric infections in a manner similar to coronavirus infections in avian species, i.e. 'common colds' of man and infectious bronchitis of chickens, and intestinal infections of turkeys ('bluecomb') and man. Caul and co-workers observed coronaviruses in 9 of 23 patients during an explosive outbreak of gastroenteritis among 500 service apprentices [19]. Mathan and associates on the other hand found virus-like particles with some morphological resemblance to coronaviruses in 90% of fecal samples from Indian children and adults but not neonates [29]. There did not appear to be an association between these virus-like particles and any specific disease state, since they were found in healthy people as well as individuals with signs of diarrhea.

Coronaviruses are, in our experience, the most difficult viruses to positively identify on a morphological basis in negatively-stained preparations. They are very pleomorphic; but there are certain characteristics which are relatively consistent. The virion itself is usually poorly penetrated by phosphotungstic acid and consists of a rather homogeneous, structureless matrix. Occasionally the center may become stained giving a doughnut-shaped appearance. The length of the peplomers is 20 nm with variations ranging from 16 to 24 nm. The shape of the peplomers may differ and have been variously described as petals, clubs or teardrops. The peplomere is, however, always larger in diameter at the distal end than at the site of attachment to the virion (Fig. 3). This characteristic as well as the length of the peplomers differentiates coronaviruses from orthomyxovirus. Certain cell artifacts such as parts of nuclear or cytoplasmic membranes or parts of organelles may be confused with coronaviruses. However, the interior of these particles is invariably well stained with a distinct 'rim' and the surface projections are generally shorter than coronavirus peplomeres (Fig. 4).

In a recent experiment 50 normal feces from adult dairy cattle were examined at TVMDL. Hollow, pleomorphic particles with about 20 nm surface projections were found in 90% of the cases. After observing nuclear membranes with similar projections we consider these particles as artifacts until proven otherwise.

Paramyxoviruses

Paramyxoviruses are frequently encountered at TVMDL in the intestinal tract of dogs. Canine distemper virus, which is known to replicate in the epithelial cells of the gastrointestinal tract is often present in high enough concentrations in the intestines to be detected by electron microscopic examination. They have been found in feces of both clinically ill and dead dogs. Canine parainfluenza virus can also be detected occasionally in the intestines. Parainfluenza virus may also be involved in canine stillbirth as evidenced by the following case. A healthy bitch delivered at term 4 normally developed dead puppies. Parainfluenza viruses and *Pasteurella multocida* were present in their lungs. On rare occasions paramyxoviruses also have been observed in diarrheic feces of cattle.

Intact paramyxoviruses are not easily identifiable morphologically and can be confused with cell artifacts such as nuclear or cytoplasmic membranes, organelles, etc. However, invariably there are also disrupted virions revealing the typical nucleocapsid present in the preparations (Fig. 5).

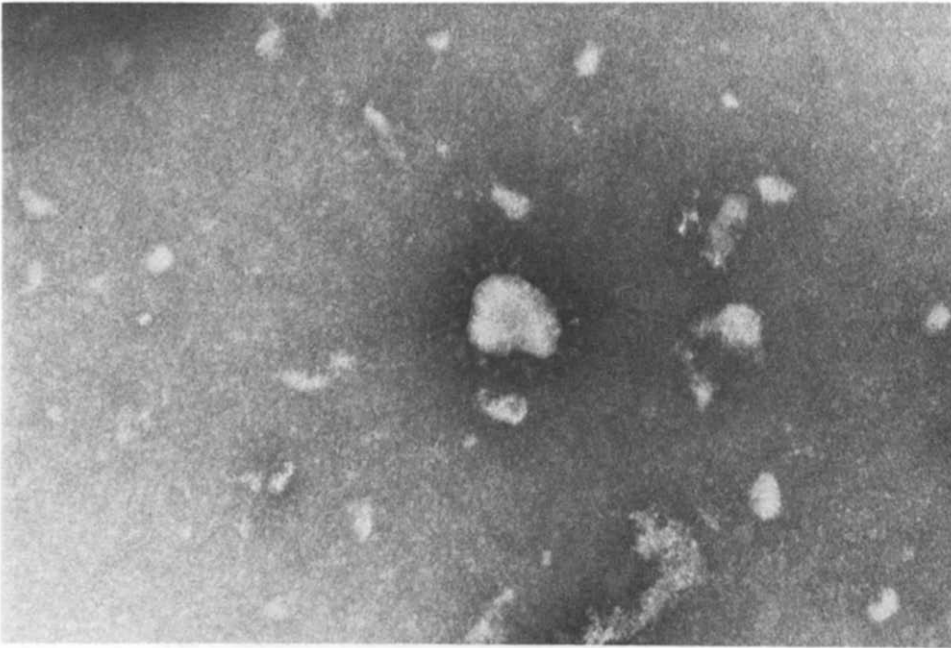


Fig. 3. Porcine coronavirus (TGE); virion: 100 nm; peplomers: 20 nm in length.

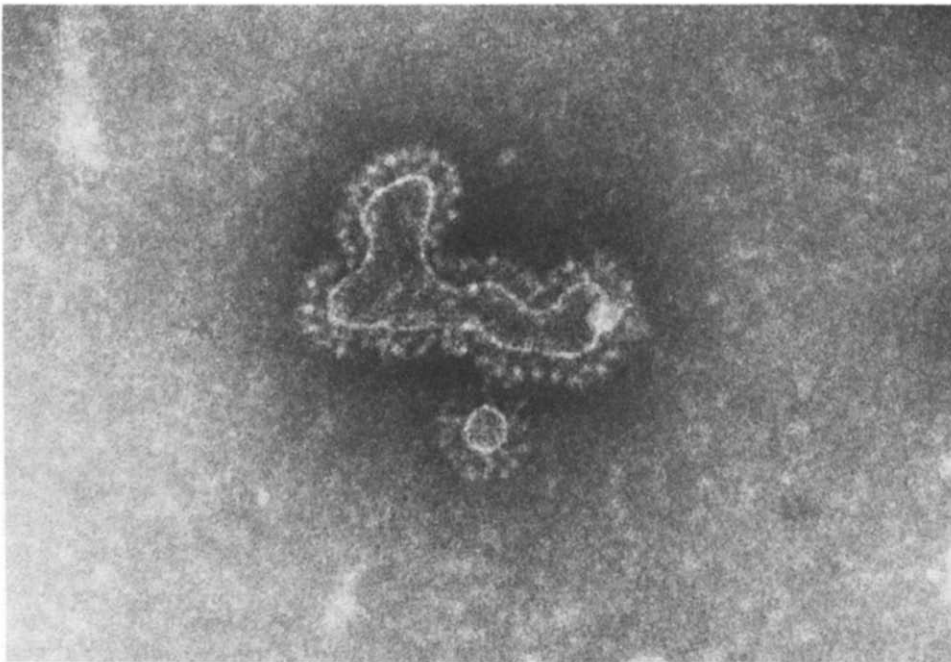


Fig. 4. Cell artifact (parts of nuclear membrane) resembling coronavirus. Note hollow interior and distinct rim with 20-nm long projections.

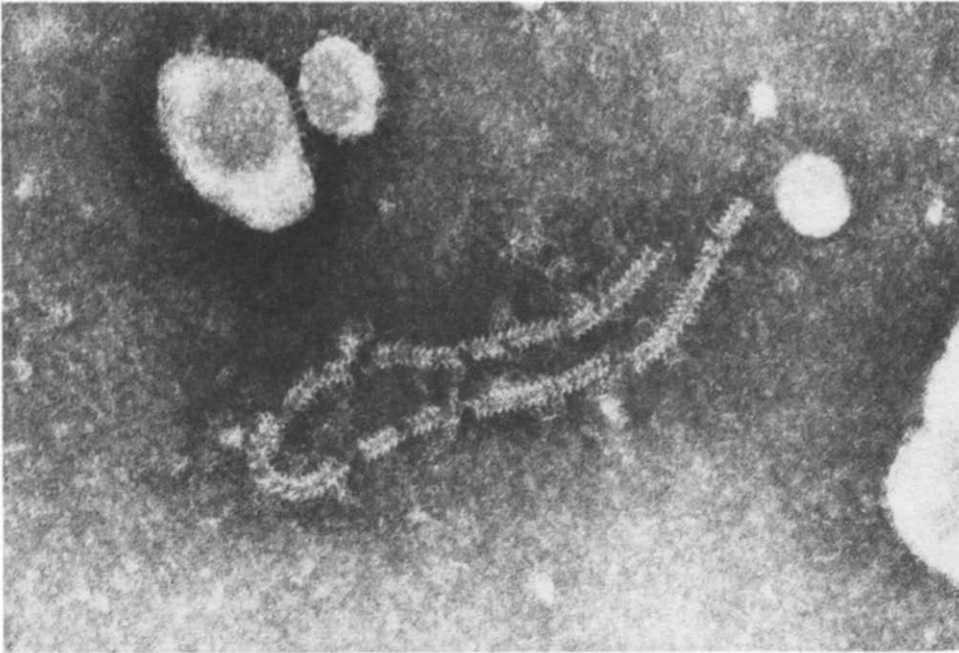


Fig. 5. Paramyxovirus nucleocapsid (canine distemper). 'Herring bone' arrangement of capsomeres. Diameter: 16 nm; pitch of helix: 5 nm.

Parvoviruses

Feline panleucopenia (FPL), the first recognized parvovirus infection (1928), was initially also described as 'infectious enteritis'. The name 'feline panleukopenia' remained, however, since the panleukopenia was a more consistent sign than enteritis [30, 31]. Parvoviruses in general are (fortunately for the diagnostician) present in high numbers at the time animals succumb to their infection. The best specimen for demonstrating parvoviruses in FPL is in the ingesta and mucosa of the lower part of the small intestine.

A parvovirus infection in puppies with similar lesions and signs to those in cats with FPL has recently been observed at TVMDL [32]. Again, the system most severely affected was the digestive tract resulting in diarrhea (frequently bloody), vomiting, and invariably a precipitous decline in the blood leukocyte counts. We have cultivated this canine parvovirus successfully in primary canine kidney, lung and intestinal cell cultures as well as a parasynchronized feline cell line (Crandel feline kidney cell line). The results so far indicate that the virus hemagglutinates porcine red blood cells at 4 and 25°C but not canine, feline or guinea-pig red blood cells. The relationship of this parvovirus to those of other species, especially FPL virus, needs to be elucidated.

Intestinal parvovirus infections have also been detected in calves [33, 34], rabbits [35] and rodents [36].

An interesting case of a parvovirus infection in rabbits was recently submitted to TVMDL. Several litters in a commercial rabbitry were stillborn. Parvoviruses were present in various tissues including the intestinal tract of the stillborn feti. The clinical history of

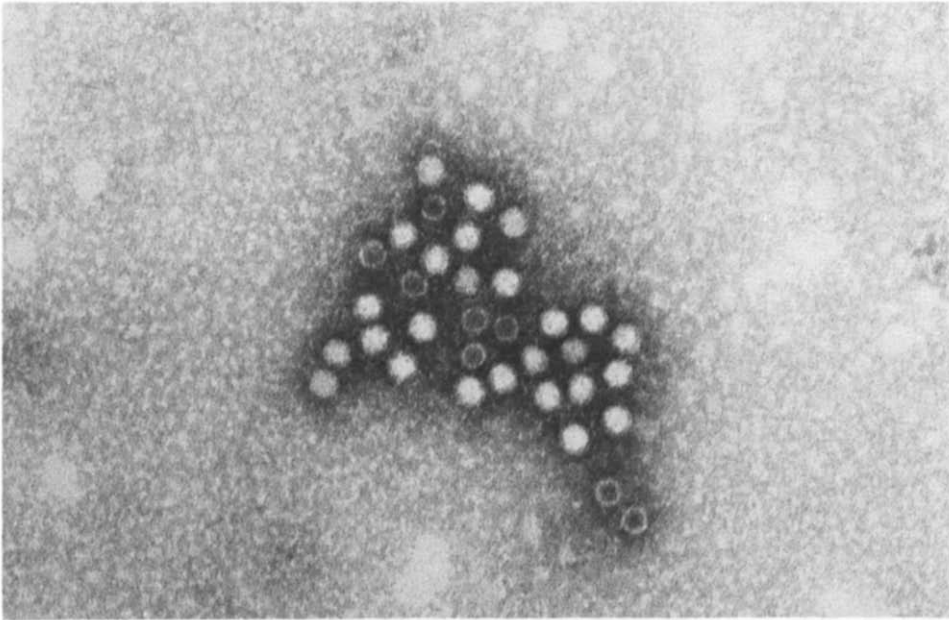


Fig. 6. Aggregates of canine parvovirus; diameter of particles 18–22 nm.

this case resembled parvovirus infections in pigs where stillbirths and fetal mummification are described.

The importance of the intestinal tract in the pathogenesis and epidemiology of parvovirus infections is also evident from findings that the virus can be recovered from the feces of apparently healthy pigs and cattle in the presence of demonstrable humoral antibody levels [37, 38]. These 'latent' parvovirus infections are not an uncommon finding. These viruses have been observed at TVMDL, either in association with adenoviruses or alone in the feces of cattle, pigs, dogs and cats that did not show any enteric signs. Therefore, for the diagnostician to implicate a parvovirus as a cause of death of an animal, the virological findings must be considered together with the clinical signs and the histological lesions.

Viral particles such as Norwalk, Hawaii and MC agents have been detected in acutely ill human patients with a nonbacterial gastroenteritis [39]. None of these agents has so far been successfully cultivated *in vitro*. However, their physical characteristics have certain similarities with parvoviruses. The size of these nonenveloped spherical particles is 25–27 nm in diameter whereas parvoviruses observed in various animal species vary in size from 18 to 25 nm. A definitive classification of these particles awaits *in vitro* cultivation and nucleic acid analysis.

Isolation of parvoviruses in cell cultures is often difficult even if their presence in a specimen is known from electron microscopic examination. Storz and co-workers [40] found a high percentage of animal sera including commercial batches of fetal bovine sera to contain parvovirus hemagglutination inhibition antibodies. These sera, if used in cell cultures, could certainly inhibit parvovirus replication. Parvoviruses are also frequently aggregated *in vivo* (Fig. 6). Isolation of parvoviruses at TVMDL was only possible in cases

where the majority of the parvovirus particles were observed to be unaggregated on electron microscopic examination. Morphological identification of parvoviruses is generally not difficult since these viruses are present in high numbers and are of uniform size and shape. Frequently one can also find a few empty capsids with a vague hexagonal outline (Fig. 7).

Picornaviruses

Picornaviruses encompass a large group of viruses found in many mammals. While some members, such as poliovirus in man, Teschen in pigs, and calicivirus in cats, cause severe clinical manifestations, the majority induce only subclinical infections or mild clinical signs.

Picornavirus (30 nm particles) have been observed at TVMDL on numerous occasions in dogs with a mucoïd to watery diarrhea. This occurs frequently in 'stressed' dogs, such as after moving into a new environment or after returning from a show, sale, etc. The clinical signs are usually limited to a transient diarrhea of a few days' duration.

Two cases were submitted to TVMDL wherein picornaviruses were observed upon necropsy in the intestines of fattening pigs that had shown CNS signs and lesions of a nonsuppurative encephalitis.

Picornaviruses in cattle can be found in normal as well as diarrheic feces. In the latter these viruses were frequently found concurrently with other viral agents such as coronaviruses, rotaviruses and bovine virus diarrhea (BVD).

Picornaviruses have also been observed in diarrheic feces of horses, but it is difficult to determine if they are the sole cause or just a contributing factor to the clinical signs since there are no experimental data reported in the literature.

Picornaviruses in cats, also known as caliciviruses, are readily observable in vesicle fluids in the oral cavity as well as in the intestines. Caliciviruses have also recently been found in feces of infants and young children [41, 42].

Picornaviruses are spherical particles measuring about 30 nm in diameter (Fig. 8). They can be confused with parvoviruses except for their size; parvoviruses larger than 25 nm or picornaviruses smaller than 25 nm have never been observed at TVMDL. Caliciviruses of cats are larger and measure 35–40 nm in diameter.

Astroviruses

These viruses with a diameter of 29 nm have so far only been observed in humans, although a short reference is made by Flewett [43] that Woode and Bridges in Compton, England, have isolated a bovine astrovirus. We have not yet knowingly encountered astroviruses at TVMDL. Astroviruses appear to cause mostly subclinical infections in man [43].

Rotaviruses

Rotaviruses, previously known as reovirus-like agents, have been demonstrated on numerous occasions in the feces of human infants [44], calves [45], piglets [46], suckling mice [47], rabbits [48], monkeys [49], lambs [50] and foals [51, 52].

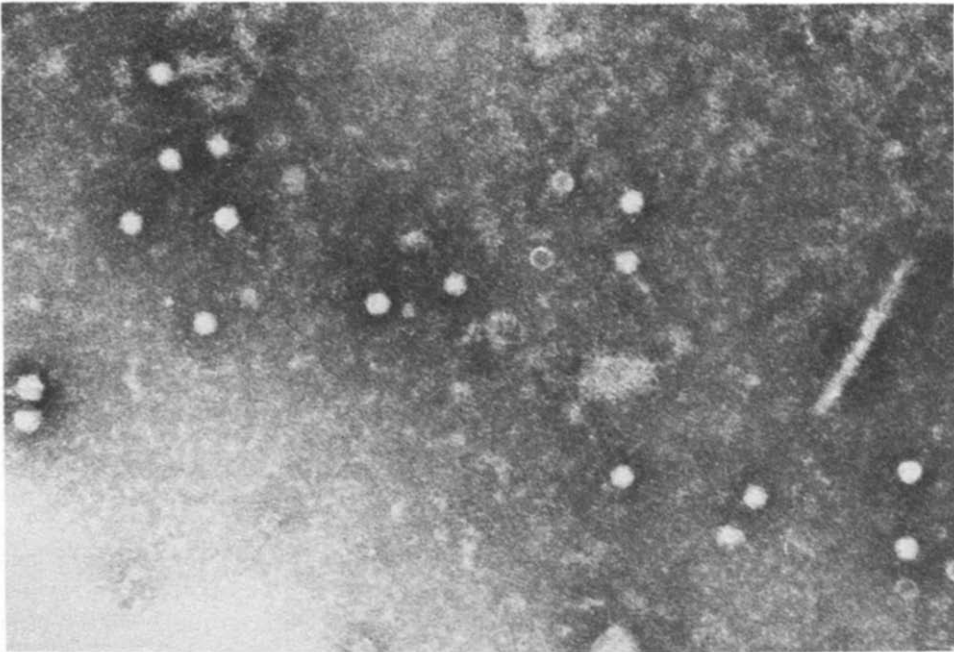


Fig. 7. Nonaggregated feline parvovirus. Complete virions as well as empty capsids present. Diameter: 18–22 nm.

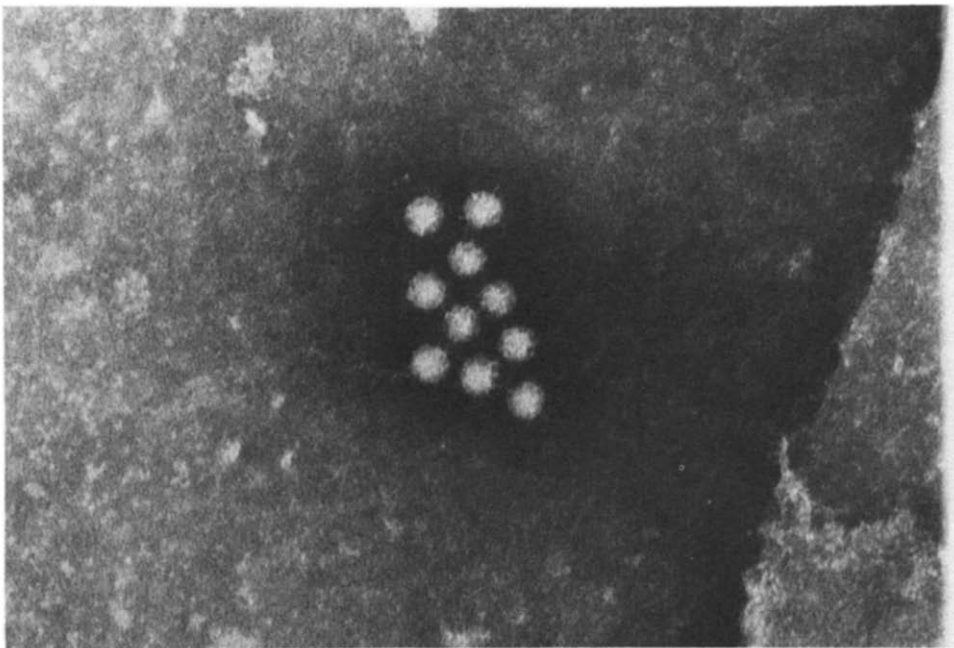


Fig. 8. Aggregate of canine picornavirus. Diameter: 30 nm.

The primary clinical manifestation of an enteric rotavirus infection is a profuse watery diarrhea with some vomiting in children and pigs. Human infants with rotavirus infections, unlike calves and piglets, are frequently febrile.

Some of the more unusual cases observed at TVMDL involved an outbreak of diarrhea in a zoo nursery involving an impala (*Aepyceros melampus*), a Thomson's gazelle (*Gazella thomsonii*) and an addax (*Addax nasomaculatus*) [53]. These neonates suffered from an acute gastroenteritis, with the infection spreading rapidly through this overcrowded nursery.

Rotaviruses in dogs have so far not been described in the literature. The first case of a canine rotavirus infection received at TVMDL occurred in a 12-week-old puppy. This animal was purchased from a pet store where canine parvovirus and *Giardia* sp. infections were previously diagnosed. The puppy had a watery diarrhea of 6-day duration with no other clinical signs and made an uneventful recovery. Feces obtained 7 days after onset of diarrhea contained numerous rotaviruses as well as some picornaviruses (Fig. 9).

Rotaviruses were also present in the intestine of two parrots suffering from an acute enteritis resembling bluecomb of turkeys. These viruses previously had not been observed in psittacine birds.

In man, as well as many animals, the neonates are the most severely affected and contain the highest concentration of rotaviruses found in these cases. On the other hand, rotaviruses in piglets appear to cause diarrhea more frequently in the 3–6-week-old age group.

Sporadically, rotaviruses are also found in older calves as well as adult cows with diarrhea. In these cases mixed infections of coronaviruses, picornaviruses, BVD and rotaviruses are not uncommon.

Morphologically, rotaviruses are spherical in shape, 75–80 nm in diameter, with a double-shelled capsid. Particles are occasionally observed in which there is no outer capsid layer; these particles are reduced in size to approximately 55–60 nm. This characteristic can sometimes lead to confusion in distinguishing a rotavirus from either a reovirus or an orbivirus; as was evidenced by a case that was received at TVMDL during the summer of 1977. Feces from a foal with diarrhea contained only the smaller, single-capsid layer particles [52]. Whether this was the result of denaturation due to time in transit, or if these were indeed complete virions, was not determined. Nevertheless, these viral particles were agglutinatable by antiserum against a bovine rotavirus as determined by immunoelectron-microscopy. Routinely, rotaviruses, reoviruses and orbiviruses are morphologically distinguishable from one another on the basis of outer capsid layer characteristics.

The rotaviruses from different hosts cannot be differentiated morphologically. Although there is a degree of antigenic relatedness, there is preliminary evidence to suggest that species specificity is retained [54, 55].

Unusual viral findings

Occasionally unusual viruses can be found in the intestinal tract or viruses can be found in unusual tissue sites as exemplified in the following two cases. Virus particles closely resembling rhabdoviruses were observed in the feces of a healthy young dog (Fig. 10). The dog was kept under observation and never developed any signs of rabies. Of course,

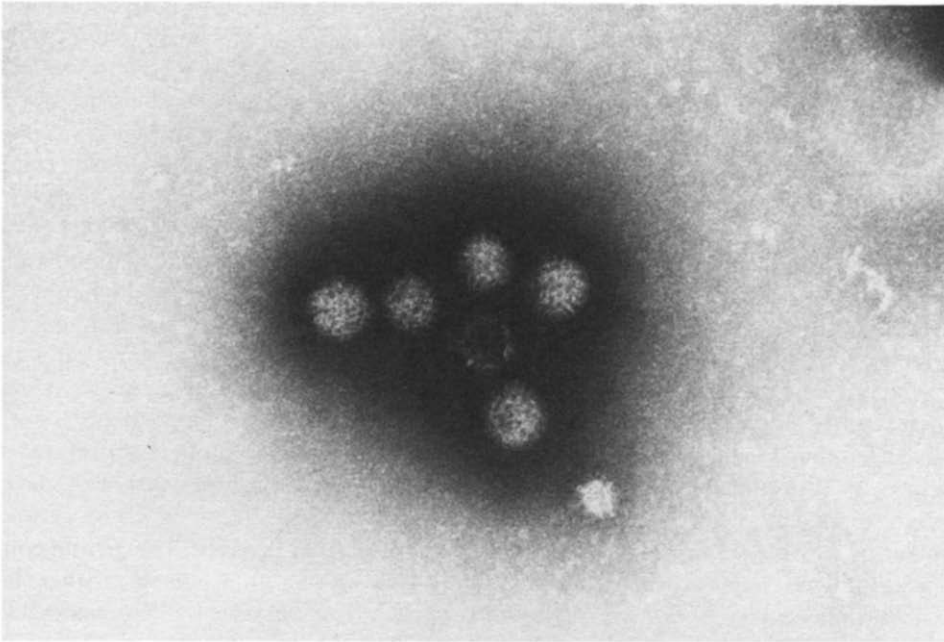


Fig. 9. Canine rotaviruses with double shelled capsids. Diameter: 80 nm.

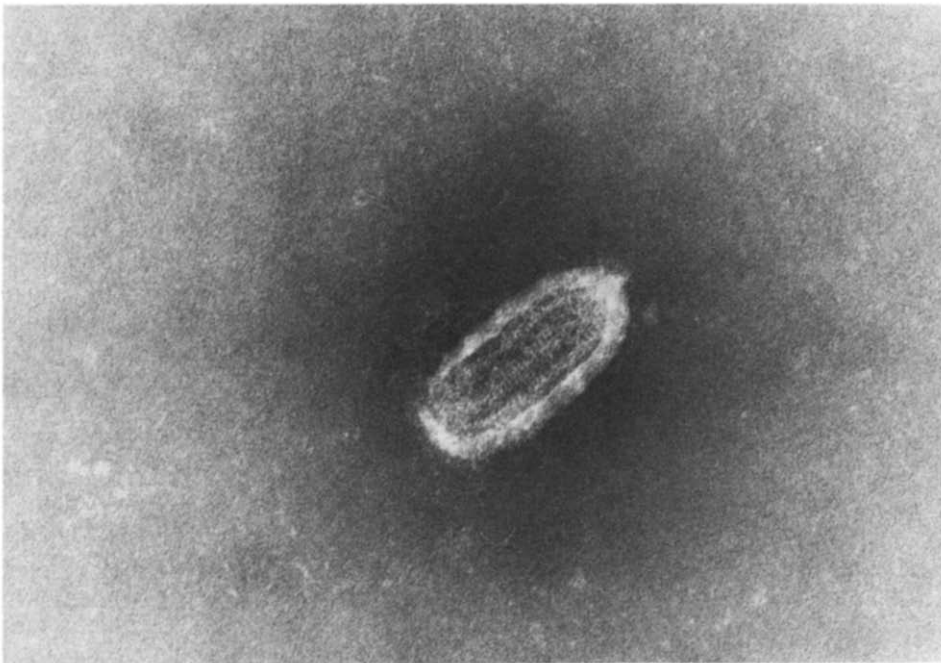


Fig. 10. Rhabdovirus found in canine feces (virus species unknown). Size: 75 × 180 nm.

rhabdoviruses can be found in plants, insects, and poikilothermic as well as homeothermic vertebrates. Undoubtedly some of the ingested viruses will pass the intestinal tract and may be observed 'accidentally'. Nevertheless, close observation of the animals is warranted since at least two rhabdoviruses, rabies virus and the Marburg agent, are lethal for man.

On two occasions parvoviruses were found in skin biopsies of swine. The skin lesions were typical of swine pox and negatively-stained homogenates of the skin biopsies revealed poxviruses as well as parvoviruses. The presence of parvoviruses in these pox lesions is not understood. Perhaps the increased mitotic activity in the early pox lesion represents a favorable environment for parvoviruses during the viremic stage.

Unidentified viral particles

In the course of examining fecal specimens, particles with some resemblance to viruses are frequently encountered. Experienced investigators will recognize many of these particles as phage heads, ribosomal aggregates or ribosomal subunits (Fig. 11), parts of bacterial or mammalian cell membrane, etc. Nevertheless, particles with definite viral characteristics but little or no resemblance to known virus families are occasionally observed.

The following viruses have been found at TVMDL in adult horses with chronic diarrhea: rotaviruses, picornaviruses (30-nm particles) and particles with viral staining characteristics measuring 45 nm in diameter (Fig. 12). Definite structural subunits were evident and of the known virus families the particles resembled most closely caliciviruses.

Virus-like helical structures of variable length and 20 nm in diameter were observed in chicken kidney cell cultures inoculated with a suspension of the Bursa Fabricius (Fig. 13). These particles resembled most closely nucleocapsids of paramyxoviruses. However, the diameter of the particle was about 5 nm larger than that of known paramyxoviruses, the central canal was wider and the capsomeres smaller. Also, the capsomeres did not appear to be arranged in the typical spiral form.

Particles with typical viral substructures were found in the feces of a 2-yr-old cow which had diarrhea and had been losing weight for at least two months (Fig. 14). Laboratory tests indicated that these signs were due to ostertagia. The few virus-like particles observed in the feces all had 4 centrally-located capsomeres of 10-nm diameter with 'empty' capsomeres outlining the surface. In comparing these particles morphologically with known virus families one could speculate that on the basis of the size and shape of the capsomeres, they may represent partially denatured herpesviruses.

CONCLUSIONS

Within the last decade viral enteropathogens have become recognized as a leading cause of diarrhea in neonates of various animal species as well as man. The ubiquitous nature of many of these viral agents makes prevention difficult since vaccines are not available. However, since at least some of the viruses exist in the form of subclinical infections in a delicate balance with the host, factors shifting this balance in favor of the parasite should be controlled. Maintaining the animal in a healthy state, avoiding overcrowding and minimizing exposure are preventative factors to be considered.

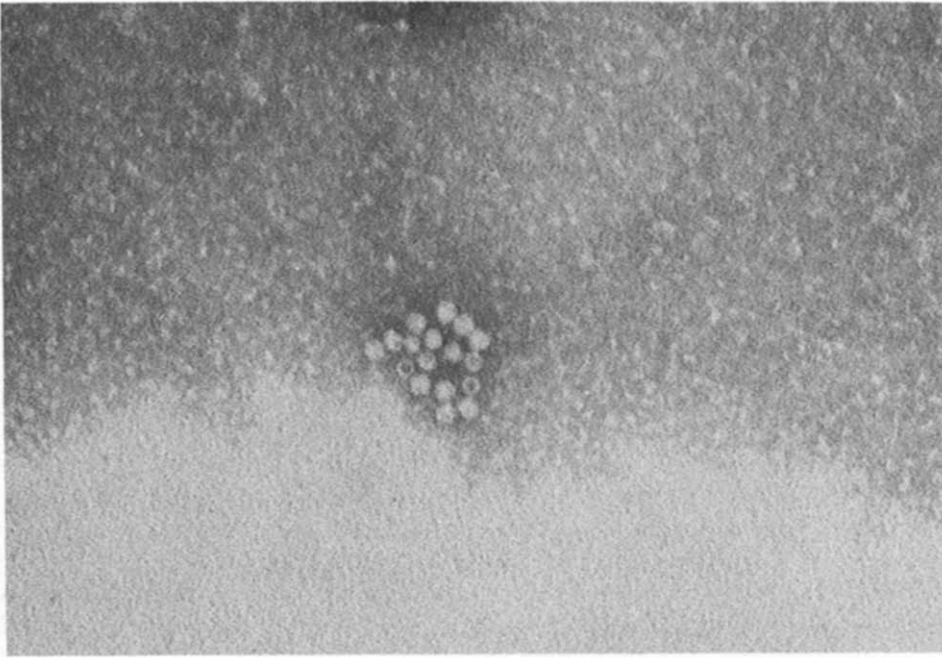


Fig. 11. Aggregates of ribosomal subunits resembling parvoviruses except for their smaller size. Diameter 8–10 nm.

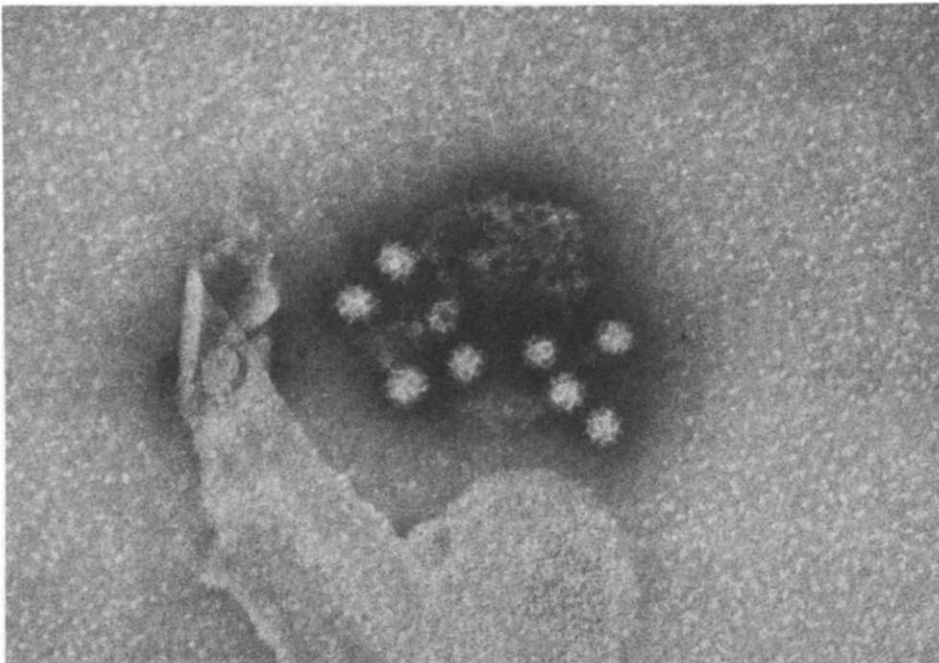


Fig. 12. Unidentified virus-like particle in diarrheic equine feces. Diameter: 45 nm.

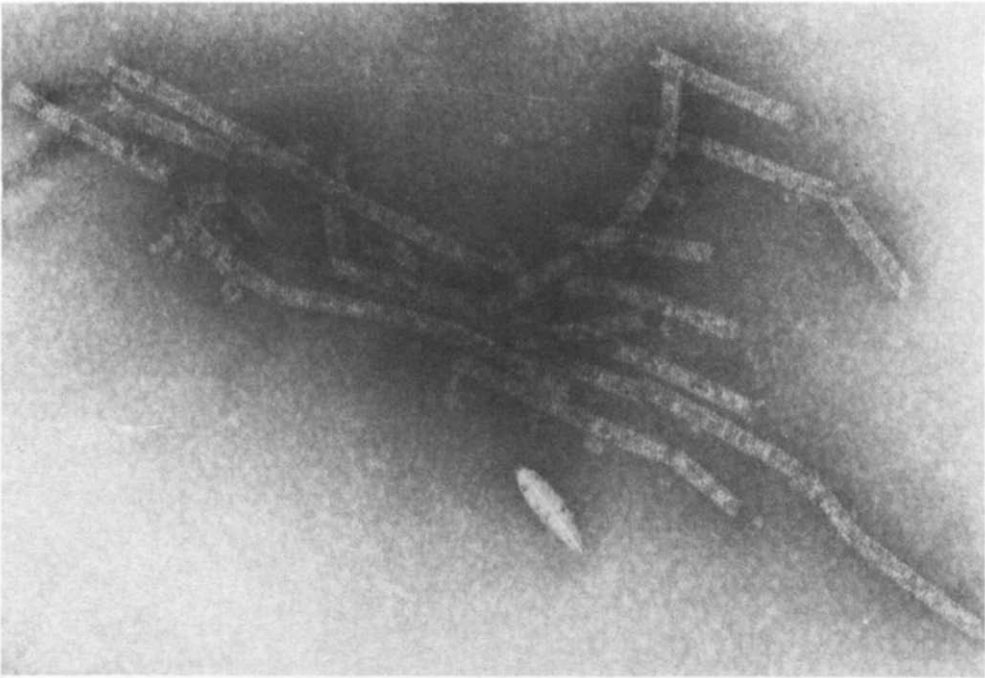


Fig. 13. Paramyxovirus-like particles. Diameter: 20 nm.

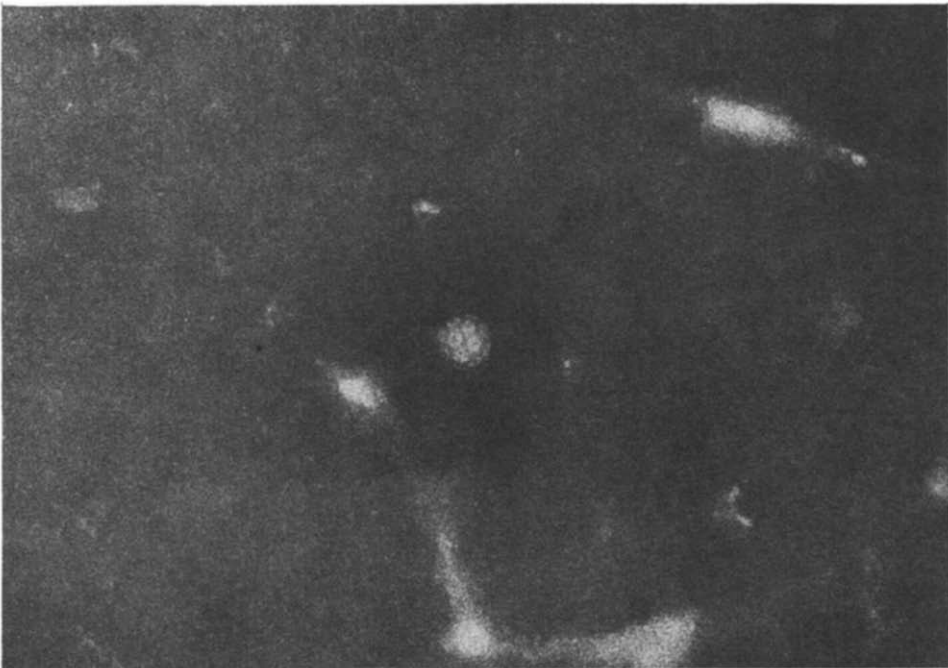

Fig. 14. Virus-like particle found in bovine feces. Diameter of particle: 35 nm; diameter of 'capsomeres': 10 nm.

Adenoviruses may cause severe enteric signs in isolated cases in man as well as in animals under certain circumstances. Pathogenicity of individual strains, genetic susceptibility of animals, concurrent infection with other pathogens as well as other factors need to be further elucidated. As the field cases reported herein illustrate, adenovirus infections are probably most prevalent in places with high animal densities such as ovine or bovine feedlots. In comparison, adenovirus infections in man also represent the most serious problem among military recruits during 'boot camp'.

Certain members of the coronavirus family, such as TGE virus, calf coronavirus and bluecomb virus, are recognized pathogens that cause severe outbreaks of enteritis. While some case reports implicate coronavirus in man and dogs as a cause of diarrhea, other studies do not associate these viruses with any specific disease state. The role of these viruses in enteric infections of man and dog must await experimental and pathogenetic studies. The pleomorphism of coronaviruses makes these viruses difficult to identify on a strictly morphological basis, and some of the electronmicrographs in the literature cast some doubt as to whether they are indeed coronaviruses.

Paramyxoviruses, with the notable exception of canine distemper virus, are not known to cause intestinal infections.

Parvoviruses are well-known enteropathogens as exemplified by feline panleukopenia and a similar syndrome recently recognized in puppies [32]. The parvoviruses in these two species appear not to be defective, as they have not been found associated with adenoviruses. Adeno-associated parvoviruses have been found in various species and their role in the pathogenesis of enteric infections, if any, is unknown. Norwalk and related agents have definitely been associated with outbreaks of gastroenteritis in man. These agents are about 5–7 nm larger in diameter than all recognized parvoviruses in animals and their classification is not certain.

The intestinal tract serves as an important replication site for picornaviruses even though some of them such as human poliomyelitis virus, and Teschen and Talfan virus of pigs may ultimately invade the nervous system. Most picornaviruses cause subclinical infections. The infections may become clinically apparent, however, if the host is stressed or concurrently infected with other potential bacterial or viral pathogens.

The host spectrum of rotaviruses now encompasses some 13 animal species and man. These viruses are a leading cause of diarrhea in the young but may also cause sporadic intestinal infections in adult animals and human beings. All known rotaviruses share some common antigens associated with the inner capsid layer but they appear to be species-specific on the basis of cross-neutralization tests and RNA migration patterns [54, 55].

REFERENCES

1. Bell, J. A., Ward, T. G., Huebner, R. J., Rowe, W. P., Suskind, G. and Paffenbarger, R. S., Studies on adenoviruses (APC) in volunteers, *Am. J. publ. Hlth.* **46**, 1130–1146 (1956).
2. Kasel, J. A., Lode, F. and Knight, V., Infection of volunteers with adenovirus type 16, *Proc. Soc. exp. Biol. Med.* **114**, 621–623 (1963).
3. Rowe, W. P., Huebner, R. J., Gilmore, L. K., Parrott, R. H. and Ward, T. G., Isolation of a cytopathogenic agent from human adenoids undergoing spontaneous degeneration in tissue culture, *Proc. Soc. exp. Biol. Med.* **84**, 570–573 (1953).
4. Couch, R. B., Cate, T. R., Fleet, W. F., Gerone, P. J. and Knight, V., Aerosol-induced adenoviral illness resembling the naturally occurring illness in military recruits, *A. Rev. Resp. Dis.* **93**, 529–535 (1966).

5. Eugster, A. K., Kalter, S. S., Kim, C. S. and Pinkerton, M. E., Isolation of adenoviruses from baboons (*Papio* sp) with respiratory and enteric infections, *Arch. ges. Virusforsch.* **26**, 260-270 (1969).
6. Kasza, L., Isolation of an adenovirus from the brain of a pig, *Am. J. vet. Res.* **27**, 751-758 (1966).
7. Sharpe, H. B. A. and Jessett, D. M., Experimental infection of pigs with two strains of porcine adenovirus, *J. comp. Path. Ther.* **77**, 45-50 (1967).
8. Kapsenberg, J. G., Relationship of infectious canine hepatitis virus to human adenovirus, *Proc. Soc. exp. Biol. Med.* **101**, 611-614 (1959).
9. McChesney, A. E., England, J. J. and Rich, L. J., Adenoviral infections in foals, *J. Am. vet. med. Ass.* **162**, 545-549 (1974).
10. Klein, M., Earley, E. and Zellat, J., Isolation from cattle of a virus related to human adenovirus, *Proc. Soc. exp. Biol. Med.* **102**, 1-4 (1959).
11. Aldasy, P., Csontos, L. and Bartha, A., Pneumonoenteritis in calves caused by adenovirus, *Acta vet. hung.* **15**, 167-175 (1965).
12. Darbyshire, J. H., Kinch, D. A. and Jennings, A. R., Experimental infection of calves with bovine adenovirus types 1 and 2, *Res. Vet. Sci.* **10**, 39-45 (1969).
13. Whitelaw, A., Davies, H. and Parry, J., Electronmicroscopy of fatal adenovirus gastroenteritis, *Lancet* **i**, 361 (1977).
14. Reed, D. E., Wheeler, J. G. and Lupton, H. W., Isolation of bovine adenovirus type 7 from calves with pneumonia and enteritis, *Am. J. vet. Res.* **39** (12), 1968-1971 (1978).
15. McFerran, J. B., Nelson, R., McCracken, J. M. and Ross, J. G., Viruses isolated from sheep, *Nature, Lond.* **221**, 194-195 (1969).
16. Belak, S., Palfi, V. and Palya, V., Adenovirus infection in lambs. I. Epizootiology of the disease, *Zentbl. VetMed. (B)* **23**, 320-330 (1976).
17. Belak, S., Palfi, V. and Tury, E., Experimental infection of lambs with an adenovirus isolated from sheep and related to bovine adenovirus type 2. I. Virological studies, *Acta vet. hung.* **25**, 91-95 (1975).
18. Doyle, L. P. and Hutchings, L. M., A transmissible gastroenteritis in pigs, *J. Am. vet. med. Ass.* **108**, 257-259 (1946).
19. Caul, E. O., Paver, W. K. and Clarke, S. K. R., Coronavirus particles in feces from patients with gastroenteritis, *Lancet* **i**, 1192 (1975).
20. Mebus, C. A., White, R. G., Stair, E. L., Rhodes, M. B. and Twiehaus, M. J., Neonatal calf diarrhea: results of field trial using a reo-like virus vaccine, *Vet. Med./Small Animal Clin.* **67**, 173-174 and 177-178 (1972).
21. Binn, L. N., Lazor, E. C., Keenan, K. P. and Huxsall, D. L., Recovery and characterization of a coronavirus from military dogs with diarrhea. Proc. U.S. Animal Health Assoc., Roanoke, VA, pp. 359-366 (1974).
22. Wolfe, L. G. and Griesemer, R. A., Feline infectious peritonitis, *Path. Vet.* **3**, 255-270 (1966).
23. Panigrahy, B., Naqi, S. A. and Hall, C. F., Isolation and characterization of viruses associated with transmissible enteritis (Bluecomb) of turkeys, *Avian Dis.* **17** (2), 430-438 (1973).
24. Rowe, W. P., Hartley, J. W. and Capps, W. I., Mouse hepatitis virus infection as a highly contagious, prevalent enteric infection of mice, *Proc. Soc. exp. Biol. Med.* **112**, 161-165 (1963).
25. Schwartz, W. L., Eugster, A. K. and Tiemann, J. F., Probable vomiting and wasting disease in Texas pigs, *Vet. Med./Sm. Animal Clin.* **71**, 1583-1587 (1976).
26. Witte, von K. H., Tuch, K., Dubenkropp, H. and Walther, C., Untersuchungen über die Antigenverwandtschaft der Viren der Felinen Infektiösen Peritonitis (FIP) und der Transmissiblen Gastroenteritis (TGE) des Schweines, *Berl. Münch. tierärztl. Wschr.* **90**, 396-401 (1977).
27. Schnagl, R. D. and Holmes, I. A., Coronavirus-like particles in stools from dogs from some country areas in Australia, *Vet. Rec.* **102**, 528-529 (1978).
28. Eugster, A. K. and Liauw, H., Detection of antibodies to feline infectious peritonitis (FIP) virus in cats using transmissible gastroenteritis (TGE) virus as antigen and an electronmicroscopic search for FIP virus, *S.W. Vet.*, **32**, 109-112 (1979).
29. Mathan, M., Mathan, V. I., Swaminathan, S. P., Yesudoss, S. and Baker, S. J., Pleomorphic virus-like particles in human feces, *Lancet* **i**, 1068-1069 (1975).
30. Verge, J. and Cristoforoni, N., La gastroentérite infectieuse des chats est-elle due à un virus filtrable?, *C. r. Séanc. Soc. Biol.* **99**, 312-314 (1928).
31. Hammon, W. D. and Enders, J. F., A virus disease of cats principally characterized by a leukocytosis, enteric lesions and the presence of intranuclear inclusion bodies, *J. exp. Med.* **69**, 327-351 (1939).
32. Eugster, A. K., Bendele, R. A. and Jones, L. P., Parvovirus infection in puppies, *J. Am. vet. med. Ass.* **173**, 1340-1341 (1978).
33. Abinanti, F. R. and Warfield, M. S., Recovery of a hemadsorbing virus (HADEN) from the gastrointestinal tract of calves, *Virology* **14**, 288-289 (1961).
34. Storz, J. and Bates, R. C., Parvovirus infection in calves, *J. Am. vet. med. Ass.* **163**, 883-886 (1973).

35. Matsunaga, Y., Matsuno, S. and Mukoyama, J., Isolation and characterization of a parvovirus of rabbits, *Infect. Immun.* **18**, 495–500 (1977).
36. Lipton, H., Nathanson, N. and Hodous, J., Enteric transmission of parvoviruses: pathogenesis of rat virus infection in adult rats, *Am. J. Epidem.* **96**, 443–446 (1973).
37. Bachmann, P. A., Parvoviren beim Schwein, *Zentbl. VetMed.* **17**, 192–194 (1969).
38. Bates, R. C., Storz, J. and Reed, D. E., Isolation and comparison of bovine parvoviruses, *J. inf. Dis.* **126**, 531–536 (1972).
39. Dolin, R., Norwalk agent-like particles associated with gastroenteritis in human beings, *J. Am. vet. med. Ass.* **173** (5), 615–619 (1978).
40. Storz, J., Bates, R. C., Warren, G. S. and Howard, T. H., Distribution of antibodies against bovine parvovirus I in cattle and other animal species, *Am. J. vet. Res.* **33**, 269–272 (1972).
41. Madeley, G. R. and Cosgrove, B. P., Calicivirus in man, *Lancet* **i**, 199–200 (1976).
42. Flewett, T. H. and Davies, H., Calicivirus in man, *Lancet* **i**, 311 (1976).
43. Flewett, T. H., Electron microscopy in the diagnosis of infectious diarrhea, *J. Am. vet. med. Ass.* **173** (5), 538–543 (1978).
44. Bishop, R. F., Davidson, G. P., Holmes, I. H. and Ruck, B. J., Virus particles in epithelial cells of duodenal mucosa from children with acute nonbacterial gastroenteritis, *Lancet* **ii**, 1281–1283 (1973).
45. Mebus, C. A., Underdahl, N. R. and Rhodes, M. B., Calf diarrhea (scours). Reproduced with a virus from a field outbreak. Bulletin 233, University of Nebraska, Agricultural Exp. Station (1969).
46. Woode, G. N., Bridges, J. C., Hall, G. A., Jones, J. M. and Jackson, G., The isolation of reovirus-like agents (rotaviruses) from acute gastroenteritis of piglets, *J. med. Microbiol.* **9**, 203–209 (1976).
47. Much, D. H. and Zajac, I., Purification and characterization of epizootic diarrhea of infant mice virus, *Infect. Immun.* **6**, 1019–1024 (1972).
48. Bryden, A. S., Thauless, M. E. and Flewett, T. H., Rotaviruses in rabbits, *Vet. Rec.* **19**, 323 (1976).
49. Els, H. J. and Lecostsas, G., Morphological studies on Semian virus SA II and the related 'Q' agent, *J. gen. Virol.* **17**, 129–132 (1972).
50. Snodgrass, D. R., Smith, W. and Gray, E. W., A rotavirus in lambs with diarrhea, *Res. vet. Sci.* **20**, 113–114 (1976).
51. Flewett, T. H., Bryden, A. S. and Davies, H., Virus diarrhea in foals and other animals, *Vet. Rec.* **95**, 477 (1975).
52. Eugster, A. K., Whitford, H. W. and Mehr, L. E., Concurrent rotavirus and salmonella infections in foals, *J. Am. vet. med. Ass.* **173** (7), 857–858 (1978).
53. Eugster, A. K., Strother, J. and Hartfiel, D. A., Rotavirus (reovirus-like) infection of neonatal ruminants in a zoo nursery, *J. Wildl. Dis.* **14**, 351–354 (1978).
54. Woode, G. N., Bridges, J. C., Jones, J. M. *et al.*, Morphological and antigenic relationships between viruses (rotaviruses) from acute gastroenteritis of children, calves, piglets, mice, and foals, *Infect. Immun.* **14**, 804–810 (1976).
55. Kalica, A. R., Wyatt, R. G. and Kapikian, A. Z., Detection of differences among human and animal rotaviruses using analysis of viral RNA, *J. Am. vet. med. Ass.* **173** (5), 531–537 (1978).