

[CASE REPORT]

Successful Endoscopic Sclerotherapy Using Polidocanol for Small Bowel Hemangioma

Taiki Aoyama, Akira Fukumoto, Kenjiro Shigita, Naoki Asayama,
Shinichi Mukai and Shinji Nagata

Abstract:

Small-bowel hemangiomas are a possible source of gastrointestinal bleeding for which there is no established treatment approach. In this report, we describe the case of a 58-year-old woman who presented with hematochezia and who was diagnosed with small bowel hemangioma. She was successfully treated using endoscopic sclerotherapy. Initial capsule endoscopy revealed bleeding in the ileum. Subsequent double-balloon enteroscopy showed a 2-cm, bluish-purple, ileal submucosal tumor with an overlying protrusion. The lesion was responsible for the hematochezia and was treated with intralesional injection of polidocanol. The hematochezia completely resolved and at 4 months after sclerotherapy, the size of the lesion was significantly reduced.

Key words: small bowel, hemangioma, endoscopic sclerotherapy, polidocanol, double-balloon enteroscopy

(Intern Med 59: 1727-1730, 2020)

(DOI: 10.2169/internalmedicine.4327-19)

Introduction

Small bowel hemangioma is a type of vascular lesion that causes gastrointestinal bleeding (1, 2). Surgical resection of the tumor remains the most common treatment method (3). Although endoscopic resection of small bowel hemangioma has been attempted as a minimally invasive treatment approach (4), the procedure is associated with some concerns related to intestinal perforation, considering the thin walls of the small bowel. A simpler, safer, and more effective treatment modality is therefore required for treating this condition.

Endoscopic injection of polidocanol is widely accepted as a safe and effective treatment for esophageal varices (5). Moreover, it can also be used to manage esophageal hemangiomas (6). Nevertheless, few reports have described the use of endoscopic sclerotherapy for the treatment of small bowel hemangiomas (7-9). Additional reports on the clinical usefulness of this procedure are needed to ascertain its utility. In the present report, we describe the case of a patient diagnosed with small bowel hemangioma of the ileum. The patient was successfully treated with intralesional injection of

polidocanol, after gaining access to the tumor via double-balloon enteroscopy.

Case Report

A 58-year-old woman presented with the complaint of hematochezia. Contrast enhanced computed tomography (CECT) revealed a non-enhancing, hemispheric, elevated mass within the ileal wall (Fig. 1). She was hospitalized in March 2019 for evaluation and treatment of the small bowel lesion. Her hemoglobin levels declined from 16.0 g/dL to 13.2 g/dL after this series of symptoms. The patient had chronic hepatitis C and reported a history of excision of cutaneous hemangiomas affecting the neck and foot during childhood. She still presented several cutaneous hemangiomas on her arm and foot (Fig. 2). Previous esophagogastroduodenoscopy revealed no varices.

The patient's entire small bowel was examined by capsule endoscopy (CE) (PillCam™ SB3 video capsule, Medtronic, Dublin, Ireland). It showed several blue-colored elevated lesions on the small bowel mucosa. The most distal of these lesions appeared to be the largest in size (Fig. 3A) and was observed to have fresh blood in its vicinity (Fig. 3B, C).

Department of Gastroenterology, Hiroshima City Asa Citizens Hospital, Japan

Received: December 11, 2019; Accepted: February 13, 2020; Advance Publication by J-STAGE: April 2, 2020

Correspondence to Dr. Taiki Aoyama, t-aoyama@asa-hosp.city.hiroshima.jp

Subsequently, we performed double-balloon enteroscopy (DBE) (EN-580T, FUJIFILM, Saitama, Japan) using an oral approach. Overall, three lesions were identified in the duodenum and the jejunum, all of which had the appearance of elastic soft, blue-colored, submucosal tumors (SMT), and which were therefore endoscopically diagnosed as heman-

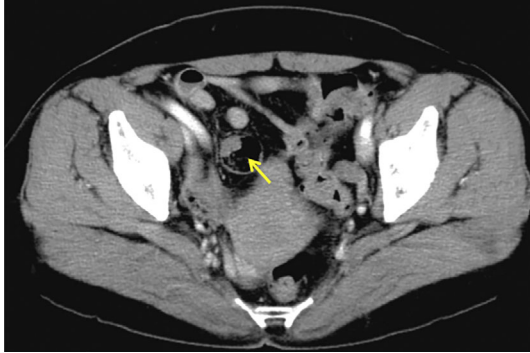


Figure 1. Contrast enhanced computed tomography performed during the portal phase reveals a non-enhancing, hemispheric elevation within the ileum (yellow arrow).

giomas. All lesions were approximately 1 cm in size and were not considered responsible for the bleeding that had been observed earlier (Fig. 4A). However, considering the patient's recent symptoms, the lesions were thought to be associated with a potential risk of bleeding, which was considered an indication for endoscopic treatment. A 0.5 mL dose of 1% polidocanol was injected into each of the three lesions. Thereafter, we performed DBE again via an anal approach to ascertain the position of the ileal lesion. Only one lesion was encountered in the ileum, which was also diagnosed as a hemangioma (Fig. 4B). The lobular 2 cm-sized ileal lesion, which was bluish-purple in color with an elastic soft SMT-like appearance, was considered responsible for the hematochezia due to the presence of a protrusion (white plaque) over the lesion. We therefore performed intralesional endoscopic sclerotherapy at this site as well. Overall, 2.5 mL of polidocanol was injected using five punctures while monitoring changes in the color and volume (inflation) of the lesion in proportion to the injected dose (Fig. 4C). No other bleeding sources were identified in the colon during the withdrawal of the anally inserted enteroscope.

The patient did not experience any post-procedural ad-

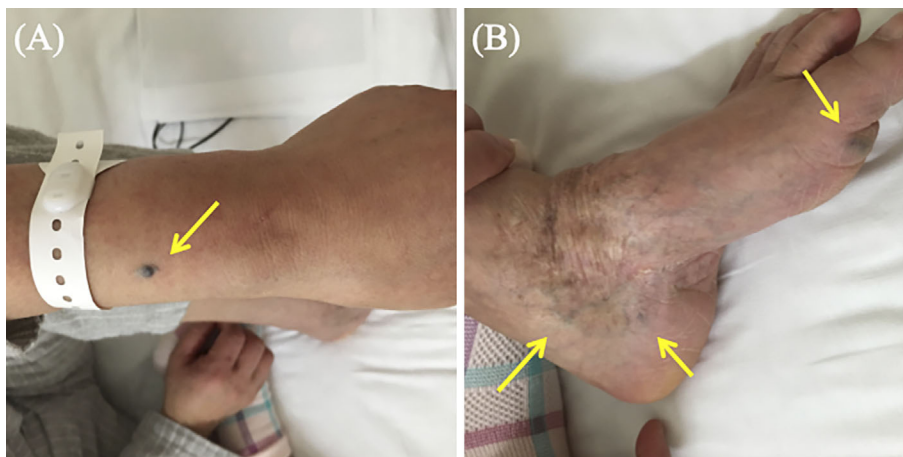


Figure 2. Cutaneous hemangiomas visible on the patient's (A) left arm and (B) left foot (yellow arrows).

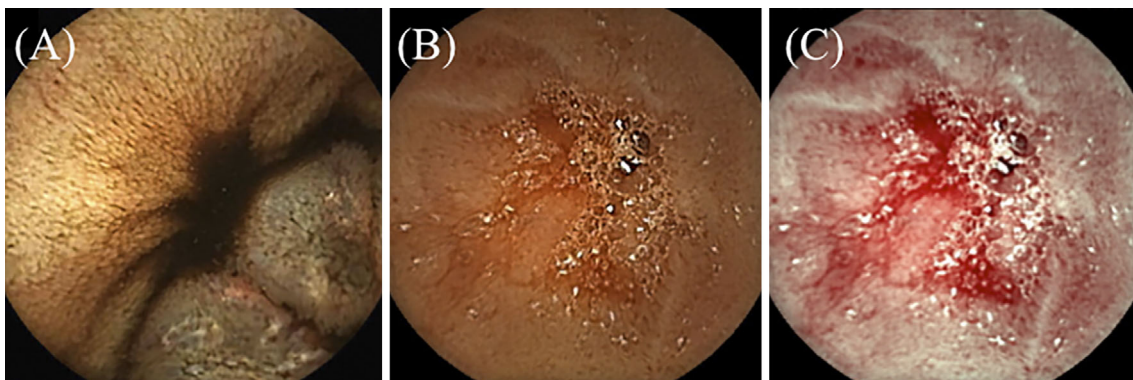


Figure 3. Capsule endoscopy findings showing (A) bluish-purple colored elevation of the intestinal mucosa and (B) fresh blood near the ileal lesion. (C) The blood is emphasized visually by the application of flexible spectral imaging color enhancement (FICE) setting 1.

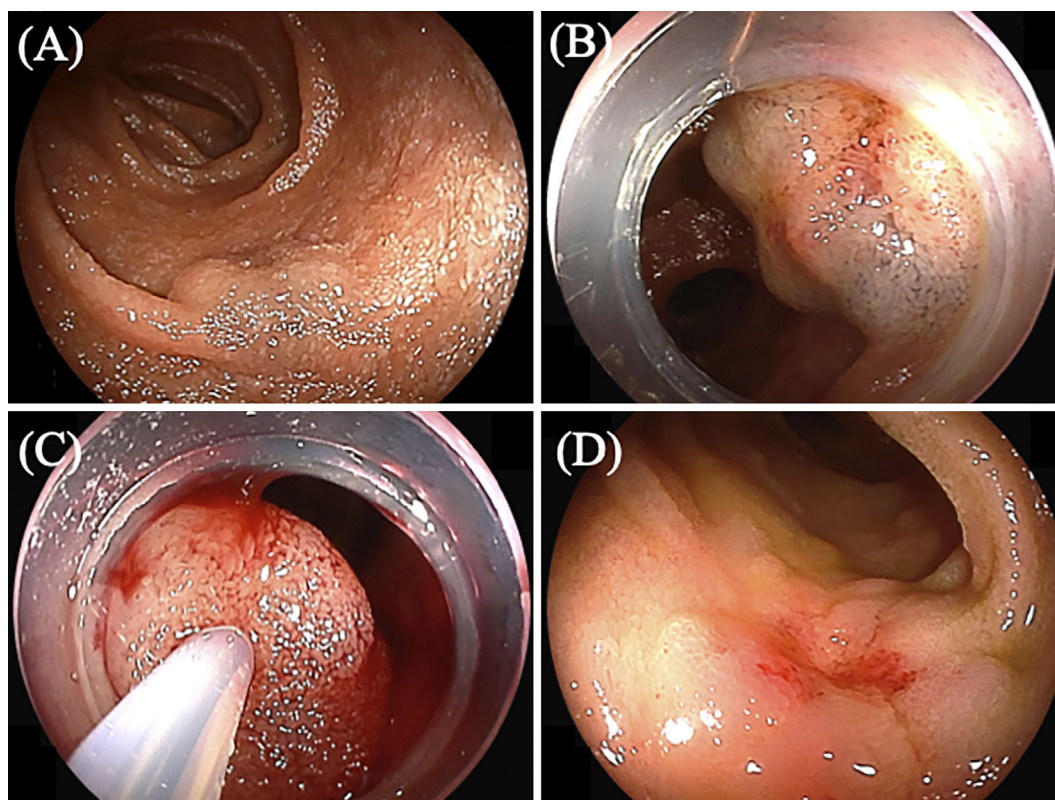


Figure 4. Small bowel hemangiomas, as visualized during double-balloon enteroscopy. (A) Hemangioma in the jejunum. (B) Hemangioma in the ileum with a protrusion over the lesion considered responsible for the hematochezia. (C) The intralesional injection of polidocanol. (D) A reduction in the size of the ileal lesion was observed at 4 months after endoscopic treatment.

verse events, such as fever, abdominal pain, or further hematochezia. She was discharged 3 days after the endoscopic treatment. Follow-up DBE, performed at 4 months after the procedure, showed a remarkable reduction (>50%) in the size of the ileal hemangioma, with scarring at the center of the lesion (Fig. 4D), and demonstrated the clinical efficacy of the endoscopic sclerotherapy procedure using polidocanol.

Discussion

In the present case, blue rubber bleb nevus syndrome (BRBNS) was initially suspected due to the presence of several cutaneous hemangiomas. However, BRBNS had not been diagnosed at the time of admission. Considering that small bowel SMTs in BRBNS patients are mainly known to present as cavernous hemangiomas (10), endoscopic ultrasonography may be omitted in the diagnosis of these lesions. Small bowel hemangiomas are non-epithelial benign tumors composed of proliferating blood vessels and are sometimes encountered as a source of bleeding, along with other vascular small bowel lesions (11-13). CECT is recommended in the early stages of the diagnostic work-up of patients presenting with acute lower gastrointestinal bleeding (14, 15). CECT can provide significant findings regarding the mass, inflammation, and hemodynamics of the lesion. The combination of CECT and CE is clinically useful

for the identification and localization of small bowel lesions. Moreover, the use of CECT in combination with DBE enabled us to exclude small bowel varices from the differential diagnosis, due to the absence of surrounding dilated venous elements and portosystemic shunts (16).

There is no specific consensus regarding the therapeutic indication for small bowel hemangioma. According to a recent case series, treatment is indicated for small bowel hemangiomas with symptoms, including gastrointestinal bleeding or abdominal pain (17). While both open surgical and endoscopic resection of small bowel hemangiomas should be considered as suitable treatment options (3, 4), a simple and conservative therapeutic approach might be required, especially for patients with multiple lesions. Surgical treatment is generally regarded as the last resort (18). There have been dermatological reports on the usefulness and tolerability of direct injection of polidocanol for the treatment of cutaneous hemangiomas (19, 20). Despite limited information being available on the efficacy of endoscopic sclerotherapy for small bowel lesions, our case demonstrated that the treatment successfully reduced the size of the ileal hemangioma by >50% in comparison to the pretreatment size (19). Furthermore, although adverse events, including fever, swelling, and ulceration are reported to occur in 25% of patients treated with polidocanol (19), no such treatment-related events were observed in this case. In order to avoid perforation and arterial aspiration, puncture should be performed

under direct vision, with verification that there is no back-flow of blood; then 0.5 mL of polidocanol should be injected. The color change of the lesion and degree of swelling at the time of injection should also be monitored. The optimal amount of polidocanol for injection has been reported to be 0.2 mL per mm of tumor size (7). In addition to hemangiomas, the intralesional administration of 1% polidocanol has been reported to be safe and effective for the management of vascular malformations, including arteriovenous malformation (21). Polidocanol is a sclerosant that exerts hemostatic effects in hemangiomas by increasing the local intravascular blood pressure and causing associated intestinal edema, inducing early hemostatic thrombosis within small blood vessels, which leads to subsequent thrombus formation due to vascular inflammation (22). Using this unique and a conservative treatment approach, we were able to achieve adequate hemostasis, a reduction in the size of the lesion, and the resolution of hematochezia.

In conclusion, this case demonstrated the clinical efficacy and tolerability of endoscopic sclerotherapy for the treatment of small bowel hemangioma.

The authors state that they have no Conflict of Interest (COI).

Financial Support

The work described herein was solely supported by departmental resources.

References

- Bae SJ, Hwang G, Kang HS, et al. Single cavernous hemangioma of the small bowel diagnosed by using capsule endoscopy in a child with chronic iron-deficiency anemia. *Clin Endosc* **48**: 340-344, 2015.
- Durer C, Durer S, Sharbatji M, Comba IY, Aharoni I, Majeed U. Cavernous hemangioma of the small bowel: a case report and literature review. *Cureus* **10**: e3113, 2018.
- Kanaji S, Nakamura T, Nishi M, et al. Laparoscopic partial resection for hemangioma in the third portion of the duodenum. *World J Gastroenterol* **20**: 12341-12345, 2014.
- Shibuya T, Osada T, Mitomi H, et al. Jejunal capillary hemangioma treated by using double-balloon endoscopy (with video). *Gastrointest Endosc* **72**: 660-661, 2010.
- Lux G, Retterspitz M, Stabenow-Lohbauer U, Langer M, Altendorf-Hofmann A, Bozkurt T. Treatment of bleeding esophageal varices with cyanoacrylate and polidocanol, or polidocanol alone: results of a prospective study in an unselected group of patients with cirrhosis of the liver. *Endoscopy* **29**: 241-246, 1997.
- Takasumi M, Hikiuchi T, Takagi T, et al. Endoscopic therapy for esophageal hematoma with blue rubber bleb nevus syndrome. *World J Gastrointest Endosc* **6**: 630-634, 2014.
- Igawa A, Oka S, Tanaka S, Kuniyama S, Nakano M, Chayama K. Polidocanol injection therapy for small-bowel hemangioma by using double-balloon endoscopy. *Gastrointest Endosc* **84**: 163-167, 2016.
- Ning S, Zhang Y, Zu Z, Mao X, Mao G. Enteroscopic sclerotherapy in blue rubber bleb nevus syndrome. *Pak J Med Sci* **31**: 226-228, 2015.
- Igawa A, Oka S, Tanaka S, et al. Major predictors and management of small-bowel angioectasia. *BMC Gastroenterol* **15**: 108, 2015.
- Gallo SH, McCrave SA. Blue rubber bleb nevus syndrome: gastrointestinal involvement and its endoscopic presentation. *Gastrointest Endosc* **38**: 72-76, 1992.
- Takase N, Fukui K, Tani T, et al. Preoperative detection and localization of small bowel hemangioma: two case reports. *World J Gastroenterol* **23**: 3752-3757, 2017.
- Aoyama T, Fukumoto A, Mukai S, Ueda H, Kimura S, Nagata S. Successful endoscopic treatment of an actively bleeding jejunal Dieulafoy's lesion. *Intern Med* **55**: 1739-1741, 2016.
- Shiotani A, Tarumi K, Honda K, et al. Application of fecal hemoglobin-haptoglobin complex testing for small bowel lesions. *Scand J Gastroenterol* **49**: 539-544, 2014.
- Yamamoto H, Ogata H, Matsumoto T, et al. Clinical practice guideline for enteroscopy. *Dig Endosc* **29**: 519-546, 2017.
- Nakatsu S, Yasuda H, Maehata T, et al. Urgent computed tomography for determining the optimal timing of colonoscopy in patients with acute lower gastrointestinal bleeding. *Intern Med* **54**: 553-558, 2015.
- Aoyama T, Oka S, Aikata H, et al. Major predictors of portal hypertensive enteropathy in patients with liver cirrhosis. *J Gastroenterol Hepatol* **30**: 124-130, 2015.
- Hu PF, Chen H, Wang XH, et al. Small intestinal hemangioma: endoscopic or surgical intervention? A case reports and review of literature. *World J Gastrointest Oncol* **10**: 516-521, 2018.
- Gerson LB, Fidler JL, Cave DR, et al. ACG clinical guideline: diagnosis and management of small bowel bleeding. *Am J Gastroenterol* **110**: 1265-1287, 2015.
- Gao Z, Zhang Y, Li W, Shi C. Effectiveness and safety of polidocanol for the treatment of hemangiomas and vascular malformations: a meta-analysis. *Dermatol Ther*. Forthcoming.
- Chai Y, Zhou Z, Song J, et al. Safety of intralesional injection of lauromacrogol combined with triamcinolone for infantile hemangiomas. *J Dermatol* **46**: 770-776, 2019.
- Jain R, Bandhu S, Sawhney S, Mittal R. Sonographically guided percutaneous sclerosis using 1% polidocanol in the treatment of vascular malformations. *J Clin Ultrasound* **30**: 416-423, 2002.
- Takeuchi T, Narimiya N, Joki M, et al. Experimental study on the effects of local injection of aethoxysklerol for gastric mucosa with special reference to the submucosal arterial plexus. *Gastroenterol Endosc* **33**: 695-704, 1991.

The Internal Medicine is an Open Access journal distributed under the Creative Commons Attribution-NonCommercial-NoDerivatives 4.0 International License. To view the details of this license, please visit (<https://creativecommons.org/licenses/by-nc-nd/4.0/>).