

# Pain mechanisms and management in corneal cross-linking: a review

Emilie Sophie van der Valk Bouman ,<sup>1</sup> Heather Pump ,<sup>2</sup> David Borsook,<sup>3</sup> Boris Severinsky,<sup>4</sup> Robert PL Wisse,<sup>5</sup> Hajirah N Saeed,<sup>6</sup> Eric A Moulton <sup>7</sup>

## To cite:

van der Valk Bouman ES, Pump H, Borsook D, *et al*. Pain mechanisms and management in corneal cross-linking: a review. *BMJ Open Ophthalmology* 2021;**6**:e000878. doi:10.1136/bmjophth-2021-000878

► Additional supplemental material is published online only. To view, please visit the journal online (<http://dx.doi.org/10.1136/bmjophth-2021-000878>).

Received 17 August 2021  
Accepted 7 November 2021

## ABSTRACT

Though corneal collagen cross-linking (CXL) is an increasingly available and effective treatment for keratoconus, few reports have considered its impact on pain-related physiology in depth. This comprehensive narrative review summarises mechanisms underlying pain in CXL and clinical care possibilities, with the goal of future improvement in management of CXL-related pain. Postoperative pain associated with CXL is largely due to primary afferent nerve injury and, to a smaller extent, inflammation. Chronification of pain after CXL has not been reported, even as long-term nerve damage without regeneration following standard CXL treatment is frequently observed. The lack of pain chronification may be due to the minimally invasive nature of the procedure, with its rapidly recovering superficial corneal wound, and to the positive anti-inflammatory changes of the tear film that have been described after CXL. Different CXL approaches have been developed, with the transepithelial epithelial-on technique (epi-on) associated with less postsurgical pain than the gold standard, epithelial-off technique (epi-off). After the first few days, however, the difference in pain scores and need for analgesics between epi-on and epi-off disappear. Patients experience relatively high-intensity pain the first few days post-CXL, and many strategies for acute pain control following CXL have been studied. Currently, no method of pain management is considered superior or universally accepted. Acute pain following CXL is a recognised and clinically significant side effect, but few CXL studies have systematically investigated postoperative pain and its management. This review aims to improve patient pain outcomes following this increasingly common procedure.

## INTRODUCTION

Corneal collagen cross-linking (CXL) is an effective and widely used surgical treatment for keratoconus patients.<sup>1</sup> CXL uses ultraviolet-A (UVA) light and riboflavin as a photosensitizer to induce photochemical damage by releasing oxygen radicals. This leads to cross-linking of the collagen fibres in the corneal stroma, thereby stabilising the cornea. Unlike any other keratoconus treatments, CXL is effective at slowing or halting disease progression with preservation of vision-related and health-related quality of life.<sup>2–4</sup>

Unfortunately, CXL causes acute postsurgical pain to the eye which can be intense even with aggressive pain management, particularly for the first few days.<sup>5,6</sup> This is especially problematic for paediatric and developmentally delayed populations which are increasingly undergoing CXL.<sup>7,8</sup> The size of the corneal epithelial defect only partially contributes to the amount of postoperative pain, which is likely influenced by other unknown factors.<sup>9</sup> Different perioperative and postoperative approaches have been explored to attempt pain reduction after CXL, but no method is universally accepted.<sup>6,10</sup>

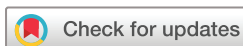A better understanding of the pathophysiological processes of corneal pain in CXL may help develop innovations in acute and postoperative pain management in corneal surgical procedures. This review aims to obtain insight into mechanisms underlying CXL pain and clinical care possibilities, with the goal of improving CXL-related pain management.

## METHODS

Studies cited were obtained through a systematic literature search in PubMed, Embase and the Cochrane Library. Different terms and synonyms for *pain* (*pain\**) and *corneal cross-linking* (*collagen crosslink\**, *collagen cross link\**, *collagen cross-link\**, *corneal plexus*, *CXL*, *C3R*, *KXL*, *CCL*) were used. All articles on the pathophysiology, epidemiology, assessment and/or management of pain in CXL were considered. All articles looking at pain following CXL were summarised ([table 1](#)). Language was limited to English and French articles. Expert consultation was obtained.

## RESULTS

Twenty-one papers on post-CXL pain were identified, with all but one about treating keratoconus (online supplemental table). Pain measurement methods varied, but acute pain within 24 hours of CXL was substantial in the studies and peaked during the first postoperative day and night ([table 2](#)). Pain levels decreased rapidly after the first few days,



© Author(s) (or their employer(s)) 2021. Re-use permitted under CC BY-NC. No commercial re-use. See rights and permissions. Published by BMJ.

For numbered affiliations see end of article.

## Correspondence to

Dr Eric A Moulton; Eric.moulton@childrens.harvard.edu

**Table 1** Summary table of 12 key studies obtained in literature search

Reference	Trial type (if applicable)	CXL method	Patients	Eyes	Lat
5		Epi-off	135 (31F)	178	M
6		Epi-off	52 (15F)	20	M
9		Epi-off	34	68	B
10	Ketorolac 10 mg q8h×3d	Epi-on A	10	NR	NR
	Gabapentin 300mg q8h×3d	Epi-on A	7	NR	NR
	Ketorolac 10 mg q8h×3d	Epi-off A	12	NR	NR
	Gabapentin 300mg q8h×3d	Epi-off A	8	NR	NR
43		Iontophoresis	15 (6F)	NR	M
		Epi-off	23 (3F)	NR	M
47		Epi-on A*	11 (4F)	NR	NR
		Epi-off A	16 (6F)	NR	NR
48		Epi-off	22	22	U
		Epi-off†	22	22	U
50	Cooled 4°C riboflavin 0.1% every 2 min for 10 min	Epi-off A	50	100	B
	Room temperature riboflavin 0.1% every 2 min for 10 min	Epi-off A	48	96	B
52	No RGTA	Epi-off A	30 (13F)	30	U
	RGTA gtt (Cacicol20)	Epi-off A	30 (9F)	30	U
53		Epi-off	18 (4F)	18	B
54		Epi-off	41	30	M
55		Epi-on A	21 (9F)	21	B
		Epi-off A	21 (9F)	21	B

\*With epithelial flap.

†With Epi-Bowman Keratectomy.

B, bilateral; CXL, corneal collagen cross-linking; Lat, laterality; M, mixed; NR, not reported; RGTA, ReGeneraTing Agents; U, unilateral.

and no studies reported persistent clinically significant pain 1 year after CXL. Reported pain was consistently lower with the epithelial-on (epi-on) CXL technique compared with other techniques, including the conventional epithelial-off (epi-off) technique. This difference in pain scores between epi-on and epi-off disappeared after the first few days. Reported pain levels were higher in accelerated versions of CXL. Perioperative and postoperative pharmacological management after CXL differed widely, but typically consisted of local anaesthetic eye drops during the procedure followed postoperatively by a topical steroid and antibiotic. Roughly half of the studies reported the use of oral painkillers, often combined with bandage contact lenses (online supplemental table).

## DISCUSSION

### Pathophysiology

Ocular pain can be categorised as nociceptive, inflammatory and/or neuropathic.<sup>11</sup> Nociceptive eye pain is due to the noxious stimulation of trigeminal afferent nociceptors, which can later cause inflammation. When nerves are damaged, the resulting abnormal population of ion channels results in erratic impulse firing, which can lead to neuropathic pain.<sup>12 13</sup> As defined by the International

Association for the Study of Pain, neuropathic pain is a direct consequence of a lesion or disease affecting the somatosensory system through the peripheral or central nervous system.<sup>14</sup> Post-CXL pain is presumably largely due to primary afferent nerve injury and, to a smaller extent, to inflammation. Corneal afferents reside in the sub-basal nerve plexus underlying the corneal epithelium, well within the area impacted by CXL.

Corneal primary afferents can be divided into three classes based on their ability to detect environmental energy changes.<sup>12</sup> Polymodal nociceptor neurons comprise about 70% of corneal neurons. They produce several quick impulses in response to mechanical, chemical, and thermal stimuli and are mediated by many types of transduction channels that transduce stimuli into nociceptive signals. The second subpopulation of corneal sensory neurons is mechanonociceptor neurons, which comprise 10%–15% of corneal neurons and respond to mechanical stimuli with short phasic nerve impulses. Lastly, 10%–15% are cold thermoreceptor neurons which increase nerve impulse firing rate in response to small temperature reductions.

In response to harmful stimuli, damaged cells release factors that activate immune cells, which in turn release

**Table 2** Postoperative pain ratings in studies with reports

Reference	Pain scale	Pain rated										
		D0	D1	D2	D3	D4	D5	D6	D7	D15	D30	
5	FACES 0–5	2.8±1.7	2.1±1.7	1.4±1.5	0.7±1.1	0.3±0.7	0.1±0.5					
6*	VAS 0–10			6.6±3.9								
9	VRS 0–5	2.2	1.5		1.2				0.3			
10	NRS 0–10		7.7	5.3	3.1	2.1	1.6					
	NRS 0–10		8.4	4.6	2.7	2.3	2.2					
	NRS 0–10		7.7	5.3	3.1	2.1	1.6					
	NRS 0–10		8.4	4.6	2.7	2.3	2.2					
43	VAS 0–10	5.3±2.8	3.6±2.3	2.1±1.9	0.5±0.5	0.9±1.3	0.6±1.1	0.4±0.9	0.3±0.8	0.5±1.1	0.2±0.6	
	VAS 0–10	5.3±3.4	3.9±2.7	2.7±2.7	0.5±0.5	0.9±1.8	0.5±1.2	0.3±0.9	0.2±0.6	0.1±0.4	0±0	
47	NRS 0–4	2.3±0.4	1.4±0.5	0.9±0.4	0.5±0.5							
	NRS 0–4	3.0±0.8	2.1±0.6	1.8±0.6	1.1±0.5							
48	FACES 0–10	4.5±1.5			1.1±0.8							
	FACES 0–10	2.7±1.2			0.4±0.4							
50	VAS 0–10	3.8±3.0	2.8±3.1	2.5±2.4	1.3±1.7	0.5±0.8	0.1±0.3					
	VAS 0–10	8.1±2.2	4.9±3.3	4.0±2.4	2.0±1.7	1.2±1.7	0.5±1.4					
52	VAS 0–10	7.8	6.9	2.3	1.2							
	VAS 0–10	7.5	5.9	4.1	1.9							
53*	0–4	3.3	2.1	0.6	0.2	0.2						
54*	VRS 0–5			2.9±0.6								
55	VRS 0–5		3.7±1.0	2.1	0.6							
	VRS 0–5		3.0±0.6	2	1.3							

\*Ratings averaged across postoperative treatment groups.<sup>6 53 54</sup>

FACES, Wong-Baker FACES pain rating scale; NR, not reported; NRS, Numeric Rating Scale; VAS, Visual Analogue Scale.

inflammatory cytokines. Inflammatory cytokines augment the activity of various transduction channels and sensitise polymodal nociceptors. Mechanonociceptors may also have augmented activity in response to inflammation, but this mechanism is not well understood. Additionally, cold thermoreceptors are desensitised, as inflammatory cytokines inhibit their specific channels.<sup>12 13</sup> Increased sensitivity of nociceptors can lead to ectopic activity resulting in spontaneous pain. Inflammation subsides through the removal of activated inflammatory cells and cell apoptosis. Continued tissue damage may lead to chronic persistent inflammation, wherein cells attract more immune cells and start an inflammatory cascade, resulting in sensitisation that leads to chronic pain.

Furthermore, during corneal surgery procedures, incisions can damage corneal sensory axons without damaging tissue, which would normally incite the inflammatory response. When axon severance occurs, the nerve terminals containing transduction channels undergo Wallerian degeneration and disappear within hours, causing reduced or complete loss of sensitivity to stimuli. Neuronal regeneration then occurs with varying results. Some neurons regain their original ion channel populations, whereas others have an abnormal distribution of

channels, resulting in spontaneous impulse firing and subsequent pain.<sup>12 13</sup>

While peripheral afferents contribute to transduction of noxious stimuli and peripheral neuropathic activity, the experience of pain only manifests after central nervous system processing. Multiple cortical and subcortical brain networks are responsible for processing sensory, affective and cognitive aspects of pain.<sup>15</sup> Some of the brain areas related to processing pain include the insula, anterior cingulate cortex, primary and secondary somatosensory cortex, amygdala, basal ganglia, thalamus and periaqueductal grey. Neuropathic pain can arise from maladaptive neuroplasticity within these central pathways.<sup>16</sup>

#### Animal studies on corneal nociception

Animal models have also been studied to better understand the mechanisms behind acute ocular pain. In murine models, corneal inflammation produced by topical 0.2% benzalkonium chloride induces activation of neurons and the microglial p38 MAPK pathway within the sensory trigeminal complex in the central nervous system.<sup>17</sup> Both chemical and mechanical corneal injury resulted in corneal hypersensitivity, increased spontaneous activity of the ciliary nerve, and faster response of the ciliary nerve to chemical stimulation.<sup>18</sup> Similarly,

a rodent model of photokeratitis using acute UV irradiation demonstrated transient sensitisation of neurons in trigeminal subnucleus caudalis, including enhanced nociceptive behaviour.<sup>19</sup> These changes in intracellular signalling may contribute to the sensitisation of ocular brainstem circuits and therefore ocular pain development downstream.

### Pain-related symptoms and complications

To our knowledge, no cases of chronic pain after CXL have been reported in the literature. A study on CXL outcomes for keratoconus and ectasia patients found no changes in reported pain between pre-CXL and 1-year post-CXL follow-up.<sup>4</sup> Thus, pain following CXL is an acute problem that does not appear to become chronic. However, few studies on CXL consider the delayed onset of persistent pain, which can develop 1–24 months following ocular surgeries such as laser-assisted in situ keratomileusis (LASIK).<sup>20 21</sup> Notably, pain is rarely the focus of reports on CXL outcomes, and methods of reporting pain in CXL literature are widely variable. To make cross-study comparisons more valid, standardisation of experimental and pain metrics should be considered, such as (1) using a Visual Analogue Scale for reporting pain intensity (0–10), (2) collecting reports of pain intensity for maximum and average daily pain, (3) daily tracking of postoperative pain intensity until it resolves, (4) including a natural history group for studies investigating postoperative pain management, (5) tracking and reporting numbers of male and female participants, and (6) consistent long-term follow-up beyond 3 months postoperatively.

Chronic pain can occur following other forms of corneal damage, such as trauma, cataract surgery and excimer laser procedures such as photorefractive keratectomy (PRK) and LASIK. With LASIK, corneal nerves are mechanically severed in the peripheral cornea and rare but severe cases on post-LASIK neuralgia are reported.<sup>12 22–26</sup> As the number of worldwide LASIK procedures performed per year greatly surpass those of CXL,<sup>27 28</sup> further investigation into the lack of chronic pain after CXL is warranted.

Other corneal procedures and pathologies frequently involve long-lasting symptoms of dry eye, including photophobia and foreign body sensation,<sup>12 24 27 29</sup> but are not mentioned in CXL literature. Dry eye is a known side effect of PRK, which involves a very similar ocular surface procedure to CXL, but without the photochemical damage. The lack of these symptoms after CXL is somewhat unexpected. Furthermore, the cornea is one of the most densely innervated structures in the body, yet chronic pain after corneal surgery is not reported at the levels seen after other non-corneal surgeries (such as groin hernia repair or thoracic surgery), in which chronic postsurgical pain is estimated to occur in 10%–50% of patients.<sup>11</sup>

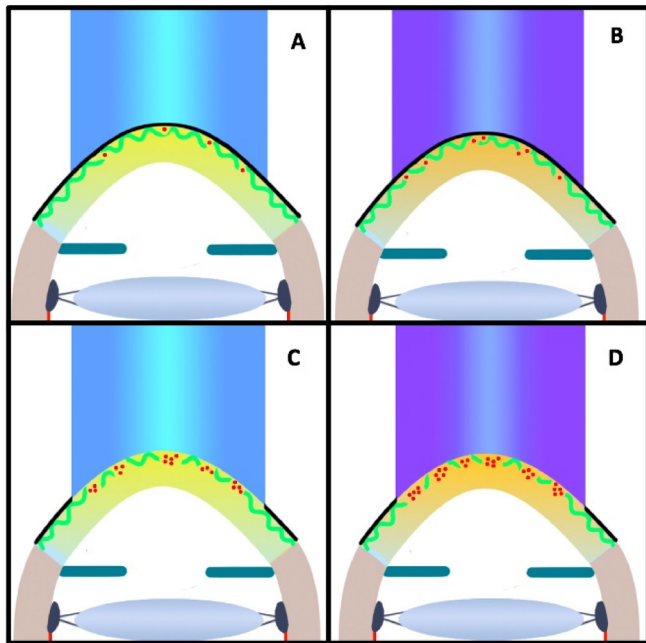
Extensive damage is inflicted on the corneal primary afferent nerves in CXL. In vivo corneal confocal

microscopy (IVCM) studies have shown the subepithelial nerve plexus is significantly reduced and corneal nerves are essentially obliterated immediately after conventional and accelerated CXL.<sup>30 31</sup> Mixed results are reported on corneal nerve recovery after CXL. An IVCM study with 24 patients showed virtually no regeneration of nerve fibres after 6 months,<sup>30</sup> while another with 38 patients showed complete regeneration of the sub-basal nerve plexus by 12 months postoperatively.<sup>32</sup> Another IVCM study with 8 patients showed no detectable sub-basal plexus 1 year postoperatively, but some sparse nerve regrowth after 3 months.<sup>33</sup> Although the evidence is ambiguous, there appears to be difficulty in nerve regeneration after CXL. As nerve damage can lead to neuropathic pain in other procedures and disorders,<sup>12 13 34</sup> it is unclear why chronic pain does not develop after CXL. Moreover, keratoconus is characterised by a pathological sub-basal nerve pattern, which did not change positively after CXL in a 5-year follow-up IVCM study.<sup>35</sup> This discrepancy between clinical outcome and research findings is notable, particularly because the intense postoperative pain suggests that nociceptors remain somewhat functionally intact.

One possible explanation for the lack of chronic pain is that CXL only involves removal of the epithelium. The cross-linking effect reaches the anterior 200–340  $\mu\text{m}$  of the cornea, which impacts the sub-basal nerve plexus and anterior stroma but not deeper structures such as the posterior stroma and endothelium.<sup>31 33</sup> There is also no incisional component. Compared with more invasive corneal procedures, CXL recovery is relatively quick, has fewer complications, and less chance of pain chronification. This suggests that damage to deeper nociceptive afferents may contribute to chronic pain, but damage to the sub-basal nerve plexus does not.

Another possible explanation is that compared with LASIK and PRK, CXL patients undergo the procedure more often at a younger age.<sup>7 8</sup> Communication with young children can introduce potential challenges in obtaining accurate pain reports. Moreover, an older age might be a greater risk factor for development of postsurgical neuropathic pain, where tissue damage in younger patients might recover sooner. Next to age difference, there is a higher prevalence of developmentally delayed patients receiving CXL, which can also present with barriers in accurate communication.

Although corticosteroid-containing eye drops are used in the acute management of inflammation in CXL, the long-term homeostasis and inflammation of the cornea may be due to the changes in tear film quality. There are positive changes in the tear film after CXL treatment, and inflammatory biomarkers decrease.<sup>34</sup> The tear film is essential to corneal wound healing and preventing evaporation of tears,<sup>35 36</sup> so the regenerative role of the tear film may contribute to fast wound healing and the lack of increased dry eye symptoms after CXL. In a study of 30 eyes in 16 patients, CXL had no impact on dry eye syndrome parameters 3 and 6 months postoperatively.<sup>29</sup> Additionally, local inflammation affects the



**Figure 1** Impact of different CXL techniques to the corneal epithelium (black line) and sub-basal nerve plexus (wavy green line). Red dots show the CXL-induced photochemical reaction and toxic effect with the release of free radicals leading to oxidative stress and nerve damage. (A) epi-on; (B) epi-on accelerated; (C) epi-off; (D) epi-off accelerated. Illustration by Emilie S. van der Valk Bouman. CXL, corneal collagen cross-linking.

development of (chronic) ocular pain,<sup>12 13</sup> therefore, the anti-inflammatory effects of CXL on the tear film could preclude the development of chronic pain.

Another possibility for chronic neuropathic pain not to develop is because certain immune cells cannot access the cornea. Perhaps the cornea as an immune-privileged site reduces the immigration of specific immune factors related to pain, thus reducing the likelihood that neuropathic pain is established.<sup>37 38</sup> However, note that following refractive surgery, the cornea can feature chronic inflammatory changes and microneuromas with neuropathic corneal pain.<sup>39</sup>

### Different CXL approaches

Many CXL techniques have been developed (figure 1). The difference in pain between the conventional epi-off and the epi-on technique has been studied extensively, and there has been much debate over which technique is preferable.

In 2003, the Dresden protocol established epi-off CXL as the gold standard, which was then approved by the US Food and Drug Administration in 2016.<sup>40</sup> With the epi-off technique, the central epithelium is removed to get faster and deeper absorption of the riboflavin into the corneal stroma. With epi-on, the epithelial layer is left intact, thereby avoiding severance of the sub-basal nerve plexus, making the approach less invasive and time consuming.

Several studies have shown that patients experience less pain after epi-on, both in intensity and duration (online supplemental table, online supplemental material). This difference can be explained by the absence of de-epithelialisation and damage to corneal nerves. Other advantages of epi-on are faster postoperative recovery and less risk of complications such as infection and corneal haze.<sup>41</sup> However, the significant advantage of epi-off is deeper and more effective therapy due to enhanced riboflavin and UV absorption with lower risk of keratoconus progression. In a systematic review in 2017 comparing epi-off to epi-on, epi-off more effectively halted the progression of keratoconus.<sup>42</sup> In a study that measured postoperative CXL pain after 30 days, pain in epi-off compared with epi-on was not significantly different.<sup>43</sup> It may be concluded that the pain difference disappears after the first several postoperative days.

Different CXL approaches have unique impacts on the corneal layers (figure 1). Although epi-on CXL does not cause direct mechanical damage to the sub-basal nerve plexus, CXL-induced release of free radicals does lead to oxidative stress and nerve damage.<sup>44</sup> On the other hand, epi-off directly severs nociceptors in the plexus in addition to the photochemical damage. Accelerated versions of epi-off and epi-on CXL use higher intensity UV light and riboflavin concentrations, which save time while producing similar results.<sup>45 46</sup> These accelerated versions do seem to result in greater pain levels, presumably due to the higher impact of the procedure to the cornea (table 2, figure 1).

Studies on other CXL methods showed significantly lower pain levels with the use of Epi-Bowman keratectomy and a technique with a subepithelial flap.<sup>47 48</sup> One study showed a significant effect of ReGeneraTing Agents on pain levels and the number of oral analgesics taken the first few days after epi-off CXL.<sup>49</sup> Another study showed significant pain reduction with corneal cooling using a cold (4°C) riboflavin solution.<sup>50</sup> Further studies must be done to validate these experimental therapies.

### Pain management strategies

Patients experience relatively high-intensity pain post-CXL, particularly in the (accelerated) epi-off technique (table 2). Many strategies have been studied to determine the most effective method in alleviating postoperative pain, with varying degrees of success. Typical pharmacological management consists of local anaesthetic eye-drops during the procedure followed postoperatively by a topical steroid to quell inflammation and antibiotic eye-drops. A variety of oral painkillers have been used as rescue medication, such as paracetamol, non-steroidal anti-inflammatory oral drugs (NSAIDs), gabapentins, and oxycontin, but the best doses and medications have not been systematically evaluated in the literature (online supplemental table). Highly gas-permeable bandage contact lenses combined with frequent instillation of preservative-free lubricants increases the level of available oxygen to the corneal

surface and promotes epithelialisation. However, the use of bandage contact lenses does not significantly alter pain scores when compared with other postoperative regimens, including occlusive patching or ointment.<sup>6</sup>

Gabapentin and NSAIDs are used following different (corneal refractive) surgery procedures and are potential therapeutics for CXL-related pain.<sup>10</sup> The NSAID ketorolac reduces inflammation, whereas gabapentin works as an inhibitory neurotransmitter analogue. Gabapentin and ketorolac have comparable efficacy in post-CXL pain management for both epi-off and epi-on techniques. However, the extent of pain relief offered by these medications was not assessed, as this study did not include a natural history group without oral analgesics.

Pain management is most needed and could provide the most benefit not when the perioperative local anaesthesia wears off, but during the middle of the first postoperative night. Extended release of low-dose local anaesthesia to the injured cornea overnight, perhaps in the form of a bandage contact lens drug delivery system,<sup>51</sup> may be a practical solution.

Typically, CXL is performed under topical anaesthetics only (online supplemental table, online supplemental material), but general anaesthetics are occasionally used in parallel with uncooperative patients.<sup>36 40–42</sup> Though beyond the scope of this paper, the use of general anaesthetics is worth future study considering that CXL is increasingly common for paediatric and developmentally delayed populations.

## CONCLUSIONS

Acute postsurgical pain is significant and predictable in the days following CXL and fortunately does not appear to transition into chronic pain. The trauma inflicted on the corneal afferents produces nerve damage that is detectable for months but with no apparent impact on pain or dry-eye symptoms beyond the initial insult. Accordingly, pain management strategies have focused specifically on the perioperative and immediate postoperative recovery. Conventional epi-off procedures produce more acute pain than epi-on, but pain diminishes several days after surgery in either approach. Despite the time saved by accelerated CXL, it generally results in greater pain with both epi-on and epi-off approaches.

Currently, no method of pain control following CXL is universally accepted, and there are no evidence-based guidelines for post-CXL care. More research with a translational approach should be conducted to obtain practical recommendations for CXL pain management. First of all, prospective comparative studies with standardised measurements of pain must be conducted to further study postoperative pain control in CXL. Future research should investigate promising therapies and new strategies for acute pain management in CXL, including cool CXL.<sup>50</sup> These findings may also apply to other surgeries that impact the cornea or shed light on chronic pain. Investigations into why acute postsurgical pain does not become chronic in CXL may aid in the

development of preventative and therapeutic strategies for chronic pain disorders. Future studies should directly compare the various epithelium removal techniques and their relationship to acute and chronic pain.

The primary goal of CXL is to manage keratoconus. In this review, we have highlighted mechanisms underlying pain in CXL as well as clinical care possibilities to improve management of CXL-related pain. Although current reports do not indicate chronic pain following CXL, managing the relatively acute postoperative pain is important, especially considering the growing number of children undergoing CXL. The absence of evidence of pain chronification does not prove its absence; given the extent of acute pain and corneal restructuring, physicians who manage chronic pain patients should consider CXL as a possible, though unproven, factor. We hope this review encourages clinicians and researchers to fine-tune treatment and postoperative care to provide the best CXL pain management.

## Author affiliations

<sup>1</sup>Department of Ophthalmology, University Medical Center, Utrecht, The Netherlands

<sup>2</sup>Boston University, Brighton, Massachusetts, USA

<sup>3</sup>Brain and Eye Pain Imaging Lab, Pain and Affective Neuroscience Center, Department of Anesthesiology, Critical Care and Pain Medicine, Boston Childrens Hospital, Harvard Medical School, Boston, Massachusetts, USA

<sup>4</sup>Department of Ophthalmology, Emory Eye Center, Atlanta, Georgia, USA

<sup>5</sup>Department of Ophthalmology, University Medical Center, Utrecht, The Netherlands

<sup>6</sup>Department of Ophthalmology, Massachusetts Eye and Ear Infirmary, Harvard Medical School, Boston, Massachusetts, USA

<sup>7</sup>Brain and Eye Pain Imaging Lab, Pain and Affective Neuroscience Center, Department of Anesthesiology, Critical Care and Pain Medicine; Department of Ophthalmology, Boston Childrens Hospital, Harvard Medical School, Boston, Massachusetts, USA

**Acknowledgements** The authors would like to acknowledge science writer Jane Patrick for her editorial assistance, and Dr Leyla Yavuz Saricay for her thoughtful input on the manuscript during the editorial review process.

**Contributors** ESvdVB, HP and EM performed the literature search and wrote the initial draft of the manuscript. DB, BS, RW and HNS contributed to critical input and refining the manuscript. EM contributed to the idea for the article, and is the guarantor for the article.

**Funding** Financial support for this project was provided by The Cathedral Fund awarded to EM.

**Competing interests** None declared.

**Patient consent for publication** Not applicable.

**Provenance and peer review** Not commissioned; externally peer reviewed.

**Data availability statement** No data are available. Not applicable.

**Supplemental material** This content has been supplied by the author(s). It has not been vetted by BMJ Publishing Group Limited (BMJ) and may not have been peer-reviewed. Any opinions or recommendations discussed are solely those of the author(s) and are not endorsed by BMJ. BMJ disclaims all liability and responsibility arising from any reliance placed on the content. Where the content includes any translated material, BMJ does not warrant the accuracy and reliability of the translations (including but not limited to local regulations, clinical guidelines, terminology, drug names and drug dosages), and is not responsible for any error and/or omissions arising from translation and adaptation or otherwise.

**Open access** This is an open access article distributed in accordance with the Creative Commons Attribution Non Commercial (CC BY-NC 4.0) license, which permits others to distribute, remix, adapt, build upon this work non-commercially, and license their derivative works on different terms, provided the original work is

properly cited, appropriate credit is given, any changes made indicated, and the use is non-commercial. See: <http://creativecommons.org/licenses/by-nc/4.0/>.

#### ORCID iDs

Emilie Sophie van der Valk Bouman <http://orcid.org/0000-0001-7807-4390>

Heather Pump <http://orcid.org/0000-0003-2448-9712>

Eric A Moulton <http://orcid.org/0000-0002-7959-8441>

#### REFERENCES

- Pron G, Ieraci L, Kaulback K, et al. Collagen cross-linking using riboflavin and ultraviolet-A for corneal thinning disorders: an evidence-based analysis. *Ont Health Technol Assess Ser* 2011;11:1–89.
- Godefrooij DA, de Wit GA, Mangen MJ, et al. Comment on 'Cost effectiveness of collagen crosslinking for progressive keratoconus in the UK NHS'. *Eye* 2016;30:1150–2.
- Sahebjada S, Fenwick EK, Xie J, et al. Impact of keratoconus in the better eye and the worse eye on vision-related quality of life. *Invest Ophthalmol Vis Sci* 2014;55:412–6.
- Brooks NO, Greenstein S, Fry K, et al. Patient subjective visual function after corneal collagen crosslinking for keratoconus and corneal ectasia. *J Cataract Refract Surg* 2012;38:615–9.
- Ghanem VC, Ghanem RC, de Oliveira R. Postoperative pain after corneal collagen cross-linking. *Cornea* 2013;32:20–4.
- Soeters N, Hendriks I, Godefrooij DA, et al. Prospective 3-arm study on pain and epithelial healing after corneal crosslinking. *J Cataract Refract Surg* 2020;46:72–7.
- Henriquez MA, Villegas S, Rincon M, et al. Long-Term efficacy and safety after corneal collagen crosslinking in pediatric patients: three-year follow-up. *Eur J Ophthalmol* 2018;28:415–8.
- Krader CG. CXL imperative in treatment of pediatric keratoconus. *ophthalmology times*, 2020. Available: <https://www.ophthalmologytimes.com/view/cxl-imperative-treatment-pediatric-keratoconus> [Accessed 8 Dec 2020].
- Zarei-Ghanavati S, Jafarpour S, Rodyn-Majd A, et al. Evaluation of early postoperative ocular pain after photorefractive keratectomy and corneal crosslinking. *J Cataract Refract Surg* 2018;44:566–70.
- Serna-Ojeda JC, Santana-Cruz O, Quiroz-Casian N, et al. Pain management in corneal collagen crosslinking for keratoconus: a comparative case series. *J Ocul Pharmacol Ther* 2019;35:325–30.
- Kehlet H, Jensen TS, Woolf CJ. Persistent postsurgical pain: risk factors and prevention. *Lancet* 2006;367:1618–25.
- Belmonte C, Pain BC. Pain, dryness, and itch sensations in eye surface disorders are defined by a balance between inflammation and sensory nerve injury. *Cornea* 2019;38 Suppl 1:S11–24.
- Belmonte C, Acosta MC, Merayo-Llones J, et al. What causes eye pain? *Curr Ophthalmol Rep* 2015;3:111–21.
- Jensen TS, Baron R, Haanpää M, et al. A new definition of neuropathic pain. *Pain* 2011;152:2204–5.
- Apkarian AV, Bushnell MC, Treede R-D, et al. Human brain mechanisms of pain perception and regulation in health and disease. *Eur J Pain* 2005;9:463–84.
- Zheng W, Woo C-W, Yao Z, et al. Pain-Evoked reorganization in functional brain networks. *Cereb Cortex* 2020;30:2804–22.
- Launay P-S, Reboussin E, Liang H, et al. Ocular inflammation induces trigeminal pain, peripheral and central neuroinflammatory mechanisms. *Neurobiol Dis* 2016;88:16–28.
- Joubert F, Acosta MDC, Gallar J, et al. Effects of corneal injury on ciliary nerve fibre activity and corneal nociception in mice: a behavioural and electrophysiological study. *Eur J Pain* 2019;23:589–602.
- Tashiro A, Okamoto K, Chang Z, et al. Behavioral and neurophysiological correlates of nociception in an animal model of photokeratitis. *Neuroscience* 2010;169:455–62.
- Moshirfar M, Bhavsar UM, Durnford KM, et al. Neuropathic corneal pain following LASIK surgery: a retrospective case series. *Ophthalmol Ther* 2021;10:677–89.
- Baksh BS, Morkin M, Felix E, et al. Ocular pain symptoms in individuals with and without a history of refractive surgery: results from a cross-sectional survey. *Cornea* 2021;00:1–8.
- Rosenthal P, Borsook D, Moulton EA. Oculofacial pain: corneal nerve damage leading to pain beyond the eye. *Invest Ophthalmol Vis Sci* 2016;57:5285–7.
- Levitt AE, Galor A, Weiss JS, et al. Chronic dry eye symptoms after LASIK: parallels and lessons to be learned from other persistent post-operative pain disorders. *Mol Pain* 2015;11:21.
- Jacobs DS. Diagnosis and treatment of ocular pain: the ophthalmologist's perspective. *Curr Ophthalmol Rep* 2017;5:271–5.
- Bethke W. When LASIK Pain Won't Go Away. Review of Ophthalmology, 2013. Available: <https://www.reviewofophthalmology.com/article/when-lasik-pain-wonand8217t-go-away-42792> [Accessed 8 Dec 2020].
- Theophanous C, Jacobs DS, Hamrah P. Corneal neuralgia after LASIK. *Optom Vis Sci* 2015;92:e233–40.
- Diel RJ, Mehra D, Kardon R, et al. Photophobia: shared pathophysiology underlying dry eye disease, migraine and traumatic brain injury leading to central neuroplasticity of the trigeminothalamic pathway. *Br J Ophthalmol* 2021;105:751–60.
- Touboul D, Efron N, Smadja D, et al. Corneal confocal microscopy following conventional, transepithelial, and accelerated corneal collagen cross-linking procedures for keratoconus. *J Refract Surg* 2012;28:769–76.
- Taneri S, Oehler S, Asimellis G, et al. Influence of corneal cross-linking for keratoconus on several objective parameters of dry eye. *J Refract Surg* 2013;29:612–6.
- Parissi M, Randjelovic S, Poletti E, et al. Corneal nerve regeneration after collagen cross-linking treatment of keratoconus: a 5-year longitudinal study. *JAMA Ophthalmol* 2016;134:70–8.
- Kohlhaas M, Spoerl E, Schilde T, et al. Biomechanical evidence of the distribution of cross-links in corneas treated with riboflavin and ultraviolet a light. *J Cataract Refract Surg* 2006;32:279–83.
- Mazzotta C, Traversi C, Baiocchi S, et al. Corneal healing after riboflavin ultraviolet-A collagen cross-linking determined by confocal laser scanning microscopy in vivo: early and late modifications. *Am J Ophthalmol* 2008;146:527–33.
- Mazzotta C, Hafezi F, Kymionis G, et al. In vivo confocal microscopy after corneal collagen crosslinking. *Ocul Surf* 2015;13:298–314.
- Recalde JL, Duran JA, Rodriguez-Agirretxe I, et al. Changes in tear biomarker levels in keratoconus after corneal collagen crosslinking. *Mol Vis* 2019;25:12–21.
- Subasinghe SK, Ogbuehi KC, Dias GJ. Current perspectives on corneal collagen crosslinking (CXL). *Graefes Arch Clin Exp Ophthalmol* 2018;256:1363–84.
- Bukowiecki A, Hos D, Cursiefen C, et al. Wound-Healing studies in cornea and skin: parallels, differences and opportunities. *Int J Mol Sci* 2017;18. doi:10.3390/ijms18061257. [Epub ahead of print: 12 Jun 2017].
- Keino H, Horie S, Sugita S. Immune privilege and eye-derived T-regulatory cells. *J Immunol Res* 2018;2018:1679197.
- Marchand F, Perretti M, McMahon SB. Role of the immune system in chronic pain. *Nat Rev Neurosci* 2005;6:521–32.
- Moein H-R, Akhlaq A, Dieckmann G, et al. Visualization of microneuromas by using in vivo confocal microscopy: an objective biomarker for the diagnosis of neuropathic corneal pain? *Ocul Surf* 2020;18:651–6.
- Stephenson M. Corneal collagen crosslinking: is epi-off or epi-on best for patients? EyeWorld, 2017. Available: <https://www.eyeworld.org/corneal-collagen-crosslinking-epi-or-epi-best-patients> [Accessed 8 Dec 2020].
- Magli A, Forte R, Tortori A, et al. Epithelium-off corneal collagen cross-linking versus transepithelial cross-linking for pediatric keratoconus. *Cornea* 2013;32:597–601.
- Liu Y, Liu Y, Zhang Y-N, et al. Systematic review and meta-analysis comparing modified cross-linking and standard cross-linking for progressive keratoconus. *Int J Ophthalmol* 2017;10:1419–29.
- Maurin C, Daniel E, Bonnin N, et al. [Assessment of postoperative pain after corneal collagen cross-linking by iontophoresis vs the rapid epithelium-off technique in progressive keratoconus patients]. *J Fr Ophthalmol* 2015;38:904–11.
- Jordan C, Patel DV, Abeysekera N, et al. In vivo confocal microscopy analyses of corneal microstructural changes in a prospective study of collagen cross-linking in keratoconus. *Ophthalmology* 2014;121:469–74.
- Jiang Y, Yang S, Li Y, et al. Accelerated versus conventional corneal collagen cross-linking in the treatment of keratoconus: a meta-analysis and review of the literature. *Interdiscip Sci* 2019;11:282–6.
- Sadoughi MM, Einollahi B, Baradaran-Rafii A, et al. Accelerated versus conventional corneal collagen cross-linking in patients with keratoconus: an inpatient comparative study. *Int Ophthalmol* 2018;38:67–74.
- Li S, Xie H, Xu M, et al. Comparison of pain after subepithelial versus conventional accelerated corneal collagen cross-linking for keratoconus. *Int Ophthalmol* 2019;39:1249–54.
- Shetty R, Nagaraja H, Pahuja NK, et al. Safety and efficacy of Epi-Bowman keratectomy in photorefractive keratectomy and corneal collagen cross-linking: a pilot study. *Curr Eye Res* 2016;41:623–9.
- Aixinjueluo W, Usui T, Miyai T, et al. Accelerated transepithelial corneal cross-linking for progressive keratoconus: a prospective study of 12 months. *Br J Ophthalmol* 2017;101:1244–9.



- 50 Toro-Giraldo L, Morales Flores N, Santana-Cruz O. Cool cross-linking: riboflavin at 4°C for pain management after cross-linking for patients with keratoconus, a randomized clinical trial. *Cornea* 2021;40:e19.
- 51 Santamaria CM, Woodruff A, Yang R, *et al.* Drug delivery systems for prolonged duration local anesthesia. *Mater Today* 2017;20:22–31.
- 52 Gumus K, Guerra MG, de Melo Marques SH, *et al.* A new matrix therapy agent for faster corneal healing and less ocular discomfort following Epi-off accelerated corneal cross-linking in progressive keratoconus. *J Refract Surg* 2017;33:163–70.
- 53 Kymionis GD, Liakopoulos DA, Grentzelos MA, *et al.* Effect of the Regenerative Agent Poly(Carboxymethylglucose Sulfate) on Corneal Wound Healing After Corneal Cross-Linking for Keratoconus. *Cornea* 2015;34:928–31.
- 54 Sameen M, Khan MS, Habib A, *et al.* Comparison of analgesic effect of preoperative topical diclofenac versus ketorolac on postoperative pain after corneal collagen cross linkage. *Pak J Med Sci* 2017;33:1101–5.
- 55 Yuksel E, Cubuk MO, Yalcin NG. Accelerated epithelium-on or accelerated epithelium-off corneal collagen cross-linking: contralateral comparison study. *Taiwan J Ophthalmol* 2020;10:37–44.