

Received: 2019.12.15

Accepted: 2020.05.12

Available online: 2020.07.03

Published: 2020.09.05

# Diagnostic Value of Magnetic Resonance (MR) Combined with Computed Tomography (CT) in Patients with Stress Injury of Femoral Neck

Authors' Contribution:

Study Design A

Data Collection B

Statistical Analysis C

Data Interpretation D

Manuscript Preparation E

Literature Search F

Funds Collection G

ABC **Jing Chen**  
DE **Shaowei Zheng**  
DE **Qingwei Song**  
DFG **Ailian Liu**

Department of Radiology, The First Affiliated Hospital of Dalian Medical University, Dalian, Liaoning, P.R. China

**Corresponding Author:** Jing Chen, e-mail: jingchendr@163.com

**Source of support:** Departmental sources

**Background:** The purpose of this research was to study and analyze the diagnostic value of magnetic resonance (MR) combined with computed tomography (CT) in patients with stress injury of the femoral neck.

**Material/Methods:** The 58 patients with stress injury of the femoral neck who were treated in our hospital from July 2017 until July 2019 were selected as subjects on the basis of clinical pathology and surgery, MR and CT examination, and related imaging data retrospectively analyzed. We observed all patients using different diagnostic methods to determine the value of diagnosis and treatment of disease.

**Results:** The patients selected for this study were confirmed by clinicopathology and surgery; the positive rate of CT diagnosis was 65.5%, the positive rate of MR diagnosis was 74.1%, and the positive rate of combined diagnosis was 91.4%. Through statistical analysis, CT and MR showed no significant difference in the detection of stress lesions in different femoral necks, indicating no statistical significance ( $P > 0.05$ ). However, the amount of stress lesions detected in the combined diagnosis was higher than that in the two separate detection methods, with statistically significant difference ( $P < 0.05$ ). The grading of stress lesions in all patients examined through MR showed that there was no proportion of grade 0, whereas grades 3–4 were the highest, accounting for 20.7% and 32.8% respectively. In CT scanning of all patients, fracture lines were observed in 35 patients, of which 25 were transparent lines and 10 were strip dense shadows; Periosteal reaction was observed in 34 patients, of whom umbilical concave was observed in 18 patients. Osteoporosis was observed in 30 patients, and the lesion showed a zone of reduced density in the cortical bone, with a stripelike shape and unclear boundary. The density tended to increase in the cavum medullare of 32 patients, with porosis being visible. Compared with CT diagnosis, the accuracy, sensitivity, and specificity of MR detection were not significantly different ( $P > 0.05$ ). The accuracy, sensitivity, and specificity of the combined detection were higher than that of CT and MR detection alone, with statistically significant differences between groups ( $P < 0.05$ ).

**Conclusions:** The application of MR combined with CT in early clinical diagnosis and treatment of femoral neck stress injury will improve the diagnosis rate; the imaging signal is obvious, which is helpful to further evaluate the severity of disease.

**MeSH Keywords:** **Dental Stress Analysis • Stress Disorders, Traumatic, Acute • Urinary Incontinence, Stress**

**Full-text PDF:** <https://www.medscimonit.com/abstract/index/idArt/922170>

 2636

 5

 5

 18



## Background

Stress injury of the femoral neck is relatively rare in clinical practice, and its occurrence is mainly caused by continuous repetition of a single load lower than that causing fracture [1]. Featured by accumulation and subtleness and difficulty to diagnose in the early stage, it is easy to misdiagnose as tumor lesions or osteomyelitis. If the disease cannot be identified in a timely and effective manner, it may evolve into a high-level injury, that is, the stress fracture [2], which can affect patients' physical and mental health and daily life in a serious way. In recent years, computed tomography (CT), magnetic resonance (MR), and other imaging technologies have been applied widely in a variety of diseases. Compared with previous X-ray plain films, missed diagnoses and misdiagnoses have been reduced, and clearer images can be obtained, especially in the detection [3] of injuries in joints, cartilage, and surrounding soft tissues. In view of this, an in-depth discussion and analysis will be made on the diagnosis and treatment value of MR combined with CT for patients with femoral neck stress injury in this study.

## Material and Methods

### General data

The 58 patients with stress injury of the femoral neck who were treated in our hospital from July 2017 until July 2019 were selected as the subjects, and all of them were confirmed through clinical pathology and surgery. There were 35 male patients and 23 female patients, ages 20–52 years, with an average age of  $36.0 \pm 16.0$  years. The disease course was 1–5 weeks, with an average course of  $4.5 \pm 1.5$  weeks. Injury positions: 29 patients on the right side, 24 patients on the left side, and 5 patients on both sides; causes of injuries: 23 patients were injured because of difficult movements in training, 20 patients were injured because of sudden falls, and 15 patients were injured because of unknown reasons. The imaging data of MR and CT were analyzed retrospectively. All patients and family members participating in this study gave informed consent and were approved by the Ethics Committee of our hospital.

### Inclusion criteria

These included: (1) all patients were consistent with the assessment criteria for stress injury of the femoral neck in the *Guidelines for Diagnosis and Treatment of Adult Femoral Neck Fractures* [4]; (2) no previous history of femoral neck injury or fracture; (3) informed consent signed by patients or family members.

**Table 1.** Analysis table of diagnostic test results.

| Diagnostic test | Gold standard |                |       |
|-----------------|---------------|----------------|-------|
|                 | Sick          | Free from sick | Total |
| Sick            | a             | b              | a+b   |
| Free from sick  | c             | d              | c+d   |
| Total           | a+c           | b+d            | n     |

### Methods

All patients were diagnosed with MR and CT and were routinely consulted after admission to check whether there was congestion or swelling in the position of the stress injury, and if there was any, they should be cleaned, disinfected, and treated with detumescence in time. MR detection method: use Signa HD 1.5TMR diagnostic instrument produced by GE Company; help patients lie with legs straight; package-type surface coil for sagittal, transverse, and coronal scanning; thickness of scanning layer: 3 mm with 0.3 mm; matrix: 256×256, field of view: 180 mm; spin-echo (SE) T1 weighted image (WI) (repetition time [TR] 400–450 ms, echo time [TE] 12 ms), fast SE (FSE) T2W1 (TR 3200 ms, TE 90 ms), fat suppression FSE double echo (TR 3500 ms, TE ms 16/96 ms). CT detection method: GE-Revolution 128-row spiral CT scanner was selected, the contrast agent iopropiramine was given, scanning parameters were set as: screw pitch 0.5: 1.0; layer spacing: 1.25 mm; layer thickness: 1.25 mm; and bed inlet speed 20.5 mm/s. We helped patients lie down, determined the needle point on the vein of the injured lower limb lateral femoral neck, disinfected the skin, placed a trocar to connect the syringe, and injected 50 mL of mixed ultravist solution and normal saline. The injection rate was 3.0 mL/s with a duration 20 to 25 s. We conducted Smart prep scanning when the femoral artery reached the peak, and applied a time–density curve line for reconstruction of curved/plane surface and multiplanar surface. Two imaging physicians with abundant experience in image reading were selected to participate in the video reading upon fulfillment of diagnosis, and the results were obtained on the basis of unified opinions.

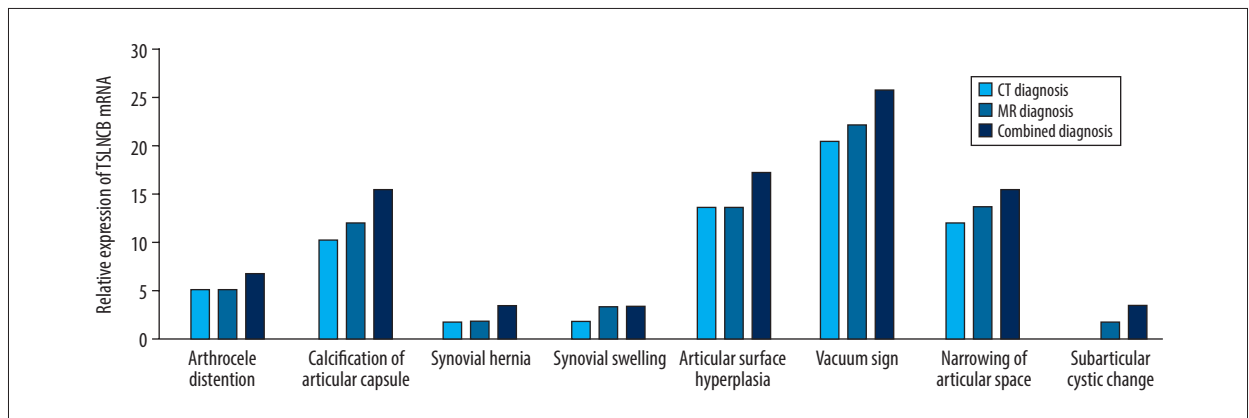
### Evaluation criteria

The accuracy, sensitivity, and specificity of different diagnostic modes for detection of stress injury in the femoral neck were compared, and the clinicopathological and surgical results were taken as the gold standard. With reference to Table 1, accuracy ( $\alpha$ ) indicates the degree to which the observed value of the diagnostic test conforms to the gold standard, and reflects the ability to correctly diagnose patients and nonpatients, i.e.,  $\alpha = (a+d)/n$ . Sensitivity (Se) is also known as the true positive rate, which is the probability of actual disease and

**Table 2.** Detection of stress lesions of femoral neck in different diagnostic methods (% , n=58).

| Diagnostic Mode    | Arthrocele distention | Calcification of articular capsule | Synovial hernia | Synovial swelling | Articular surface hyperplasia | Vacuum sign | Narrowing of articular space | Subarticular cystic change |
|--------------------|-----------------------|------------------------------------|-----------------|-------------------|-------------------------------|-------------|------------------------------|----------------------------|
| CT                 | 3 (5.2)               | 6 (10.3)                           | 1 (1.7)         | 1 (1.7)           | 8 (13.8)                      | 12 (20.7)   | 7 (12.1)                     | 0 (0.0)                    |
| MR                 | 3 (5.2)               | 7 (12.1)                           | 1 (1.7)         | 2 (3.5)           | 8 (13.8)                      | 13 (22.4)   | 8 (13.8)                     | 1 (1.7)                    |
| Combined Diagnosis | 4 (6.9)               | 9 (15.5)                           | 2 (3.5)         | 2 (3.5)           | 10 (17.2)                     | 15 (25.9)   | 9 (15.5)                     | 2 (3.5)                    |

Compared with CT, MR  $P>0.05$ , combined diagnosis  $P<0.05$ ; Compared with MR, combined diagnosis  $P<0.05$ .



**Figure 1.** Detection of stress lesion of femoral neck by different diagnostic methods.

being diagnosed with a disease by a diagnostic test, reflecting the ability to detect patients (the greater the value, the better):  $Se=a/(a+c)$ . Specificity (Sp) is also known as the true negative rate, which is the probability of actually having no disease and being diagnosed as having no disease by a diagnostic test, reflecting the ability to identify nonpatients (the greater the value, the better):  $Sp=d/(b+d)$ .

The detection rates of stress lesions in the femoral neck through different diagnostic methods were compared. The lesions included joint capsule swelling, joint capsule calcification, synovial swelling, synovial hernia, articular surface hyperplasia, joint space narrowing, subarticular capsule degeneration, and vacuum sign.

The grading scale of stress injury in all patients through MR examination was as follows: grade 0 indicated normal. If fat inhibited T2W1 and short-tau inversion recovery, only slight symptoms of periosteum edema were found, indicating grade 1; if fat inhibited T2W1 in the test, increased signals of bone marrow and periosteum edema could be seen, whereas T1W1 showed a slight difference with normal red bone marrow, indicating grade 2; extensive bone marrow edema and periosteum in both T2W1 and T1W1 indicated grade 3; if both MR and CT showed clear bone injury line, it was a real stress injury, indicating grade 4 [5,6].

The subjects underwent CT scanning, and the proportion of positive patients was confirmed as fracture line, periosteum reaction, osteoporosis, and callus formation.

### Statistical methods

The observation data obtained in this study were included in SPSS20.0 software for statistics and analysis. The counting data were expressed in percent (%) and examined with  $\chi^2$ .  $P<0.05$  showed a statistically significant difference.

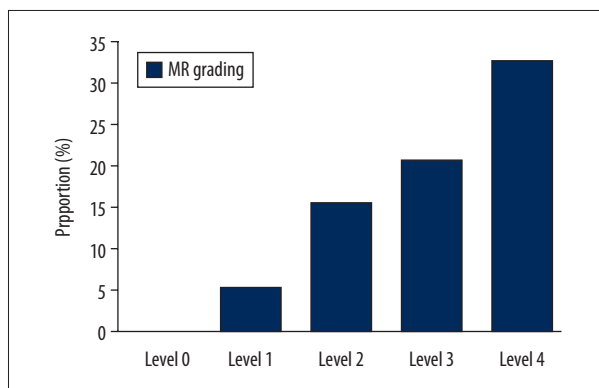
## Results

### Detection of stress lesions of femoral neck with different diagnostic methods

All the patients selected for this study were confirmed by clinicopathology and surgery, including 38 patients diagnosed to be positive through CT with a detection rate of 65.5%, 43 patients diagnosed to be positive through MR with a detection rate of 74.1%, and 53 patients diagnosed to be positive through combined diagnosis with a detection rate of 91.4%. According to statistical analysis, CT and MR showed no significant difference in detection of stress lesions in different femoral necks ( $P>0.05$ ). However, the amount of detection of stress lesions

**Table 3.** Grading of stress injury in all patients after MR examination (%).

| Grading | Cases | Proportion |
|---------|-------|------------|
| Level 0 | 0     | 0.0        |
| Level 1 | 3     | 5.2        |
| Level 2 | 9     | 15.5       |
| Level 3 | 12    | 20.7       |
| Level 4 | 19    | 32.8       |



**Figure 2.** Grading map of stress injury in all patients after magnetic resonance (MR) examination.

with both diagnostic methods was higher than that with the two separate detection methods, with statistically significant difference ( $P < 0.05$ ), as shown in Table 2 and Figure 1.

**Grading of stress injury in all patients after MR examination**

According to the statistical data, grading of stress injury in all patients after MR examination showed no cases for level 0; the proportion of levels 3 and 4 was the highest, accounting for 20.7% and 32.8% respectively. For details, please refer to Table 3 and Figure 2.

**Expression of all patients after CT scanning**

According to the statistical data, fracture lines were observed in 35 of patients in CT scans, of which 25 showed transparent

**Table 4.** Expression of all patients after CT scanning (%).

| Grading             | Cases | Proportion |
|---------------------|-------|------------|
| Fracture lines      | 35    | 60.3       |
| Periosteum reaction | 34    | 58.6       |
| Osteoporosis        | 30    | 51.7       |
| Porosis             | 32    | 55.2       |

lines and 10 showed strip-shaped dense shadows. The periosteum reaction was observed in 34 patients, including 18 with umbilical depression. Osteoporosis was observed in 30 patients, and the lesion showed a zone of reduced density in the cortical bone, with a stripelike shape and unclear boundary. Porosis was observed in 32 patients, with increased density in the medullary cavity. Refer to Table 4 for details.

**Detection of stress injury of femoral neck with different diagnostic methods**

According to the research data, compared with CT diagnosis, the accuracy, sensitivity, and specificity of MR detection were not significantly different ( $P > 0.05$ ). The accuracy, sensitivity, and specificity of the combined diagnosis were higher than those of CT and MR detection alone, with statistically significant differences between groups ( $P < 0.05$ ), as shown in Table 5.

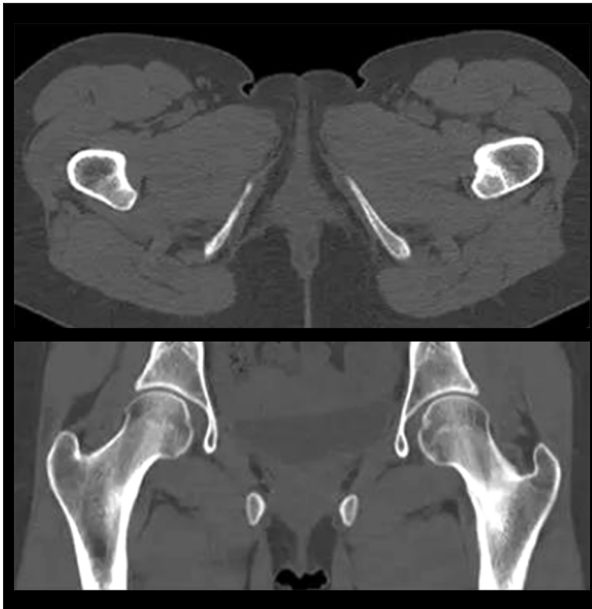
**Case analysis**

The patient was a 27-year-old female with left groin pain caused by excessive exercise, which became worse 3 weeks later. X-ray plain film showed no fracture or acute injury, but the symptoms continued for 2 weeks. Therefore, CT scan was continued and the left femoral neck bone cortical tissue structure was shown to be disordered, as shown in Figure 3. MR imaging scan showed that the left femoral neck fracture (FNF) was not accompanied by dislocation, and the fracture line wrapped about half the length of the femoral neck, as shown in Figure 4. The patient underwent partial weight-bearing activities after 6 weeks of nonweight-bearing rest according to the doctor's advice, returned to normal daily activities after 3 months, and the symptoms disappeared after 6 months. Follow-up CT showed that the fracture line healed well without any delayed healing or ischemic necrosis, as shown in Figure 5.

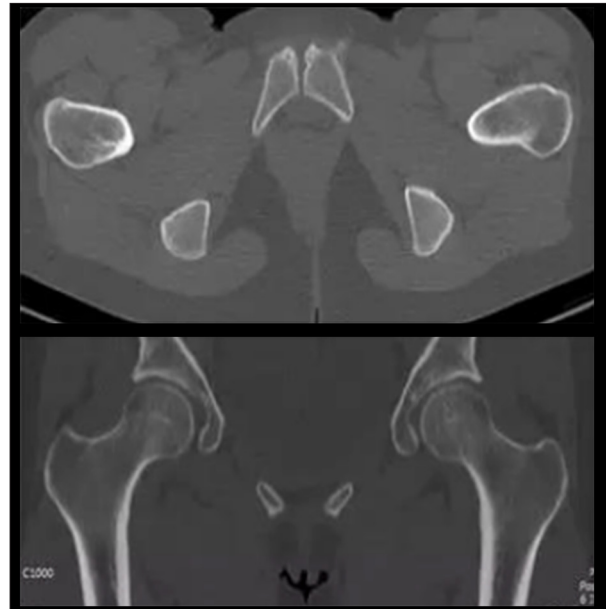
**Table 5.** Detection of stress injury of femoral neck in different diagnostic methods (%).

| Diagnostic mode    | Cases (n) | Accuracy | Sensitivity | Specificity |
|--------------------|-----------|----------|-------------|-------------|
| CT                 | 58        | 65.5     | 73.1        | 68.0        |
| MR                 | 58        | 74.1     | 82.5        | 79.4        |
| Combined diagnosis | 58        | 91.4     | 94.3        | 88.2        |

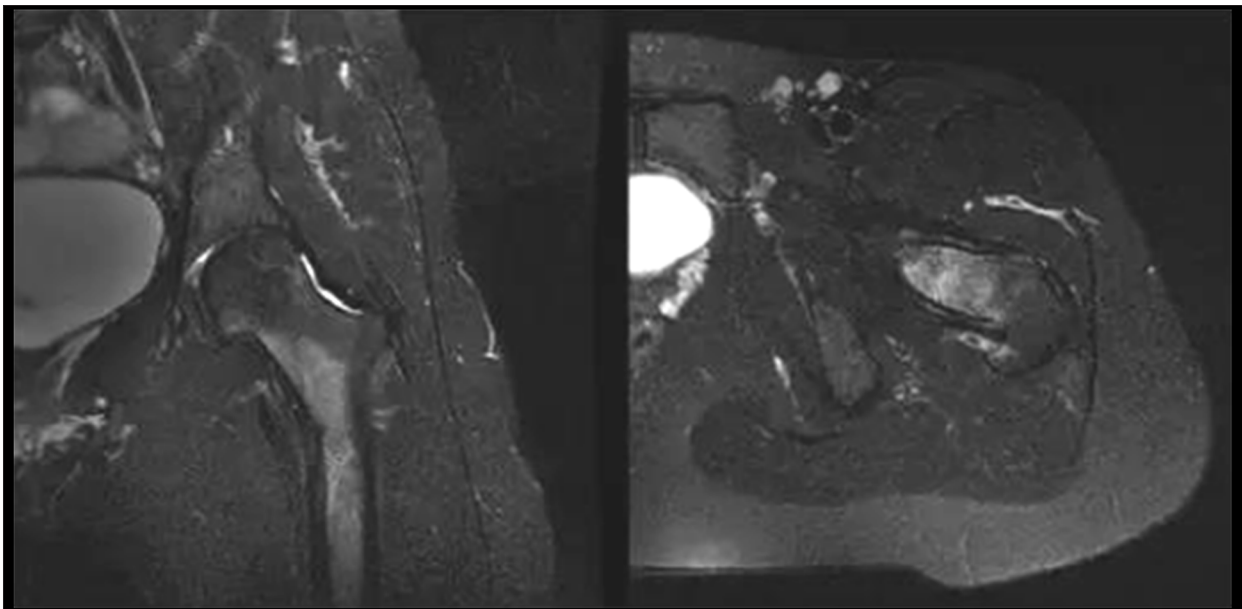
Compared with CT, MR  $P > 0.05$ , combined diagnosis  $P < 0.05$ ; Compared with MR, combined diagnosis  $P < 0.05$ .



**Figure 3.** Computed tomography (CT) scan: Cortical tissue of the left femoral neck.



**Figure 5.** Computed tomography (CT) follow-up: The fracture line healed well.



**Figure 4.** Magnetic resonance (MR) scan: Left femoral neck fracture (FNF) is not accompanied by dislocation, and the fracture line is about half the length of the femoral neck.

## Discussion

The stress injury of the femoral neck mainly occurs in athletes, dancers, recruits, elderly groups, and other specific groups, mainly because the muscles of patients are too tired to absorb the vibration generated by repeated collisions in a timely manner, and the stress is transmitted to the bones, resulting in small fractures or fractures [7]. If stress injury occurs in a bearing bone such as the tibia and fibula of crus, it may result

in sustained stress on the affected limb and prolong the clinical treatment. Therefore, stress injury is also known as fatigue injury or cumulative injury. Under such long-term, repeated, indirect, or direct injury, fracture may be induced in patients, affecting their daily life and even increasing the risk of femoral head necrosis [8]. It is suggested in the clinical study of Liu et al. [9] that stress injury serves as the key factor affecting the FNF healing and contributing to femoral head necrosis. In patients with normal physiological activity, the femoral neck



under load is essentially dynamic and a few are static, but the intense disturbance will lead to bone stress injury in which the femoral neck stiffness and elastic modulus will decrease as a result of increase of microcracks. In particular, when the strain in the femoral neck is already higher than the normal threshold, it will increase subtle damage and exceed the bone's ability to repair itself, which in the long run will increase the risk of bone brittleness and lead to bone collapse [10]. The clinical characteristics of femoral stress injury are accumulative and subtle, and early diagnosis is difficult. It is often misdiagnosed as neoplastic lesions or osteomyelitis, resulting in inappropriate treatment. Without timely and accurate identification, recovery from femoral injury is difficult, and it will evolve into a high-level injury, i.e., a stress fracture, which will seriously interfere with the daily activities and physical and mental health of patients. It is of great significance to explore a reliable examination method to improve the accuracy of early diagnosis of femoral stress injury. Once diagnosed, patients can effectively avoid further aggravation of the disease by implementing reasonable management of restricted activities within a very short period. In addition, accurate assessment of the patient's condition is of practical guiding significance to the necessity of surgical treatment. Early diagnosis and early treatment are also conducive to shortening the patient's course of disease and improving the prognosis.

In recent years, with changes in living environments and the increasing trend of population aging, age, environment, and other factors have led to an increase in the incidence of femoral neck stress injury. However, because of its slight clinical symptoms, fractures or hard injuries are usually rare, and are more common in vascular or soft tissue injuries. If the malformation and clinical signs of the patients are not obvious, the rate of misdiagnoses and missed diagnoses will become higher [11]. In the past, the application of plain X-ray film could only show the linear periosteum reaction with a small amount of shallow density and the expression was not obvious, so it was easily neglected. With the development and progress of clinical imaging technology, a variety of imaging diagnosis methods, mainly CT and MR, are used widely in early differential diagnosis of clinical diseases. In CT scanning, the precise collimation Y-ray, X-ray beam, or ultrasound can be applied to perform cross-sectional scanning of a certain part of the patient's body in combination with high-sensitivity detectors, which makes scanning images clearer and saves more time spent on diagnosis [12]. As a more advanced medical imaging, MR maintains the advantages of precision, safety, and no radiation in scanning, and can be used for multiangle, multiplane, and multisequence imaging with good imaging quality and high spatial resolution, which will show the bone and soft-tissue damage [13] at lesion positions in an all-round way compared with CT diagnosis. However, it is proposed in the study of Sun et al. [14] that CT diagnosis conducted for patients with femoral neck stress

injury in the early stage can solve image overlap, display fine details more clearly, and focus on the density of medullary cavity change, but it is still far from being ideal for the ligament injury due to trauma, and scans may be affected by partial volume effect, restricted by soft tissue resolution, misdiagnosis, and diagnosis. In view of this, it is proposed in the study of Hu et al. [15] that the combination of CT and MR can be applied for patients with femoral neck stress injury in the early differential diagnosis. The multisequence and multilayer scanning of the femoral neck position by MR will find the limited hemorrhage of bone marrow cavity, fracture line, and periosteum reaction timely, show the local callus formation or cortical thickening reaction clearly, and improve the diagnostic accuracy by combining CT and clinical signs.

The femoral neck stress injury is diagnosed by combination of CT and MR in this study and the outcome shows that there is significant difference between single diagnosis and combined diagnosis on articular swelling, calcification of the joint capsule, synovial swelling, synovial hernia, and hyperplasia of the joint surface, and the positive rate detected through combined diagnosis reached 91.4%. Meanwhile, the specificity and sensitivity of different diagnostic methods for clinical use were compared. There was no significant difference in the specificity and sensitivity of the single diagnosis, whereas the accuracy, sensitivity, and specificity of the combined diagnosis were higher, which was basically consistent with the results of Dareez et al. and Chilvers et al. [16,17]. It has been confirmed that CT and MR combined diagnosis is synergistic in minimizing misdiagnosis or missed diagnosis, and plays a positive role in realizing early accurate differential diagnosis. In this study, CT diagnosis shows clearly the fracture line, periosteum reaction, osteoporosis, callus formation, and other conditions, whereas MR diagnosis can grade the stress injury of patients. In the studies of Lee et al. [18], it was believed that the MR grading of stress injury of the femoral neck was directly related to clinical response and also the scale standard for the degree of stress injury, which had a positive effect on improving the prognosis. It was proposed in the study of Schoenfeld et al. [12] that with the combined diagnosis of CT and MR, changes in bone marrow signals could be identified to minimize the occurrence of high-level stress injury after treatment, namely, the occurrence of stress fracture.

## Conclusions

The application of MR combined with CT in early clinical diagnosis and treatment of femoral neck stress injury disease will improve the accuracy of clinical diagnosis. The imaging signals are obvious and conducive to further evaluating the severity of the disease and improving the prognosis.

## References:

1. Aghajanzadeh M, Asgary MR, Mohammadi F et al: An investigation into symptoms, diagnosis, treatment, and treatment complications in patients with retrosternal goiter. *J Family Med Prim Care*, 2018; 7(1): 224
2. Biz C, Berizzi A, Crimi A: Management and treatment of femoral neck stress fractures in recreational runners a report of four cases and review of the literature. *Acta Biomed*, 2017; 88(45): 96
3. Fan K-J, Chen K, Ma W-L et al: [Treatment of multi-segment fracture of complex femoral shaft with instrument-assisted reduction combined with intramedullary interlocking nail fixation.] *Zhongguo Gu Shang*, 2018; 31(5): 472–76 [in Chinese]
4. Trauma Orthopedics Group, Orthopedics Branch, Chinese Medical Association, Trauma Expert Working Committee, Orthopedics Branch, Chinese Medical Association: Guidelines for diagnosis and treatment of adult femoral neck fracture. *Chin J Trauma Orthop*, 2018; 20(11): 921
5. Vidiri A, Curione D, Piludu F et al: Non-squamous tumors of the oropharynx and oral cavity: CT and MR imaging findings with clinical pathologic correlation. *Curr Med Imag Rev*, 2017; 13(2): 166–75
6. Stambough JB, Nunley RM, Spraggs-Hughes AG et al: Clinical practice guidelines in action: Differences in femoral neck fracture management by trauma and arthroplasty training. *J Am Acad Orthop Surg*, 2018; 27(8): 287–94
7. An D, Li C, Shao G et al: Clinical observation of closed reduction and percutaneous cannulated screw fixation in treatment of femoral neck fracture in adolescents. *J Jilin Univ Med Ed*, 2017; 43(2): 396–401
8. Guan HZ, Ding Y, Li DX et al: [Clinical diagnosis and treatment of three cases with hyperornithinemia-hyperammonemia-homocitrullinuria syndrome.] *Zhong Er Ke Za Zhi*, 2017; 55(6): 428–33 [in Chinese]
9. Liu J, Zhen P, Zhou S-H et al: [Application of tri-lock bone preservation stem in acetabular protrusion combined with shorten defect of femoral head and neck.] *Zhongguo Gu Shang*, 2018; 31(2): 129–34 [in Chinese]
10. Cosman F, Miller PD, Williams GC et al: Eighteen months of treatment with subcutaneous abaloparatide followed by 6 months of treatment with alendronate in postmenopausal women with osteoporosis: Results of the ACTIVEExtend Trial. *Mayo Clin Proc*, 2017; 92(2): 200–10
11. Rohenaquiquilla IR, Rohenaquiquilla FJ, Scully WF et al: Femoral neck stress injuries: Analysis of 156 cases in a U.S. military population and proposal of a new MRI classification system. *Am J Roengenol*, 2018; 210(3): 1–7
12. Schoenfeld AJ, Tobert DG, Le HV et al: Utility of adding magnetic resonance imaging to computed tomography alone in the evaluation of cervical spine injury: A propensity-matched analysis. *Spine*, 2018; 43(3): 179–84
13. Saxena A, Behan SA, Valerio DL et al: Navicular stress fracture outcomes in athletes: Analysis of 62 injuries. *J Foot Ankle Surg*, 2017; 56(5): 943–48
14. Sun Q, Li G, Ge W et al: [Effectiveness analysis of surgical treatment of ipsilateral femoral neck fracture and subtrochanteric fracture.] *Zhongguo Xiu Chong Jian Wai Ke a Zhi*, 2017; 31(9): 1043–48 [in Chinese]
15. Hu ZS, Liu X-L, Zhang Y-Z: Comparison of proximal femoral geometry and risk factors between femoral neck fractures and femoral intertrochanteric fractures in an elderly Chinese population. *Chin Med J (Engl)*, 2018; 131(21): 2524–30
16. Dareez NM, Dahlslett KH, Engesland E et al: Scaphoid fracture: Bone marrow edema detected with dual-energy CT virtual non-calcium images and confirmed with MRI. *Skel Radiol*, 2017; 46(12): 1753–56
17. Chilvers G, Janjua U, Choudhary S: Blunt cervical spine injury in adult polytrauma: Incidence, injury patterns and predictors of significant ligament injury on CT. *Clin Radiol*, 2017; 72(11): 907–14
18. Lee JM, Lee YS, Kim YB et al: What effects does necrotic area of contrast-enhanced MRI in osteoporotic vertebral fracture have on further compression and clinical outcome? *J Korean Neurosurg Soc*, 2017, 60(2): 181–88