

Review began 09/08/2021
Review ended 09/23/2021
Published 09/24/2021

© Copyright 2021

Allawati et al. This is an open access article distributed under the terms of the Creative Commons Attribution License CC-BY 4.0., which permits unrestricted use, distribution, and reproduction in any medium, provided the original author and source are credited.

Colonic Lipoma as a Leading Cause of Intussusception Resulting in Bowel Obstruction

Meetham Allawati¹, Tagalsir Logman², Murtadha T. Al Qubtan²

1. Medicine and Health Sciences, Sultan Qaboos University, Muscat, OMN 2. General Surgery, Royal Hospital, Muscat, OMN

Corresponding author: Meetham Allawati, allawati01@gmail.com

Abstract

A colon lipoma is defined as a benign tumor made of adipose tissue present in the submucosa. Lipomas of the colon are unusual with a frequency of 0.035%-4.4%. We present an uncommon case of a 41-year-old female with left colonic lipoma causing intussusception. The patient presented with abdominal pain at the left iliac fossa. She underwent an emergency exploratory laparotomy plus left hemicolectomy and was followed in the surgical out-patient clinic postoperatively. She was found doing well taking a normal diet and having normal bowel habits. The overall prognosis depends on the complete removal of the tumor.

Categories: General Surgery

Keywords: case report, intussusception, colonic lipoma, lipoma, bowel obstruction

Introduction

A colon lipoma is defined as a benign tumor made of adipose tissue present in the submucosa [1]. Lipomas of the colon are unusual with a frequency of 0.035%-4.4% [2]. Small lipomas are generally asymptomatic; on the other hand, large lipomas are symptomatic and may result in intussusception and intermittent colonic obstruction. Symptoms include abdominal pain, constipation, lower gastrointestinal bleeding and intussusception [3]. We present an uncommon case of left colonic lipoma causing intussusception.

Case Presentation

A 41-year-old female with no previous comorbidity and no significant medical history presented with a history of abdominal pain at the left iliac fossa (LIF), which was relieved by defecation. She had four previous lower segment cesarian sections (LSCS) the last one being seven years back and an umbilical hernia repair six years back. The patient had constipation for over a few weeks. She felt nauseated and had episodes of vomiting and passed a bloody diarrhea stool. On physical examination, there was tenderness at the LIF with a mild abdominal distention. The patient was stable, appeared to be in pain, afebrile, the abdomen was flatulent, the heart rate was 95/min, and the respiratory rate was 19/min. Laboratory findings were as follows: hemoglobin 13.8 g/dL, hematocrit : 41.3%, platelets 462,000/mm³, and white count 7,500/mm³.

A CT abdomen with oral and IV contrast showed an intussusception of the proximal part of the descending colon into its distal part (Figure 1), with a lead of the intussusception in the colonic lipoma measuring 4.6 x 4.2 cm (Figures 2, 3). The length of the intussuscepted segment was about 14 cm. There was a small amount of fluid and gas trapped between the intussusceptum and the intussusciptien. The proximal large bowel loops were distended measuring 5 cm in the transverse colon, and 6.5 cm maximum diameter of the cecum. The small bowel loops were normal in diameter and no evidence of obstruction was seen.

How to cite this article

Allawati M, Logman T, Al Qubtan M T (September 24, 2021) Colonic Lipoma as a Leading Cause of Intussusception Resulting in Bowel Obstruction. Cureus 13(9): e18261. DOI 10.7759/cureus.18261

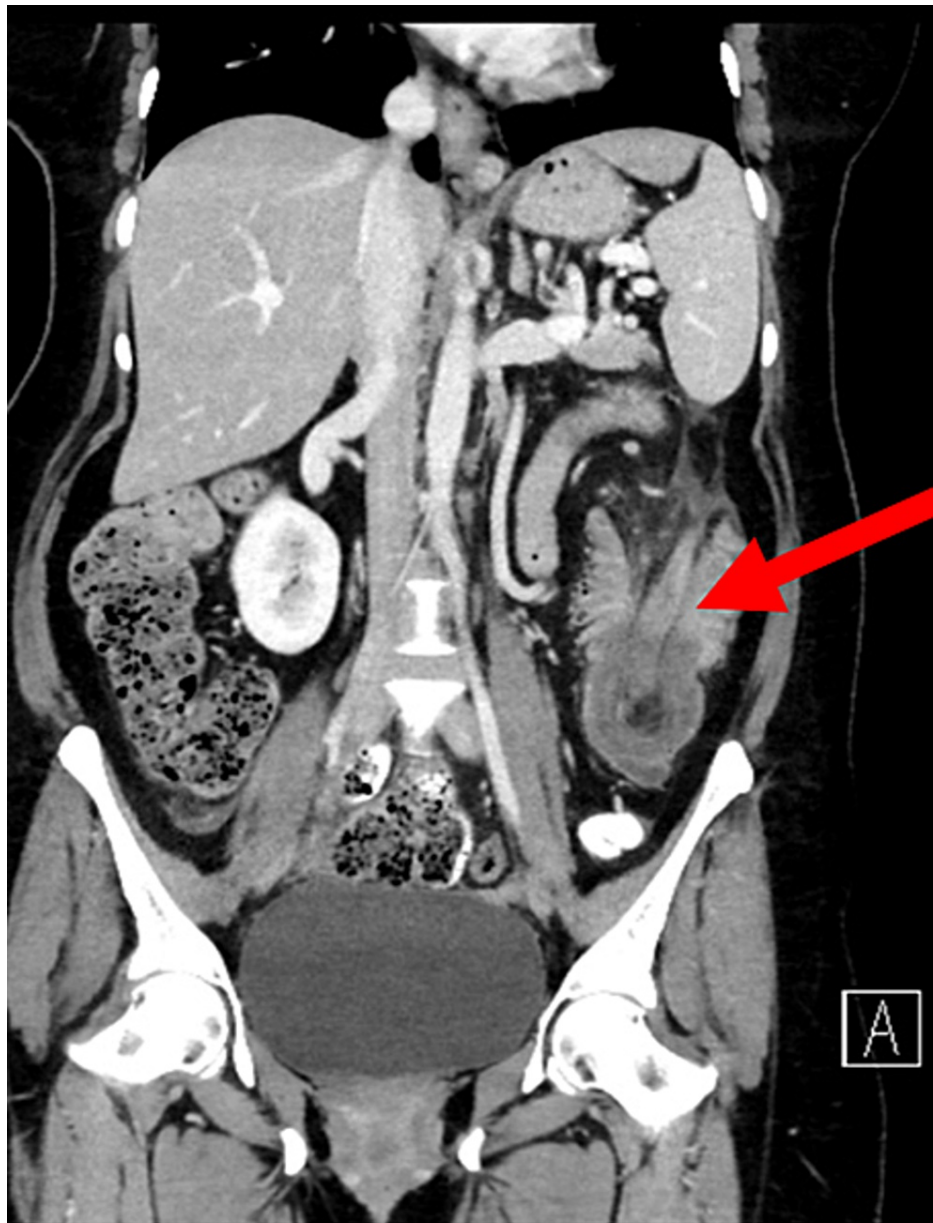


FIGURE 1: Coronal CT scan showing intussusception

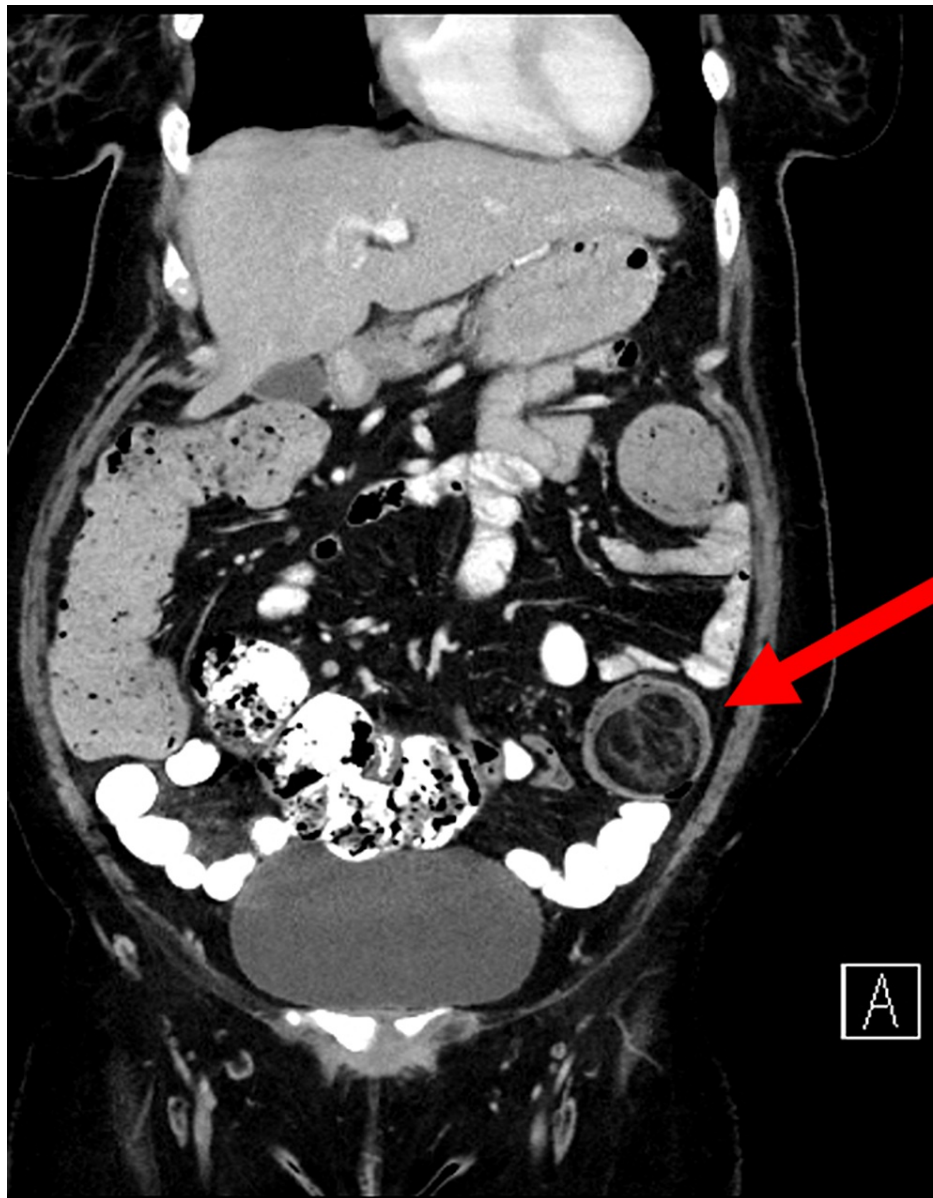


FIGURE 2: Coronal CT scan showing lipoma

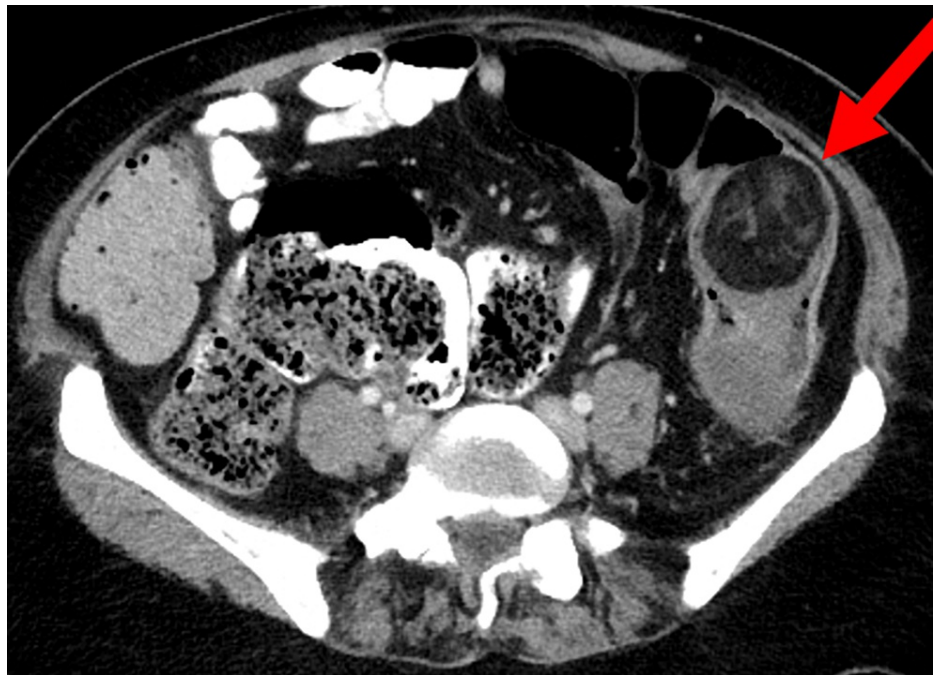


FIGURE 3: Axial CT scan showing lipoma

A colonoscopy was done and the finding was a large mass lesion in the descending colon obstructing the lumen and the scope could not be passed beyond the mass. The patient was taken for surgery and underwent exploratory laparotomy and left hemicolectomy. The specimen was sent to the pathology lab and it confirmed a benign lipoma.

The patient stayed few days in the hospital and the post-operative period was uneventful. The histopathology showed an ulcerated lipomatous lesion with hemorrhagic necrosis and perforation. Thirteen reactive lymph nodes were identified with the specimen. The margins were clear. The patient was followed in the surgical out-patient clinic postoperatively and was found doing well taking a normal diet and having normal bowel habits.

Discussion

Lipomas of the colon were described for the first time by Bauer in 1757 [3,4]. They are relatively rare. Lipomas of the colon are generally asymptomatic, while large ones are associated with complications, so they may require surgery [5]. Most of the patients with intussusception are children, as only 5% of the cases occur in adults [6,7]. Approximately 90% of intussusceptions in adults are caused by an anatomic or pathologic disease. In adults, idiopathic instances without a lead point lesion are uncommon, accounting for 8%-20% of cases. The occurrence of intussusception is low in adults, especially in the descending colon. This is due to the fact that the descending colon has an anatomical attachment to the retroperitoneum [6]. The most frequent sites in the gastrointestinal tract where intussusception occur are the junctions between freely moving segments and the ones fixed by the retroperitoneum or adhesions [7,8]. The exact mechanism of the intussusception of the proximal colon into the distal colon is unknown in adults. It is thought that any lesion within the lumen or in the wall of the bowel that changes the normal peristaltic activity may initiate the intussusception process [7]. In adults, up to 30% of intussusception cases in the small intestine are malignant, while up to 66% of cases of intussusception in the large intestine are malignant [7,9-11]. In most of the adult cases, the treatment of intussusception is surgical, depending on the preoperative diagnosis, size, location of the lipomas, and complications. The majority of authors recommend the excision of the lipomas bigger than 2 cm, especially in the old people, in whom intussusception is more linked to malignancy [12,13]. The prognosis depends on the complete removal of the tumor [13].

Conclusions

In conclusion, the patient presented with signs of abdominal obstruction. Further investigations including a CT scan showed an intussusception with this case. The patient was treated surgically, which is the treatment of choice for such conditions. Even though colonic lipomas are rare, they should be put in the differential diagnosis of bowel tumors presenting with symptoms.

Additional Information

Disclosures

Human subjects: Consent was obtained or waived by all participants in this study. **Conflicts of interest:** In compliance with the ICMJE uniform disclosure form, all authors declare the following: **Payment/services info:** All authors have declared that no financial support was received from any organization for the submitted work. **Financial relationships:** All authors have declared that they have no financial relationships at present or within the previous three years with any organizations that might have an interest in the submitted work. **Other relationships:** All authors have declared that there are no other relationships or activities that could appear to have influenced the submitted work.

References

1. Farfour AN, AbuOmar NA, Alsohaibani FI: Large lipoma of the ascending colon: a case report and review of literature. *J Surg Case Rep*. 2020, 2020:rjaa554. [10.1093/jscr/rjaa554](https://doi.org/10.1093/jscr/rjaa554)
2. Yaman İ, Dericı H, Demirpolat G: Giant colon lipoma. *Ulus Cerrahi Derg*. 2015, 31:102-4. [10.5152/UCD.2013.15](https://doi.org/10.5152/UCD.2013.15)
3. Moussally M, Mokalled I, Jamali F, Khalife MJ: Splenic flexure colonic lipoma causing intussusception. *JRSM Open*. 2021, 12:2054270420983088. [10.1177/2054270420983088](https://doi.org/10.1177/2054270420983088)
4. Mason R, Bristol JB, Petersen V, Lyburn ID: Gastrointestinal: lipoma induced intussusception of the transverse colon. *J Gastroenterol Hepatol*. 2010, 25:1177. [10.1111/j.1440-1746.2010.06360.x](https://doi.org/10.1111/j.1440-1746.2010.06360.x)
5. Nallamotheu G, Adler DG: Large colonic lipomas. *Gastroenterol Hepatol (N Y)*. 2011, 7:490-2.
6. M'rabet S, Jarrar MS, Akkari I, et al.: Colonic intussusception caused by a sigmoidal lipoma: a case report. *Int J Surg Case Rep*. 2018, 50:1-4. [10.1016/j.ijscr.2018.06.009](https://doi.org/10.1016/j.ijscr.2018.06.009)
7. Khan Z, Darr U, Renno A, Alkully T, Rafiq E, Sodeman T: Transient descending colocolonic intussusception due to a large fecaloma in an adult. *ACG Case Rep J*. 2017, 4:e94. [10.14309/crj.2017.94](https://doi.org/10.14309/crj.2017.94)
8. Loukas M, Pellerin M, Kimball Z, de la Garza-Jordan J, Tubbs RS, Jordan R: Intussusception: an anatomical perspective with review of the literature. *Clin Anat*. 2011, 24:552-61. [10.1002/ca.21099](https://doi.org/10.1002/ca.21099)
9. Eisen LK, Cunningham JD, Aufses AHJ: Intussusception in adults: institutional review. *J Am Coll Surg*. 1999, 188:390-5. [10.1016/s1072-7515\(98\)00331-7](https://doi.org/10.1016/s1072-7515(98)00331-7)
10. Begos DG, Sandor A, Modlin IM: The diagnosis and management of adult intussusception. *Am J Surg*. 1997, 173:88-94. [10.1016/S0002-9610\(96\)00419-9](https://doi.org/10.1016/S0002-9610(96)00419-9)
11. Takeuchi K, Tsuzuki Y, Ando T, Sekihara M, Hara T, Kori T, Kuwano H: The diagnosis and treatment of adult intussusception. *J Clin Gastroenterol*. 2003, 36:18-21. [10.1097/00004836-200301000-00007](https://doi.org/10.1097/00004836-200301000-00007)
12. Cordeiro J, Cordeiro L, Póssa P, Candido P, Oliveira A: Intestinal intussusception related to colonic pedunculated lipoma: a case report and review of the literature. *Int J Surg Case Rep*. 2019, 55:206-9. [10.1016/j.ijscr.2019.01.042](https://doi.org/10.1016/j.ijscr.2019.01.042)
13. Pintor-Tortolero J, Martínez-Núñez S, Tallón-Aguilar L, Padillo-Ruiz FJ: Colonic intussusception caused by giant lipoma: a rare cause of bowel obstruction. *Int J Colorectal Dis*. 2020, 35:1973-7. [10.1007/s00384-020-03629-4](https://doi.org/10.1007/s00384-020-03629-4)