



# Severe exacerbation of immune thrombocytopenia and COVID-19: the favorable response to corticosteroid-based therapy—a case report

Zhiliang Hu<sup>1,2</sup> · Wei Chen<sup>3</sup> · Wenyan Liang<sup>4</sup> · Chuanjun Xu<sup>5</sup> · Wenkui Sun<sup>4</sup>  · Yongxiang Yi<sup>1</sup>

Received: 16 April 2020 / Accepted: 28 April 2020 / Published online: 4 June 2020  
© Springer-Verlag GmbH Germany, part of Springer Nature 2020

Dear Editor,

Immune thrombocytopenia (ITP) is an immune-mediated hematologic condition, characterized by isolated thrombocytopenia due to immune disorder [1]. Some other reasons were in association with ITP, including viral infection [1, 2]. Many viruses have been identified as a trigger of the autoimmune process. It is reported that thrombocytopenia is common among patients infected with Dengue virus and Zika virus [3]. Recently, the emerged novel coronavirus diseases 2019 (COVID-19) became a serious public health concern [4]. Acute exacerbation of thrombocytopenia during the course of COVID-19 has not been reported yet.

Here, we describe a patient with COVID-19 pneumonia who received maintenance immunosuppressive drugs for chronic ITP. There was a fast progression of thrombocytopenia during the initial 4 inpatient days. Methylprednisolone-based treatment was added to treat thrombocytopenia. Thrombocytopenia and pneumonia both relieved quickly.

A 72-year-old female patient (51 Kg) was admitted to hospital with productive cough for 5 days and fever for 1 day. Diagnosis of SARS-COV-2 infection was confirmed with positive quantitative reverse transcription polymerase chain reaction (qRT-PCR) result on throat swab samples (Fig. 1A). The qRT-PCR was performed every other day to monitor the existence of severe acute respiratory syndrome (SARS)-COV-2 [5]. She had a history of idiopathic thrombocytopenic purpura for about 2 years and currently received immunosuppressive therapy with prednisone (10 mg/d) and cyclosporine (50 mg/d). On admission, the baseline blood lymphocyte count was  $2.55 \times 10^9/L$ , and the platelet count was  $61 \times 10^9/L$ , respectively (Fig. 1B). Chest computed tomography (CT) scanning on day 1 revealed peripheral ground-glass opacity in the right lower lobe. Oral antiviral therapy with arbidol was administered. However, the treatment did not improve the patient's clinical symptoms. A CT scanning on day 4 revealed prominently enlarged area of pneumonia. In addition, platelet count of the patient was  $18 \times 10^9/L$ . Thrombocytopenia did not respond to intravenous immunoglobulin and platelet transfusion. Methylprednisolone (40 mg/d, intravenously) was then included into the treatment. Thrombocytopenia quickly went into remission (Fig. 1B). Chest CT follow-up after 3 days of application of methylprednisolone-based treatment suggested a slightly improvement. Methylprednisolone was administered for a total of 5 days. The platelet count remained normal, and COVID-19 pneumonia continued to improve during the following days despite the persistence of SARS-COV-2 in throat swab samples.

The pathophysiology of ITP remains incompletely understood. Immune disorders, such as immune dysfunction, immune-mediated platelet destruction, inhibition of platelet release by megakaryocytes, and abnormalities in T cells, were related to ITP pathogenesis [1]. Glucocorticoid treatment is the standard initial therapy for patients with ITP. The patient's favorable response to methylprednisolone suggested that acute exacerbation

✉ Wenkui Sun  
sunwenkui@njmu.edu.cn

✉ Yongxiang Yi  
ian0126@126.com

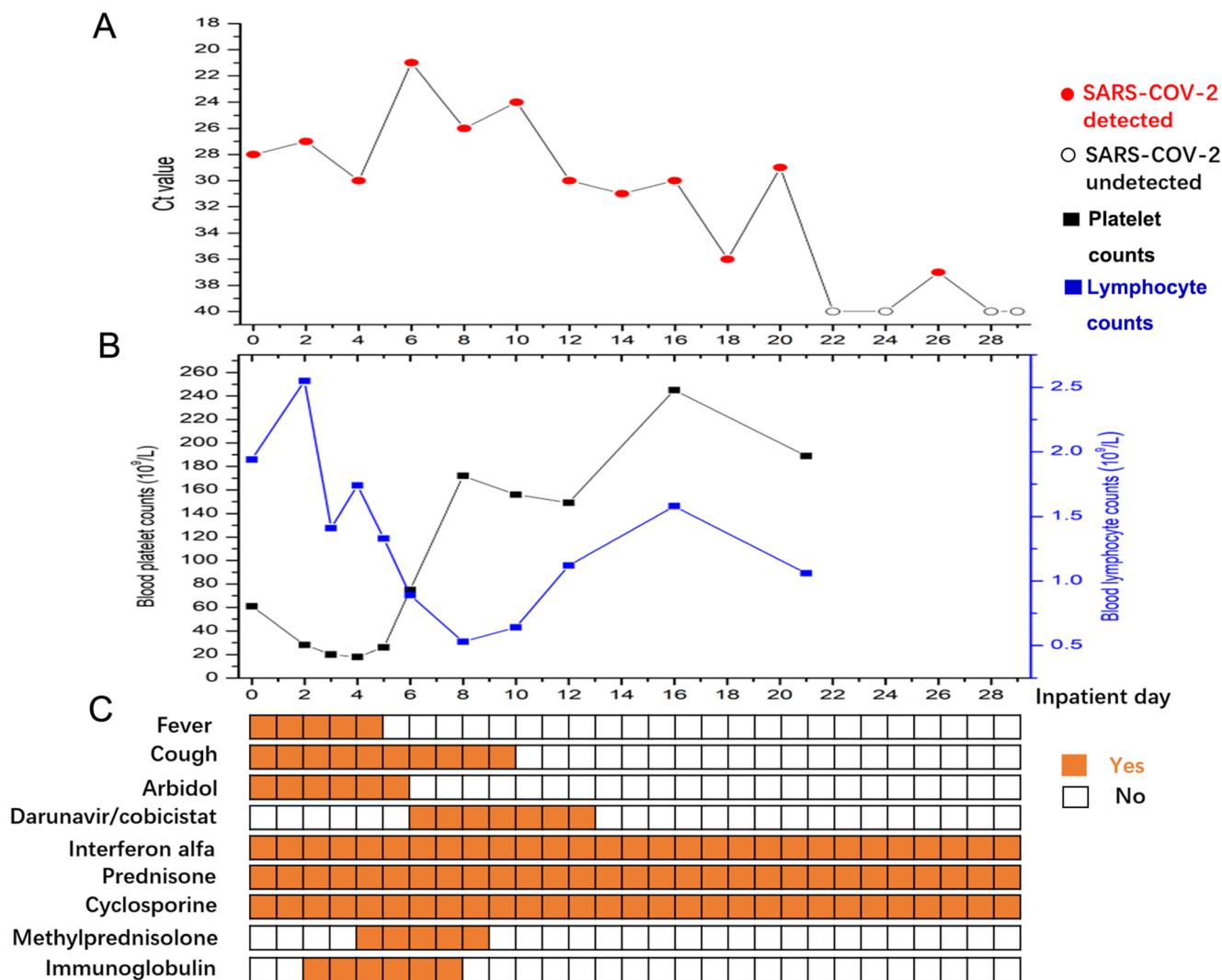
<sup>1</sup> Nanjing Infectious Disease Center, The Second Hospital of Nanjing, Nanjing University of Chinese Medicine, Nanjing 210003, China

<sup>2</sup> Center for Global Health, School of Public Health, Nanjing Medical University, Nanjing 211166, China

<sup>3</sup> Department of Clinical Research Center, The Second Hospital of Nanjing, Nanjing University of Chinese Medicine, Nanjing 210003, China

<sup>4</sup> Department of Respiratory & Critical Care Medicine, The First Affiliated Hospital of Nanjing Medical University, 300 Guangzhou Road, Nanjing 210029, China

<sup>5</sup> Department of Radiology, The Second Hospital of Nanjing, Nanjing University of Chinese Medicine, Nanjing 210003, China



**Fig. 1** Summary of main clinical features, laboratory parameters, and treatment of the patient (a) Dynamic changes of SARS-CoV-2 viral loads evaluated by specific quantitative reverse transcription polymerase chain reaction (qRT-PCR) of the throat swab samples. SARS-CoV-2 were continually detected for about 3 weeks. There was a weak positive result on day 26 after two 2 consecutively negative qRT-PCR. (b) Progressive depletion of lymphocytes and platelets during early

inpatient days. (c) Clinical features and treatments of the patient. The dosage of the drug: Arbidol (0.2 g, every 8 h); darunavir/cobicistat (0.95 g per day); interferon alfa (500 WU, twice a day, aerosol inhalation); prednisone (10 mg per day); ciclosporin (50 mg, twice a day); methylprednisolone (40 mg per day, intravenously); immunoglobulin (20 g per day, intravenously); platelet transfusion (1 unit per day)

of thrombocytopenia and progression of pneumonia in our patient were probably associated with immune-mediated damages. Infection of some viruses has been proposed to immune disorders, such as complement activation and development of antiplatelet IgM antibodies and autoantibodies against endothelial and blood coagulation pathway cells that cross-react with platelets [6]. Furthermore, autopsy of patients with COVID-19 also revealed severe immune-mediated injury [7].

Taken together, we proposed that immune-mediated damages may be activated by SARS-CoV-2 and play an important role in the pathogenesis of thrombocytopenia and COVID-19.

**Funding information** This study was funded in part by the National Natural Science Foundation of China (NSFC 81770009), project of Jiangsu province medical youth talent (QNRC2016059), and Nanjing Medical Science and Technique Development Foundation (ZKX17040). The funders had no role in study design, data collection and analysis, decision to publish, or preparation of the manuscript.

### Compliance with ethical standards

**Conflict of interest** The authors declare that they have no conflict of interest.

**Ethics approval and consent to participate** All procedures performed in studies involving human participants were in accordance with the ethical standards of the institutional and/or national research committee and with

the 1964 Helsinki Declaration and its later amendments or comparable ethical standards. This study was approved by the ethical committee of the second hospital of Nanjing (reference number 2020-LS-ky003).

**Informed consent** Written informed consent was obtained from the patient.

## References

1. Cooper N, Ghanima W (2019) Immune thrombocytopenia. *N Engl J Med* 381(10):945–955. <https://doi.org/10.1056/NEJMcp1810479>
2. Karimi O, Goorhuis A, Schinkel J, Codrington J, Vreden SGS, Vermaat JS, Stijns C, Grobusch MP (2016) Thrombocytopenia and subcutaneous bleedings in a patient with Zika virus infection. *Lancet* 387(10022):939–940. [https://doi.org/10.1016/S0140-6736\(16\)00502-X](https://doi.org/10.1016/S0140-6736(16)00502-X)
3. Sharp TM, Munoz-Jordan J, Perez-Padilla J, Bello-Pagan MI, Rivera A, Pastula DM, Salinas JL, Martinez Mendez JH, Mendez M, Powers AM, Waterman S, Rivera-Garcia B (2016) Zika virus infection associated with severe thrombocytopenia. *Clin Infect Dis* 63(9):1198–1201. <https://doi.org/10.1093/cid/ciw476>
4. WHO (2020) Coronavirus disease (COVID-19) Pandemic. <https://www.who.int/emergencies/diseases/novel-coronavirus-2019>. Accessed 16 Apr
5. Hu Z, Song C, Xu C, Jin G, Chen Y, Xu X, Ma H, Chen W, Lin Y, Zheng Y, Wang J, Hu Z, Yi Y, Shen H (2020) Clinical characteristics of 24 asymptomatic infections with COVID-19 screened among close contacts in Nanjing. *China Science China Life sciences* 63:706–711. <https://doi.org/10.1007/s11427-020-1661-4>
6. Van Dyne EA, Neaterour P, Rivera A, Bello-Pagan M, Adams L, Munoz-Jordan J, Baez P, Garcia M, Waterman SH, Reyes N, Richardson LC, Rivera-Garcia B, Sharp TM (2019) Incidence and outcome of severe and nonsevere thrombocytopenia associated with Zika virus infection-Puerto Rico, 2016. *Open Forum Infect Dis* 6(1):ofy325. <https://doi.org/10.1093/ofid/ofy325>
7. Xu Z, Shi L, Wang Y, Zhang J, Huang L, Zhang C, Liu S, Zhao P, Liu H, Zhu L, Tai Y, Bai C, Gao T, Song J, Xia P, Dong J, Zhao J, Wang FS (2020) Pathological findings of COVID-19 associated with acute respiratory distress syndrome. *Lancet Respir Med* 8(4):420–422. [https://doi.org/10.1016/s2213-2600\(20\)30076-x](https://doi.org/10.1016/s2213-2600(20)30076-x)

**Publisher's note** Springer Nature remains neutral with regard to jurisdictional claims in published maps and institutional affiliations.