

# A rare case of *Mycoplasma*-induced rash and mucositis in a 44-year-old female patient



Anne-Sophie Smilga, MD,<sup>a,c</sup> Suzel Fournier, MD,<sup>a,c</sup> H el ene Veillette, MD, FRCPC,<sup>a,c</sup>  
Marie- eve L egar e, MD, FRCSC,<sup>b,c</sup> and Martin Gilbert, MD, FRCPC<sup>a,c</sup>  
Quebec, Quebec, Canada

**Key words:** drug reactions; female adult patient; mucocutaneous eruptions; mycoplasma-induced rash and mucositis.

## INTRODUCTION

*Mycoplasma*-induced rash and mucositis (MIRM), also referred to as “reactive infectious mucosal-predominant eruption,” is a relatively newly described entity. Differential diagnosis includes erythema multiforme, Stevens-Johnson syndrome (SJS), and toxic epidermal necrolysis. It is characterized by clinical symptoms of pneumonia, including fever and cough, and by mucosal lesions that usually affect 2 or more sites. In about half of the reported cases, it is also accompanied by a cutaneous eruption that is often vesiculobullous and sometimes presents with typical and atypical target lesions. It has been mostly reported in children and young adolescents with a mean age of 12 years, and it affected males in two-thirds of the reported cases.<sup>1,2</sup>

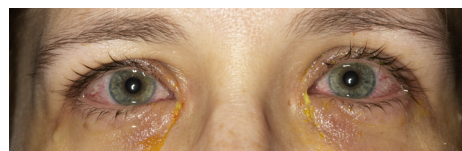
Here, we report an unusual case of MIRM occurring in a middle-aged female.

## CASE REPORT

A 44-year-old Caucasian woman presented to the emergency department complaining of productive cough with fever for the previous month and painful mucosal lesions for the previous week, with no other pertinent past medical history. She had been taking lamotrigine and levothyroxine for 20 years without interruption, with no other recent medications. Physical examination revealed marked bilateral conjunctival injection (Fig 1), with 360-degree ulcerations of the bulbar conjunctiva and palpebral margins. There was no epithelial deficit on the forniceal and palpebral conjunctiva or on the cornea. She had several erosions and ulcers, 1–2 cm in diameter, on the entire oral mucosa (Fig 2) and, to a lesser extent,

### Abbreviations used:

EM:	erythema multiforme
MIRM:	<i>mycoplasma</i> -induced rash and mucositis
PCR:	polymerase chain reaction
SJS:	Stevens-Johnson syndrome
TEN:	toxic epidermal necrolysis



**Fig 1.** Marked bilateral conjunctival injection with 360-degree ulcerations of the bulbar conjunctiva and palpebral margins.

on the labia minora of the vulva. Hemorrhagic crusts were also seen on the nasal mucosa. A dozen erythematous papules and vesicles, a few millimeters in diameter, were scattered on the limbs (Fig 3), and there was one atypical target lesion on the left arm (Fig 4). Laboratory studies showed a WBC count of  $1042 \times 10^9/L$  ( $N = 420\text{--}1000$ ) with neutrophil count of  $7230 \times 10^9/L$  ( $N = 1900\text{--}7000$ ) and C-reactive protein level of 254 mg/L ( $N < 10$  mg/L). Renal function and liver enzyme levels remained normal. Herpes simplex polymerase chain reaction (PCR) was negative for both the lesions of the lips and the conjunctiva. Serum IgM for *M pneumoniae* was positive, and nasopharyngeal swab for *M pneumoniae* PCR was also positive. PCR for *Chlamydia pneumoniae*, *Bordetella pertussis*, and common viruses, including severe acute respiratory syndrome coronavirus 2, were all negative.

From the Department of Dermatology,<sup>a</sup> and Department of Ophthalmology and Ear, Nose, and Throat,<sup>b</sup> Laval University, Quebec, and Centre Hospitalier Universitaire de Quebec.<sup>c</sup>

Funding sources: None.

Conflicts of interest: None disclosed.

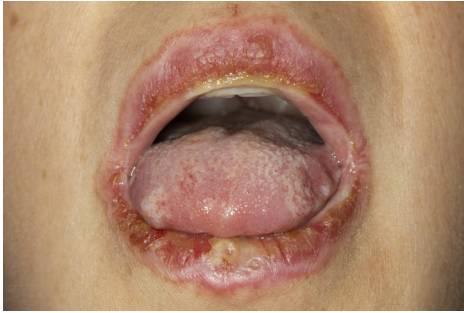Correspondence to: Anne-Sophie Smilga, MD, 745-1 rue Sainte-Madeleine, Quebec, Quebec, Canada G1R 3M5. E-mail: anne-sophie.smilga.1@ulaval.ca.

JAAD Case Reports 2020;6:1333-5.

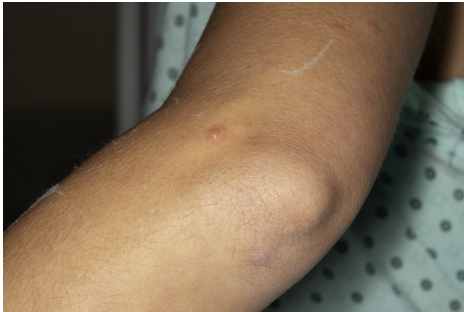2352-5126

  2020 by the American Academy of Dermatology, Inc. Published by Elsevier, Inc. This is an open access article under the CC BY-NC-ND license (<http://creativecommons.org/licenses/by-nc-nd/4.0/>).

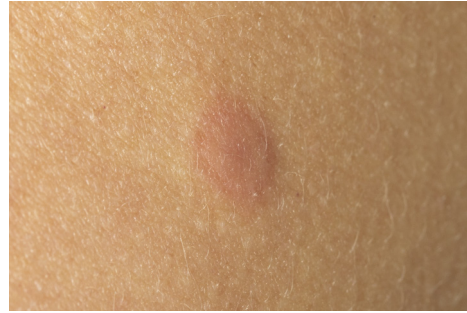<https://doi.org/10.1016/j.jdc.2020.09.014>



**Fig 2.** Erosions and ulcers on the oral mucosa.



**Fig 3.** Scattered erythematous papules and vesicles on the limbs.



**Fig 4.** One atypical target lesion on the left arm.

Chest X-ray revealed a pulmonary infiltrate in the lower portion of the right lung lobe. Skin biopsy revealed interface dermatitis with numerous basal necrotic keratinocytes.

Based on these findings, MIRM was diagnosed.

In addition to dermatologists, a multidisciplinary team was involved in the treatment, including infectious disease experts, ophthalmologists, gynecologists, otolaryngologists, and nutritionists. The patient was admitted and successfully treated with clarithromycin, 500 mg orally twice daily for 14 days, and oral prednisone that was started at 50 mg daily (1 mg/kg/day) and then tapered over 10 days. Local treatments included mouthwash with lidocaine, dexamethasone elixir, and prednisolone 1% eye drops. Amniotic membrane grafts were also placed over the entire conjunctival mucosa of both eyes in the form of biological bandages with local anti-inflammatory and antiscarring effects. The patient was hospitalized for a total of 13 days until complete healing of all mucous membranes and skin lesions was achieved.

## DISCUSSION

*M pneumoniae* infection that was ascertained using PCR and an extensive involvement of the ocular, nasal, oral, and genital mucosae was confirmed as classic MIRM due to the sparse and mainly distally distributed cutaneous vesiculobullous lesions. MIRM

sine rash and severe MIRM, which are the two other types of MIRM, present with no significant cutaneous rash and widespread non-mucosal blisters or flat, atypical target lesions.<sup>1</sup>

Although only recently described, MIRM is now a well-recognized distinct entity. It is almost exclusively seen in the pediatric population, probably because *M pneumoniae* infections tend to be more symptomatic in this age group.<sup>3</sup> Only four case reports of MIRM in adults were found in the literature, including three men (26-, 27-, and 42-years-old) with classic MIRM and one 46-year-old man with MIRM skin rash.<sup>4,5,6,7</sup> There is a known male predominance in MIRM, with 66% of the identified cases occurring in males, and this predominance may even be more pronounced in the adult population. There is some evidence that men develop more severe lung disease in response to *M pneumoniae* infections as compared to women.<sup>8</sup> The question is whether this also applies to the skin. To our knowledge, our patient represents the first case of an adult female diagnosed with classic or any other type of MIRM.

Regardless of the age and sex of the patient, MIRM is an important diagnosis to consider when a patient presents with an acute mucocutaneous eruption. Indeed, the main differential considerations for MIRM are erythema multiforme, SJS, and toxic epidermal necrosis, and early diagnosis is important for its appropriate management.<sup>1</sup> Caution must be exercised when interpreting the histopathology report because there is nothing pathognomonic for MIRM and it can encompass well-described features of EM and SJS/TEN.<sup>1</sup>

MIRM patients generally have a good prognosis overall and respond well to oral antibiotics (e.g., azithromycin or clarithromycin) and immunosuppressive therapy, such as systemic corticosteroids.<sup>1,2</sup> However, the prevention of severe long-term ocular sequelae, such as those seen in SJS, warrant early and aggressive ophthalmological intervention. In the current case, the medical team kept a

low threshold of suspicion for MIRM, despite the patient being an adult woman, which allowed early diagnosis and rapid implementation of the appropriate treatment.

#### REFERENCES

1. Frantz GF, McAninch SA. Mycoplasma Mucositis. In: *StatPearls [Internet]*. Treasure Island, FL: StatPearls Publishing; 2020.
2. Varghese C, Sharain K, Skalski J, Ramar K. Mycoplasma pneumonia-associated mucositis. *BMJ Case Rep*. 2014;2014.bcr2014203795.
3. Kashyap S, Sarkar M. Mycoplasma pneumonia: clinical features and management. *Lung India*. 2010;27(2):75.
4. Vujic I, Shroff A, Grzelka M, et al. *Mycoplasma pneumoniae*-associated mucositis: case report and systematic review of literature. *J Europ Acad Dermatol Venereol*. 2014;29(3):595-598.
5. Figueira-Coelho J, Lourenço S, Pires AC, Mendonça P, Malhado JA. *Mycoplasma pneumoniae*-associated mucositis with minimal skin manifestations. *Am J Clin Dermatol*. 2008;9(6):399-403.
6. Song H, Huang JT, Tan JK. Mycoplasma-induced rash and mucositis in a father and son. *Ped Infect Dis J*. 2018;37(7):e205-e206.
7. Yancey AL, Watson HL, Cartner S, Simecka JM. Gender is a major factor in determining the severity of mycoplasma respiratory disease in mice. *Infect Immun*. 2001;69(5):2865-2871.
8. Zão I, Ribeiro F, Rocha V, Neto P, Matias C, Jesus G. *Mycoplasma pneumoniae*-associated mucositis: a recently described entity. *Europ J Case Rep Intern Med*. 2018;5(11):000977.