

Managing transvenous right ventricular leads in the era of transcatheter tricuspid valve interventions



Rand Ibrahim, MD, Neal Bhatia, MD, FHRS, Faisal M. Merchant, MD, FHRS, Mikhael F. El-Chami, MD

From the Division of Cardiology-Section of Electrophysiology, Emory University School of Medicine, Atlanta, Georgia.

Introduction

Tricuspid regurgitation (TR) is commonly encountered in patients with transvenous right ventricular (RV) pacing or implantable cardioverter-defibrillator (ICD) leads.^{1,2} Possible etiologies for TR in the presence of transvenous leads include lead impingement of the tricuspid valve (TV) leaflets or papillary muscles. Non-lead-related mechanisms for TR may also contribute, even if transvenous leads are present. Managing TR by extracting a long-indwelling lead is often unsuccessful in reversing the regurgitation and could result in further damage to the TV apparatus.³ Transcatheter TV interventions (TTVI) are increasingly performed as part of clinical trials or off-label use for patients deemed high-risk for surgical repair or replacement. TTVI may result in “jailing” of transvenous RV pacing and ICD leads, which can result in lead damage. Furthermore, this has serious implications on the ability to extract these leads if needed in the future.

Case report

A 73-year-old male patient had a history of dilated cardiomyopathy and mitral valve prolapse status post bioprosthetic mitral valve replacement in 1979 and redo mitral valve replacement with a mechanical mitral valve and TV repair with an annuloplasty ring in 1990. He had a single-chamber ICD implanted in 2006, with a Riata lead (St. Jude, Minneapolis, MN), and an upgrade to cardiac resynchronization therapy (CRT) defibrillator in 2020 owing to progressive conduction system disease and increased burden of RV pacing. The Riata lead had been followed serially with normal function. At the time of CRT upgrade in 2020, minimal externalization of conductors between the RV and superior vena cava coils was noted but the lead was otherwise performing normally, with stable electrical parameters, and was therefore retained.

KEYWORDS Tricuspid valve; Percutaneous repair; Jailed RV lead; Transcatheter valve replacement; Fractured lead
(Heart Rhythm Case Reports 2022;8:692–694)

Funding Sources: None. Disclosures: MFE is a consultant for Medtronic and Boston Scientific. **Address reprint requests and correspondence:** Dr Mikhael El-Chami, Medical Office Tower 12th Floor, 550 Peachtree St NE, Atlanta, GA 30308. E-mail address: melcham@emory.edu.

KEY TEACHING POINTS

- Transcatheter tricuspid valve replacement is increasing.
- Pacing or ICD leads are at risk of damage by transcatheter replacement.
- Managing pacing and ICD system at time of transcatheter tricuspid valve replacement might require placement of valve sparing pacing and ICD leads.

He was referred to the structural heart team with progressive TR and annuloplasty ring dehiscence and perivalvular leak, ultimately classified as torrential. The patient was deemed high-risk for open valve repair, and subsequently underwent valve-in-ring TTVI using a 29 mm SAPIEN 3 valve and the use of 2 4.5 x 36 mm endografts filled with a 48 mm Gore ASO device (Figure 1), which resulted in jailing of the RV lead. Postoperatively, the RV lead was noted to have low impedance (<200 ohms), “make and break” noise signals compatible with lead fracture, and drop in R-wave sensing from 11 mV to 2 mV. Lead revision was planned. An echocardiogram after the TTVI showed an ejection fraction of 40%–45%. Given the improvement in ejection fraction and no history of VT, it was decided to revise the system into a CRT-pacing system while avoiding crossing the new valve. A new bipolar left ventricular lead was placed in the anterior-interventricular vein (AIV). The patient left the hospital with a pacing lead in the AIV, a quadripolar pacing lead from 2020 in a lateral coronary sinus (CS) branch, an atrial lead in the right atrial appendage, and a jailed RV ICD lead.

After discharge, he presented 6 days after lead revision with syncope and sustained monomorphic ventricular tachycardia (VT) (rate 170 beats/min) requiring cardioversion in the emergency room. He was having frequent premature ventricular contractions originating from the RV base of similar morphology to the VT. Amiodarone was started owing to recurrence of VT. These premature ventricular contractions

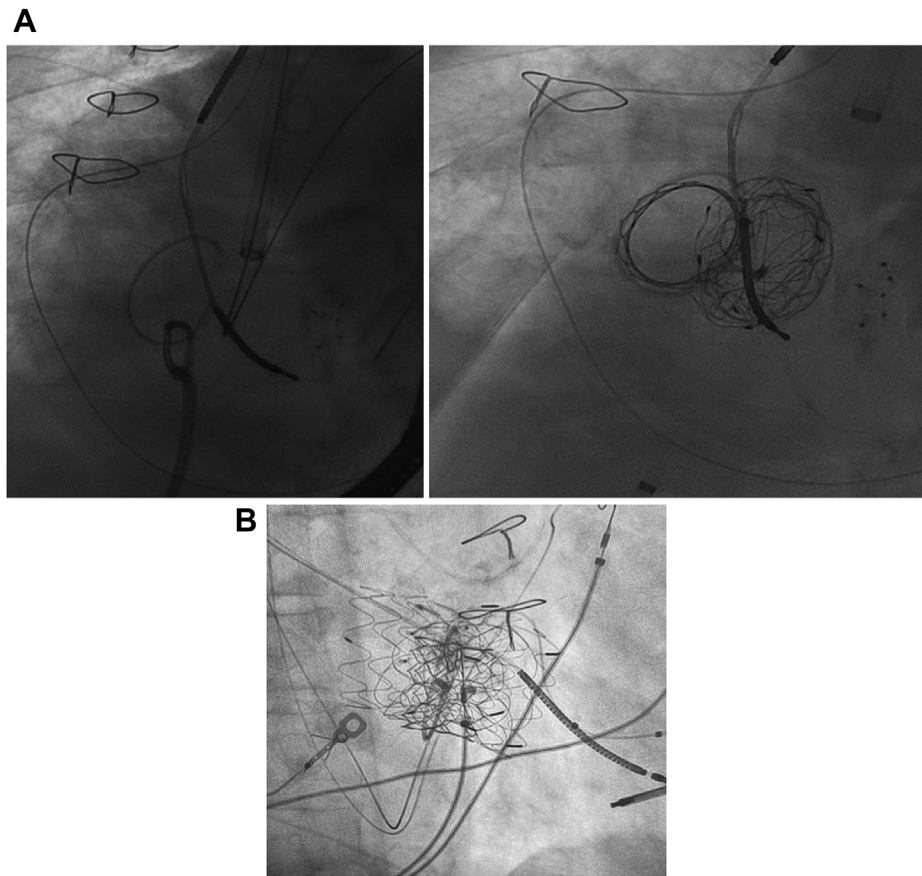


Figure 1 A: Left anterior oblique cine pre and post percutaneous valve and closure device deployment. B: Right anterior oblique cine showing the implantable cardioverter-defibrillator lead and the percutaneous tricuspid valve

and VT were thought to be related to the recent TTVI based on morphology originating from the RV base.

Given the sustained VT and syncope, an ICD was deemed necessary for secondary prevention of sudden cardiac death.

Multiple options were considered: (1) adding an azygous or a CS coil, (2) implanting a subcutaneous ICD, and (3) adding a subcutaneous array (Medtronic 6996SQ).

The subcutaneous ICD was not pursued because of the likely need for antitachycardia pacing and sensing. We opted to implant a subcutaneous coil to avoid placing additional transvenous hardware. Additionally, placing a coil in the CS would have resulted in 3 leads in the CS with potential for dislodging the recently placed AIV lead, which was needed for sensing and pacing.

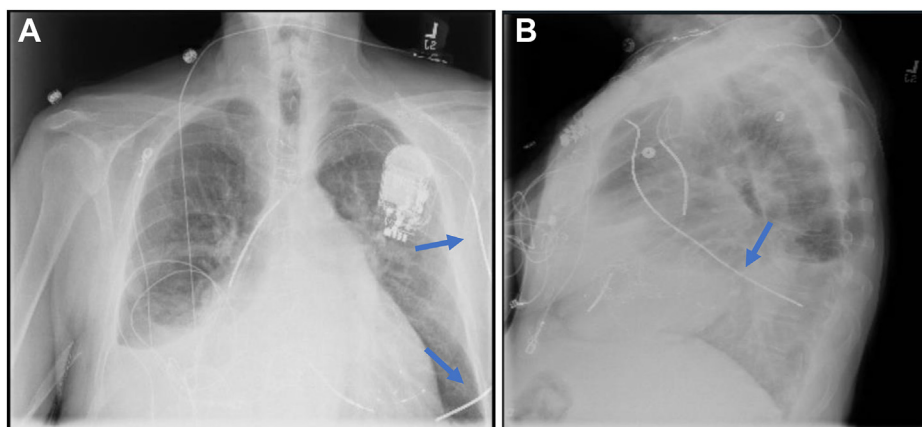


Figure 2 A, B: Chest radiograph after introducing the subcutaneous array (blue arrow).

Under therapeutic international normalized ratio (2.8), a subcutaneous array was tunneled laterally and posteriorly. This coil was used as a substitute for an RV coil (cathode +) and the ICD can was used as the anode (-). Defibrillation testing was successful at 30 joules. A postprocedure chest radiograph shows the posteriorly directed subcutaneous array ([Figure 2](#)).

Discussion and conclusion

Valvular interventions for severe TR will continue to increase, as percutaneous TTVI are currently undergoing clinical trials. Many of these patients with TR also have an indwelling cardiac implantable electronic device with leads across the TV. TTVI in those patients is feasible but may result in lead damage from mechanical forces during TTVI. Electrophysiology consultation is warranted in these patients, especially in those who are pacemaker-dependent patients or require a defibrillator. Tricuspid-sparing pacing and defibrillator systems have been described to avoid crossing a surgically repaired/replaced TV. In a small series, Blank and colleagues⁴ described the use of CS coils with or without

additional subcutaneous coils and epicardial or CS pacing to provide a functional ICD system while sparing the TV. Here, we present a case that illustrates the consequences of TTVI in patients with a cardiac implantable electronic device. This patient was managed by adding a subcutaneous coil without the use of an intravascular coil (azygos, superior vena cava, or CS coil). This approach is potentially less invasive and could be an option, particularly in patients with limited vascular access.

References

1. Chang JD, Manning WJ, Ebrille E, Zimetbaum PJ. Tricuspid valve dysfunction following pacemaker or cardioverter-defibrillator implantation. *J Am Coll Cardiol* 2017;69:2331–2341.
2. Tatum R, Maynes EJ, Wood CT, et al. Tricuspid regurgitation associated with implantable electrical device insertion: a systematic review and meta-analysis. *Pacing Clin Electrophysiol* 2021;44:1297–1302.
3. Park SJ, Gentry JL 3rd, Varma N, et al. Transvenous extraction of pacemaker and defibrillator leads and the risk of tricuspid valve regurgitation. *JACC Clin Electrophysiol* 2018;4:1421–1428.
4. Blank E, Shah AD, Rosenblum JM, Lloyd MS. "Valve-sparing" transvenous defibrillator systems after tricuspid valve intervention. *Heart Rhythm* 2021; 18:2212–2214.